

Dermis fat Graft in the Management of Contracted Anophthalmic Socket

Trishulamurthy Chinmayee J¹, Swathi M¹, Samhitha HR²

¹Ophthalmology, Minto Ophthalmic Hospital, Bangalore Medical College and Research Institute, Bangalore, India

²Ophthalmology, Ex-Senior Resident, Minto Ophthalmic Hospital, Bangalore Medical College and Research Institute, Bangalore, India

Corresponding author: Dr. Swathi M, Address: Senior Resident, Department of Ophthalmology, Minto Ophthalmic Hospital, Bangalore Medical College and Research Institute, Opp. Tipu Sultan Palace, New Tharagupet-560002, Bangalore, India, Phone number: +91 9481446708, E-mail address: swathichakrapani93@gmail.com

Received: 5-6-2022, Accepted: 14-8-2022, Published online:16-9-2022

EJO(MOC) 2022;0:00-00.

Running title: DFG in contracted socket.

Abstract:

Purpose: Contracted anophthalmic socket poses a challenge to the ophthalmologist in terms of patient comfort and cosmesis. Dermis fat graft can be performed as a primary procedure following destructive surgeries or as a secondary procedure for mild contracted anophthalmic socket.

Aims: To analyse the effectiveness of dermis fat graft in all grades of contracted anophthalmic socket.

Settings and Design: Retrospective interventional study in a tertiary oculoplasty centre in south India.

Methods and Material: Twenty-three patients with anophthalmic socket of varying degree underwent dermis fat grafting harvested from the gluteal region. Post operatively, patients were followed up to one year. Customized prosthesis fitting was done after 6 weeks.

Results: Most common indication for enucleation was retinoblastoma (43.37%) followed by trauma (39.13%). Most of the patients presented with grade III contracture (43.47%). Post-operative complications included graft ulceration (8.6%), loss of volume (8.6%) and lower lid ectropion (4.3%) which were managed medically. Most (78.26%) of patients had uneventful post-operative course. 82.61% of patients had grade 0 contracture at end of follow up. All the patients had acceptable prosthesis fit.

Conclusions: Dermis fat graft gives good results with respect to volume replacement, cosmesis and artificial prosthesis fit for all grades of contracture.

Key-words: Dermis fat graft, contracted socket, prosthesis

INTRODUCTION:

Contracted socket is one where there is a difficulty in implanting the prosthesis.¹ It leads to volume loss, scarring and loss of fornices and sometimes bony contracture as well.

Contracted socket is caused due to fibrosis of the soft tissues and scarring following enucleation and evisceration. It is seen in about 7.7% of cases of enucleation.² Chronic infection and inflammation can also lead to fibrosis. Growth retardation of bony orbit was seen in children with enucleation done before 1 year of age.³ The most common cause is absence of orbital implant.² Non-compliance with wearing of

prosthesis, too, can lead to contracture of the socket.¹ Other causes include severe trauma causing loss of tissue, excessive removal of conjunctiva or Tenon's capsule during surgery, radiation induced fibrosis, chemical injury, alkali injuries and scarring due to multiple procedures.¹⁻⁵

Dermis fat graft may be performed as a primary procedure to replace orbital volume after enucleation and evisceration, or as a secondary procedure in case of extrusion/exposure of implant, chronic socket infection and post-enucleation socket syndrome.⁵ It has shown good results in reconstruction of mild contracted sockets with good vascularity.⁵

Though there are other methods of reconstruction of the orbit, dermis fat graft is autologous and hence has less chances of rejection and foreign body reaction. It has less chances of graft migration. It can be performed by a trained ophthalmologist with minimum equipment. This is a study to analyze the effectiveness of dermis fat graft in the management of all the grades of contracted anophthalmic socket.

METHODOLOGY:

It is a retrospective interventional case series. After obtaining clearance from institutional ethics committee, 23 patients with contracture of anophthalmic socket who were willing to give informed consent were included in the study. They were treated with dermis fat graft and additional lid procedures wherever necessary.

Patients were evaluated in detail with thorough history, noting the causes for anophthalmos, duration of anophthalmos, previous surgical orbital reconstruction (if any) and number of previous surgeries. Time since non-fitting of ocular prosthesis were noted. Any associated ptosis, ectropion, entropion and any other diseases were noted. The severity of contracture was graded according to Krishna classification.⁶

Krishna Classification of Grading of contracted socket:

Grade 0: Socket is lined by healthy conjunctiva and has deep and well formed fornices.

Grade I: Shallow lower fornix or shelving of lower fornix.

Grade II: Loss of upper and lower fornix

Grade III: Loss of upper, lower, medial and lateral fornices.

Grade IV: Loss of all fornices and reduction of dimensions of vertical and horizontal palpebral apertures.

Grade V: Recurrence of contracture after repeated trial of reconstruction.

Dermis fat graft procedure:

Patients were operated under general anesthesia or local anesthesia.

Preparation of the bed: Host bed was infiltrated with 7 ml of 2% xylocaine. Existing orbital implant, if present was removed. Conjunctiva was incised and Tenon's capsule was identified. Scar tissue and fibrous tissue was excised. Edges of the extra ocular muscles were identified wherever possible. Fornix deepening sutures were placed inferiorly whenever necessary.

Harvesting the graft: Graft site was infiltrated with 5ml of 2% xylocaine. Intra-dermal injection of five ml of 0.9% saline was given to delineate a plane. Dermis with fat of approximately 1x2x2cm size was harvested from the gluteal area. The epidermis was scraped off using scalpel No. 15 blade. Harvested graft was placed in the socket with the dermis toward the conjunctiva and the conical fat toward the apex, and sutured to the muscle ends with 5-0 Polyglactin. Dermis was sutured to the edge of the anterior Tenon's capsule, conjunctiva was overlapped on the dermis by 1mm, taking care to keep the edge everted. The wound was closed and a large conformer was placed.

Post operatively, patients were given prophylactic oral antibiotics for five days and topical antibiotic ointment for the donor site and recipient site for 7 days. Donor site was examined and dressing was changed every day. Suture removal was done from donor site after tenth post-operative day. Recipient site was assessed regularly for progress, to look for complications, rejection, fitting of prosthesis and grading of socket up to one year.

Patients were referred to ocularist for customised prosthesis after 6 weeks.

Data was analysed using SPSS version 20. Descriptive statistics like mean, percentage, standard deviation were used to analyse the data.

RESULTS:

Twenty-three patients in age group from 1.5 to 55 years (mean 17 ± 14 years) underwent dermis fat graft. Of these, 13(56.5%) patients were female, 10 (43.5%) patients were male. Ten (43.5%) patients were less than 10 years of age.

Twenty-two patients (95.7%) were operated for post enucleation socket syndrome and one (4.3%) for congenital anophthalmos. Two patients (8.70%) underwent primary dermis fat graft following enucleation. Rest of the patients (n=21, 91.30%) underwent secondary dermis fat graft procedures.

Etiology of anophthalmos:

The most common indications for enucleation was Retinoblastoma (n=11, 43.47%), followed by trauma (n=9, 39.13%). Other causes included painful blind eye (n=1, 4.34%) and endophthalmitis (n=1, 4.34%). (Figure 1). This

correlates with the finding that retinoblastoma is the most common indication for enucleation in patients less than 10 years of age.

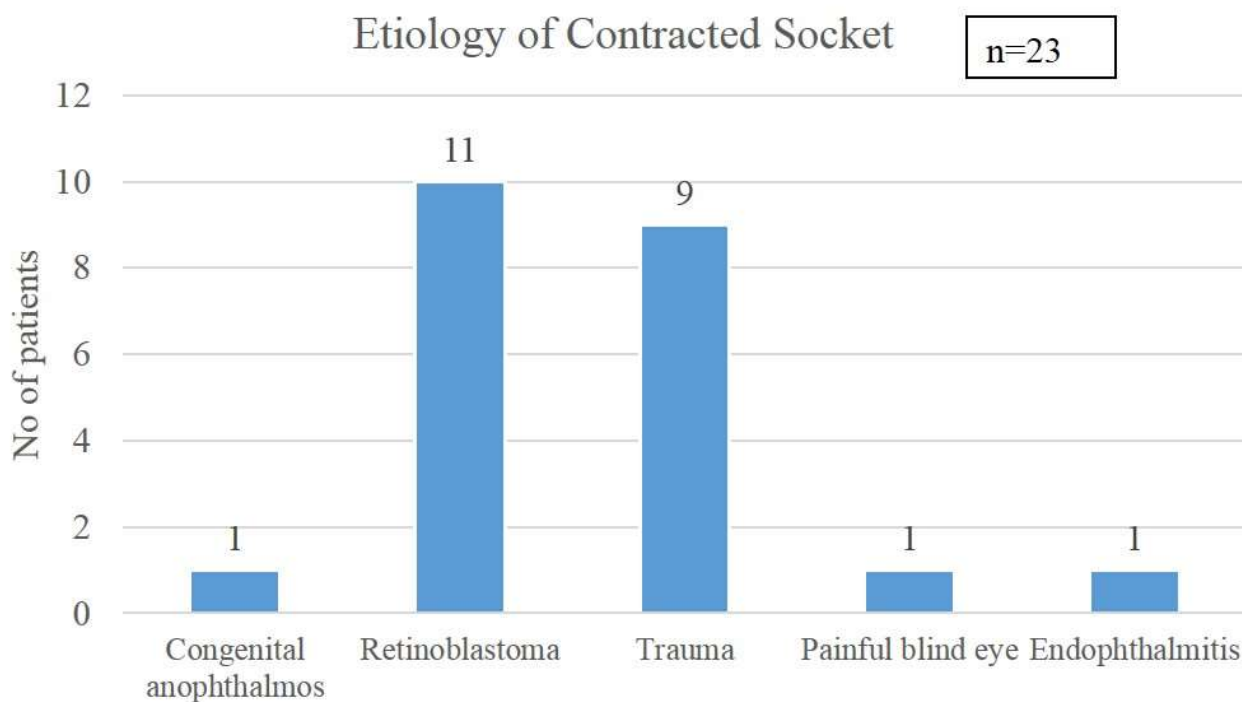


Figure-1: Etiology of contracted socket

Severity of contracture at presentation:

The severity of contracture at presentation is shown in Table 1. Ten patients had grade III socket contracture at presentation (43.37%). Three patients (13.04%) had grade IV contracture. Of these, one patient (4.34%) had history of trauma, one patient (4.34%) did not undergo primary orbital implant placement, and one patient (4.34%) underwent external beam radiotherapy for retinoblastoma after enucleation.

Interval between primary surgery to dermis fat graft ranged from 1 to 30 years. It was seen that longer the interval, greater was the degree of contracture.

Table 1: Grading of contracted socket

Grade	Number of patients	Percentage
Grade I	1	4.3%
Grade II	9	39.13%
Grade III	10	43.47%
Grade IV	3	13.04%

Most of the cases of retinoblastoma and trauma had higher grades of contracture (Grade III and IV) of socket. (Figure-2) This could be due to the younger age at enucleation leading to higher degree of scarring in children.

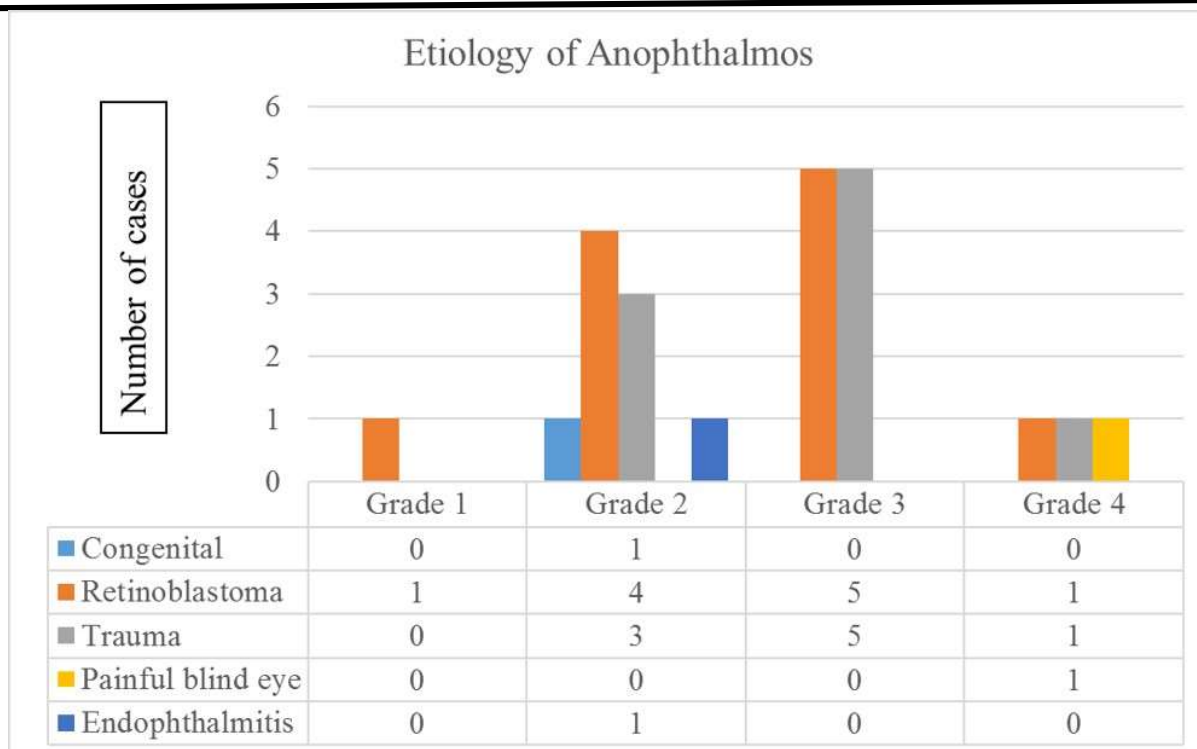


Figure-2: Distribution of cases with respect to grade of contracture

Additional procedures: Eight patients (34.78%) underwent fornix deepening sutures and two patients (8.69%) underwent lid reconstruction with anterior lamellar graft along with dermis fat graft. But all of these 10 patients in our study had good post-operative results during the follow up period.

Post-operative course:

Majority of the patients (n=18, 78.26%) had uneventful post-operative period. (Figure-3)

Early post-operative graft ulceration was seen in two patients (8.70%). Daily dressing and gentle debridement was done and patients were started on a second oral antibiotic for one week. The ulcer healed by the end of one week and patients were carefully monitored till the end of two months. Two patients (8.70%) had loss of volume due to fat loss which were managed by adjustment of prosthesis size by the ocularist. Mild lower lid ectropion was seen in one patient (4.3%), but lower fornix was deep and ocular prosthesis fit well

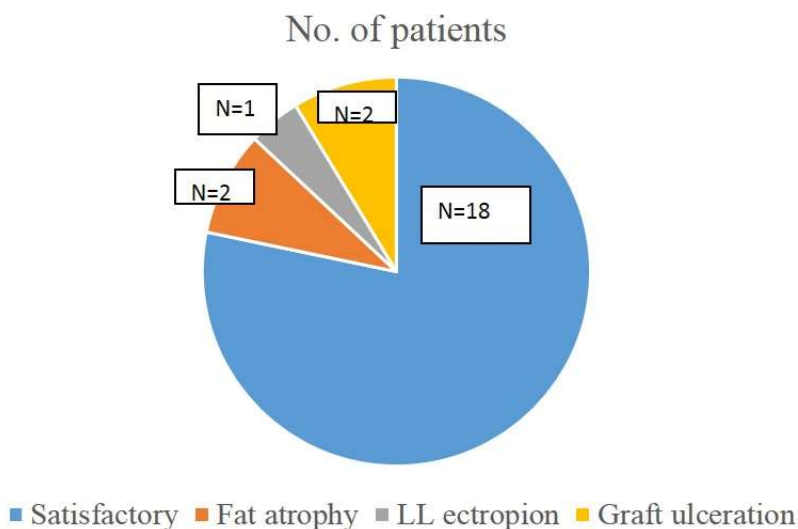


Figure-3: First year post-operative outcome after dermis fat graft

Post-operative outcome:

At the end of the follow up period, nineteen patients (82.61%) had a satisfactory outcome: that is, no contracture, four (17.39%) patients had grade I contracture. Among these, two

(8.69%) patients had history of trauma, one patient (4.34%) had retinoblastoma, one patient (4.34%) had history of irradiation for retinoblastoma (Figure-4).

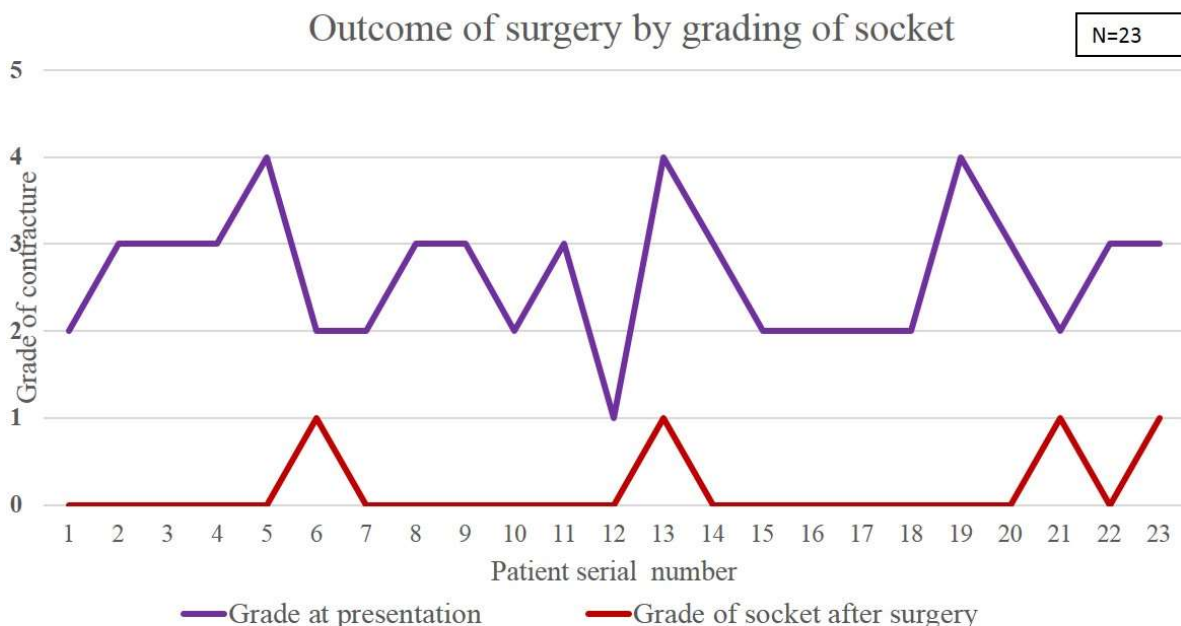


Figure-4: Grade of socket contracture before and after dermis fat graft

DISCUSSION:

Dermis fat graft was introduced by Smith et al in 1978.⁷ As primary procedure, it has shown good results in children as the graft expanded with growth of the orbital bones whereas it showed variable and unpredictable resorption in adults resulting in contracture of socket.¹

In our study, most of our patients had history of retinoblastoma (n=10, 47.82%) and five (50%) of them had grade III contracture. Nine patients had history of trauma (39.13%). Among them, five patients (55.56%) had grade III contracture. This could be due to the loss of conjunctiva and Tenon’s capsule due to the trauma, scarring and fibrosis due to the injury, improperly sized implant, not placing implant during primary procedure, cicatrix formation due to multiple procedures. Loss of eye before two years of age can also lead to bony contracture.

A retrospective study done in Thailand evaluated the profile and outcome in 41 patients receiving dermis fat graft as a primary or secondary procedure. They found that the most

common indication was exposure of implant followed by extrusion of the implant. Eleven of the patients receiving dermis fat graft underwent destructive procedures following trauma. This study showed good results with respect to cosmetic outcome and patient acceptance in primary and secondary dermis fat graft at the end of one year.⁷ They also concluded that dermis fat graft alone gave better results (73.3%) than in those cases which were combined with mucous membrane graft (25%).⁷ In our study, all the 10 patients who required additional lid reconstruction procedures had good post-operative results during the follow up period. A study by Galindo-Ferreiro and others also showed good results with dermis fat graft (88.7% success rate) and recommend this procedure for primary and secondary orbital reconstruction.⁸

A review by Jovanovic N and others has shown that in adults, primary dermis-fat graft showed lesser fat atrophy than secondary grafting. They hypothesize that scarring and loss of vascularity of socket in cases of secondary grafting may be the causative factor. They also found better cosmetic results in

primary grafting (83.3% success rate) with better prosthesis fit, patient satisfaction and lesser chances of superior fornix shortening, than with secondary grafting (37.5%). They recommend primary dermis-fat grafting in both adult and pediatric age groups.⁹ But a study conducted by Bhattacharjee and others found that porous orbital implant with mucus membrane grafting had a better cosmetic outcome (59%) than dermis fat graft (39.2%) in reconstruction of a severely contracted anophthalmic socket.¹⁰ In our study, both primary and secondary grafting showed good outcome with 19 patients (82.61%) showing no contracture and prosthesis fit was good in all patients (100%). Primary dermis fat graft can prevent severe contracture of sockets and give a better cosmesis and reduce need for future surgeries.

The complications of dermis fat graft are infection, ulceration, recurrence, fat necrosis, atrophy, graft failure,¹ donor site infection, under-sized graft,¹⁶ non-healing of donor site wound.⁸ Most of these can be managed medically with good results. The chances of foreign body reaction and asymptomatic socket pain was found to be lesser in patients who underwent dermis fat graft as compared to orbital implants.¹³ We did not see graft rejection in any of our patients in the study. Epidermoid cyst formation, keratinization, growth of hair (due to retained hair follicles) and discharge were seen in patients where the epidermis was not removed completely. A study done by Diab and Alahmadawy showed that these complications were less common in patients where epithelium was removed using scalpel as compared to electro-coagulation, although the cosmetic outcome was comparable between the two methods of epidermis removal.¹⁷ In our study all patients had epithelium removed from the graft with scalpel No.15 blade before implantation and we saw none of above complications in any of the patients. Mukherjee B describes a technique of measuring the size of the conical dermis fat graft by using Archimedes principle of displacement of water. This helps to avoid under-sized and over-sized grafts.¹⁶

Post enucleation socket syndrome can be minimized to a great extent by proper technique of enucleation, creating adequate fornices during primary surgery to allow for the 15% decrease in orbital volume post-surgery,² ensuring adequate removal of scar and fibrous tissue, replacing lost volume of

It has also been recommended for primary orbital reconstruction in children,¹¹ severe contracted socket¹² and asymptomatic socket pain¹³ by various authors. Aggarwal H and others recommend primary dermis fat graft in cases with higher risk of contracture like irradiation, previous multiple surgeries and peri-ocular scarring.¹⁴

Webb M C F recommends custom designed conformers for patients with contractures of grade III and above. They recommend using buccal mucous membrane to line the conformers and to be sutured to the periosteum if necessary.¹⁵ Post-operatively, Lafuente pressure mask or capillary traction devices are given to apply proper pressure to orbit to maintain the reconstructed fornices and prevent contracture.

orbit along with primary surgery itself,¹⁴ by orbital implants, dermis fat graft or by using volume expanders like silicone expander, hydrogel expander and others. It is recommended to place a large conformer in all cases so as to avoid shortening of fornices.^{2,15} It is recommended to not leave the socket empty for even a short duration of time.¹⁸ We recommend a dermis fat graft in selected patients in view of it being patients own biological tissue, lesser rate of complications and good cosmetic outcome after surgery irrespective of grade of contracture.

CONCLUSION:

The most common causes of contracted socket are enucleation for retinoblastoma or trauma. Contracture was more common in children and directly related to time gap between primary procedure and socket reconstruction. Dermis fat graft gives good results with respect to volume replacement and cosmesis and prosthesis fit and patient comfort, both as a primary or secondary procedure, with very few complications. It can offer a better cosmetic outcome in children as a primary procedure.

DATA AVAILABILITY

All data are included in this article.

ACKNOWLEDGEMENT

None

Conflict of Interest

Authors declare no conflicts of interest.

Corresponding author

Correspondence to: Swathi M

Email: swathichakrapani93@gmail.com

Affiliations

Swathi M, Ophthalmology, Minto Ophthalmic Hospital, Bangalore Medical College and Research Institute, Bangalore, India.

Ethics declarations

The Tenets of Declaration of Helsinki have been adhered to while conducting the study.

Conflict of interest

Trishulamurthy Chinmayee J, Swathi M, Samhitha HR all authors have no conflicts of interest that are directly relevant to the content of this review.

Funding: No sources of funding were used to conduct this review.

Reviewer disclosures: No relevant financial or other relationships to disclose.

Declaration of interest: No financial affiliations or financial involvement with any organization or entity with a financial competing with the subject matter or materials discussed in the review.

REFERENCES:

1. Foster JA, Carter KD, Durairaj VD, Kavanagh MC, Korn BS, Nelson CC et al. Orbital surgery. In: Cantor L B, Rapuano C J, Cioffi G A: Basic and Clinical Science Courses: Chapter 8: Anophthalmic socket: In: Section 7: Orbit, eyelids and lacrimal system. San Francisco, American Association of Ophthalmology: 2016: 93-111.
2. Adhikari R K, Khazai H, Usha K D. Prospective evaluation of contracted sockets. Kathmandu University Medical Journal; 2007;5(3)19: 391-395.
3. Peylan-Ramu N, Bin-Nun A, Skleir-Levy M, Bibas A, Koplewitz B, Anteby I et al. Orbital growth retardation in retinoblastoma survivors: Work in progress. Medical and Pediatric Oncology 2001;37(5): <https://doi.org/10.1002/mpo.1231>.
4. Didem S, Karslioglu S, Akbaba M, Buttanri I B, Fazil K. Clinical evaluation of 188 patients with contracted socket. Surgery Curr Res; 2014, 4:6. 203.
5. Goel R, Kumar S, Kamal S, Kaur S, Jain S, Tiwari B Et al. Contracted Socket. DOS Times; 2010(Jul):16:p18-30.
6. Krishna G. Contracted Sockets –I (Aetiology and types). Indian J Ophthalmol 1980;28:117-120.
7. Aryasit O, Preechawai P. Indications and results in anophthalmic socket reconstruction using dermis fat graft. Clinical Ophthalmology 2015;9 795–799.
8. Galindo-Ferreiro A, Khandekar R, Al Hassan S, Al-Hammad , Al-Subaie H, Artioli Schellini S. Dermis-fat graft for anophthalmic socket reconstruction: indications and outcomes. Arq Bras Oftalmol. 2018;81(5):366-370.
9. Jovanovic N, Carniciu A, Russel W, Jarocki A, Kahana A. Reconstruction of the Orbit and anophthalmic Socket using dermis fat graft: A major review. Ophthalmic Plastic and Reconstructive Surgery 2020;36(6): 529-539.
10. Bhattacharjee K, Bhattacharjee H, Kuri G, Das J K and Dey D. Comparative analysis of use of porous orbital implant with mucus membrane graft and dermis fat graft as a primary procedure in reconstruction of severely contracted socket. Indian J Ophthalmol. 2014 Feb; 62(2): 145–153.
11. Al-Mujani A, Ganesh A, Al-Zuhaibi S. Autogenous Dermis-Fat Orbital Implant for Anophthalmic Socket. Sultan Qaboos University Medical Journal 2007 7(2), P. 145-148.
12. Betharia S M, Patil ND. Dermis fat graft in contracted socket. Indian J Ophthalmol 1988;36:110-112.
13. Shams P N, Bohman E, Baker M S, Maltry A C, Kopp E D, Allan R C. Chronic anophthalmic socket pain treated by implant removal and dermis fat graft. Br J Ophthalmol 2015;0:1–6.
14. Aggarwal H, Singh K, Kumar P, Alvi HA. A multidisciplinary approach for management of post enucleation socket syndrome with dermis-fat graft and ocular prosthesis: a clinical report. J Prosthodont. 2013; 22:657-660.
15. Webb MCF. Issues in the Management of the Anophthalmic Socket: Clinical, Comfort, and Cosmetic. Ophthalmology Rounds 2010;8(1):130-044E.

-
16. Mukherjee B. An objective technique to calculate dermis-fat graft volume. *Indian J Ophthalmol* 2021;69(9): 2524-2526.
 17. Diab MM. Alahmadawy YA. Primary Dermis Fat Grafting for Socket reconstruction: Retrospective comparison of electrocoagulation versus scalpel dissection for epidermis removal. *Clinical Ophthalmology* 2020;14: 2925-2933.
 18. Krishna G. Contracted sockets –II. *Indian J Ophthalmol* 1981; 29(2):75-79.