

# Evaluation of the effects of the Incisal capping twin block on the flaring of the lower incisors in the treatment of skeletal Class II malocclusion

Asmaa A. Elabd<sup>1</sup>, Marwa A. Tawfik<sup>2</sup>, Ahmed M. Hafez<sup>3</sup>

## Abstract:

**Objective:** The purpose of this research was to evaluate the effect of the incisal capped Twin Block on the proclination of the lower incisors in the treatment of skeletal class II malocclusion. **Materials and Methods:** Ten patients (age ranged from 9 to 14 y) with skeletal class II due to mandibular retrusion were selected and treated with the incisal capped Twin Block appliance. Overjet was more than 4 mm. Lateral cephalometric radiographs, photographs, and study casts were obtained before and after treatment. The collected data were analyzed using (SPSS) program for Windows (Standard version 26). The treatment duration was about 8-12 months. **Results:** Incisal capped TB appliance had Dento-skeletal and soft tissue effects including non-significant effect on the maxillary growth, significant advancement of the mandible, increase in the posterior and total anterior facial height, decrease in the overjet and overbite, retroclination of the upper incisors, significant proclination of the lower incisors and improvement of the soft tissue profile. **Conclusions:** The incisal capped Twin Block appliance was effective in the correction of skeletal class II patients. It produced a combination of skeletal and dental effects by forward movement of the mandible, palatal tipping of the upper incisors and labial flaring of the lower incisors. The addition of the acrylic capping to the lower incisors did not control the position of the lower teeth and did not prevent their labial flaring.

## Introduction:

Class II malocclusion is one of the most common skeletal deformities in the clinical practice. About 21% of the Egyptian people suffer from this deformity which is characterized by abnormal relation between the upper and lower jaws. Class II malocclusion may be due to skeletal, dental background or may be due to abnormal habits. Skeletal class II may be due to mandibular retrognathism which represented the majority, maxillary prognathism or a combination of both.<sup>1,2</sup>

Class II deformity in orthodontic field can be treated in the growing patients by wide variety of fixed and removable appliances. These appliances perform their action by a combination of skeletal and dentoalveolar effects.<sup>3</sup> As a general rule, tooth borne appliances produce more dental compensation and less skeletal effects when compared to tissue borne ones.<sup>4</sup> Twin block is one of the most common appliances that depend on the teeth in anchorage. They are preferred by the patients as they composed of two separate parts that enable them to eat, speak and move the jaw freely during various movements of the jaws.<sup>5,6</sup> There was a conflict between researchers regarding the skeletal, dental and soft tissue effects of the Twin Block appliance.<sup>5,7</sup> Some studies reported that Twin Block increased the mandibular length while others did not agree with them.<sup>5</sup> All studies accepted the concept that all functional appliances restrict maxillary growth, enhance mandibular advancement and modify the dentoalveolar system. Dentoalveolar compensation was

the most prominent effect of the functional appliances.<sup>8</sup>

Twin Block was first developed by Clark, which composed of two bite blocks with inclined planes made with 45° angle. They were designed to be worn full time to utilize all functional forces applied to them during function.<sup>7</sup> Unfortunately, the main drawback of the TB was the flaring of the lower incisors which was believed to be the major factor in minimizing skeletal effect and maximizing dentoalveolar effects (60%).

So, in this study we tried to modify the Twin Block device in a way to control position or decrease flaring of lower incisors by the acrylic capping of the lower teeth in the treatment of skeletal class II patients with mandibular retrognathism.

## Materials and Methods:

The sample of the study included ten patients with mean age 11.90±0.87. The patients were chosen from the clinic of orthodontic department, faculty of dentistry, Mansoura University.

The patients were enrolled the study having the following inclusion criteria:

- Age (early permanent dentition 9-14 y).
- Skeletal class II due to mandibular retrusion.
- Overjet more than 4mm.

## Exclusion criteria:

- Cleft lip or palate.
- Systemic disease.
- Previous orthodontic treatment or abnormal habits.
- Congenital craniofacial deformity.
- Bad oral hygiene.

## Patient records:

For every patient in the sample, the following records were taken:

<sup>1</sup>Postgraduate MSc student, Department of Orthodontics, Faculty of Dentistry, Mansoura University, Egypt. Corresponding author: asmaaelabd55@gmail.com

<sup>2</sup>Associate Professor, Department of Orthodontics, Faculty of Dentistry, Mansoura University, Egypt.

<sup>3</sup>Associate Professor, Department of Orthodontics, Faculty of Dentistry, Mansoura University, Egypt.

doi: 10.21608/MJD.2022.259769

1. A signed informed consent, describing the following: Aim of the study, features of the incisal capped Twin Block appliance used in the study, expected benefits and possible drawbacks of using it.

2-Photographs which include:

- Extraoral Photographs: three photos were taken for all patients prior to and after treatment; frontal view during rest, smiling and lateral views.
- Intraoral Photographs: six photos were taken for all patients prior to and after treatment; the teeth in occlusion -frontal and lateral (right and left sides) and the overjet photo, also upper and lower occlusal views.

3-Radiographs which include:

- Panoramic x-ray films: were taken prior to and after treatment.
- Lateral cephalogram: were taken prior to and after treatment.
- Hand wrist films were taken before treatment to evaluate skeletal age for some patients.

### Appliance design:

After taking the upper and lower impressions; a construction wax bite was obtained, the mandible was positioned anteriorly to achieve an edge-to-edge relationship. Single step advancement of the mandible was achieved if the over jet ranged between (3-4 mm) or segmental advancement if it was larger than 5 mm using the exacto-bite.

The modified Twin Block, which was constructed for all patients in the study, composed of upper and lower part. The upper part was similar to the conventional one as it incorporated labial bow with U loop around canines, ball clasps and Adam clasps on the upper first molars for retention.

The lower part included ball clasp between lower two central incisor and Adam clasp on lower first premolar with the additional modifications:

- The lower incisors had acrylic capping.
- The lingual side of lower incisors had wax relief.

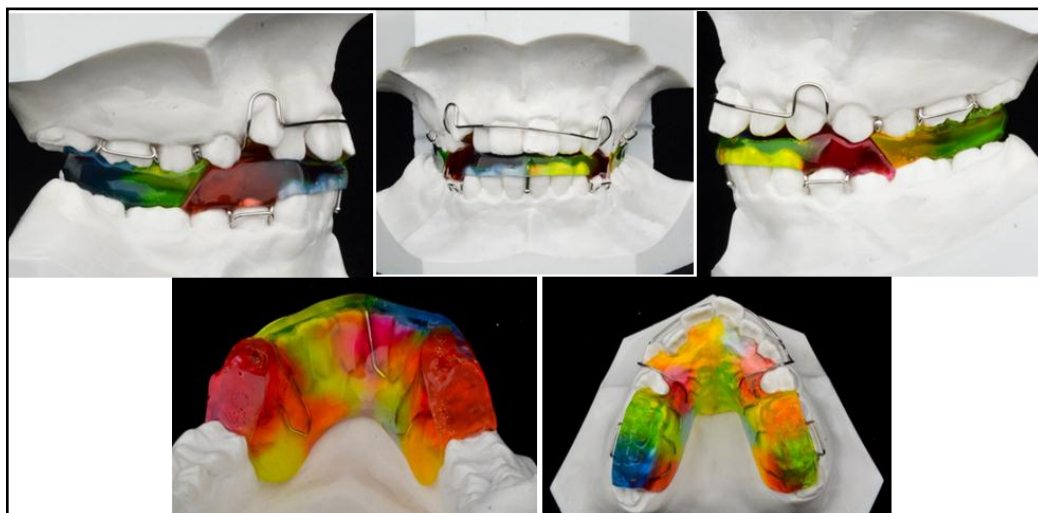


Figure 1: Showing the design of the incisal capped Twin Block appliance on study cast model.

When the overjet was corrected (incisor edge to edge relation); a retention appliance (anterior inclined plane) was constructed to allow for maximum interdigitation to maintain the results till cessation of growth. It consisted of upper acrylic plate that did not extend to the occlusal or incisal parts of the upper teeth. From this acrylic plate, an inclined plane extended down lingually to the lower anterior teeth. Passive labial bow over the upper six anterior teeth was constructed as a retentive component. An expansion screw may be incorporated as needed to control transverse dimensions. No lower part was utilized in this phase.

### Cephalometric measurements:

#### Cephalometric reference points:

Nasion (N): The most anterior point of the frontonasal suture in the median plane.

Sella (S): The point representing the midpoint of the sella turcica.

A point –Subspinale: The deepest point at midline concavity on the maxilla

B point –Supramentale: The point at the deepest midline concavity on the mandibular symphysis.

Gnathion (Gn): The most anteroinferior point of the bony chin.

Menton (Me): the most inferior point of the mandibular symphysis in the midline.

Gonion (Go): The most posteroinferior point at the angle of the mandible.

Condylion (Co): The most posterosuperior point on the outline of the condyle.

Labrale superius (Ls): The most anterior point on the convexity of the upper lip.

Labrale inferius (Li): The most anterior point on the convexity of the lower lip.

Soft tissue pogonion (Pg'): The most anterior point on the soft tissue chin in the midsagittal plane.

### Cephalometric reference line and planes:

Sella-Nasion plane (SN): Reference line joining sella and nasion points.

Mandibular plane (MP): Plane joining Gonion and Menton points.

Steiner's S-line (S line): Line joining (Pg') and midpoint of the curve "S" formed by the lower border of the nose.

### Skeletal measurements:

SNA: The angle formed between sella, nasion and point A.

SNB: The angle between the SN and NB planes.

SN-MP: The angle formed by the intersection of SN and MP.

FMA: The angle between the Frankfort plane and mandibular plane.

Ar-Go-Me (Gonial angle): Angle between (Articulare-Gonion) line and (Gonion-Menton) line.

Co-Gn: The linear measurement between Condylion and Gnathion.

Go-Gn: The distance between Gonion and Gnathion.

### Dentoalveolar measurements:

U1-NA (deg): The angle formed between the long axis of the upper central incisor and NA

U1-SN (deg): The angle formed between the long axis of the upper central incisor and SN

U1-NA (mm): The distance between the labial surface of the upper central incisor and the NA line

L1-NB (deg): The angle between the long axis of the mandibular central incisor and the NB line.

IMPA (deg): The angle between the long axis of the mandibular central incisor and mandibular Plane.

L1-NB (mm): Distance from the labial surface of the lower central incisor and NB line.

### Maxillary mandibular measurements:

ANB (deg): The angle between NA and NB planes (ANB = SNA – SNB).

Interincisal Angle: Formed between the long axis of the upper and lower central incisors.

### Soft tissue measurements:

Nasolabial angle: The angle is formed by drawing a line tangent to the base of the nose and a line tangent to the upper lip.

Ls-S (mm): the distance from upper lip to Steiner's S line.

Li-S (mm): the distance from lower lip to Steiner's S line.

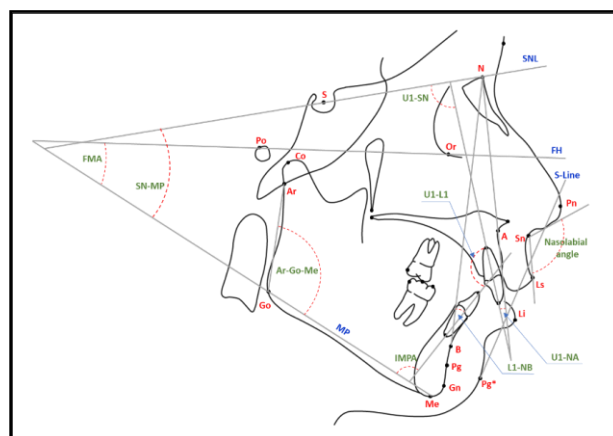


Figure 2: Cephalometric points, lines and angles

### Data analysis:

Data were analyzed using the Statistical Package of Social Science (SPSS) program for Windows (Standard version 26). Paired t test was used in this analysis to compare pre and post measurements. The results were considered significant when  $p \leq 0.05$ .

### Results:

The mean, standard deviations and the results of paired t-test for the pretreatment and post treatment cephalometric measurements are presented in, (Tables 1-3).

Table 1: Descriptive information and paired t-test results of pretreatment and post-treatment of skeletal variables

Variables	Pre	Post	P value
SNA (deg.)	81.15±1.73	81.30±1.70	0.193
SNB (deg.)	73.90±2.42	76.80±2.44	≤.001*
SN-MP (deg.)	38.70±4.73	38.80±4.82	0.882
FMA (deg.)	29.05±3.30	31.45±4.45	0.005*
Ar-Go-Me (deg.)	130.15±2.53	132.40±3.02	0.006*
Co-Gn (mm)	98.40±4.19	101.70±4.49	0.001*
Go-Gn (mm)	62.75±4.36	63.70±3.94	0.032*
ANB (mm)	7.15±1.49	4.15±1.24	≤.001*

\* $p \leq 0.05$  (significant)

Table 2: Descriptive information and paired t-test results of pretreatment and post-treatment for Dento-alveolar variables

Variables	Pre	Post	P value
U1-NA (deg.)	28.55±5.91	22.45±4.12	≤.001*
U1-SN (deg.)	109.60±4.64	103.40±3.62	≤.001*
U1-NA (mm)	6.60±1.89	3.70±1.49	≤.001*
L1-NB (deg.)	25.60±3.09	31.35±4.54	0.001*
IMPA (deg.)	90.50±4.90	95.80±5.51	≤.001*
L1-NB (mm)	5.55±1.21	7.70±1.25	≤.001*
Inter incisal angle (deg.)	118.20±6.67	121.20±7.43	≤.001*
Overjet (mm)	8.25±1.90	2.55±0.76	≤.001*
Overbite (mm)	5.30±1.94	2.35±1.10	≤.001*

\*p ≤ 0.05 (significant)

Table 3: Descriptive information and paired t-test results of pretreatment and post-treatment for soft tissue variables

Variables	Pre	Post	P value
Nasolabial angle (deg.)	109.00±8.47	111.40±9.26	0.007*
Ls-S (mm)	1.25±0.85	0.95±0.89	0.111
Li-S (mm)	1.00±1.63	2.85±1.29	≤.001*

\*p ≤ 0.05 (significant)

**Skeletal measurements:**

There was no statistically significant difference in SNA (°) ( $P > 0.05$ ), while the SNB (°), FMA, Ar-Go-Me, Co-Gn and Go-Gn showed a significant statistical increase ( $P \leq 0.05$ ), and the ANB (°) showed a significant statistical decrease ( $P \leq 0.05$ ).

**Dentoalveolar measurements:**

There was a significant statistical decrease in U1-NA, U1-SN, U1-NA, overjet and overbite ( $P \leq 0.05$ ). On the other hand, there was a significant increase in L1-NB, IMPA and inter incisal angle ( $p \leq 0.001$ ).

**Soft tissue measurements:**

There was a significant increase in nasolabial angle ( $P \leq 0.05$ ). In linear measurements, there was insignificant decrease in (Ls-S line) ( $P \leq 0.05$ ), while the (Li-S line) significantly increased ( $P \leq 0.05$ ).

**Discussion:**

There are several modalities for the treatment of skeletal class II patients that depends mainly on the age of the patient to select the appropriate option. Treatment may be accomplished by functional appliances, dental camouflage or orthognathic surgery. Furthermore, management of growing individuals with large overjet by functional appliances diminishes the probability of need for late orthognathic surgery. These appliances have skeletal effects look like those produced from different phenomena: relocation and remodeling of the glenoid fossa, accelerated and enhanced condylar growth and neuromuscular adaptation. Therefore, functional appliances have been suggested to manage skeletal deficiencies, like deficiencies of the mandibular growth.<sup>9</sup>

Most of functional appliances depend on the principle of encouraging the forward position of the mandible. They are successful in correcting the antero-posterior discrepancy between the upper and lower jaws especially in mild to moderate cases.<sup>10</sup>

Twin Block appliance aids in the correction of skeletal class II problems as it is accepted by many patients, allows easy mastication and speech.<sup>5,6</sup> Twin Block appliance aids in the correction of the malocclusion by a combination of skeletal and Dento-alveolar changes. Flaring of lower incisors produced by this appliance is the most important drawback that the authors try to overcome as it takes support from teeth rather than bone.<sup>11</sup>

So, the aim of our study was to evaluate the effect of acrylic capping of lower incisors on the proclination of lower incisors during treatment with Twin Block appliance.

**Skeletal effects:**

In this study, the appliance showed non-significant increase in SNA. This result was in line with some studies.<sup>12,13</sup> While other studies observed restricting effect of the TB on the maxilla.<sup>14,15</sup>

Regarding the mandible, there was a significant increase in SNB, mandibular length and body of the mandible. This might be due to the anterior positioning of the B point and advancement of the mandible by the remodeling in the condylar- glenoid fossa system. These results were in line with some studies.<sup>5,15-17</sup> There also was a significant decrease in ANB which might be due to the forward advancement of the mandible.<sup>15,16</sup>

**Dentoalveolar effects:**

Treatment with incisal capped Twin Block produced significant retroclination of the upper incisors which

might be due to the presence of the labial bow and the distally acting forces on the maxillary dentition applied through the inclined planes. These results were in line with Illing et al.<sup>15</sup>, O'Brien et al.<sup>14</sup> and Khoja et al.<sup>5</sup>

Mandibular incisors which were the main item in the study showed a significant proclination due to the mesial forces on the lower dentition. This finding was in line with Sandler<sup>18</sup> and Khoja et al.<sup>5</sup> While, Illing et al.<sup>15</sup> demonstrated a non-significant change in the position of the lower incisors.

**Soft tissue effects:**

The upper lip showed insignificant retrusion due to the retroclination of the upper incisors. This finding was in line with Morris et al.<sup>15</sup> While Khoja et al.<sup>5</sup> demonstrated a significant change in upper lip position. The lower lip demonstrated a significant forward advancement. Baysal<sup>17</sup> and Khoja et al.<sup>5</sup> were in line with our study.

**Conclusions:**

The conclusion of the present study was that the incisal capped Twin Block appliance is a good solution for the treatment of skeletal class II patients with mandibular retrognathism. It improves soft tissue profile and decreases the increased overjet through a combination of the dental and skeletal effects. Regarding the axial inclination of the lower incisors, the incisal capped Twin Block did not prevent the flaring of the lower incisors.

**Recommendation:**

Further investigation should be done to modify the Twin Block in a way to increase anchorage to the bone rather than teeth to maximize skeletal effect and minimize dental effects.

**Case presentation:**

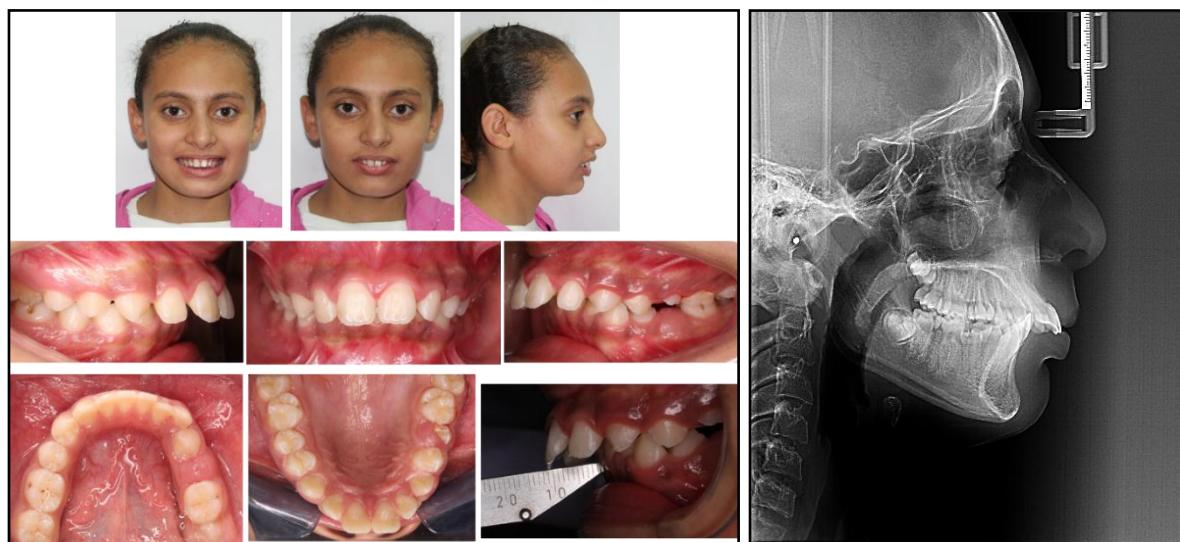

Figure 3: Pretreatment extra-oral and intra-oral photographs and cephalometric radiograph for a patient with skeletal class II malocclusion.

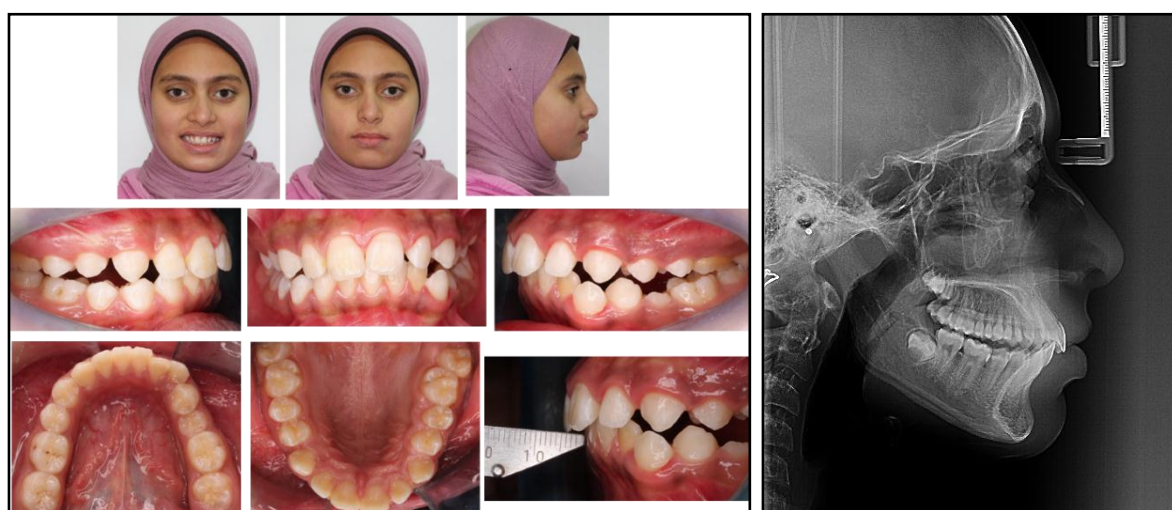


Figure 4: Post treatment extra-oral and intra-oral photographs and cephalometric radiograph for patient treated with incisal capped Twin Block appliance

**References:**

1. Proffit WR, Fields Jr H, Moray L. Prevalence of malocclusion and orthodontic treatment need in the United States: estimates from the NHANES III survey. *Int J Adult Orthodon Orthognath Surg.* 1998;13(2):97-106.
2. El-Mangoury NH, Mostafa YA. Epidemiologic panorama of dental occlusion. *Angle Orthod.* 1990;60(3):207-214.
3. Siara-Olds NJ, Pangrazio-Kulbersh V, Berger J, Bayirli B. Long-term dentoskeletal changes with the Bionator, Herbst, Twin Block, and MARA functional appliances. *Angle Orthod.* 2010;80(1):18-29.
4. Pakshir H, Mokhtar A, Darnahal A, Kamali Z, Behesti MH, Jamilian A. Effect of bionator and farmand appliance on the treatment of mandibular deficiency in prepubertal stage. *Turk J Orthod.* 2017;30(1):15-21.
5. Khoja A, Fida M, Shaikh A. Cephalometric evaluation of the effects of the Twin Block appliance in subjects with Class II, Division 1 malocclusion amongst different cervical vertebral maturation stages. *Dental Press J Orthod.* 2016;21(7):73-84.
6. Proffit WR, Fields H, Sarver D. Contemporary orthodontics. 4th ed. St. Louis: Mosby. 2007; p.207-217.
7. Varlık SK, Gültan A, Tümer N. Comparison of the effects of Twin Block and activator treatment on the soft tissue profile. *Eur J Orthod.* 2008;30(2):128-134.
8. Ahmadian-Babaki F, Araghbidi-Kashani SM, Mokhtari S. A cephalometric comparison of Twin Block and bionator appliances in treatment of class II malocclusion. *J Clin Exp Dent.* 2017;9(1): 107-122.
9. Ramirez-Yanez G, Sidlauskas A, Junior E, Fluter J. Dimensional changes in dental arches after treatment with a prefabricated functional appliance. *J Clin Pediatr Dent.* 2007;31(4):279-283.
10. Littlewood SJ, Mitchell L. An introduction to orthodontics: 5th ed Oxford university press; 2019; p.347-358.
11. Saikoski LZ, Canjado RH, Valarelli FP, Freitas KMSd. Dentoskeletal effects of Class II malocclusion treatment with the Twin Block appliance in a Brazilian sample: a prospective study. *Dental Press J Orthod.* 2014;19(8):36-45.
12. Jena AK, Duggal R, Parkash H. Skeletal and dentoalveolar effects of Twin-block and bionator appliances in the treatment of Class II malocclusion: a comparative study. *Am J Orthod Dentofacial Orthop.* 2006;130(5):594-602.
13. Gilmore WA. Morphology of the adult mandible in Class II, Division 1 malocclusion and in excellent occlusion. *Angle Orthod.* 1950;20(3):137-146.
14. O'Brien K, Wright J, Conboy F, Sanjie Y, Mandall N, Chadwick S, et al. Effectiveness of early orthodontic treatment with the Twin-block appliance: a multicenter, randomized, controlled trial. Part 1: dental and skeletal effects. *Am J Orthod Dentofacial Orthop.* 2003;124(3):234-243.
15. Illing HM, Morris DO, Lee RT. A prospective evaluation of Bass, Bionator and Twin Block appliances. Part I-The hard tissues. *Eur J Orthod.* 1998;20(5):501-516.
16. Toth LR, McNamara Jr JA. Treatment effects produced by the Twin-block appliance and the FR-2 appliance of Fränkel compared with an untreated Class II sample. *Am J Orthod Dentofacial Orthop.* 1999;116(6):597-609.
17. Baysal A, Uysal T. Soft tissue effects of Twin Block and Herbst appliances in patients with Class II division 1 mandibular retrognathia. *Eur J Orthod.* 2013;35(1):71-81.
18. Lund DI, Sandler PJ. The effects of Twin Blocks: a prospective controlled study. *Am J Orthod Dentofacial Orthop.* 1998;113(1):104-110.