

## Outcomes of the Greater Trochanter Epiphysiodesis in Treatment of Children with Hip Pathology

Muhammed Yasser Kamel Mahmoud,<sup>1</sup> M.B.B. Ch, Ibrahim Elsayed Abdellatif Abuomira,<sup>1</sup> MD, Amer Alkott Mostafa Alsadiq,<sup>1</sup> MD.

### \* Corresponding Author:

Muhammed Yasser Kamel Mahmoud  
[Docmuhammed1@gmail.com](mailto:Docmuhammed1@gmail.com)

Received for publication March 17, 2022; Accepted September 18, 2022; Published online September 18, 2022.

doi: 10.21608/aimj.2022.119777.1827

**Citation:** Muhammed Y., Ibrahim E. and Amer AMA. Outcomes of the Greater Trochanter Epiphysiodesis in Treatment of Children with Hip Pathology. AIMJ. 2022; Vol.3-Issue9 .28-31.

<sup>1</sup>Orthopedic Surgery Department, Faculty of Medicine, Al-Azhar University, Assiut, Egypt.

### ABSTRACT

**Background:** Many hip diseases in children can affect growth of the greater trochanter (GT), as a result, it is raised in relation to the femoral head. This disturbs normal biomechanics of hip joint and affect hip abductors. This problem is called Relative overgrowth of the greater trochanter (ROGT).

**Aim of the study:** Analysis of the radiological parameters of proximal femur after trochanteric epiphysiodesis.

**Patients and Methods:** Twenty child with unilateral ROGT were included in this prospective study. Epiphysiodesis was done by multiple drill holes and a screw with washer. We analysed the short-term radiological outcomes of 20 individuals after treatment.

**Results:** The surgery can stop growth of GT by about 48.6% ( $p < 0.05$ ) in comparison with normal side indicating that the greater trochanter tip did not displace in relation to the head of the femur with time.

**Conclusion:** Greater trochanteric epiphysiodesis (GTE) can prevent the progression of moderate femoral head epiphysis growth plate problems and, in some cases, restore the normal shape of proximal femur, avoid the need to more invasive surgery.

**Keywords:** Greater trochanter epiphysiodesis; hip Pathology; trochanteric-pelvic impingement (TPI)

**Disclosure:** The authors have no financial interest to declare in relation to the content of this article. The Article Processing Charge was paid for by the authors.

**Authorship:** All authors have a substantial contribution to the article.

**Copyright** The Authors published by Al-Azhar University, Faculty of Medicine, Cairo, Egypt. Users have the right to read, download, copy, distribute, print, search, or link to the full texts of articles under the following conditions: Creative Commons Attribution-Share Alike 4.0 International Public License (CC BY-SA 4.0).

### INTRODUCTION

Pediatric hip disorders that affect femoral capital epiphysis are usually associated with growth and elevation of the Greater trochanter relative to the femur head. Later on, this leads to weakness of hip abductors and femoro-acetabular impingement. Clinically this will result in limping and hip pain <sup>[1]</sup> The most common causes of this development are hip dislocation and Perthes disease. Post septic hip, trauma, and problems such coxa vara in infants are less prevalent causes. <sup>[2]</sup> The outcome depend on the age at which the patient reach skeletal maturity. The femoral neck becomes short, thick and develops a varus deformity which may cause leg length discrepancy as a result of complete growth arrest. <sup>1</sup> In general, there are three surgical procedures for greater trochanter overgrowth management. By epiphysodesis, lateral displacement of the greater trochanter, or a complex osteotomy including distal displacement of the greater trochanter with concomitant femoral neck lengthening. <sup>2</sup> Langenskiold and Salenius <sup>3</sup> were the first to try GTE In pediatric with Perthes disease, Matan et al. <sup>4</sup>

and Kwon et al. <sup>5</sup> applied GTE as well as corrective (varus) femur osteotomy. The Phemister technique<sup>9</sup>, bone peg epiphysiodesis <sup>3</sup>, and drilling of the growth plate associated with a screw epiphysiodesis are among the approaches for trochanteric epiphysiodesis that have been published.<sup>6</sup> So, our aim of the work is to analysis the radiological parameters of proximal femur after trochanteric epiphysiodesis.

### PATIENTS AND METHODS

This is prospective study that was performed at Al-Azhar Assiut University hospital, Department of Orthopedics and Trauma Surgery between January 2019 and October 2021. Twenty patients with unilateral ROGT caused by various hip joint disorders were enrolled in current work. Patients having a high greater trochanter, with its tip above the centre of the femoral head but below the superior pole and Patients who have never had hip surgery may see alterations in the femoral neck anatomy, such as a shortening, met the inclusion criteria. patients with hip dislocation, varus deformity of the

femoral neck (neck–shaft angle  $<120^\circ$ ), patients with hip trauma, rickets, skeletal dysplasia, patients with neurological disorders and refusal to participate in this study were excluded.

Methods of examination included clinical examination as well as X-ray examination. We looked at the short-term radiological outcomes of 20 patients up to 24 months after surgery. These patients had unilateral lesions and had at least an 18-month follow-up period. The parameters were compared using the opposite normal hip joint, so our sample contained 20 affected and 20 unaffected hip joints. The proximal femur is shown using X-rays. Through the course of the follow-up time, the greater trochanter growth measured in millimeters as a result of the difference in TTD from surgery and after 2 years follow up. As a result, the difference in TTD between the healthy hip joint and the impaired hip joint throughout the follow-up time was represented AS percent of growth inhibition by epiphysiodesis.

### Clinical examination

All patients are exposed to a full history and clinical assessment, including musculoskeletal examination of all the joints with stress on hip examination.

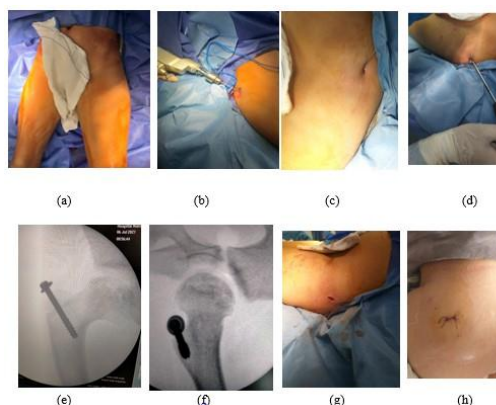
### Radiographic measurements

The trochanter-to-trochanter distance (TTD) was used to determine the extent of trochanter development [2]. TTD is measured radiographically from the greater trochanter's tip to the centre of the lesser trochanter. A greater trochanter growth was found by subtracting the pre-surgery TTD from the last follow-up TTD measurement. The development of the capital femoral epiphysis has no bearing on this measure. [3] For the greater trochanter that underwent epiphysiodesis, the difference in accepted length between it and healthy hip was seen as a sign of a growth impairment. Anatomically, we looked at the articular surface to greater trochanter distance (ATD) [3] and lesser trochanter-to-articular surface distance (LTA), which is used to estimate femoral capital epiphysis development [4]. Varus femoral neck remodelling was quantified using a measurement known as the neck shaft angle (NSA) [2], that is the angle generated between femoral shaft in relation to a line drawn along the neck's axis and crossing the femoral head in the middle.

### Surgical technique

Patients received intravenous antibiotic (first generation Cephalosporin 50-100 mg /kg 30 minutes before surgery). The surgery was performed while the patients were supine and under general anaesthesia. With the use of a guided growth method, all procedures were carried out utilizing a minimally invasive way. The greater trochanter was identified using fluoroscopy and fixed to the femur using a cortical screw with a washer. Trochanter epiphysiodesis was conducted using a percutaneous approach in the projection of the greater trochanter if

it was done alone. It was possible to locate the greater trochanter's growing zone. An epiphysiodesis was performed by drilling five to six holes across the greater trochanteric physis, followed by cannulated screw placement. The cortical screw was inserted from the superior lateral parts of the greater trochanter toward the lesser trochanter parallel to the intertrochanteric line of the femur. [2] A dosed walk without assistance was permitted 3–5 days following surgery after trochanteric epiphysiodesis.



**Fig 1:** operative technique: a, supine position of patient b, drilling of greater trochanteric physis c, guide wire for cannulated screw d, cannulated screw entered from the superior lateral sections of the greater trochanter toward the lesser trochanter, parallel to the intertrochanteric line of the femur e, f, intra operative antero-posterior and lateral x-ray g, wound after operation h, wound closure.

### Statistical Analysis

Data obtained were processed using statistical methods. Categorical data were presented in number and percent (N, %), where continuous data presented in mean and standard deviation (Mean, SD). Comparing among continuous data by t-test (Paired-Samples T test). A two-tailed  $p < 0.05$  was considered significant. All analyses were performed with the IBM SPSS 26.0 software.

## RESULTS

Twenty patients with unilateral ROGT caused by various hip joint disorders followed up for 24 months after surgery. They were twelve boys (60.0%) and eight girls (40.0%), and their age mean was  $8.18 \pm 1.77$  years (ranging from 5 to 10 years). The postoperative follow-up period mean was  $18.09 \pm 3.70$  months (ranging from 18-24). Eleven (55.0%) patients were affected at left hip and nine (45.0%) at right hip (Table 1). The patients had different etiologies: fourteen patients with Perthes disease, four cases with femoral head avascular necrosis, and two patients with post septic hip arthritis (Table 2). The clinical presentation following surgery did not significantly change. In any case, no complications were discovered. According to table (3), Differences between the parameters did not significantly differ, indicating stationary state of the greater trochanter growth. Furthermore, the mean values of normal

greater trochanter growth (TTD index) for healthy and impaired joints were comparable, indicating that the status of the greater trochanter on the impaired side is not in progress . TTD index raised by 10.18 mm in the normal joint and 4.94 mm in the diseased hip joint over the surgical follow-up period. Surgical treatment decreased the greater trochanter's growth by 48.6 percent ( $p < 0.05$ ) based on changes in the TTD index. The diseased side had a significant lower initial ATD value ( $p < 0.05$ ). During the follow-up period, the ATD values on the diseased and normal sides were almost constant. The normal growth of the capital femoral epiphysis did not affected as indicated by increasing value of LTA. During the follow-up period, the neck–shaft angle on both the diseased and normal sides did not vary significantly ( $p > 0.05$ ).

	No.	%
Age Range	5-10yrs	
Mean±SD	8.18±1.77	
Sex		
Male	12	60.0
Female	8	40.0

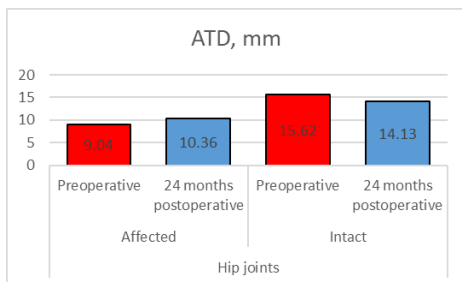
**Table 1:** Demographic characteristics of the studied patients.

	Number	percentage
Affected side		
Rt side	9	45.0
Lt side	11	55.0
Diagnosis		
Post septic hip arthritis	2	10.0
Bilateral perthes	14	70.0
Avascular necrosis of femoral head	4	20.0

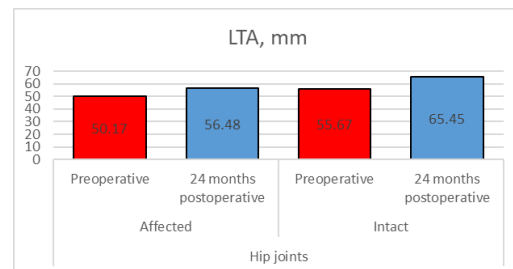
**Table 2:** Distribution of clinical data among studied patients..

Parameters	Hip joints Preoperative		24 months postoperative	
	Affected	Normal side	Affected	Normal side
ATD (M±SD), mm	9.04 ± 4.37	15.06±4.22**	9.84 ± 6.61	15.76 ± 3.64
TTD (M±SD), mm	40.62 ± 3.68	39.45 ± 4.36	45.56 ± 1.75	49.63 ± 5.26
LTA (M±SD), mm	50.17 ± 6.24	55.67 ± 6.47	56.48 ± 6.97	65.45 ± 5.78
NSA (M±SD), deg.	135.34± 4.17	138.89 ± 4.96	133.42± 6.58	136.16± 6.53

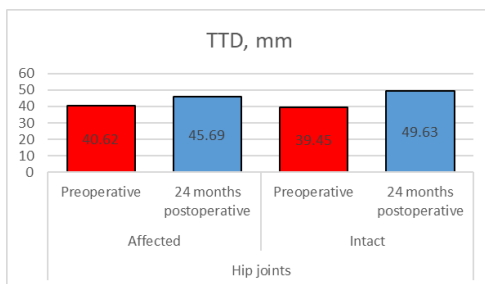
**Table 3:** Measurements of the radiological data of the affected and normal hip joint preoperative and 24 months postoperative.



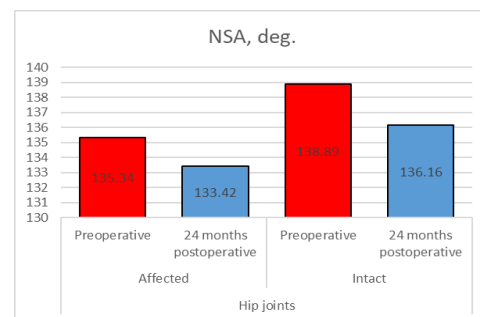
**Fig 2:** Comparison between mean of articlrotrochanteric distance (ATD) in affected hip joints preoperative and 24 months postoperative.



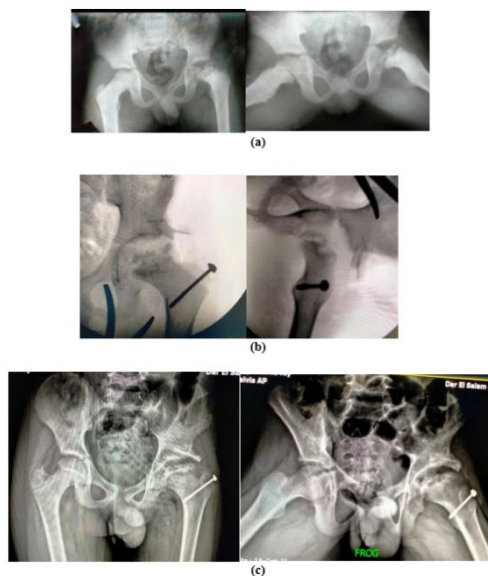
**Fig 4:** Comparison between mean of lesser trochanter-to-articular surface distance (LTA) in affected hip joints preoperative and 24 months postoperative.



**Fig 3:** Comparison between mean of lesser trochanter-to-articular surface distance(LTA) in affected hip joints preoperative and 24 months postoperative.



**Fig 5:** Comparison between mean of Femoral neck–shaft angle (FNSA)in affected hip joints preoperative and 24 months postoperative.



**Fig 6:** Radiographs of patient 9years old with left side Perthes disease a, before surgery; b, intra operative radiograph c, 1 year after the trochanteric epiphysiodesis on the left.

### DISCUSSION

Among common deformities that occur in pediatric patients with hip diseases is the high location of the greater trochanter. The short lever arm of the hip abductor muscle caused by trochanteric overgrowth results in a Trendelenburg gait. This condition is marked by aberrant anatomical relation among the femoral head, femoral neck, and greater trochanter, as well as impaired femoral neck growth. Because the attachment points of the gluteal muscles are converged in this situation, the gluteal muscles weaken and the gait is disrupted. A further decrease in the length between the greater trochanter and the acetabulum results in limitation of hip abduction and rotation, the development of trochanteric-pelvic impingement, and pain. Greater Trochanter epiphysiodesis is a minimally invasive procedure that aims to stop growth in the greater trochanter. The treatment goal is to restore normal anatomy by lengthening the abductor lever arm or gradual adaptation to restore their strength. The greater trochanter's growth is composed of appositional development in the superior part of the greater trochanter and metaphysis development. Theoretically, complete GTE can arrest development by 50%<sup>2</sup>. In our study the growth of the greater trochanter slowed by 48.6% ( $p < 0.05$ ). Clinically, the result of GTE is not clear. Matan et al.<sup>4</sup> showed a clinical and radiological improved results in patients around age of 8 years after GTE. McCarthy and Weiner<sup>7</sup> said that it is preferable to perform epiphysiodesis on children older than 8 years because of their rapid development, or because epiphysiodesis is technically easier at this age. The overall growth restriction expected to be higher in children less than six years old. In contrast to Stevens and Coleman<sup>8</sup>, who performed 35 GTE for coxa breva, found that epiphysiodesis can stabilise the ATD if it is done before the age of eight, but the ATD will continue to decline if it is done after this

age. The Plemister approach has been modified by most researchers in the past to introduce a procedure for GTE<sup>9</sup>. This technique has been modified to include multiple drill holes and screw insertion. Shah H et al.<sup>10</sup> recommended prophylactic GTE in older children with Perthes' disease to reduce trochanter overgrowth and Trendelenburg gait. We see that trochanteric epiphysiodesis is highly recommended as a result of its short operative time, minimal bleeding, and simple therapy after surgery to children with capital femoral epiphysis necrosis, as these patients will have a short femoral neck and relative trochanteric overgrowth over the time they become skeletally mature. As soon as the osseous nucleus of the trochanteric epiphysis emerges on radiology, the surgery should be carried out for the best outcomes (usually at 5 years old).

### CONCLUSION

This study of modified of the Iselin technique results it is stable, safe, minimal invasive and allow to immediately mobilization then removal Kirschner wire is easily at out clinic.

Conflict of interest : none

### REFERENCES

1. Pozdnykin IY, Baskov VE, Barsukov DB, et al. Relative overgrowth of the greater trochanter and trochanteric-pelvic impingement syndrome in children: causes and X-ray anatomical characteristics. *Pediatric traumatology, orthopaedics and reconstructive surgery*. 2019; 7(3):15-24.
2. Pozdnykin IY, Baskov VE, Barsukov DB, et al. Trochanteric epiphysiodesis in complex treatment of children with hip pathology: analysis of preliminary results. *Pediatric Traumatology, Orthopaedics and Reconstructive Surgery*. 2020; 8(3):249-58 .
3. Langenskiöld A and Salenius P. Epiphyseodesis of the greater trochanter. *Acta Orthopaedica Scandinavica*. 1967; 38(1-4):199-219.
4. Matan AJ, Stevens PM, Smith JT, et al. Combination trochanteric arrest and intertrochanteric osteotomy for Perthes' disease. *Journal of Pediatric Orthopaedics*. 1996; 16(1):10-4
5. Kwon K-S, Wang SI, Lee J-H, et al. Effect of greater trochanteric epiphysiodesis after femoral varus osteotomy for lateral pillar classification B and B/C border Legg–Calvé–Perthes disease: A retrospective observational study. *Medicine*. 2017; 96(31).
6. Gage JR and Cary J. The effects of trochanteric epiphysiodesis on growth of the proximal end of the femur following necrosis of the capital femoral epiphysis. *The Journal of bone and joint surgery American volume*. 1980; 62(5):785-94
7. McCarthy JJ and Weiner DS. Greater trochanteric epiphysiodesis. *International orthopaedics*. 2008;32(4):531-4
8. Stevens PM and Coleman SS. Coxa breva: its pathogenesis and a rationale for its management. *J Pediatr Orthop*. 1985; 5(5):515–21
9. Plemister DB. Operative arrestment of longitudinal growth of bones in the treatment of deformities. *J Bone Joint Surg Am*. 1933; 15:1–15
10. Shah H, Siddesh ND, Joseph B, et al. Effect of prophylactic trochanteric epiphysiodesis in older children with Perthes' disease. *Journal of Pediatric Orthopaedics*. 2009; 29(8):889-95.