

Spontaneous Intra-Cerebral Hematoma; Results of Surgical Management in Benha University Hospitals

Mohamed Elhawary, Mohamed M Elmaghrabi, Hany Elnemr

Department of Neurosurgery,
Benha faculty of medicine,
Benha University, Egypt.

Correspondence to:
Mohamed M Elmaghrabi,
Department of Neurosurgery,
Benha faculty of medicine,
Benha University, Egypt.

Email:

dr_elmaghrabi@yahoo.com

Received: 8 September 2022

Accepted: 22 September 2022

Abstract

Purpose: The aim of this study was to evaluate the outcome of surgical management of spontaneous intra-cerebral hematoma, and express the predicting factors favoring good or bad outcome.

Patients and Methods: The present research was brought in Benha university hospitals on 40 patients having to deal with spontaneous intracerebral hemorrhage with clinical diagnosis of hypertension where we operated upon. The end result of surgery and determinants of the outcome were noted regarding 2 divided groups (survived and died). **Results:** The mean age \pm SD was 56.89 ± 7.93 and 57.64 ± 9.73 years in survived and died groups respectively. Preoperative Glasgow coma scale (GCS) of 13-15 in survived cases was 80% while all cases were died (100%) in died group of GCS 5-8 which was statistically significant. The most common site was basal ganglia (55%). The volume of hematoma and preoperative GCS had a significant prognostic predictor of surgical outcome that detected by Receiving Operator Characteristic (ROC) curve with cutoff point of 56.0 cm^3 and 9 respectively. **Conclusion:** The sizable

hypertensive ICH is a surgically treatable condition. The predicting factors of mortality outcome are preoperative GCS ≤ 9 and hematoma volume $\geq 56.0 \text{ cm}^3$ with no value of age, sex or site of hematoma.

Key words: Intracerebral, hematoma, Glasgow coma scale.

Introduction

Spontaneous Intra-cerebral hemorrhage (ICH) is defined as hemorrhage in the cerebral matter without history of trauma. It can be divided into primary and secondary types. Primary ICH occurs in the absence of a structural disease process; secondary ICH is associated with a congenital or acquired lesion, it accounts for 10% to 30% of all strokes ⁽¹⁾.

Primary ICH is responsible for 70-80% of patients and is a result of either chronic hypertension, which accounts for more than 50% of patients, or amyloid angiopathy ⁽²⁾.

Secondary ICH is associated with underlying condition such as vascular malformations, coagulopathy, tumors, or substance abuse ⁽³⁾.

The most common locations of cases of spontaneous ICH are basal ganglia (50%) of cases, followed by subcortical white matter, cerebellum, and thalamus.

Common neurological signs in cases of putaminal ICH are hemiparesis, hemisensory syndrome, homonymous hemianopsia, horizontal gaze palsy, aphasia (in dominant hemisphere), and hemineglect (in non- dominant hemisphere).The

bleeding vessels are the perforating branches of the anterior and middle cerebral arteries ⁽⁴⁾.

Computed Tomography (CT) scan of the brain has a sensitivity and specificity that approaches 100% for acute ICH. The volume of the ICH can be approximated rapidly with a CT brain scan. The management of ICH is controversial. Studies show that those who suffer ICH have a 30 days mortality rate of 35-44% and a 6 months mortality rate approaching 50%. The medical management includes control of blood pressure which is the most important factor in determining the rapid extension of ICH ⁽⁵⁾.

Medical control of Intracranial Pressure (ICP) with the use of osmotic diuretics; mannitol safely and effectively lowers the ICP. The use of steroids is controversial ⁽⁴⁾.

PURPOSE

The aim of this study was to evaluate the outcome of surgical management of spontaneous intra-cerebral hematoma, and express the predicting factors favoring good or bad outcome.

Patients and methods

Study design: The study was clinical cohort prospective study in Benha University Hospitals on 40 cases admitted in the period between December 2019 and June 2021, suffering from spontaneous hypertensive intracerebral hemorrhage. Inclusion criteria are patients with Glasgow coma scale (GCS) $\geq 5/15$, history of hypertension and hematoma volume ≥ 30 cc. Exclusion criteria include patients of non-hypertensive spontaneous ICH, fatal GCS 3-4/15 and hematoma volume < 30 cc. The studied group was divided into 2 groups (survived and died).

Pre-operative assessment: All patients underwent complete general and neurological examination. Presenting symptoms, GCS, sex, age, blood pressure, and blood glucose level were observed. Associated medical history was evaluated (Diabetes Mellitus, hepatic diseases, cardiac diseases and if any medication was taken especially antihypertensive, anti-platelets and anticoagulant drugs). We classified the patients according to GCS into three categories; GCS 5-8, GCS 9-12 and GCS 13-15⁽³⁾.

Routine laboratory investigations were done: CBC, bleeding profile (PT, PC, INR, and

PTT), liver and kidney function tests and serum electrolytes.

Pre-operative CT scan brain was done to all the cases. The hematoma volume was calculated using the modified ellipsoid method: $(A \times B \times C)/2$, where **A** is the largest diameter of the hematoma on axial CT scan slice in centimeters, **B** is the diameter perpendicular to **A** on the same slice, and **C** is the thickness of the hematoma on CT in centimeters, also counted as the number of axial cuts on CT multiplied by slice thickness in centimeters (excluding the highest and lowest cuts visualizing the ICH)⁽⁶⁾. Hematomas were subdivided into medium (31-60 cm³), large (61-90 cm³) and extensive > 90 cm³⁽³⁾.

Operative note: All patients were entered to the unit of intensive care (ICU) and given loading dose of phenytoin and brain dehydrating measures as mannitol 20% and furosemide. Patients were operated upon within a span of time of 24-36 hours of admission after their preparation and blood pressure control. Approach design according to site of hematoma (**Figure 1**).

Lobar hemorrhages were emptied using craniotomies centered over the hematoma. After the craniotomy, opening of the dura was done with caring for arachnoid layer and

superficial cortical vessels to be not injured. Superficial hematomas were reached by means of a combination of bipolar cautery and small suction tips until the hematoma cavity is reached. Once in the hematoma, tumor forceps were used to evacuate solid parts of the hematoma. Semisolid parts of the hematoma were erased using suction tips. Then Hemostasis can be accomplished with a combination of topical hemostatic agents like microfibrillar collagen, Floseal (gelatin matrix thrombin sealant) and Gelfoam (gelatin sponge, Baxter). The systolic blood pressure can be raised 10 to 20 points before closure to identify any potential bleeding sources. The mass effect is typically relieved after hematoma removal, and the bone flap can be replaced (7).

For putaminal hemorrhages, two strategies were utilized: Trans temporal or transsylvian; the transsylvian approach puts the minor amount of brain in danger, because the insular cortical point of entry is the most proximal to the putamen. For putaminal hematomas that expand considerably into the temporal lobe, the trans-temporal approach was utilized. Complete evacuation and good hemostasis were considered important for better surgical outcome. Complications during surgery as

challenging hematoma removal, difficult hemostasis and inadequate evacuation were all noted (7).

Postoperative follow up: All cases underwent post-operative general and neurological examination, CT brain (**Figure 2**) and the outcome of the operated patients was evaluated as regards; GCS, residual neurological deficits, residual hematoma and rebleeding. Postoperative complications as re-bleeding, the need for a second operation for re-evacuation of hematoma and/or the need for decompression craniotomy\craniectomy were observed and recorded. Postoperative ICU related and coma related complications, specially chest infection, wound infection, deep venous thrombosis (DVT) and pulmonary embolism were observed and recorded.

Ethical approval: This research accepted by Research Ethics Committee (REC) of Faculty of Medicine, Benha University. The reference number of the ethics approval from the ethics committee: RC 20/10/2021. All procedures performed in studies involving human participants were in accordance with the ethical standards of the institutional and/or national research committee and with the 1964 Helsinki declaration and its later amendments or comparable ethical standards. A written

informed consent was taken from first order relatives of patients after explaining all steps of this study.

Statistical analysis: The data was analyzed by SPSS version 26 Armonk, USA. Frequency and percentage was calculated for categorical variables. Mean \pm SD was calculated for quantitative data. Receiving operator characteristic (ROC) curve was used to detect validity of age and volume of hematoma. Statistical significance was accepted at P value ≤ 0.05 while a P value > 0.05 was considered insignificant.

Results

Our study was conducted prospectively in the Benha University Hospitals on 40 patients experiencing unexpected hypertensive intracerebral bleeding whom were operated in Neurosurgery department with age ranged between (40 and 83 years) and the mean (\pm SD) was 56.89 ± 7.93 and 57.64 ± 9.73 years in survived and died groups respectively with male predominance (60%) which were statistically insignificant (**Table 1**).

Preoperative GCS of 13-15 in survived cases was 80% while all cases were died (100%) in died group of GCS 5-8 which was statistically significant. Volume of

hematoma also affects the outcome as in moderate hematoma 67% of cases survived but 33% died, in large hematoma 17% survived while 83% died and all cases (100%) were died in extensive hematoma which statistically significant. According to site of hematoma, the most common site was basal ganglia with 45.5% and 54.5% of cases in survived and died groups respectively which were statistically insignificant.

There is direct relation between conscious level and average volume of hematoma (**Table 2**) with subsequent affecting the outcome.

Table 3 shows that the most of these postoperative complications occurred relating to ICU stay in 22 cases (55%) with 17 cases (42.5%) due to chest infection. Only 2 cases (5%) had complications related to wound infection which treated successfully by antibiotics.

Receiving Operator Characteristic (ROC) curve in **Figure 3** shows that volume of hematoma had a significant prognostic predictor of surgical outcome with cutoff point of 56.0 cm^3 which had 90.9% sensitivity and 77.8% specificity which was statistically significant. Age was detected of no prognostic value as cutoff point was 53.5 years with 50%

sensitivity and specificity which was statistically insignificant.

Receiving Operator Characteristic (ROC) curve (**Figure 4**) shows that GCS had a

significant prognostic predictor of surgical outcome with cutoff point of 9 which had 86.4% sensitivity and 83.3% specificity which was statistically significant.

Table (1): Relation between age, sex, preoperative assessment of conscious level (GCS), volume of hematoma & site of hematoma and surgical outcome

Surgical outcome	Survived (18)	Died (22)	Total (40)	Statistical test	P value
Age/years Mean ±SD	56.89±7.93	57.64±9.73	57.3±8.86	0.26	0.80
Sex: no(%)				0.017	0.90
Male	11(45.8%)	13(54.2%)	24(60.0%)		
Female	7(43.75%)	9(56.25%)	16(40.0%)		
Preoperative GCS: no(%)				8.55	0.014*
5-8					
9-12	0(0%)	10(100%)	10(25%)		
13-15	14(56%)	11(44%)	25(62.5%)		
	4(80%)	1(20%)	5(12.5%)		
Volume of hematoma (Cm3): no(%)				8.92	0.012*
Moderate (31-60)	12(67%)	6(33%)	18(45%)		
Large (61-90)	3(17%)	15(83%)	18(45%)		
Extensive (>90)	3(17%)	1 (100%)	4(10%)		
Site of hematoma: no(%)				0.97	0.91
Basal Ganglia	10(45.5%)	12(54.5%)	22(55%)		
Lobar	3(75%)	1(25%)	4(10%)		
Thalamic	2(40%)	3(60%)	5(12.5%)		
Basal ganglia & Lobar	0(0%)	2(100%)	2(5%)		
Putaminal & Lobar	3(42.9%)	4(57.1%)	7(17.5%)		

*Significant

Table (2): Relationship between conscious level and average volume of hematoma:

Conscious Level	Average Volume of Hematoma in cm³
GCS 13 – 15	47
GCS 9 – 12	65
GCS 5 – 8	84

Table (3): Postoperative complications

Complication	Number	%
Chest infection	17	42.5%
DVT	3	7.5%
Wound infection	2	5%
No complication	18	45%
Total	40	100%

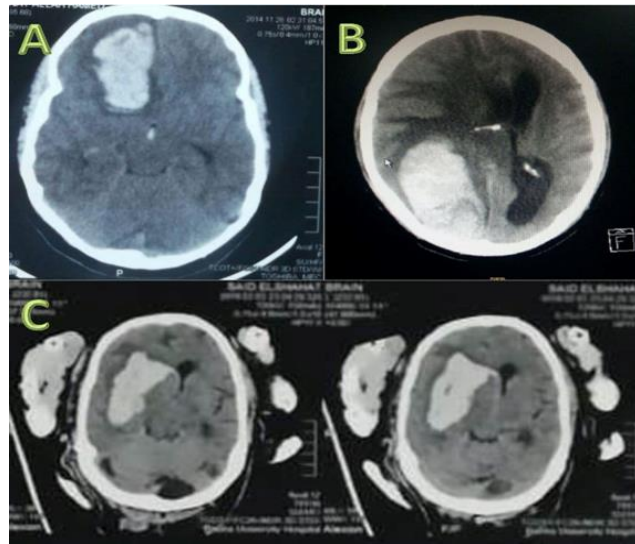


Figure (1): Preoperative CT brain axial cuts without contrast showing different sites of intra-cerebral hematoma (A: frontal, B: occipital lobar, C: ganglionic)

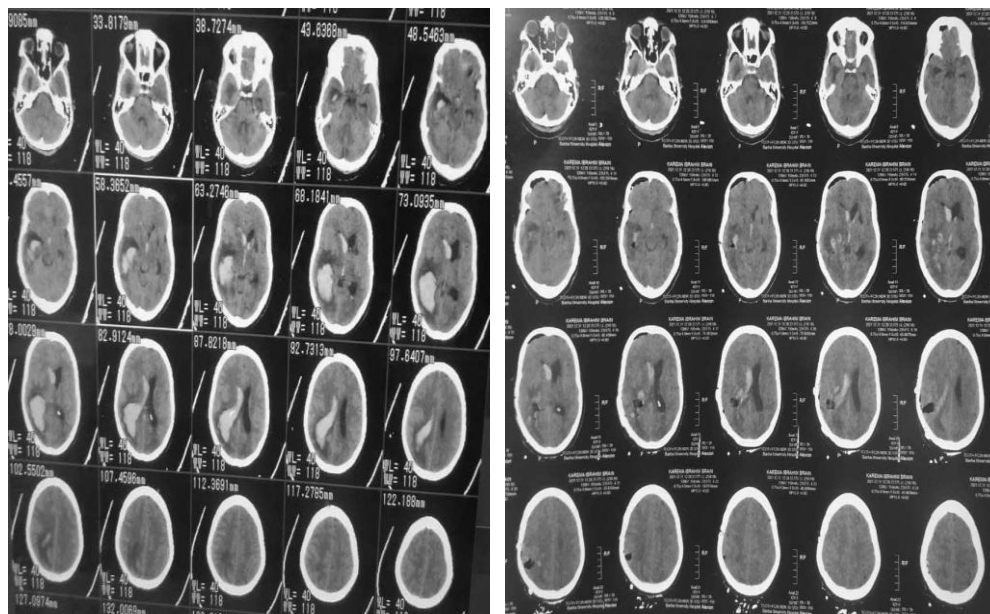


Figure (2): CT brain axial cuts without contrast showing: A) preoperative right temporo-occipital ICH with intraventricular hemorrhage, B) postoperative after hematoma evacuation

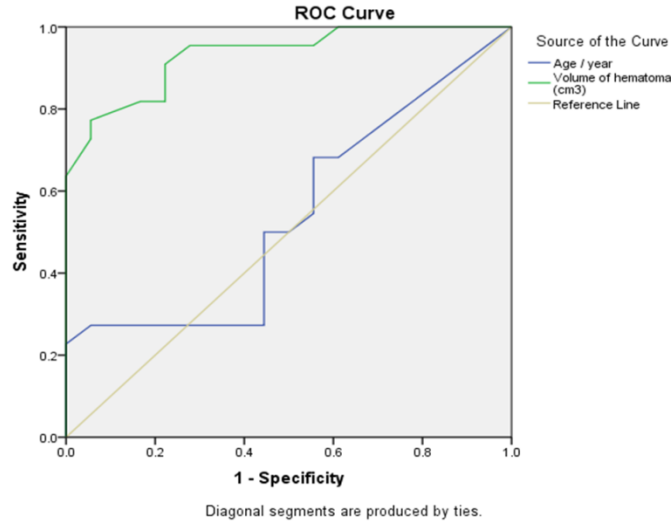


Figure (3): ROC curve of validity of age and volume of hematoma in prognosis of patients

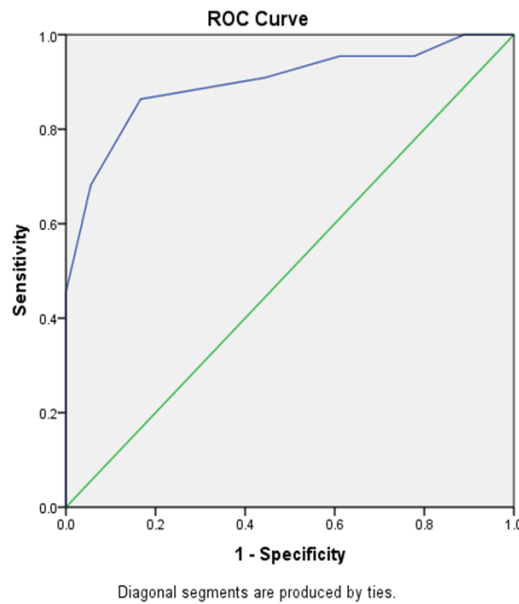


Figure (4): ROC curve of validity of GCS in prognosis of patients

Discussion

This study aims at discussing the outcome of surgical management of hypertensive intracerebral hematoma, factors favoring good or bad outcome especially age, sex,

preoperative GCS and volume and site of hematoma. The occurrence of ICH rises over the age of 55 ⁽⁸⁾. In our research the age varied from 40 – 83 years with mean age of

61.5 years. According Qureshi et al. ⁽⁹⁾, ICH is more prevalent in males more than females. In our study the male: female ratio was approximately 3:2 (24 males and 16 females).

The basal ganglia is the most popular location of ICH, representing 50- 60% of hypertensive ICH, and basal ganglia ICH accounts for 50% of deaths ⁽¹⁰⁾. In our study ICH occurred in basal ganglia in 55%.

In our study most patients presented with disturbed conscious level, this may be due to the large size of the hematoma. Owing to the reality that areas deep in the brain, as basal ganglia are less capable of accommodating large sizes ⁽³⁾, the level of consciousness the patient on admission was linked to the size of the hematoma in our research, as the greater the size of the hematoma, the least the conscious level.

This was clear in our study as the best prognosis was in patients with higher GCS. The mortality rate in patients who presented with GCS 13-15 was 20%, compared to 44% in patients with GCS 9-12, and 100.0% in patients with GCS 5-8. The predicting factors of mortality outcome are preoperative GCS ≤ 9 . Mendelow et al. ⁽¹¹⁾ shows that the worst the conscious level on admission, the worst the prognosis.

The GCS score at admission was significantly higher in the favorable outcome group than that in the poor outcome group ⁽¹²⁾. The factors influencing the prognosis were Glasgow coma scale (GCS) before surgery and the incidence of postoperative complications, volume of hematoma and duration between ictus and surgery ⁽¹³⁾. There was a statistically highly significant relationship between GCS on admission (preoperative) and outcome.

As regards the best choice of management, i.e. medical versus surgical management, a study conducted by Kaya et al., compared the conservative medical treatment with open craniotomy for intracerebral hemorrhage of more than 30 cm³. The surgical group had 34.0% mortality at 6 months compared with 63.1% mortality in the medically treated group ⁽¹⁴⁾. In our study, hematoma volume cut off point with high mortality was larger than 56.0 cm³.

There is a major problem encountered not only in our hospital, but all over the country as we do not have any specially trained nursing staff with special expertise in managing ICH patients. ICH patients are managed in the emergency department, with medical cases managed by the internal medicine physicians and surgical cases

managed by neurosurgeons. In our study we encountered postoperative complications (Chest infection, DVT and wound infection) in 55% of patients.

In our study the limit for evacuation was hematoma larger than 30 cm³. Kaya et al. found that, when hypertensive putaminal hematomas with the volume 30 cm³ or higher are operated, the results are superior to medical treatment. The patients who benefit most from surgical treatment, with respect to functional status, are the ones in stupor or semicomatose without herniation signs on admission, indicating that those patients are good candidates for surgery; furthermore, surgery is a life saving measure in patients with herniation signs⁽¹⁴⁾.

Naidech et al.⁽¹⁵⁾ detected that, the most patients that die from ICH do so during the initial acute hospitalization, and these deaths usually occur in the setting of withdrawal of support due to presumed poor prognosis.

Conclusion

The sizable hypertensive ICH is a surgically treatable condition. The predicting factors of mortality outcome are preoperative GCS ≤ 9 and hematoma volume ≥ 56.0 cm³ with no value of age, sex or site of hematoma. The reason of mortality in a lot of patients was

correlated to perioperative complications apart from the hematoma or the surgery.

References

1. **Hsieh P.C., Awad I.A., Getch C.C., Bandok B.R., Rosenblatt S.S., Bayjer H.H.:** Current Updates in the Perioperative Management of Intracerebral Hemorrhage. *Neurol. Clin*; 2006, 24:745-64.
2. **Mayer S.A., Rincon F.:** Treatment of intracerebral hemorrhage. *Lancet Neurol*; 2005, 4:662-72.
3. **Broderick J.P., Brott T., Tomsick T., Huster G.:** Intracerebral hemorrhage more than twice as common as subarachnoid hemorrhage. *J. Neurosurg*; 1993, 78:188-91.
4. **Singh R.V., Prusmack C.J., Morcos J.J.:** Spontaneous Intra-cerebral Hemorrhage: Non-Arteriovenous Malformation. In Winn HR (eds): *Youmans Neurological Surgery*. Philadelphia, PA, Saunders Publishers, 2004, pp 1733-68.
5. **Bae HG, Lee KS, Yun IG; Bae WK, Choi SK, Byun BJ, Lee IS:** Rapid expansion of hypertensive intracerebral hemorrhage. *Neurosurgery*, 1992, 31:35-41.
6. **Kothari R.U., Brott T., Broderick J.P., Barsan W.G., Sauerbeck L.R., Zuccarello M., et al.:** The ABCs of measuring intracerebral hemorrhage volumes. *Stroke*, 1996, 27:1304-5.
7. **Aghi M.K., Ogilvy C.S. & Carter B.S.:** (Surgical management of intracerebral hemorrhage) in (Schmidek HH, & Roberts DW) eds., *Operative Neurosurgical Techniques*, 6th edition, ELSEVIER saunders; 2012, 69: 823-835.
8. **Giroud M., Gras P., Chandan N.:** Cerebral hemorrhage in a French prospective population study. *J. Neurol. Neurosurg. Psychiatry*, 1991, 54:595-598.

- 9. Qureshi A.I., Giles W.H., Croft J.B.:** Racial differences in the incidence of intracerebral hemorrhage: Effects of blood pressure and education. *Neurology*, 1999, 52:1617-21.
- 10. Alkhadrawy S.M., Alaghory I.M., Selim M.M.:** Surgical management of spontaneous intracerebral hemorrhage. *Sci J Al-Azhar Med Fac Girls*, 2019; 3:131-41.
- 11. Mendelow A.D., Gregson B.A., Fernandes H.M., Murray G.D., Teasdale G.M., Hope D.T., et al.:** Early surgery versus initial conservative treatment in patients with spontaneous supratentorial intracerebral hematomas in the International Surgical Trial in Intracerebral Hemorrhage (STICH): a randomized trial. *Lancet*, 2005, 365:387-397.
- 12. Takeuchi S., Takasato Y., Masaoka H., Hayakawa T., Yatsushige H., Shigeta K., et al.:** Decompressive craniectomy with hematoma evacuation for large hemispheric hypertensive intracerebral hemorrhage. *Acta Neurochir Suppl*; 2013, 9:118-27.
- 13. Wang D.J., Wang S., Zhao Y.L., Kang S., Wang M., Liu K.J., et al.:** Multianalysis of short-term prognostic factors in surgical practices for hypertensive intracerebral hemorrhage. *Zhonghua Yi Xue Za Zhi*; 2005, 44:23-85.
- 14. Kaya R.A., Türkmenoğlu O., Ziyal I.M., Dalkiliç T., Sahin Y., Aydın Y.:** The effects on prognosis of surgical treatment of hypertensive putaminal hematomas through transsylvian transinsular approach. *Surg Neurol*; 2003, 59:176-83.
- 15. Naidech A.M., Bernestein R.A., Bassin S.L., Garg R.K., Liebling S., Bendok B.R., et al.:** How patients die after intracerebral hemorrhage. *Neurocrit Care*, 2009, 11:45-9.

To cite this article: Mohamed Elhawary, Mohamed M Elmaghrabi, Hany Elnemr. Spontaneous Intra-Cerebral Hematoma; Results of Surgical Management in Benha University Hospitals. *BMFJ* 2023;40(surgical issue):224-234.