

Laparoscopic Adhesiolysis in Manegment of Adhesive Intestinal Obstruction

Fathy El Azizy Mohamed Abd Ellatif ^{1,*} M.B.B.Ch, Mohamed Kamel Elmezain ¹ MD and

Alsayed Basiony Moghazy Aboulyazied ¹ MD

*Corresponding Author:

Fathy El Azizy Mohamed Abd Ellatif
fat7eelazizy1992@gmail.com

Received for publication March 12, 2022; Accepted September 24, 2022; Published online September 24, 2022.

doi: 10.21608/aimj.2022.125330.1864

Citation: Fathy E. , Mohamed K. and Alsayed B., Laparoscopic Adhesiolysis in Manegment of Adhesive Intestinal Obstruction. AIMJ. 2022; Vol.3-Issue9 : 108-115.

¹General Surgery Department, Faculty of Medicine, Al-Azhar University Cairo, Egypt.

ABSTRACT

Background: A frequent surgical illness is bowel obstruction. The mechanical and non-mechanical causes of bowel obstruction may be split into two groups, with mechanical obstruction being the more prevalent.

Aim of the work: To see how effective laparoscopic adhesiolysis is in treating those who have recurring adhesive intestinal obstruction incidents.

Patients and methods: Twenty patients with adhesive intestinal obstruction were enrolled in the research and underwent diagnostic laparoscopy in in general surgery department at Al-Azhar University Hospitals and Damanhour Medical National Institute.

Results: In our study, median operative time was 93.42 ± 24.67 min, and median hospital stay was 3.85 ± 4.46 days. Adhesiolysis was successfully done by laparoscopy in 95% of the patients. Also Majority of the patients had no complications (80%) however, the most common complication was prolonged postoperative ileus (10%). One patient was converted to laparotomy.

Conclusion: In the hands of an experienced surgeon, laparoscopic adhesiolysis for recurring postoperative adhesive bowel obstruction is practical and secure, with a high rate of success and minimum perioperative morbidity.

Keywords: Bowel obstruction; Postoperative ileus; Adhesiolysis; Adhesive intestinal.

Disclosure: The authors have no financial interest to declare in relation to the content of this article. The Article Processing Charge was paid for by the authors.

Authorship: All authors have a substantial contribution to the article.

Copyright The Authors published by Al-Azhar University, Faculty of Medicine, Cairo, Egypt. Users have the right to read, download, copy, distribute, print, search, or link to the full texts of articles under the following conditions: Creative Commons Attribution-Share Alike 4.0 International Public License (CC BY-SA 4.0).

INTRODUCTION

Intra-abdominal adhesions may be congenital or acquired. Acquired adhesions usually occur as a result of abdominal surgery, trauma, or inflammatory insult. Adhesion development may result in intestinal obstruction, prolonged stomach discomfort, or infertility in women. Preventive treatment advancements have not yet achieved the anticipated impact of preventing adhesive formation.¹

The Halstedian concepts of precise hemostasis, gentle tissue handling to reduce trauma, and keeping tissues wet have long been recommended as excellent adhesion prevention measures. Peritoneal damage, abdominal wall trauma, foreign body introduction, trauma to nearby or distant organs, and tissue ischemia are all hypothesized to play a role in adhesion formation aetiology.²

A laparoscopic method should presumably make it easier to avoid these risk factors. Laparoscopy often does not need the use of retractors or bowel packing, resulting in less tissue manipulation. Other benefits of laparoscopic surgery in terms of adhesion prevention include: decreased peritoneal surface dryness and reduced gastrointestinal motility impairments.³

Glucocorticoids and antihistamine preparations, Glucocorticosteroids reduce the vascular permeability by reducing the systemic inflammatory response of the body and increases the separation of cytokines and hemotaxial factors. These medications have yielded few results in the prevention of adhesions. Corticosteroids, such as dexamethasone, hydrocortisone and prednisolone, were tested and tested separately, along with antihistamines, such as promethazine. Antihistamines, combined with glucocorticoids, inhibit the proliferation of fibroblasts, which in turn prevents the growth of the adhesions. However, these drugs have side effects, such as immunosuppression or retardation of wound healing, so they are used with caution nowadays.⁴

Operative adhesiolysis is the only way to get rid of adhesion after it has developed. When conservative therapy fails or symptoms signal a clinical or physiological emergency, like toxemia or ischemia, open laparotomy is universally acknowledged as the standard procedure for Adhesive Intestinal Obstruction, but this open method may be followed by many complications such as postoperative pain, ileus, increased incidence of wound infections, a more incisional hernia rate, increased incidence of recurrent attack of adhesive intestinal obstruction, longer postoperative hospital stay, aesthetic Traditional laparotomy has been replaced as an

elective therapy for a variety of disorders by laparoscopy. It's linked to a decreased risk of morbidity and a shorter stay in the hospital. Adhesive intestinal obstruction might be a possibility for modification to laparoscopic surgery, as it is becoming a therapeutic option in emergency surgery for acute cholecystitis, acute appendicitis, and peptic ulcer rupture.⁵

Theoretically, adhesiolysis with a laparoscope should result in better results than traditional open surgery.⁶

Due to the higher risk of iatrogenic injuries, the difficulties in controlling dilated intestinal segments, and the inferior operating area, bowel obstruction has traditionally been considered an absolute contraindication for the laparoscopic technique.⁷

Because the above-mentioned challenges have been significantly minimized as a result of growing expertise with this method, this contraindication is now just relative. As a result, patients undergoing this procedure can reap the following benefits: less postoperative pain, less ileus, a lower incidence of wound infections, a lower rate of incisional hernia, a shorter postoperative hospital stay, aesthetic benefits, and a reduction in future adhesions.⁷

This final benefit is likely the most significant, considering that the likelihood of a subsequent episode of bowel obstruction in these patients rises by 30% after the first incident, 40% after the second, and up to 60% after the third.⁷

Patients who show indications of strangulation or peritonitis (fever, tachycardia, leukocytosis, continuous pain, focal tenderness, guarding) and/or radiological findings of bowel ischemia (free peritoneal fluid, mesenteric edema, presence of the small bowel feces sign in CT) need an urgent exploration and a bowel resection in case of ischemia.⁸

The goal of our research was to see how effective laparoscopic adhesiolysis is in treating individuals with recurring adhesive intestinal obstruction.

PATIENTS AND METHODS

This was a prospective research including 20 participants diagnosed with adhesive intestinal obstruction and underwent diagnostic laparoscopy in general surgery department at Al-Azhar University Hospitals and Damanhour Medical National Institute.

Inclusion criteria: Patients with adhesive intestinal obstruction not, and resolving with conservative management.

Exclusion criteria: Suspicion of organic intestinal obstruction than adhesions, severe abdominal distension, previously confirmed or strongly suspected abdominal malignancy, abdominal radiation in the past, abdominal surgery in the recent past (within 30 days), and pregnancy, uncontrolled hepatic diseases and cardiopulmonary problems.

According to the ethics committees of both institutions, every patient who participated in the research gave their informed permission.

Preoperatively, all patients underwent to:

History taking including nature of previous surgery and number of previous attacks of intestinal obstruction.

Clinical examination.

Pre-operative Radiological investigations including: Abdominal plain erect x-ray, ultrasonography and CT.

Laboratory tests performed before to surgery, including: Complete blood count, coagulation profile, serum ALT level, random blood glucose level, serum creatinine level, serum sodium and potassium levels, serum CRP level, and serum LDH level.

Initially, the patients were closely monitored throughout a period of conservative therapy that included fasting, insertion of a nasogastric tube, antibiotic medication, and intravenous fluids and electrolytes. Serial abdominal radiographs, clinical examination, and necessary laboratory testing are all part of the observation process. Patients who did not have their bowel obstruction cleared within 72 hours were operated on.

Operative procedure:

For the laparoscopic approach:

With either an open approach or a Veress needle, the abdomen was penetrated away from scars from prior procedures. When using the Veress needle, a syringe test was done to ensure that the needle's tip was not lodged in a vessel or the intestines, as follows: The Veress needle is used to inject a 5 mL normal saline solution. The saline solution could not be respired if it got into the peritoneal cavity. Respiration of the saline solution indicated that the Veress needle tip was in a closed cavity or freshly created space.

Carbon dioxide insufflation to a maximum pressure of 14 mmHg had been used to create a pneumoperitoneum. The remaining ports are introduced under direct vision based on the first telescopic inspection of the abdominal cavity and adhesion sites to make it accessible for cutting.

The bowel was manipulated with atraumatic graspers and adhesions are identified and lysed with combination of sharp and blunt dissection. To reduce the incidence of intestinal injury and recurrence of adhesion formation, diathermy is not used except for haemostasis. The lysed region was meticulously evaluated for any bleeding and intestinal damage once appropriate adhesiolysis was completed. Ports were removed under vision after insertion of a tubal drain. Fascial defects 10 mm or larger are closed with non-absorbable sutures to prevent port site hernia.

To ensure patient safety, certain criteria for converting to open surgery are established: A minor intestinal perforation that could not be repaired with laparoscopic suturing was confirmed or suspected. There was no mention of a changeover point. The cause of the impediment has yet to be discovered. The presence of peritoneal carcinomatosis is discovered. Diffuse adhesions are prevalent across large areas. Resection of the bowel was required.

The following operative data had been recorded: Number of ports used, site of first port, location of adhesions, duration of operation, and intraoperative complications as visceral injury need for blood transfusion or conversion to laparotomy.

Postoperatively, the patients will be managed as follow:

Patients had been kept nil by mouth on IV fluids till regaining of bowel activity in the form of audible bowel sounds and passing of flatus or motion. After regaining bowel activity, the nasogastric tube is removed and oral fluids are started first followed by soft diet.

Wound infection, postoperative ileus, peritonitis and other general complications eg. DVT and chest infection, if any, are recorded and taken care of. Patients are discharged after per oral nutrition was tolerated and sufficient pain relieve is achieved. Duration of postoperative hospital stay is recorded. Patients were asked to follow up after 1week, 1, 3, and 6 months for later complications as port site hernia, recurrence of obstruction and need for reoperation. The outcome of the operation will be recorded.

Ethical considerations:

The collected data had been used in research purpose only, the approval of parents of the children were mandatory after informing them about the study's purpose and the procedures their children had been undergo.

Statistical analysis

The data was entered into a computer and statistically evaluated using the SPSS (Statistical Package for Social Science) version 24 application. The Shapiro Walk test was used to determine whether the data had a normal distribution. Frequencies and relative percentages were used to depict qualitative data. The difference between qualitative variables was calculated using the Chi square test (χ^2). The median and standard deviation were used to convey quantitative data. For parametric and non-parametric parameters, the Student t test was employed to quantify the variance between quantitative variables in two groups. All statistical comparisons were done using a two-tailed significance level. A P-value of <0.05 shows a substantial variance, while a P-value of ≥ 0.05 shows a non-significant variance.

RESULTS

Variables		Patients (n=20)
Age (years)		
Mean \pm SD.		37.24 \pm 8.67
Range		20 - 58
Sex	Male	12 (60%)
	Female	8 (40%)
BMI (kg/m ²)		
Mean \pm SD		29.33 \pm 2.94

Table 1: Demographic characteristics of studied patients

Patients aged between 20 to 58 years with mean BMI 29.33 kg/m². 60% of the patients were males (Table 1).

	Patients (n=20)	
	N	%
Comorbidities:		
Smokers	9	45
Hypertension	5	25
Diabetes mellitus	3	15
Previous surgeries history:		
No history of previous surgeries	6	30
Appendicectomy	6	30
Gynecological surgeries	4	20
Inguinal hernia	2	10
Perforated peptic ulcer	1	5
Cholecystectomy	1	5
Site of adhesions:		
Lower abdomen	16	80
Upper abdomen	4	20

Table 2: Comorbidities distribution, previous surgeries history and Site of adhesions between the studied patients

Table 2 showed 45% of the patients were smokers, while 25% of the patients were hypertensive and 15% of the patients were diabetics. There was 30% of the patients had no history of previous surgeries due to congenital Adhesions, while 70% had history of previous surgeries, the most common surgery was appendicectomy (30%) and gynecological surgeries (20%) and inguinal hernia (10%). In 80% of patients, adhesions were found in the lower abdomen while 20% of the patients had adhesions in the upper abdomen.

	Patients (n=20)	
	N	%
Number of episodes/attacks	2	60
	3	25
	4	15
Number of ports	16	80
	3	4
	4	20
Location of the first port	13	65
	Umbilical	4
	Left upper quadrant	2
	Right upper quadrant	1
	Right lower quadrant	5

Table 3: Clinical characteristics between the studied patients

Most of the patients had previous two attacks of bowel obstruction (60%), 25% had attacks for three times and 15% had attacks for four times. Laparoscopic access was performed through the umbilicus in 65% of the patients, 20% through the left upper quadrant and 10% through the right upper quadrant while through the right lower quadrant was done in only one patient (5%). 80% of the patients had 3 ports while 20% had 4 ports (Table 3).

Variables	Patients (n=20)	
	Mean± SD	Range
Operative time (min)	93.42 ± 24.67	74 - 140
Hospital stay (days)	3.85 ± 4.46	2 - 21

Table 4: Operative time and hospital stay of studied patients

This table shows that the average operating duration was 93.42 ± 24.67 min, and average hospital stay was 3.85 ± 4.46 days (Table 4).

	Patients (n=20)	
	N	%
Success	19	95%
Failed	1	5%

Table 5: Success rate among the studied patients

Adhesiolysis was successfully done by laparoscopy in 95% of the patients (Table 5).

	Patients (n=20)	
	N	%
No complications	16	80%
Prolonged postoperative ileus	2	10%
Wound infection	1	5%
Intestinal serosal injury	1	5%
Bladder injury	1	5%
Conversion to laparotomy	1	5%

Table (6): Postoperative complications among the studied patients

Majority of the patients had no complications (80%). However, the most common complication was prolonged postoperative ileus (10%). One patient was converted to laparotomy (Table 6).

CASES

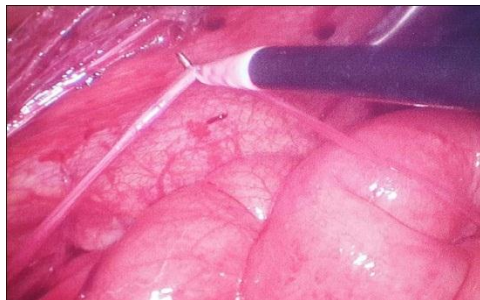


Fig. 1: Adhesive band during laparoscopic adhesiolysis.

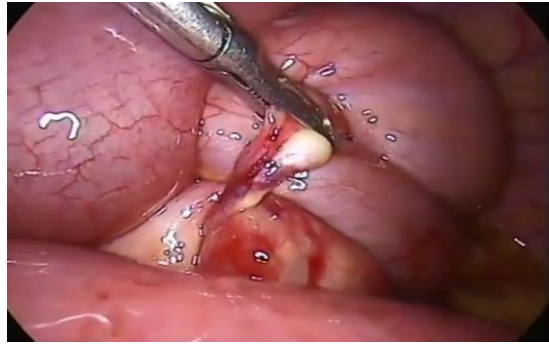

Fig. 2: Intestinal obstruction due to Adhesive band on appendicular stamp "during laparoscopic adheiolysis".

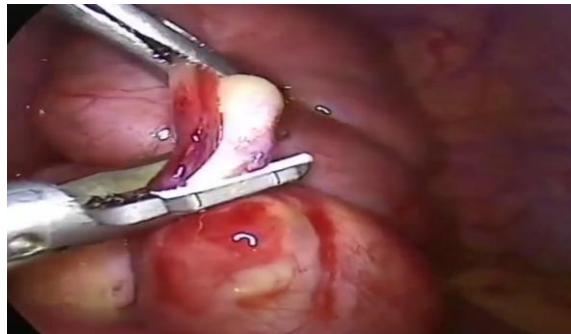

Fig. 3: During release of the band by scissors.

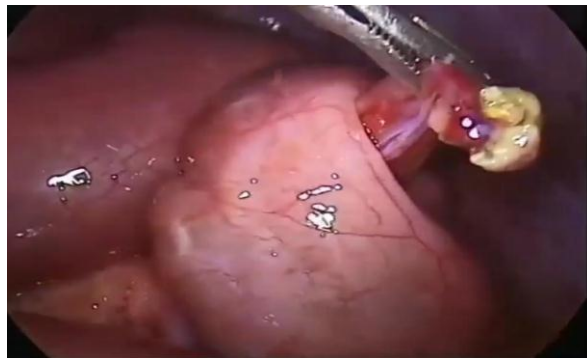


Fig. 4: After releasing the band.

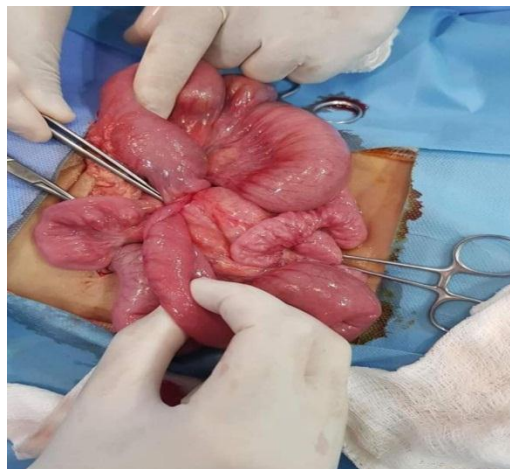


Fig. 5: Congenital adhesive band in mal patient presented by intestinal obstruction.

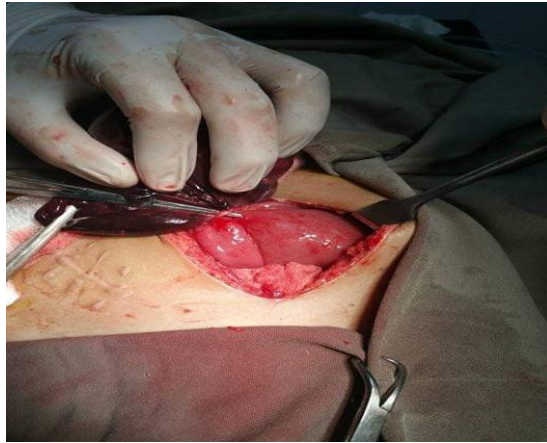


Fig. 6: Adhesive Intestinal obstruction due to Adhesive band post appendectomy with gangrenous part of small bowel "ilium Adhesive Intestinal.

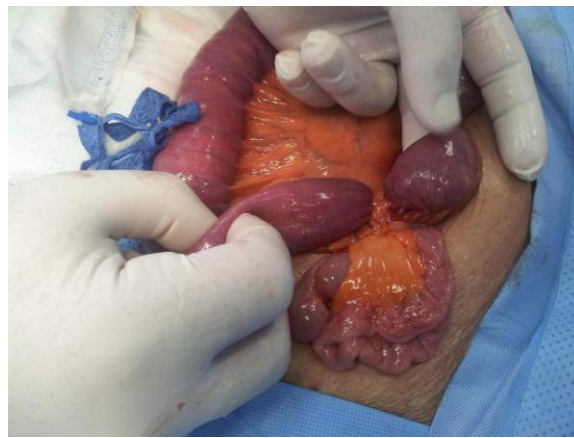


Fig. 7: Obstruction in femal patient due to Adhesive band post appendectomy with dilated part proximal to band and collapsed part distal to the band.

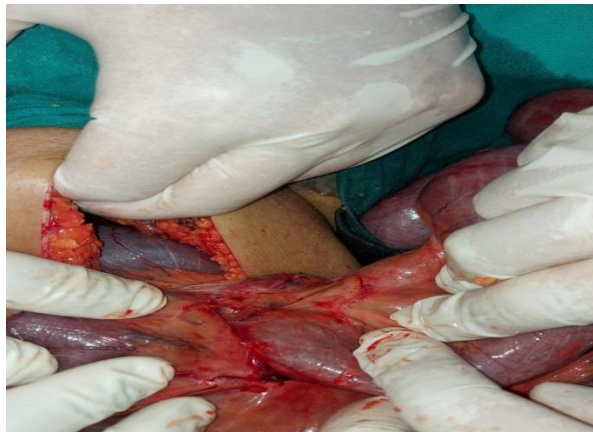

Fig. 8: Adhesive Intestinal obstruction due to multiple Adhesive bands.

DISCUSSION

As regarding Demographic characteristics of studied patients, Patients aged between 20 to 58 years with mean BMI 29.33 kg/m². 60% of the patients were males. This is concordant with many studies regarding studying adhesive intestinal obstruction. Albatanony et al.⁶ concluded that age range of the studied patients with adhesive I.O was 10.0-56.0 years, most of them were males (60.0%). Also, Khalil et al.⁹ reported mean age of 47.5 years but

females represented 53.9% of the studied subjects suffering from adhesive I.O. Also this is similar to the results obtained by Kuremu and Jubi¹⁰ in South Africa in 2006. They found tha the male to female ratio was 1.6: 1.

As regarding sex distribution, our results are similar to the results obtained by Kuremu and Jubi¹⁰ in South Africa in 2006. They found that the male to female ratio was 1.6: 1. In contrast Sastry et al.¹¹ reported that women have a greater risk for

postoperative adhesive SBO than men, even after exclusion of operations for gynecological indications.

As regarding Previous surgeries history between the studied patients, there was 30% of the patients had no history of previous surgeries, while 70% had history of previous surgeries, the most common surgery was appendectomy (30%) and gynecological surgeries (20%).

Previous surgeries are the most common causes of adhesive intestinal obstruction. In concordance with our results Albatanony et al.⁶ concluded that the operations accounting for the majority of postoperative, adhesive intestinal obstruction were appendectomies, followed by gynecological surgeries, then colonic surgeries. In this study, appendectomy was the commonest previous operation that caused postoperative adhesive intestinal obstruction.

The study of Leung et al.¹² reported that Adults have a 2.8 percent chance of developing SBO after an appendectomy. Appendiceal perforation, midline incision, and chronic appendicitis are all risk factors for developing SBO after an appendectomy for appendicitis.

In our study, as regarding site of adhesions distribution among the studied patients. In 80% of patients, adhesions were found in the lower abdomen while 20% of the patients had adhesions in the upper abdomen. This is concordant with previous results as most cases were operated in lower abdomen and pelvis.

As regarding clinical characteristics between the studied patients. Most of the patients had previous two attacks of bowel obstruction (60%), 25% had attacks for three times and 15% had attacks for four times. Laparoscopic access was performed through the umbilicus in 65% of the patients, 20% through the left upper quadrant and 10% through the right upper quadrant while through the right lower quadrant was done in only one patient (5%). 80% of the patients had 3 ports while 20% had 4 ports.

Postoperative adhesions cause small bowel obstruction (SBO) in 6–11% of all patients who have a laparotomy.¹³ It may happen at any moment after the original laparotomy and leads to a lot of readmissions in the following years.¹¹

Open surgical treatment of ASBO may result in the creation of new adhesions, which may contribute to recurrent ASBO episodes. Adhesive SBO is the natural next target for a laparoscopic technique as laparoscopic surgery becomes increasingly frequent in emergency surgery.¹⁴

In our study, median operative duration was 93.42 ± 24.67 min, and median hospital stay was 3.85 ± 4.46 days. Adhesiolysis was successfully done by laparoscopy in 95% of the patients. Also, majority of the patients had no complications (80%). However, the most common complication was prolonged postoperative ileus (10%). One patient was converted to laparotomy.

Our results were consistent with the study of Khalil et al.⁹ A total of 51 individuals were found and

separated into two groups, each having a diagnosis of recurrent small bowel obstruction. A total of 26 patients were treated with laparoscopic adhesiolysis (23 were successfully treated and three required open surgery), with low repetition, short hospital stays, and early bowel movement recovery. A total of 25 patients had conservative therapy, with three instances requiring surgical intervention. In terms of morbidity and death, there was no substantial difference between the two groups.

This study adheres to the dictum 'the sun should never rise or set on a small bowel obstruction'. We performed laparoscopic adhesiolysis to free the adhesions and relieve the obstruction. We used laparoscopy as a minimally invasive technique to minimize recurrence, which was significantly increased in the conservative method, and this is in line with the findings of the research by Fevang et al.¹⁵ and Niyaf et al.¹⁶.

In our study we achieved Adhesiolysis successfully done by laparoscopy in 95% of the patients. Which is higher than what reported by El Labban¹⁷, he reported Laparoscopy was tried in 36 patients with intestinal blockage in this research, and it was effective in 15 instances (the laparoscopic group) with a 41.6 percent success rate. Multiple adhesions or difficult adhesiolysis, gangrenous bowel, and insufficient laparoscopic visibility due to intestinal distention or iatrogenic damage were all reasons for failure in 21 instances. We owe that difference to the good selection of cases in our study.

Our results were similar to Albatanony et al.⁶ they concluded that All patients with sticky intestinal obstruction had postoperative adhesions that were detected laparoscopically. Adhesions were seen distal to the lower abdomen in the vast majority of patients (80%). In 18 (90 percent) of the patients, full laparoscopic adhesiolysis was possible. Two patients (10%) needed laparotomy conversion because to intestinal perforation ($n = 1$) or a convoluted mass of adherent intestine ($n = 1$). Over a 6-month follow-up period, one recurrence of intestinal obstruction was detected, which improved with conservative therapy.

Regarding complications, most common complication was prolonged postoperative ileus (10%). One patient was converted to laparotomy. This is comparable to Albatanony et al.⁶ in the 18 cases completed laparoscopically, intraoperative complications were present in three (15%) occasions and 2 cases (10%) converted to open. Also the results of Sato et al.¹⁸ In their research, they looked at the effectiveness and outcomes of laparoscopic adhesiolysis in the management of individuals with recurrent postoperative SBO. Iatrogenic intestinal injuries occurred during laparoscopic adhesiolysis in three instances out of 14 when adhesiolysis was performed laparoscopically, according to the researchers.

From all the aforementioned data we can conclude that, In the hands of an experienced surgeon, laparoscopic adhesiolysis for the recurrence of postoperative adhesive bowel obstruction is practical and safe, with a high rate of success and minimal perioperative morbidity.

CONCLUSION

In the hands of an experienced surgeon, laparoscopic adhesiolysis for the recurrence of postoperative adhesive bowel obstruction is practical and safe, with a high rate of success and minimal perioperative morbidity.

Conflict of interest : none

REFERENCES

1. ten Broek RP, Strik C, Issa Y, Bleichrodt RP, van Goor H. Adhesiolysis-related morbidity in abdominal surgery. *Annals of Surgery*. 2013; 258(1): 98-106.
2. Chandel AS, Shimizu A, Hasegawa K, Ito T. Advancement of Biomaterial-Based Postoperative Adhesion Barriers. *Macromolecular Bioscience*. 2021; 21(3), 2000395. <https://doi.org/10.1002/mabi.202000395>
3. Anderson SA, Beierle EA, Chen MK. Role of laparoscopy in the prevention and in the treatment of adhesions. *Seminars in Pediatric Surgery*. 2014; 23(6): 353- 6.
4. Fakhradiev IR, Zhumataev DT, Baymakhanov AN, Almabayev IA, Raimkhanov AD. Adhesive Disease. *Bulletin of Surgery of Kazakhstan*. 2019; 1(58): 1-7.
5. Otani K, Ishihara S, Nozawa H, Kawai K, Hata K, et al. A retrospective study of laparoscopic surgery for small bowel obstruction. *Annals of Medicine and Surgery*. 2017; 16: 34-9.
6. Albatanony AA, El Meligy HM, Dorbok MA. The role of laparoscopic adhesiolysis in the treatment of patients with recurrent, adhesive intestinal obstruction. *Menoufia Med J*. 2019; 32:499–505.
7. Fortea-Sanchis C, Priego-Jiménez P, Martínez-Ramos D, et al. A preliminary experience in the laparoscopic approach to bowel obstruction. *Revista de Gastroenterología de México*. 2013; 78(4): 219-24.
8. Abongwa HK, Bresciani P, Tarasconi A, Perrone G, Catena F. Adhesive Small Bowel Obstruction (ASBO): Role of CT scan in guiding choice and timing for treatment options. En: Catena F, Di Saverio S, Ansaloni L, Coccolini F, Sartelli M. editores. *CT Scan in Abdominal Emergency Surgery. Hot Topics in Acute Care Surgery and Trauma*. Cham: Springer. 2018; Pp.137-159. https://doi.org/10.1007/978-3-319-48347-4_13.
9. Khalil OM, Abdalla WM, Allam ZA. Early laparoscopic adhesiolysis versus conservative treatment of recurrent adhesive small intestinal obstruction: a prospective randomized controlled trial. *The Egyptian Journal of Surgery*. 2016; 35(2):96-102.
10. Kuremu RT, Jumbi G. Adhesive intestinal obstruction. *East Afr Med J*. 2006; 83: 333–6.
11. Sastry A, Grigoreva M, Leitman IM. Risk factors for the development of adhesive small bowel obstruction after abdominal and pelvic operations. *Open J Gastroenterol*. 2015; 5:11–6.
12. Leung TT, Dixong E, Gill M, Mador BD, Moulton KM, et al. Bowel obstruction following appendectomy: what is the true incidence?. *Ann Surg*. 2009; 250:51–3.
13. Zielinski MD, Bannon MP. Current management of small bowel obstruction. *Adv Surg*. 2011; 45:1–29.
14. Di Saverio S, Coccolini F, Galati M, Smerieri N, Biffl WL, et al. Bologna guidelines for diagnosis and management of adhesive small bowel obstruction (ASBO): 2013 update of the evidence-based guidelines from the world society of emergency surgery ASBO working group. *World Journal of Emergency Surgery*. 2013; 8(1): 1-14.
15. Fevang BT, Fevang J, Lie SA, Søreide O, Svanes K, et al. Long-term prognosis after operation for adhesive small bowel obstruction. *Ann Surg*. 2004; 240(2): 193–201.
16. Niyaf A, Bhandari RS, Singh KP. Management of adhesive intestinal obstruction. *J Inst Med*. 2010; 32:18–20.
17. El Labban GM. Assessment of laparoscopy in diagnosis and management of adhesive intestinal obstruction. *Archive of Urological Research*. 2018; 2(1): 1-4.
18. Sato Y, Ido K, Kumagai M, Isoda N, Hozumi M, et al. Laparoscopic adhesiolysis for recurrent small bowel obstruction: long-term follow-up. *Gastrointest Endosc*. 2001; 54:476–9.