

Evaluation of Ipsilateral Antegrade Techniques for Endovascular Treatment of Ostial Superficial Femoral Artery Lesions

Khalid Helmi Al-Bealy Al-Belqasy,¹ M.Sc., Ashraf Mohammed Eweda,¹ MD and Abdelaziz Ahmed Abdelhafez,¹ MD.

* Corresponding Author:

Khalid Helmi Al-Bealy Al-Belqasy
tabeebgarrah_khalid@yahoo.com
Received for publication March 11, 2022; Accepted September 27, 2022; Published online September 27, 2022.

doi: 10.21608/aimj.2022.126768.1874

Citation: Khalid H., Ashraf M. and Abdelaziz A. Evaluation of Ipsilateral Antegrade Techniques for Endovascular Treatment of Ostial Superficial Femoral Artery Lesions. AIMJ. 2022; Vol.3-Issue9 .7-13.

¹Vascular Surgery Department, Faculty of Medicine, Al-Azhar University, Assiut, Egypt.

ABSTRACT

Background: The most prevalent cause of intermittent claudication is peripheral arterial disease (PAD) of the superficial femoral artery (SFA). The SFA is a target of atherosclerotic disease predominantly in the distal section in the region of Hunter's canal where the adductor muscles tend to compress the artery and in the proximal section near the bifurcation to the deep femoral artery.

Aim of the study: In patients with persistent lower limb ischemia, to determine the feasibility, adequacy, safety, and consequences of an ipsilateral antegrade approach in the event of superficial femoral artery ostial lesions.

Patients and Methods: Between August 2019 and August 2021, 30 patients with peripheral arterial occlusive disease were included in this prospective cohort research at Al-Azhar University Hospitals (Al-Hussain and Bab-Alsheryah) (affecting ostium of the superficial femoral artery).

Results: The most frequent extension of the lesion was SFA CTO total length till the adductor canal (36.7%), followed by proximal 1/3 SFA tight stenosis extending into middle 1/3 of SFA (26.7%), proximal SFA CTO extending into middle 1/3 of SFA (20%), and proximal 1/3 SFA tight stenosis (16.7%). Most patients showed technical success (80%), and most of them (79.2%) had endo-luminal wire passage. The most frequent type of passage in failure cases was contralateral antegrade (50%), followed by trans brachial antegrade (33.3%) and popliteal ipsilateral retrograde (16.7%).

Conclusion: Endovascular therapy (EVT) in ostial and near ostial SFA occlusive lesions with ipsilateral antegrade access through common femoral artery puncture is a feasible and effective approach.

Keywords: Ipsilateral Antegrade Techniques; Ostial Superficial; Femoral Artery Lesions

Disclosure: The authors have no financial interest to declare in relation to the content of this article. The Article Processing Charge was paid for by the authors.

Authorship: All authors have a substantial contribution to the article.

Copyright: The Authors published by Al-Azhar University, Faculty of Medicine, Cairo, Egypt. Users have the right to read, download, copy, distribute, print, search, or link to the full texts of articles under the following conditions: Creative Commons Attribution-Share Alike 4.0 International Public License (CC BY-SA 4.0).

INTRODUCTION

Peripheral arterial disease (PAD) is a term used to describe the gradual narrowing and blockage of peripheral arteries, particularly those in the lower limbs. Smoking, diabetes mellitus (DM), end-stage renal disease (ESRD), obesity, high blood pressure, high cholesterol, ageing, and a family history of PAD, heart disease, or stroke are all risk factors for PAD. Diabetes is a significant risk factor for PAD.¹

Although accessing the contralateral common femoral artery (CFA) is the standard treatment route, an ipsilateral, antegrade CFA approach offers certain benefits. The main benefit is the shorter access-to-

lesion distance, which increases the mechanical advantage and responsiveness of the instruments employed in the intervention.²

Endovascular revascularization of a flush blockage involving the ostium of the superficial femoral artery (SFA) provides a unique difficulty, requiring advanced methods such as retrograde recanalization from the popliteal artery.³

Owing to a lack of working length distal to the tip of the access sheath, the ipsilateral CFA cannot be used as an access due to ostial lesions of the superficial femoral artery (SFA). The most popular alternate techniques are retrograde contralateral CFA and

trans-brachial CFA. In the presence of iliac artery excess tortuosity, blockage, or stent, the former is problematic.⁴

In the case of SFA ostial lesions, operators who use the antegrade ipsilateral approach usually only implant the last few centimetres of the sheath into the CFA. As a consequence, the sheath is often unstable in this posture. This method of insertion commonly abuts the ostial SFA lesion during insertion. When trying to bridge an Obstruction, the force is conveyed to the partly implanted sheath, which might get dislodged from the artery, resulting in bleeding and access loss.⁵

In this situation, keeping a wire in the profunda femoris artery (PFA) throughout the process and allowing a buddy wire to pick the SFA is one option for maintaining access. If accessibility is mistakenly lost, the sheath may be reinserted over the profunda wire.⁵

For flush SFA ostial occlusions, however, ipsilateral CFA access is difficult. This is due in part to the CFA's short length, which doesn't provide enough "working room" for sheath landing and stability, as well as catheter manipulation. To address this shortcoming, a double-wire approach called the "profunda anchor" was devised to enable ipsilateral antegrade intervention in situations with flush SFA blockage.⁶

Even if there is PFA stenosis, using a steerable microwire at entrance enables for the selection of PFA branches that are ideal for sheath implantation. In addition, if there is substantial PFA disease, endovascular "profundoplasty" might be done at the completion of the operation.⁵

Another procedure reported is inserting 2 to 3 cm of the sheath into the common femoral artery and leaving the rest of the sheath in a fashioned subcutaneous tunnel of the lower most abdomen, securing and shielding the sheath against unintended dislodgement.⁷

Except for the necessity for careful identification of both radiological and anatomical landmarks, the technical demands are similar to those for performing established antegrade punctures. Furthermore, the procedure does not need the use of any extra instruments. Limitations to using the suggested procedure include the PFA's inability to be cannulated and/or the CFA's high bifurcation.⁷

Aim of the work was to assess the feasibility, adequacy, safety, as well as complications of an ipsilateral antegrade procedure in patients with persistent lower limb ischemia who had superficial femoral artery ostial lesions.

PATIENTS AND METHODS

Between August 2019 and August 2021, 30 patients with peripheral arterial occlusive disease were

included in this prospective cohort research at Al-Azhar University Hospitals (Al-Hussain and Bab-Alsheryah) (affecting ostium of the superficial femoral artery).

Inclusion criteria:

The study included patients with critical lower limb ischemia with Computerized Topographic Angiography (CTA) evidence of significant ostial lesion of femoral vessels with or without tibial lesions and presenting with the following: (1) Patient with previous angioplasty of aortic, ipsilateral iliac, contralateral iliac and CFAs lesions. (2) Thin and average built patients. (3) Patients with generally adequate state of cardiac, respiratory and renal conditions that allow the procedure. (4) Clinically, patients have: Disabling claudication or Ischemic rest pain, and tissue loss (as nonhealing foot ulcers or focal gangrene).

Exclusion criteria:

(1) Morbid obesity and pendulous abdomen. (2) A high bifurcation or occlusion of the CFA. (3) Aneurysmal disease and AVF at femoral region. (4) Patients with creatinine > 1.5 mg/dl have a known intolerance to study medicines or contrast agents. (5) Poor general condition (decompensated heart failure, stroke, bed ridden). (6) Clinically, patients have: Inevitable Above knee amputation, acute on top of chronic ischemia, and incapacitating claudication.

All patients were subjected to: Pre-procedural assessment, history and Examination, ankle brachial pressure index measurement, routine laboratory investigations, plain X-ray of the foot (if ulcer or infection was present), duplex scanning, and CTA done to assess the infra-inguinal arterial system and to describe the femoral artery lesion characteristics (stenosis/occlusion), and length.

Equipment:

Duplex Ultrasound and C-arm (angiographic apparatus).

Materials:

Seldinger's needle. A 0.018-inch microwire. 6 or 7 French caliber sheaths & their dilators. Hydrophilic coated Terumo® guidewire 0.035 French "J tipped" of 180 cm length. A 200-cm-long V18 (Boston Scientific, Natick, MA), for distal lesions. For procedure after passing lesion: 4 or 5 French Bernstein catheter. Balloon catheters (5-6 mm in diameter for femoral dilatation) with or without stent, and inflation device. Medications as xylocaine 2%, non-ionic contrast material, heparin, and nitroglycerine (Tridil).

Access Techniques:

Profunda Ancor technique:

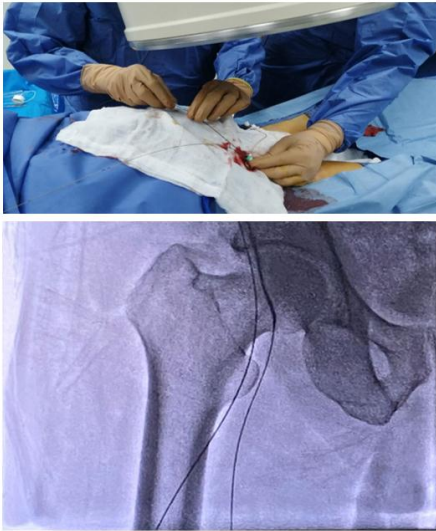

Fig. 1: Double wire technique and engaging the ostial cap.

Tunneled novel technique:

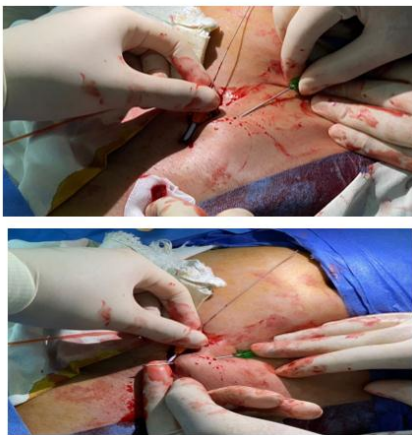


Fig. 2: Tunnel creation after 2nd puncture site.

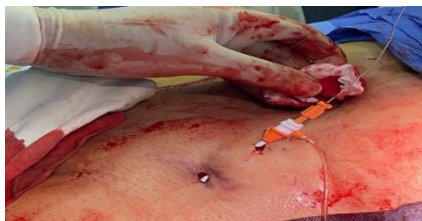

Fig. 3: Sheath stability after tunneling.

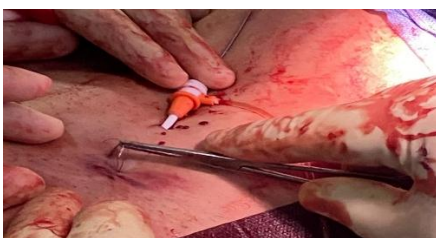


Fig. 4: 1st puncture site suturing.

Procedure out comes:

The procedure was considered to be successful depending on the following:

Technical success; when PFA accessed firstly, then engagement of ostial lesion of SFA.

Post-operative success; no complication occurs as extravasation, hematoma, losing profunda access or pseudo aneurysm.

Clinical success; as improvements should include symptomatic improvement and change of at least one category according to TASC classification.

Operative follow-up:

Intraoperative:

Procedure-related complications occurred in 4 cases. Vessel perforation and extravasation in 1 patient and the perforations occurred at the proximal SFA during the attempt to cross the lesion which treated only by balloon tamponade without surgical intervention, Residual stenosis in another case , Dissection in mid SFA and treated by stenting and puncture site hematoma which resolved spontaneously by compression. However, none of our cases suffered Intraoperative thrombosis, pseudoaneurysm or arteriovenous fistula. And Finally, No life threatening complications or retroperitoneal hematoma occurred in any patient

Post-operative:

At 1, 6 & 12 months"

One patient was lost to follow-up throughout the follow-up period, which lasted from one to twelve months. In addition, two patients died for other reasons at this time. Claudication severity, rest pain, and toe ulcers all enhanced considerably during a 10.5 month \pm 1.5 follow-up period. The pulse of the distal arteries could be felt, as well as the filling of the veins. At one year following intervention, the ankle-brachial index increased from 0.48 ± 0.17 to 0.84 ± 0.11 ($P < .001$), and patency rates were 95 percent, 72 percent, and 41 percent, respectively, at 1, 6, and 12 months.

Minor amputation on occurred in three cases after 6 months and and major amputation occurred in one case.

Restenosis occurred in 5 cases after 1 year duo to neglectation of treatment and remaining of risk factors specially smoking.

Statistical analysis:

SPSS version 28 was used for data administration and statistical analysis (IBM, Armonk, New York, United States). The sole numerical variable was age, which was represented by the average and standard deviations. Numbers and percentages were used to

summarize categorical data. The age of individuals who had technical success was compared using an independent t-test, while categorical data was compared using Fisher's exact test. To calculate the time to occurrence, the Kaplan Meier curve was utilized. To compute the difference between two or more sets of qualitative variables, use the Chi square test (χ^2). P values of less than 0.05 were deemed relevant.

RESULTS

The median age of the studied patients was 56 \pm 8 years. There was a male predominance (70%). Rutherford Category was four in 30%, five in 40%, and six in 30%. About three quarters had hypertension (70%), and most patients had diabetes (86.7%). Smoking was reported in about two-thirds (63.3%). Ischemic heart disease was reported in 43.3%, while dyslipidemia was reported in 53.3% (Table 1).

The most frequent extension of the lesion was SFA CTO total length till the adductor canal (36.7%), followed by proximal 1/3 SFA tight stenosis extending into middle 1/3 of SFA (26.7%), proximal SFA CTO extending into middle 1/3 of SFA (20%), and proximal 1/3 SFA tight stenosis (16.7%). Most patients showed technical success (80%), and most of them (79.2%) had endo-luminal wire passage. The

most frequent type of passage in failure cases was contralateral antegrade (50%), followed by transbrachial antegrade (33.3%) and popliteal ipsilateral retrograde (16.7%) (Table 2).

Most patients showed no complications (86.7%). Only four patients reported dissection in mid-SFA (one patient), puncture site hematoma (one patient), residual stenosis (one patient), and vessel perforation and extravasation (one patient) (Table 3).

All patients showed clinical improvement at one month. At six months, minor and major amputations were reported in three patients and one patient, respectively. Also, one patient lost follow-up, and one patient died. At one year, one patient had restenosis (20.8%), and one died (Table 4).

There was no significant variances were reported between those with and without technical success regarding age (P = 0.796), gender (P = 1.0), rutherford Category (P = 0.616), hypertension (P = 1.0), diabetes (P = 1.0), smoking (P = 1.0), ischemic heart disease (P = 0.672), and dyslipidemia (P = 1.0) (Table 5).

Kaplan Meier curve was done to estimate time to event (any) in the studied patients. At six months, the improvement rate declined to 83.3%, and at one year, it declined to 62.5% (Figure 5).

General characteristics		n (%)
Age (years)	Mean \pm SD	56 \pm 8
Gender	Males	21 (70.0)
	Females	9 (30.0)
Rutherford Category	Four	9 (30.0)
	Five	12 (40.0)
	Six	9 (30.0)
Hypertension		21 (70.0)
Diabetes		26 (86.7)
Smocking		19 (63.3)
Ischemic heart disease		13 (43.3)
Dyslipidemia		16 (53.3)

Table 1: General characteristics of the studied patients.

		n (%)
Extension of lesion	Proximal 1/3 SFA tight stenosis	5 (16.7)
	Proximal 1/3 SFA tight stenosis extending into middle 1/3 of SFA	8 (26.7)
	Proximal SFA CTO extending into middle 1/3 of SFA	6 (20.0)
	SFA CTO total length till the adductor canal	11 (36.7)
Technical success	Not passed	6 (20.0)
	Passed	24 (80.0)
Type of wire passage *	Endo-luminal	19 (79.2)
	Sub-intimal	5 (20.8)
Type of passage in failure cases **	Contralateral antegrade	3 (50.0)
	Popliteal ipsilateral retrograde	1 (16.7)
	Trans brachial antegrade	2 (33.3)

* The proportions are based on a total of 24 patients that had technical success.

** The proportions are based on a total six patients without technical success

Table 2: Extension of the lesion and procedure characteristics in the studied patients.

		n (%)
Complication	Dissection in mid SFA	1 (3.3)
	Puncture site hematoma	1 (3.3)
	Residual stenosis	1 (3.3)
	Vessel perforation and extravasation	1 (3.3)
	No complications	26 (86.7)

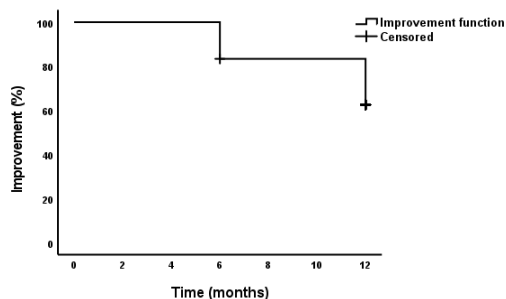
Table 3: Procedure complications in the studied patients.

		n (%)
At one month	Clinically improved	30 (100.0)
	Clinically improved	24 (80.0)
	Major amputation	1 (3.3)
At six months	Minor amputation	3 (10.0)
	Missed follow up	1 (3.3)
	Death	1 (3.3)
At one year *	Clinically improved	18 (75.0)
	Restenosis	5 (20.8)
	Death	1 (4.2)

* Percentages were calculated based on 24 patents

Table 4: Follow up findings in the studied patients.

		Technical success		P-value
		Passed	Not passed	
Age (years)	Mean \pm SD	56 \pm 9	55 \pm 5	0.796
Gender	Males	17 (70.8)	4 (66.7)	1.0
	Females	7 (29.2)	2 (33.3)	
Rutherford Category	Four	8 (33.3)	1 (16.7)	0.616
	Five	10 (41.7)	2 (33.3)	
	Six	6 (25.0)	3 (50.0)	
Hypertension	n (%)	17 (70.8)	4 (66.7)	1.0
Diabetes	n (%)	21 (87.5)	5 (83.3)	1.0
Smocking	n (%)	15 (62.5)	4 (66.7)	1.0
Ischemic heart disease	n (%)	11 (45.8)	2 (33.3)	0.672
Dyslipidemia	n (%)	13 (54.2)	3 (50.0)	1.0

Table 5: Patients' characteristics according to technical success.**Fig 5:** Kaplan Meier curve for time to event (any) in the studied patients.

DISCUSSION

In the present study of 30 patients, 21 of them were males (70%) and 9 females (30%) (p value = 1) and Rutherford category 4 (30%), 5 (40%) and 6 (30%) (p value 0.616) which was in accordance with Ghani et al.⁸ who stated that the males 14 out of 16 patients were more affected than females which represent

only 2 patients. However, in the study of El-Maadawy et al.⁹ they were 17 patients with frequency of gender, 11 were males and 6 were females and Rutherford (3 to 5), from the above mentioned data, males were majority and This might indicate that gender is a considerable risk factor.¹⁰

Most of patients in the present study ranged in age from 44 to 68 years (56 \pm 8 years) with p value (0.796) and this result was in agreement with Ghani et al.⁸ who stated that the median age of patients included in their research was 65.4 years (ranged from 60-71 years). However, in the study of El-Maadawy et al.⁹ the age of patients ranged from 48-85 years with a mean of 63.2 years.

Regarding to risk factors, there was high incidence regarding diabetes mellitus, IHD, hypertension, smoking and dyslipidemia with percentage of 86.7%, 43.3%, 70%, 63.3% and 53.3% respectively, and that result is in accordance to Ghani et al.⁸ who stated that these risk factors have a higher incidence of co-morbidity.

There was strong statistical significant difference regarding risk factors of diabetes mellitus, hypertension, smoking and dyslipidemia with technical success (passed, Not passed) with (p value=1), and with IHD (p value=0.67).

The present study is concerned with evaluate the effectiveness of ipsilateral antegrade management of ostial and near ostial SFA occlusive lesions which represent around 24 cases showed technical success "the guidewire crossed the lesion out of 30 cases where the guidewire couldn't be passed through the lesion in the remaining six cases because of suffering total length complete occlusion of the SFA.

The findings of the current study which was in accordance with El-Maadawy et al.⁹ who stated that Ipsilateral antegrade (tunneled novel) is a safe, simple, and repeatable procedure. Except for the necessity for careful identification of both radiological and anatomical landmarks, the technical demands are similar to those for performing established antegrade punctures.

Another study compatible with our present study Pua⁵ which reveals that The profunda anchor method's ipsilateral antegrade approach is a flexible technique that offers a secure platform for a broad spectrum of SFA intervention, including ipsilateral antegrade SFA ostial balloon angioplasty and stenting.

In research comparing contralateral and ipsilateral techniques in endovascular treatment of high superficial femoral artery lesions, Abd El-Rahman et al.¹¹ found that antegrade puncture is the most frequent way to get access to the common femoral artery for infrainguinal intervention. The antegrade method has the benefit of allowing the use of shorter instruments and providing more support for catheter and guidewire manipulation. It is important to notice that presence of lesion in proximal part of SFA needs suprainguinal puncture of the iliac artery which is better to be avoided as it cannot be effectively compressed.

Because retrograde punctures are commonly utilized to get access for diagnostic angiography, they are technically simpler to conduct and most operators have far more expertise with them. Many vascular physicians prefer the contralateral crossover technique to gain distance from the target lesion and provide a more comfortable working area, as well as to reduce the danger of hemorrhage and the necessity for compression on the ipsilateral groin.

In the study of Ye et al.¹² they explained that an antegrade ipsilateral common femoral artery (CFA) procedure or a retrograde contralateral CFA procedure are generally used for endovascular management of chronic complete blockage of the femoropopliteal artery. Patients with convoluted iliac arteries or an aortobifemoral Y-prosthesis used to repair a prior abdominal aortic aneurysm may find it challenging to manipulate from the contralateral CFA. The ipsilateral antegrade approach provides

better push ability than the contralateral retrograde approach, but there are some situations where ipsilateral CFA access would be difficult or contraindicated, such as obesity, surgical scars in the groin, and lesions involving the CFA and a flush SFA occlusion without proximal stump. But in the last point (flush SFA) in our present study can manage the flush SFA lesion by new techniques (profunda anchor, tunneled novel) which make very good stability of the sheath and prevent its dislodgment.

There was study of Eleissawy et al.⁹ The study compared ipsilateral antegrade angioplasty for flush superficial femoral artery blockage against open bypass surgery and found that the surgical and endovascular groups had 100% and 89.3 percent technical success, respectively. At 12 months, there were no significant differences in the main, aided, and secondary patency rates between the two groups. Limb salvage was 88 percent in the surgical group and 92 percent in the endovascular group. The surgical group had a longer hospital stay and had more local issues than the endovascular group, which was consistent with the findings of the current research and suggested that the endovascular technique was favored over surgical intervention.

In the present study complications occurred in 4 cases (3.3%). Vessel perforation and extravasation in 1 patient and the perforations occurred at the proximal SFA during the attempt to cross the lesion which treated only by balloon tamponade without surgical intervention, Residual stenosis in another case, Dissection in mid SFA and treated by stenting and puncture site hematoma which resolved spontaneously by compression. However, none of our cases suffered Intraoperative thrombosis, pseudoaneurysm or arteriovenous fistula. And Finally, No life threatening complications or retroperitoneal hematoma occurred in any patient. But in study presented by Barrette et al.¹³, Device deployment failure occurred in 7/107 limbs, with hemostasis (without extra manual compression) accomplished in 86/107 (80.4%). (6.5 percent). In 1/107, a femoral pseudoaneurysm appeared, followed by a small hematoma in 3/107. The average time it took to ambulate was 204.1 minutes.

The popliteal retrograde approach at Ye et al.¹² Because of the difficulty to re-enter the real lumen below or at the level of the deep femoral artery's origin, it has a 10% -20% chance of technical failure. However, with the patient prone, the interventionist's techniques from the femoral access are challenging and often lengthen the surgery. Furthermore, patients in the prone position, particularly those who are obese or have poor respiratory function, are more likely to feel tired. Complications related to the puncture site in the traditional retrograde popliteal approach, such as arteriovenous fistulas, hematomas, plaque shift, PA occlusion, and distal embolization, have been concerns that have limited their acceptance, so the ipsilateral antegrade approach's complication is more widely accepted in this study.

CONCLUSION

Endovascular therapy (EVT) in ostial and near ostial SFA occlusive lesions with ipsilateral antegrade access through common femoral artery puncture is a feasible and effective approach. The significant success rate shown in this research supports the efficacy of this method in individuals with ostial SFA lesions and occlusive peripheral artery disease. The ipsilateral antegrade technique has the benefit of allowing the use of smaller instruments and providing more support for catheter and guidewire manipulation. Superior wire's pushability, trackability, and torquability as the entire force applied to the wire and catheter is transmitted to the lesion. It is also the sole safe alternative to the preferred "contralateral crossover technique" to the severely convoluted iliac arteries, hostile aortic bifurcations, and abdominal aortic stent grafts. Elderly patients, who are unfit for surgery may greatly benefit from this less invasive therapy.

Conflict of interest : none

REFERENCES

1. Li C, Kitzerow O, Nie F, et al. Bioengineering strategies for the treatment of peripheral arterial disease. *Bioact Mater.* 2021; 6(3): 684-96.
2. Wager J, Gandhi R and Powell A. Erratum to Technical Approach to Antegrade Femoral Access. *Techniques in Vascular and Interventional Radiology.* 2015; 18 (2): 82-6.
3. Shi W, Yao Y, Wang W, et al. Combined antegrade femoral artery and retrograde popliteal artery recanalization for chronic occlusions of the superficial femoral artery. *Techniques in Vascular and Interventional Radiology.* 2014; 25(9): 1363-8.
4. Bosiers M and Deloose K. Femoral bifurcation disease: balloon or knife. *Catheterization and Cardiovascular Interventions.* 2009; 74(4): 627-33.
5. Pua U. Profunda anchor technique for ipsilateral antegrade approach in endovascular treatment of superficial femoral artery ostial occlusion. *Cardiovasc Intervent Radiol.* 2015;38(2):453–6.
6. Hayes DJ, Dougherty MJ and Calligaro KD. Management of flush superficial femoral artery occlusions with combined open femoral endarterectomy and endovascular femoral–popliteal angioplasty and stent-grafting. *Ann Vasc Surg.* 2011; 25(4): 519-23.
7. El-Maadawy MI, Balboula AM and Zaghoul HJ. Tunneled ipsilateral sheath: a novel technique in endovascular management of superficial femoral artery ostial lesions. *Vasc Endovascular Surg.* 2019; 53(4): 337-40.
8. Ghani AA, El Samadoni AA, Afifi HS, et al. Ipsilateral antegrade access for management of ostial and near ostial SFA. *Benha Journal of Applied Sciences.* 2019; 4:1-5.
9. Eleissawy MI, Elbarbary AH, Elwagih MM, et al. Ipsilateral antegrade angioplasty for flush superficial femoral artery occlusion versus open bypass surgery. *Annals of Vascular Surgery.* 2019; 61: 55-64.
10. Hossny AM, Eldesouky MS and Abdellatif MA. Angiosome based revascularization for diabetic foot ulcer. *Int Surg J.* 2019; 6(10): 3474-9.
11. Abd El-Rahman MA, Abd El-Fattah HA, Ghanem MM, et al. Comparative study between contralateral and ipsilateral approaches in endovascular treatment of high superficial femoral artery lesions. *J The Egyptian Journal of Hospital Medicine.* 2019; 76(1): 3366-72.
12. Ye M, Zhang H, Huang X, et al. Retrograde popliteal approach for challenging occlusions of the femoral-popliteal arteries. *Journal of Vascular Surgery.* 2013; 58(1): 84-9.
13. Barrette LX, Vance AZ, Mantell MP, et al. Safety and efficacy of arterial closure devices following antegrade femoral access: A case–control study. *Vascular and Endovascular Surgery.* 2020; 54(7): 612-7.