

Predictors of Endoscopy Success in Treatment of Pediatric Idiopathic Obstructive Hydrocephalus

Mohamed M. Elmaghrabi*¹, Ahmed A. Arab¹, Tamer A. Samih², Mona A. Elawady³, Mahmoud M. Wahdan¹

Departments of ¹Neurosurgery, ²Radiology, ³Public Health, Faculty of Medicine, Benha University, Benha, Egypt

*Corresponding author: Mohamed M. Elmaghrabi, Mobile: (+20)1222751406, Email: dr_elmaghrabi@yahoo.com

ABSTRACT

Background: Hydrocephalus is defined as an inappropriate increased pressure of cerebrospinal fluid (CSF) within the intracranial spaces with an inappropriate amount of CSF. Endoscopic third ventriculostomy (ETV) is considered an effective procedure that is safe.

Purpose: The aim of the current work was to detect the factors those predict success parameters in selecting patients with idiopathic obstructive hydrocephalus as candidates for the ETV procedure at a pediatric age.

Patients and methods: A clinical prospective cohort study was conducted at Benha University Hospitals from September 2018 to July 2021. A total of 61 patients with inclusion criteria of idiopathic (congenital) obstructive hydrocephalus of pediatric age (under 18 years old) with and without previous ventriculoperitoneal (VP) shunt insertion were included according to calculated sample size who undergoing ETV with a follow-up period of 6-12 months. All patients were evaluated by pre and post-operative operative MRI CSF flowmetry.

Results: Sixty-one patients were operated on, with age ranged from 3 to 120 months, and the median (IQR) was 13.0 (5.5-24). Previous VP shunting was done in 15 patients (24.6%). According to the receiving operator characteristic (ROC) curve, the cut off point for ETV success age was 11.5 months; while the cut off point for ETV success score (ETVSS) was 70. MRI CSF flowmetry detected and measured the size of the ventriculostomy stoma and evaluated the flow direction and stroke volume.

Conclusions: It could be concluded that endoscopy has reliable validity and safety in the treatment of idiopathic obstructive hydrocephalus. ETV success predictors are patients' age above 11.5 months and ETVSS ≥ 70 , led to increase validity of endoscopy. MRI CSF flowmetry is safe and accurate method for evaluation of the ventriculostomy stoma.

Keywords: Predictors, Endoscopy, Hydrocephalus, Pediatric.

INTRODUCTION

Hydrocephalus is defined as an inappropriate increased pressure of cerebrospinal fluid (CSF) within the intracranial spaces with an inappropriate amount of CSF. So it included a variety of childhood and adult syndromes of abnormal CSF flow, production, or absorption patterns with the sequelae of their management. The main cause of congenital hydrocephalus is obstruction resulting from local narrowing of the CSF pathway due to idiopathic aqueduct stenosis⁽¹⁾.

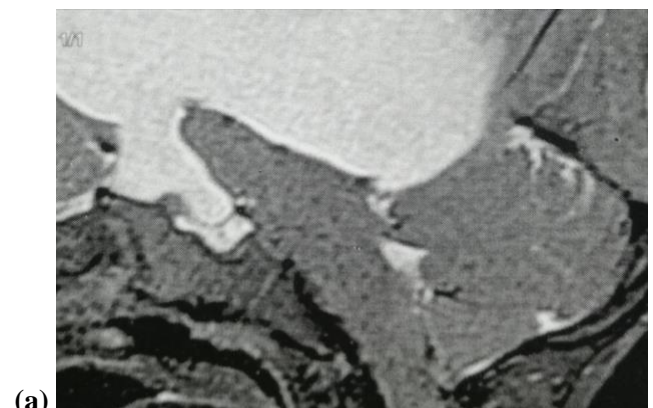Endoscopy is considered a good alternative for shunt dependence; an opening is created in the floor of the third ventricle (endoscopic third ventriculostomy; ETV) using an endoscope placed within the ventricular system through a burr hole. So, allowing the movement of CSF across the blocked ventricular pathway into the interpeduncular cistern (a normal CSF space) results in bypassing the obstruction. The aim of ETV is to normalize the intracranial pressure and its compression on the brain matter without using a shunt⁽²⁾.

ETV is considered as a safe effective procedure. The pre-operative ETV success score may be useful for predicting post-operative outcomes⁽¹⁾.

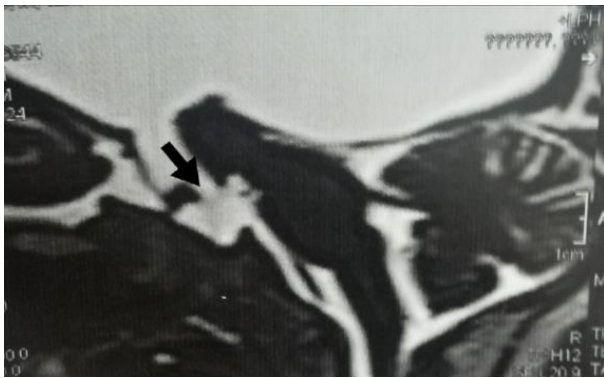This study was aimed to identify the factors predicting the success parameters in selecting patients with idiopathic obstructive hydrocephalus as candidates for the ETV procedure at pediatric age.

This clinical prospective cohort study included a total of 61 patients with inclusion criteria of idiopathic obstructive hydrocephalus, treated at Benha University Hospitals. This study was conducted between September 2018 to July 2021.

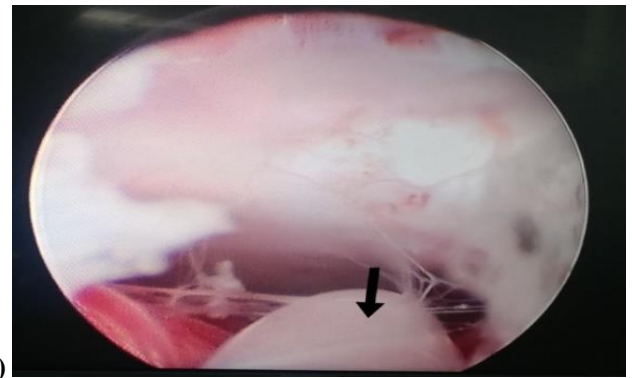
Figure 1 shows patients with inclusion criteria of idiopathic obstructive hydrocephalus, aqueduct stenosis, and pediatric age (under 18 years old) with and without previous ventriculoperitoneal (VP) shunt insertion were included. Sample size was calculated according to data obtained using the Epi Info program Version 3, open-source calculator, SS Cohort⁽⁴⁾.



PATIENTS AND METHODS



(b)
Figure (1): T2 weighted magnetic resonance images, sagittal cut, show supratentorial hydrocephalus due to aqueduct stenosis: (a) apparent no CSF flow in basal cisterns, (b) adequate opening of 3rd ventricular floor (black arrow) with CSF flow in basal cisterns.



(c)
Figure (2): Intraoperative ETV: (a) fenestration of floor of third ventricle by fogarty catheter, (b) widening of fenestrum by fogarty balloon inflation, (c) free connection to prepontine cistern (black arrow: basilar artery).

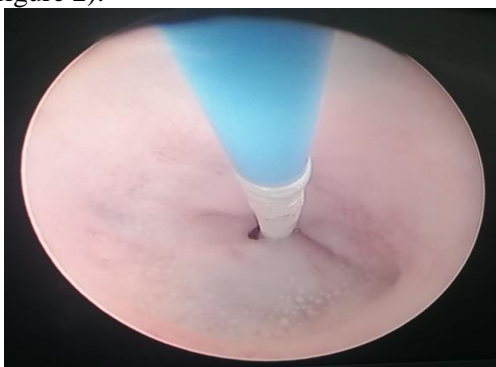
Exclusion criteria, including patients with communicating hydrocephalus and obstructive hydrocephalus of post-infectious, hemorrhagic or tumor nature, and the presence of CSF loculations, were excluded.

All hydrocephalic cases underwent a comprehensive general and neurosurgical history and examination, as well as radiological diagnosis via computerized tomography (CT) scan and magnetic resonance imaging (MRI) brain with CSF flowmetry. A Lotta rigid endoscope (ventriculoscope 6° of working channel, 2.9 mm with obturator and operating sheath 6.8 mm; Karl Storz, Tuttlingen, Germany) was used for performing ETV with an opening through lilliequist's membrane and assuring free connection and CSF flow to the prepontine cistern (figure 2).

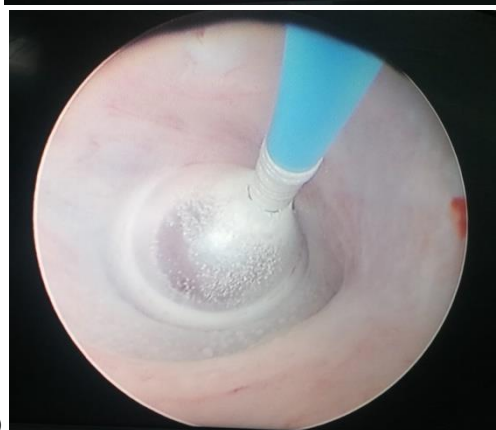Follow up: All patients were postoperatively evaluated with clinical examination and radiological imaging with a follow-up period of 6–12 months. The outcome of ETV was evaluated clinically and radiologically at the time of discharge and on subsequent follow-up visits (2 weeks, 1 month, and every 3 months). The surgical result was recorded as a failed or succeed group. Succeed group had partial or complete relief of symptoms without the need for a subsequent VP shunt surgical procedure, while the failed group had no improvement with subsequent VP shunt revision (if already shunted) or new shunt application.

ETV Success Score (ETVSS), decision making and success score: It is considered a validated mean for predicting the likelihood of success of ETV and therefore may assist in the selection of appropriate patients for this procedure. The total of the 3 parameters (age, aetiology, and previous shunt) as shown in table 1, expressed as a percentage probability of ETV success (summed to get a score out of 100), as it is the approximate chance of an ETV success lasting 6 months without failure. Scores of 40% are correlated with a very low chance of success. Scores of > 80% are correlated with a better chance of success than scores of 50-70%⁽⁵⁾.

Table (1): Calculation of the ETVSS; The ETVSS is calculated as Age Score + Etiology Score + Previous shunting⁽⁶⁾.



(a)



(b)

Score	Age	Aetiology	Previous shunt
0	1 month<	Post-infectious	Yes
10	1 month to <6 months		NO
20		Intraventricular hemorrhage Myelomeningocele Non-tectal brain tumors	
30	6 months to <1 year	Aqueduct stenosis Tectal tumors Others	
40	1 year to <10 years		
50	≥10 years		

MRI CSF flowmetry done using sagittal 3D heavy T2 sequences including 3D-CISS (constructive interference in steady-state), SPACE (sampling perfection with application-optimized contrasts using different flip angle evolution) with constant angle and SPACE with variable angle, 3D heavily T2W sequences have been accepted to provide morphologic data regarding CSF pathways, It allows good visualization of the cerebral aqueduct and demonstrates the underlying cause of the obstructive pathology also all ventricles assessment including third ventricle floor. For phase-contrast MR imaging, two imaging techniques were applied: Axial for quantification of CSF flow at aqueduct and Sagittal for qualitative analysis and quantification of the ventriculostomy.

Ethical approval:

This study was ethically approved by Benha University's Research Ethics Committee (REC). All procedures performed in studies involving human participants were under the ethical standards of the institutional and/or national research committee and with the 1964 Helsinki declaration and its later amendments or comparable ethical standards. Written informed consent was obtained from each parent of the participants after explaining all steps of this study.

Statistical analysis

The data was analyzed by SPSS version 26. Frequency and percentage was calculated for categorical variables and analyzed using chi square and Fischer exact test. Mean ± SD and median (IQR) were calculated for quantitative data. Receiving operator characteristic (ROC) curve was used to detect validity of age and ETVSS. Statistical significance was accepted at P value ≤0.05 with <0.01 was highly significant while a P value >0.05 was considered insignificant.

RESULTS

Sixty one patients were operated on during this study period, with an age range of 3 to 120 months. The median (IQR) was 13.0 (5.5-24) with a sex distribution of 34 males (55.7%) and 27 females (44.3%) as in table 2. Previous VP shunting was done in 15 patients (24.6%). Vomiting was the most common presentation in 40 patients (65.6%). Head circumference had a mean of 47.97 cm with a SD of 5.16. ETV surgery outcome: 25 patients (41%) were in the failed group with a subsequent surgical procedure, while 36 patients (59%) were in the succeed group (table 2).

Table (2): Descriptive data of the studied group

	No (61)	%
Sex		
Male	34	55.7
Female	27	44.3
Age / month		
Mean ±SD (range)	23.61±26.68 (3-120)	
Median (IQR)	13.0 (5.5-24.0)	
Previous VP shunt		
Yes	15	24.6
No	46	75.4
Vomiting pre-op		
Yes	40	65.6
No	21	34.4
Fits pre-op		
Yes	19	31.1
No	42	68.9
Cranial nerve affection		
Present	23	37.7
Absent	38	62.3
Head circumference		
Mean ±SD (range)	47.97±5.16 (39-57)	
Fontanel		
Open	22	36.1
Closed	39	63.9
Delayed milestones		
Present	28	45.9
Absent	33	54.1
Surgery after ETV		
Yes (failed)	25	41.0
No (succeed)	36	59.0

Table 3 shows that the complications reported after ETV surgery were CSF leak in 21 patients (34.4%) in both groups, with 15 of them in 25 patients of the failed group (60%) while in 6/36 of succeed group (16.7%), which was statistically highly significant.

Intraventricular hemorrhage occurred in 7 patients (11.4%) and infection in 8 patients (13.1%), which was statistically insignificant. Death was reported only in 6 patients (9.8%) in the failed group, with no mortality in the successful group, which was statistically highly significant.

Table (3): Relation between post-operative ETV complications and ETV outcome

ETV complications	Failed (25)		Succeed (36)		Test	P value
	No	%	No	%		
CSF leak						
Yes	15	60.0	6	16.7	X2=	<0.001**
No	10	40.0	30	83.3	12.27	
Convulsions						
Yes	5	20.0	10	27.8	X2=	0.488
No	20	80.0	26	72.2	0.48	
Haemorrhage						
Yes	3	12.0	4	11.1	FET=	1.0
No	22	88.0	32	88.9	0.0	
Infection						
Yes	4	16.0	4	11.1	FET=	0.71
No	21	84.0	32	88.9	0.03	
Mortality						
Yes	6	24.0	0	0.0	FET=	0.003**
No	19	76.0	36	100	7.07	

** Highly significant

Table (4) shows that ETVSS $\leq 40\%$ was 0.0% with 50–70 in 26 patients (72.2%) and $\geq 80\%$ in 10 patients (27.8%) of succeed group while no patients in the failed group $\geq 80\%$ which was statistically highly significant.

Table (4): Relation between ETVSS values and ETV outcome

ETVSS	Failed (25)		Succeed (36)		Statistical test	P value
	No	%	No	%		
$\leq 40\%$	3	12.0	0	0.0	FET= 12.15	0.001**
50-70%	22	88.0	26	72.2		
$\geq 80\%$	0	0.0	10	27.8		

** Highly significant

The ROC curve (figure 3) shows that the cut off point for age for the success of ETV was found to be 11.5 months with sensitivity of 92%, specificity of 97% and an area under the curve (AUC) of 0.949, while the cut-off point of the ROC curve for ETVSS was 70% with sensitivity of 88%, specificity of 72% and an AUC of 0.962 (Figure 3).

DISCUSSION

Endoscopy is currently well applied in neurosurgery, either alone or with other procedures. ETV is an effective treatment option for obstructive

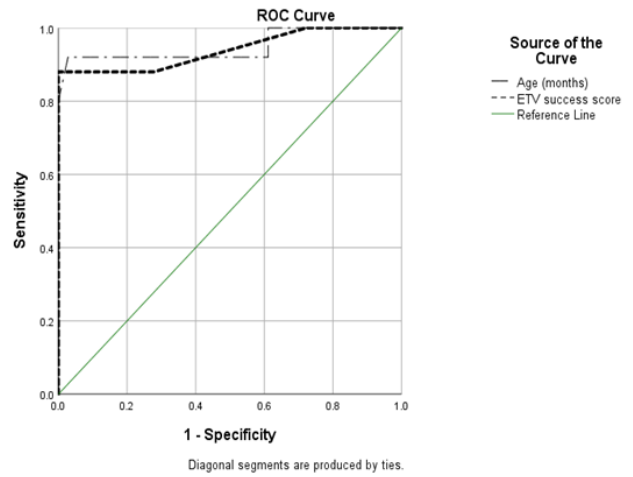


Figure (3): ROC curve for age and ETV success score

Pre-operative CSF flowmetry showed complete aqueduct obstruction in 49 patients (80.3%) and partial obstruction with hyperdynamic CSF flow across the aqueduct in 12 patients (19.7%). Post-operative MR CSF flowmetry showed third ventriculostomy stoma with well-defined cranio-caudal CSF flow in 35 patients of succeed group (97.2%) while 18 patients of failed group (72.0%) with no or turbulent flow which was statistically highly significant (table 5).

Table (5): Pre and post-operative MR CSF flowmetry

	Failed (25)		Succeed (36)		Test	P – value
	No	%	No	%		
Pre-operative finding:						
-Complete aqueduct obstruction	17	68.0	32	88.9	FET= 2.86	0.09
-Partial aqueduct obstruction	8	32.0	4	11.1		
Post-operative finding:						
-Well defined stoma flow	7	28.0	35	97.2	X2= 32.97	<0.001**
-No or turbulent stoma flow	18	72.0	1	2.8		

** Highly significant

The stomas were at the anterior third ventricle floor (best depicted in T2 SPACE with variable angle and sagittal phase contrast sequences) with defect diameter ranges from 5 to 16 mm (average 8mm). Measuring the stroke volume (in well-defined flow) at the ventriculostomy stoma was hyperdynamic flow at least 135 microliter/cycle and maximum 278 microliter/cycle (average 165 microliter/cycle). hydrocephalus and may also be useful in other circumstances, such as VP shunt failure management (6-7).

Our study was carried out on 61 patients. The age of the study group was a constant criterion for selection, as all had an age less than 18 years old, with a success rate of 59%. The relationship between age and success was found to be statistically highly significant, with a cut-off point for success found to be 11.5 months.

This indicates that age is considered an important prognostic factor in the outcome of ETV patients and this agreed with the results of **Fani et al.** ⁽⁸⁾ who believed that age is an important factor in determining success and that it is also the most important independent risk factor for effectiveness of surgery and functional long-term outcome.

However, **Lipina et al.** ⁽⁹⁾ reported that the hydrocephalus etiology and pathophysiology are more important for ETV outcome than the child's age. Also, a good selection of the indicated child and optimal technical performance of the surgical procedure are crucial for a higher ETV success outcome. The age in this study seems to be unimportant.

In our study, the success rate in patients was 59%. These results are accepted by most studies in the literature ⁽⁹⁻¹⁰⁾. However many authors found the results much higher than that of about 70-90% success rate ^(11, 12). **Zohdi et al.** ⁽¹³⁾ found the success rate was less than 40%, especially in the younger age groups, with only <12.5% in the first 6 months.

Like other surgical procedures, ETV could have various degrees of complications. In our study, the overall complications occurred as follows: post-operative CSF leak was present in 34.5% of all patients (16.7% of succeed group and in 60% of the failed group), 11.4% had hemorrhage, and 13.1% had infection. Mortality occurred in 6 cases (9.8%) of all 61 cases (all in the failed group only).

The complications rate between different studies may vary due to the difference in the number of cases included in these studies; our study was done on 61 patients, but the study of **O'brien et al.** ⁽¹¹⁾ was done on 32 cases. Other than that study was done on patient numbers ranging from 155 to 450 patients ⁽¹²⁾. Nevertheless, there can also be delayed fatalities due to acute hydrocephalus or secondary infection after ventriculostomy closure ⁽¹⁴⁾.

Endoscopy indications have remained consistent, including patients with infection ⁽¹⁵⁾, neural tube defects⁽¹⁶⁾, and other forms of hydrocephalus⁽¹⁷⁾. These patients were conventionally believed to have had a higher risk of ETV failure.

In our study, the success rate was 59.02% of all studied group (36 of 61 patients). These results are accepted by most studies in the literature ⁽¹⁸⁻¹⁹⁾. However, many authors found the results much higher than that of about 70-90% success rate ⁽²⁰⁻²¹⁾. In our study, when the ETV success score is higher, the success rate increases, especially after the success score cut off point of 70% or more. This was agreed to by the results

of **Labidi et al.** ⁽¹⁰⁾, who showed that success above ETVSS of 70% is associated with a higher percentage of success in their study. Scores 40% correlated with a very low chance of success, while scores > 80% correlated with a better chance of success compared to VP shunting from the outset. In intermediate scores (50–70%), ETV had a higher initial failure rate compared to VP shunting, but after 3-6 months, the balance shifted in favour of ETV⁽⁵⁾.

With long-term follow-up data on high-risk patients and prognostic factors, ideal patient selection criteria will be further identified ⁽¹²⁾.

So we search for predictors to increase the validity of endoscopy in idiopathic obstructive hydrocephalus as a safe, effective and successive tool of management instead of the long-term hazards of VP shunts.

MRI has been accepted as a powerful imaging modality for the assessment of CSF pathways ⁽²²⁾. A combination of T2-weighted sequences with thin slice-thickness, three-dimensional heavily T2W sequences [3D -SPACE]), and phase-contrast cine MRI (PC-MRI) have gained wide acceptance by the authors for the evaluation of CSF imaging ⁽²³⁾.

The patients of hydrocephalus could be examined by CT or conventional MR determining the level and cause yet the CSF drive (heavy T2) added high resolution image for differentiation CSF from surrounding tissue⁽²⁴⁾, detecting any obstructing agent even thin septations or web, cine phase quantitative and qualitative assessment helped the understand of flow dynamic, evaluating the flow across the aqueduct and foramen magnum helping choice of surgical or conservative treatment, it also helped the assessment of spontaneous ventriculostomy and evaluation post-operative cases⁽²⁵⁾.

CONCLUSIONS

It could be concluded that endoscopy has reliable validity and safety in the treatment of idiopathic obstructive hydrocephalus. ETV success predictors are patients' age above 11.5 months and ETVSS ≥ 70 , indicating increasing validity of endoscopy. It is a safe and accurate method for mostly post-operative evaluation of the stoma and can be considered as the imaging modality of choice.

Funding: This research did not receive any specific grant from funding agencies in the public, commercial, or not-for-profit sectors.

Consent for publication: Available, it was obtained from their parents.

Competing interests: The authors declare that they have no conflict of interest.

REFERENCES

1. **Kahle K, Kulkarni A, Limbrick D et al. (2016):** Hydrocephalus in children. *Lancet*, 387:788-99.

2. **Tubbs R, Hattab E, Loukas M et al. (2012):** Histological analysis of the third ventricle floor in hydrocephalic and non-hydrocephalic brains: application to neuroendocrine complications following third ventriculostomy procedures. *J Neurosurg Pediatr.*, 9:178-81.
3. **Ali M, Usman M, Khan Z et al. (2013):** Endoscopic third ventriculostomy for obstructive hydrocephalus. *J Coll Physicians Surg Pak.*, 23(5):338-41.
4. **Kelsey J, Whittemore A, Evans A et al. (1996):** Methods in observational epidemiology, 2nd edition, Pp. 12-15.
https://onsearch.nihlibrary.ors.nih.gov/discovery/fulldisplay/alma991000214619704686/01NIH_INST:NIH
5. **Kulkarni A, Drake J, Mallucci C et al. (2009):** Endoscopic third ventriculostomy in the treatment of childhood hydrocephalus. *J Pediatr.*, 155:254-9.
6. **Raouf A, Zidan I, Mohamed E (2015):** Endoscopic third ventriculostomy for post-inflammatory hydrocephalus in pediatric patients: is it worth a try? *Neurosurgical Review*, 38:149-55.
7. **Tamburrini G, Pettorini B, Massimi L et al. (2008):** Endoscopic third ventriculostomy: the best option in the treatment of persistent hydrocephalus after posterior cranial fossa tumour removal? *Child's Nervous System*, 24:1405.
8. **Fani L, Jong D, Dammers R et al. (2013):** Endoscopic third ventriculocisternostomy in hydrocephalic children under 2 years of age: appropriate or not? A single-center retrospective cohort study. *Child's Nervous System*, 29:419-23.
9. **Lipina R, Reguli S, Dolezilova V et al. (2008):** Endoscopic third ventriculostomy for obstructive hydrocephalus in children younger than 6 months of age: is it a first-choice method? *Child's Nervous System*, 24:1021-7.
10. **Labidi M, Lavoie P, Lapointe G et al. (2015):** Predicting success of endoscopic third ventriculostomy: validation of the ETV Success Score in a mixed population of adult and pediatric patients. *J Neurosurg.*, 123: 1447-55.
11. **O'brien D, Javadpour M, Collins D et al. (2005):** Endoscopic third ventriculostomy: an outcome analysis of primary cases and procedures performed after ventriculoperitoneal shunt malfunction. *Journal of Neurosurgery: Pediatrics*, 103:393-400.
12. **Paidakakos N, Borgarello S, Naddeo M (2012):** Indications for endoscopic third ventriculostomy in normal pressure hydrocephalus. *Acta Neurochir.*, 113:123-7.
13. **Zohdi A, Eldamaty A, Aly K et al. (2013):** Success rate of endoscopic third ventriculostomy in infants below six months of age with congenital obstructive hydrocephalus (a preliminary study of eight cases). *Asian J Neurosurg.*, 8(3):147-52.
14. **Kim S, Wang K, Cho B (2000):** Surgical outcome of pediatric hydrocephalus treated by endoscopic III ventriculostomy: prognostic factors and interpretation of postoperative neuroimaging. *Child's Nervous System*, 16:161-8.
15. **Bouras T, Sgouros S (2011):** Complications of endoscopic third ventriculostomy. *J Neurosurg Pediatr.*, 7(6):643-9.
16. **Shimizu T, Luciano M, Fukuhara T (2012):** Role of endoscopic third ventriculostomy at infected cerebrospinal fluid shunt removal. *Journal of Neurosurgery: Pediatrics*, 9:320-6.
17. **Warf B, Stagno V, Mugamba J (2011):** Encephalocele in Uganda: ethnic distinctions in lesion location, endoscopic management of hydrocephalus, and survival in 110 consecutive children. *Journal of Neurosurgery: Pediatrics*, 7: 88-93.
18. **Drake J, Canadian Pediatric Neurosurgery Study Group (2007):** Endoscopic third ventriculostomy in pediatric patients: the Canadian experience. *Neurosurgery*, 60(5):881-86.
19. **Sacko O, Boetto S, Lauwers-Cances V et al. (2010):** Endoscopic third ventriculostomy: outcome analysis in 368 procedures. *Journal of Neurosurgery: Pediatrics*, 5:68-74.
20. **Gangemi M, Mascari C, Maiuri F et al. (2007):** Long-term outcome of endoscopic third ventriculostomy in obstructive hydrocephalus. *Minim Invasive Neurosurg.*, 50(5):265-9.
21. **Yadav Y, Jaiswal S, Adam N et al. (2006):** Endoscopic third ventriculostomy in infants. *Neurol India*, 54(2):161-3.
22. **Dallery F, Makki M, Capel C et al. (2017):** A phase – contrast MRI study to investigate the interaction of the CSF dynamics with the intracranial CSF distribution. *JSM Neurosurg spine*, 5(1):1-9.
23. **Ucar M, Tokgoz N, Damar C et al. (2015):** Diagnostic performance of heavily T2-weighted techniques in obstructive hydrocephalus: comparison study of two different 3D heavily T2-weighted and conventional T2-weighted sequences. *JPN Radiol.*, 33(2): 94-101.
24. **Dinçer A, Yildiz E, Kohan S et al. (2011):** Analysis of endoscopic third ventriculostomy patency by MRI: value of different pulse sequences, the sequence parameters, and the imaging planes for investigation of flow void. *Childs Nerv Syst.*, 27:127–35.
25. **Algin O, Turkbey B, Ozmen E et al. (2013):** Evaluation of spontaneous third ventriculostomy by three-dimensional sampling perfection with application-optimized contrasts using different flip-angle evolutions (3D-SPACE) sequence by 3T MR imaging: preliminary results with variant flip-angle mode. *J Neuroradiol.*, 40: 11–18.