

Pyogenic granuloma of tongue in a 10-year-old child – A case report

Mahdy Mohammed Nassar¹, Osama Fathy Besar²

Case Report

Department of Otolaryngology, ¹Helwan University Hospital, Cairo, ²Shebeen Teaching Hospital, Cairo, Egypt.

ABSTRACT

Background: Pyogenic granuloma is a kind of inflammatory hyperplasia in response to chronic irritation. Pyogenic granuloma is a misnomer since neither it is due to bacterial infection nor does it produce any pus. Also, histopathologically there is no granuloma formation. In general, pyogenic granuloma is treated by surgical excision.

Here, we describe a case of pyogenic granuloma of the tongue, include a related literature regarding possible causes, sites, differential diagnosis, biopsy findings and its treatment.

Case presentation: A 10-year-old child developed swelling at the lateral side of the tongue one month after dental procedure. By examination, it was soft with a smooth surface. The mass was excised using coblation system without recurrence till six months.

Conclusions: Dental procedure may induce trauma to the tongue and act as an initiating factor for formation of pyogenic granuloma. Histopathological examination is a corner stone for the definitive diagnosis. Lesion Excision is the main treatment.

Key Words: Case report, pyogenic granuloma, tongue.

Received: 18 December 2021, **Accepted:** 28 July 2022

Corresponding Author: Mahdy Mohammed Nassar, MD, Department of Otolaryngology, Helwan University Hospital, Cairo, Egypt. **Tel.:** 00201004583129, **E-mail:** madynasr@yahoo.com

ISSN: 2090-0740, 2022

BACKGROUND

Soft tissue enlargements of the oral cavity often present a diagnostic dilemma because a wide group of pathologic processes can produce such lesions.

Pyogenic granuloma is a tumor- like growth of the oral cavity or skin that is considered to be non - neoplastic in nature. It is the most common type of hyperplasia in the mouth; histologically, Pyogenic granuloma shows proliferation of granulation tissue with inflammatory infiltration and great angiogenic capacity^[1].

Etiology still remains unclear for this type of lesion. It is supposed to be a response to various stimuli such as chronic localized irritation, trauma, hormones, and drugs. Its incidence in the oral cavity is not uncommon, and poor oral hygiene is considered to be the precipitating factor. The high incidence of this lesion during pregnancy is due to high levels of estrogen and progesterone. Oral pyogenic granuloma usually affects gingiva but can affect other sites like lips, tongue, buccal mucosa and palate.

Oral pyogenic granuloma is usually presented as a slow growing nodular mass which ranges from a few millimeters

to centimeters in size and is usually slowly growing and asymptomatic^[2]. The mass can be ulcerated and bleeding may occur.

CASE PRESENTATION:

A 10-year-old child came with his mother to our clinic with a history of a slowly growing mass on the right side of his tongue for 5 months duration. The mother gave history of dental filling in the same side of the swelling 6 months back. There were no constitutional symptoms such as fever, loss of appetite or

Upon physical examination, there was no cervical lymphadenopathy. Oral examination revealed 2 × 2 cm polypoidal mass whitish pink in color on the right lateral border of the posterior 1/3rd of the tongue (Fig. 1-A). It was soft with a smooth surface, non-tender and did not bleed on touch.

After routine laboratory investigations, excision biopsy was done under general anesthesia. Coblation wand is used for hemostasis. The patient recovered well postoperatively

and was discharged on the same day of the operation.

The histopathological report confirms pyogenic granuloma. The sections revealed lobulated angiomatous tissue with dense chronic inflammatory infiltration lined by stratified squamous epithelium showing hyperplasia (Fig. 2).

The patient followed in two visits after the resection: two weeks then after 6 months and no recurrence was observed (Fig. 1-B).

Trauma to the tongue may be the initiating factor in this case, as the patient developed the mass after dental procedure.

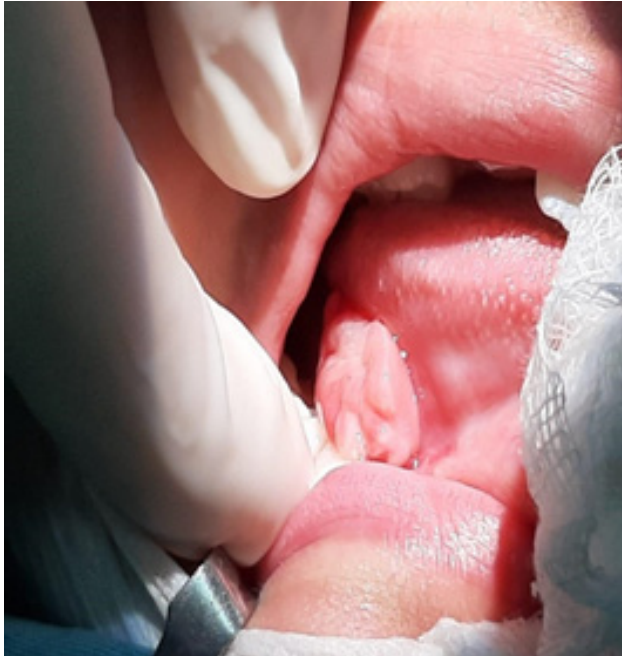

Fig. 1-A: Preoperative view of the mass.

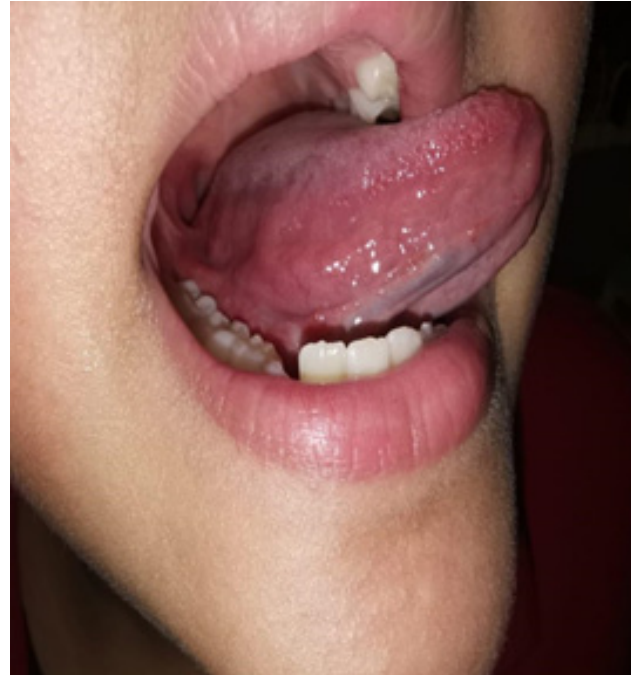

Fig.1-B: Outcome six months postoperatively.

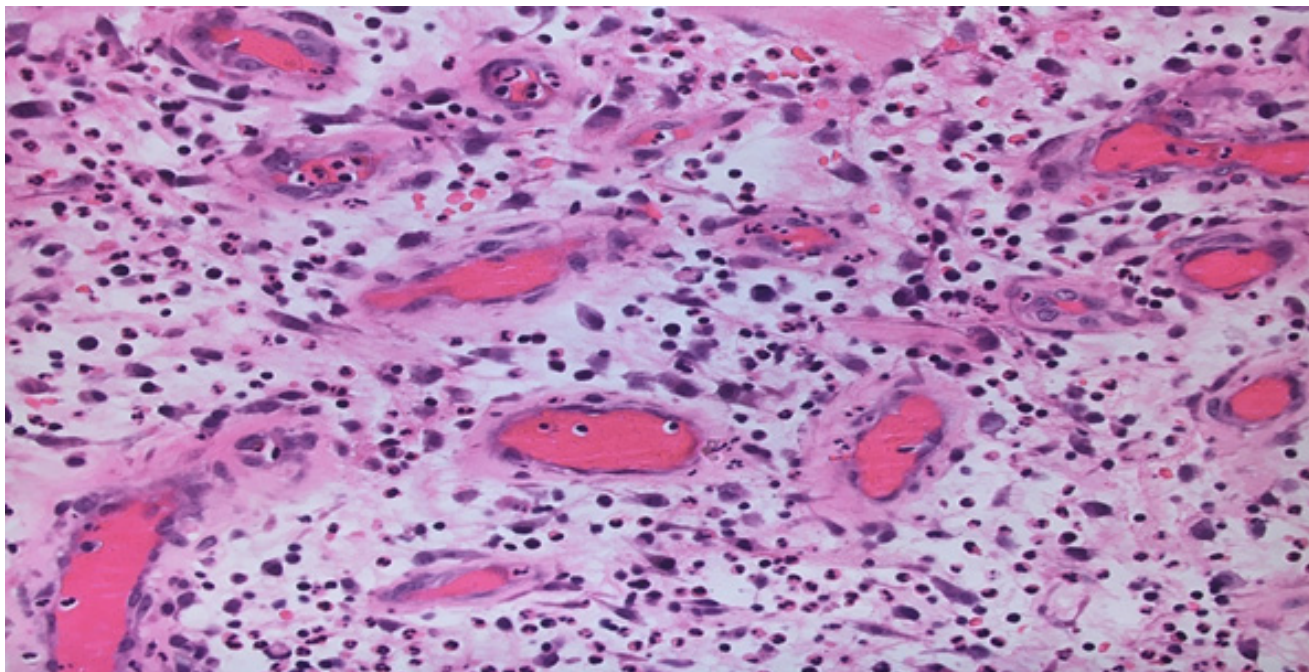


Fig. 2: Microscopic view showing lobulated angiomatous tissue with dense chronic inflammatory infiltrate lined by stratified squamous epithelium showing hyperplasia

DISCUSSION

Pyogenic granuloma is an inflammatory hyperplasia formed as a result of an exaggerated reaction of connective tissue to some localized minor lesion or any underlying irritation. Irritation factors can be dental calculi, poor oral hygiene and unspecified infection^[1,3].

Pyogenic granuloma can be found anywhere in the oral cavity, including the lining of the lips, cheeks, palate and tongue^[1,3].

The pathogenesis of the pyogenic granuloma remains unexplained. Commonly, trauma is often considered as the initiating factor. Approximately 25% of pyogenic granuloma, especially the gingival, are occur after trauma^[4].

In addition, female hormones increase the production of angiogenic factors, such as the basic fibroblast growth factor and the vascular endothelial growth factor which leads to the appearance of pyogenic granuloma^[5]. literature review of pyogenic granuloma of the tongue including the case reports illustrated in (Table1)^[6,7,8,9,10,11,12,13].

Table 1 :-Pyogenic granuloma of the tongue -review of literature.

Serial Number	Author	YEAR	AGE	SEX
6	Beata Zielnik Jurkiewicz	2005	8weeks	male
7	M Abdallah-Lotf <i>et al</i>	2005	2.5years	male
8	Salvador Arias-Santiago <i>et al</i>	2011	34years	female
9	Marcos Ximenes <i>et al</i>	2013	4yaers	male
10	Sonam Sharma <i>et al</i>	2014	64 years	male
11	Vinson Louis Gonzaga Fernandes <i>et al</i>	2018	24 years	male
12	Scott M Peters <i>et al</i>	2018	5 years	female
13	Elisângela Santos Dias <i>et al</i>	2020	20 years	male

Clinically, it is a small, deep red to purple lesion which can be sessile or pedunculated. The surface may be smooth, lobulated, ulcerated and can bleed spontaneously or upon slight trauma. Sizes range from 0.5 to 3 cm and may suddenly grow over weeks or months to subsequently remain indefinitely^[14].

Definitive diagnosis of pyogenic granuloma can be made only after histopathological examination of the biopsied tissue. From the histological point of view, this lesion can be classified into two groups: when capillary vessels are found to be organized into granulomatous tissue lobes surrounded by a thin collagen band, the formation is called «capillary lobular hemangioma», whereas when vascular formations are intertwined in the tissue without apparent order, it is called «non lobular capillary hemangioma»^[15].

Epivatianos A *et al*^[16] described two types of pyogenic granuloma with different clinical and histological aspects: lobular capillary hemangioma which is often a sessile lesion and non- lobular capillary hemangioma with a stalk.

Differential diagnosis for pyogenic granuloma is kaposi's sarcoma, angiosarcoma, non-hodgkin's lymphoma, metastatic tumor, postextraction granuloma,

pregnancy tumor, peripheral giant cell granuloma, peripheral ossifying fibroma, hemangioma, peripheral fibroma, leiomyoma, hemangioendothelioma, hemangiopericytoma, bacillary angiomatosis^[17].

Treatment of pyogenic granuloma involves the removal of the causative agent which may sometimes result in spontaneous resolution. Excision of the lesion is the treatment of choice^[18]. Different therapeutic approaches are reported, such as cryosurgery, laser excision. In our case, the coblation system was used in excision.

CONCLUSION

Dental procedure may be act as an initiating factor to give rise pyogenic granuloma in the tongue. Histopathological examination of the biopsied tissue is a corner stone for a definitive diagnosis. Lesion Excision is the main treatment.

CONFLICT OF INTEREST

There are no conflicts of interest.

REFERENCES

1. Jafarzadeh H, Sanatkhani M, Mohtasham N (2006) Oral pyogenic granuloma: a review. *J Oral Sci* 48:167–175.Link
2. M Rachappa, M Triveni (2010) Capillary hemangioma or pyogenic granuloma: a diagnostic dilemma. *Contemporary Clinical Dentistry* 1(2): 119–122. Link
3. A Castillo-Castillo, C Doncel-Pérez (2013) Granuloma piógeno Presentación de un caso. *Rev Haban de Cienc Méd* 12 (3) : 322-328.Link
4. Scheinfeld NS (2008). Pyogenic granuloma. *Skinmed* 7:89-92. Link
5. Andrikopoulou M, Chatzistamou I, Gkilas H *et al* (2013) Assessment of angiogenic markers and female sex hormone receptors in pregnancy tumor of the gingiva. *J Oral Maxillofac Surg* 71:1376-1381. Link
6. Beata Zielnik Jurkiewicz (2005) Rare case of pyogenic granuloma of the tongue in an 8-week-old infant. *Otolaryngol Pol* 59 (5):755-8.Link
7. M Abdallah Lotf , B Bonin-Goga, G Lorette (2005) Pyogenic granuloma (botryomycoma) of the tongue in a child. *Presse Med* 4;34(10):754. Link
8. Salvador Arias-Santiago, José Aneiros-Fernández, Jacinto Orgaz-Molina, María Antonia Fernández-Pugnaire, Maria Sierra Girón-Prieto, Ramon Naranjo-Sintes and Jose Aneiros-Cachaza (2011) A pregnant woman with a nodule on the tongue: a quiz. Lobular capillary haemangioma (pyogenic granuloma). *Acta Derm Venereol* 91: 607–61. Link
9. Marcos Ximenes , Thaisa C Triches, Mariane Cardoso, Michele Bolan (2013) Pyogenic granuloma on the tongue: a pediatric case report. *Gen Dent* 61(5):27-9.Link
10. Sonam Sharma, Amita Sharma, Ashok Kumar, Shivani Kalhan, Jasmine Kaur (2014) Pyogenic granuloma of tongue – A rare case report. *Asian Journal of Medical Sciences* 6(3). Link
11. Vinson Louis Gonzaga Fernandes, Nina Margarida De Gouveia Pinto, Vibhav B. Sanzgiri, Purva Khandolkar, Isha Rajendra Sukhthankar (2018) A Rare Case Report of Pyogenic Granuloma of Tongue. *International Journal of Otolaryngology and Head & Neck Surgery* 07(03):75-79.Link
12. Scott M Peters, David A Koslovsky, Angela J Yoon, Elizabeth M Philipone (2018) Pyogenic Granuloma in the Tongue in a Five Year Old: A Case Report . *J Clin Pediatr Dent* 42(5):383-385. Link
13. Elisângela Santos Dias, Laura Cruz-Mamani, Alessandro Antônio Pereira, Felipe Fornias Sperandio, Kellen Cristina Gasque, Marina Lara de Carli, João Adolfo Hanemann (2020) Pyogenic granuloma in the tongue of a patient with Down syndrome. *Dent* 68(4):61-63.Link
14. Patil K, Mahima VG, Lahari K (2006) Extralingival Pyogenic Granuloma. *Indian Journal of Dental Research* 17: 199-202.Link
15. Ramanaryana B, Kotya NM, Sam SS (2016) Pyogenic granuloma: Report of two cases with review of literature. *J Periodontal Implant Dent* 8(2):73–76.Link
16. M. Amirchaghmaghi, F. Falaki, N. Mohtasham, P.M. Mozafari (2008) Extralingival pyogenic granuloma: a case report *Cases J*, 1, pp. 371.Link
17. Amirchaghmaghi, M., Farnaz, F., Nooshin, M. and Mozafari, P.M. (2008) Extralingival Pyogenic Granuloma: A Case Report. *Cases Journal* 1, 371. Link
18. Lawoyin JO, Arotiba JT, Dosumu OO (1997) Oral Pyogenic Granuloma. A Review of 38 Cases from Ibadan, Nigeria. *British Journal of Oral and Maxillofacial Surgery* 35:185-189.Link