

Hernio-Abdominoplasty Versus Hernioplasty of Incisional Hernia Associated with Pendulous Abdomen: A Comparative Study

Mahmoud Abdou Yassin, Amr A. Abdelghani, Mostafa M Elaidy, Ahmed Shafik Mohamed El Hefnawy

Department of General Surgery, Faculty of Medicine, Zagazig University, Egypt

*Corresponding author: Mahmoud Abdou Yassin, Mobile: (+20) 01226523031, E-Mail: mahmoudyassin42@yahoo.com

ABSTRACT

Background: Incisional hernia is one of the most common types of the ventral hernia. It nearly complicates 4-18% of abdominal operations within 5 years follow up. In women with pendulous abdomen, a combined hernio-abdominoplasty anticipated to improve the cosmeses as well as life quality. As it is expected to reinforce the muscular bending, improve intertrigo, stead lumbar spine and decrease the postoperative drawbacks.

Objective: The aim of this study is to enhance the result of incisional hernia repair and to compare the outcome of combined hernio-abdominoplasty and hernioplasty of incisional hernia in obese female with lax redundant abdomen.

Patients and Methods: The present study was carried out at Zagazig University Hospitals, in the period between March 2021 and June 2022, on 80 multiparous women admitted for incisional hernia repair. Patients were divided randomly into two equal groups, the first group (A) included 40 patients corrected by hernioplasty alone, while the second group (B) corrected by concomitant hernioplasty and abdominoplasty.

Results: Both time of operation and hospital stay were significantly more in the group (B). However, recurrence, infection, intertrigo, abdominal deformity and need for refashioning, were significantly complicate the patients of group (A). Although, hematoma and seroma were more common in group (B) yet, without significant difference, and the quality of life was highly improved in this group.

Conclusion: A combined hernio-abdominoplasty of incisional hernia in female with pendulous abdomen, significantly improves the esthetic results and the quality of life, and can also decrease the postoperative complications.

Keywords: Incisional hernia, Tummy Tuck abdominoplasty, Hernio-abdominoplasty, pendulous abdomen, Diastasis of recti.

INTRODUCTION

Ventral hernia (Umbilical, para-umbilical, epigastric, and incisional hernia) is one of the most common surgical problems in general. Twenty millions of hernias operations are carried out yearly, 4-18% of them are on the incisional hernia⁽¹⁾.

Incisional hernia, associated with pendulant abdomen, is commonly found in obese multiparous female with abdominal wall laxity and deformity⁽²⁾. This redundancy can't be corrected either by diet control or muscular exercise⁽³⁾.

Management of incisional hernias have been evaluated by many literatures, however they lacking its evaluation when associated with redundant abdomen⁽⁴⁾. Abdominoplasty is one of Tummy Tuck procedures performed for making the lax abdominal wall, as well as firm and thin. It has an esthetic component done by removal of lower abdominal redundant skin and fat and reconstructive component on diastasis of recti⁽⁵⁾. Mini-abdominoplasty is similar but with no umbilical reposition. Weakness of the linea Alba is common in obese multiparous women with pendulant abdomen, aggravated by incisional hernia especially, if developed in midline⁽⁶⁾.

Incisional hernia is the protrusion appearing along a prior abdominal wound, it complicates 4-18% of abdominal operations and increases up to 23% if associated with wound infection⁽¹⁾. It has a wide range (0%-46%) of recurrence⁽⁷⁾ especially when corrected by primary closure⁽²⁾. Recurrence cannot be avoided even with prosthetic mesh and perfect repair of the defect⁽⁸⁾. Concomitant hernio-abdominoplasty has many

advantages as cost and time saving, declines back pain, and recurrence⁽⁹⁾, it improves the cosmeses, quality of life and decreases the postoperative complications⁽¹⁰⁾. As much as, improving lipid profile, hypertension controls and lowering the diabetic risk by 75%, and the mortality associated with obesity can be declined by 24%⁽¹¹⁾.

AIM OF THE STUDY

The aim of this study is to enhance the result of incisional hernia repair, and to compare the outcome of combined hernio-abdominoplasty and hernioplasty of incisional hernia in obese female with lax redundant abdomen.

PATIENTS AND METHODS

A comparative study was carried out on 80 obese female patients with incisional hernia. Patients were randomly allocated into two equal groups, each containing 40 patients. In the first group (group A) we did hernioplasty alone, while in the second group (group B) we did combined hernio-abdominoplasty, was carried out at Zagazig University Hospitals, in the period between March 2021 and June 2022.

Ethical consent:

An approval of the study was obtained from Zagazig University Academic and Ethical Committee (IRB#:9768-27-2-2021). Every patient signed an informed written consent for acceptance of participation in the study. This work has been carried out in accordance with The Code of Ethics of

the World Medical Association (Declaration of Helsinki) for studies involving humans.

Inclusion criteria:

1. Female patients with incisional hernia and pendulous abdomen
2. Uncomplicated incisional hernia
3. Age from 30 to 60 years old
4. BMI >25
5. Patients with low risk of anesthesia (ASA stage I&II).

Exclusion criteria:

1. Male patients
2. Female patients with incisional hernia but without pendulant abdomen
3. Age <30 and >60 years
4. Disturbed coagulation profile
5. Complicated incisional hernia
6. BMI < 25
7. Patients with high risk of anesthesia (ASA stage >II)

Preoperative:

Thorough history about previous operation was taken and physical examination was done. All our patients were assessed for the risk factors including diabetes mellitus, corticosteroid medication, smoking, thrombo-embolic disease. Body mass index (BMI) was calculated for all patients.

Preoperative pelvi-abdominal ultrasound, full laboratory investigations to detect liver or kidney dysfunction and exclusion of coagulopathy. Preoperative prophylactic single dose of third generation cephalosporin one hour before operation and prophylactic low molecular weight heparin was given to all patients at the night of operation.

Procedure: All operations were performed under general or high level spinal anesthesia. A urinary

catheter and nasogastric tube were inserted to decompress both bladder and stomach respectively.

Incisional hernia corrected by hernioplasty (figure 1); an elliptical incision around the hernia, dissection on the sac, opening of the sac at its neck and reduction of its contents, repair of the defect by polypropylene 1/0. Mesh fixation and suction drain was inserted, subcutaneous approximation by polyglactin 2/0, the skin closed by subcuticular polypropylene 3/0.

Incisional hernia corrected by hernio-abdominoplasty (figures 2, 3, 4 & 5); a curved handle-bar suprapubic incision and the wound extended approximately till the flanks. Epifascial tissue dissection, the flap was raised above the level of the umbilicus with meticulous preservation of its blood as well as its nerve supply. Healthy umbilicus, saved by an elliptical incision around it down till the sheath, and replaced in its new position (**figure 2**). However, unhealthy umbilicus sacrificed within the excised part of the flap, and new one can be created by two polypropylene 2/0 stitches, dimpling across the dermis (**figures 3, 4 & 5**).

Diastasis of recti was plicated by polypropylene 1/0. Good hemostasis was done and large onlay polypropylene mesh 30*30 cm was fixed in the costal margin above and the iliac crest below, two negative suction drains were inserted, and excess redundant tissue was excised.

Subcuticular Closure of skin by polypropylene 3/0 or stapler, and the wound covered by bulky dressing, facilitating good observation of the flap. Drains were removed when its contents became as little as 50 ml in 24 hours, and stitches or staples removed in outpatient clinics. Mean hospital stay was recorded and our patients were followed-up in outpatient clinics weekly for one month, and then monthly for six months.

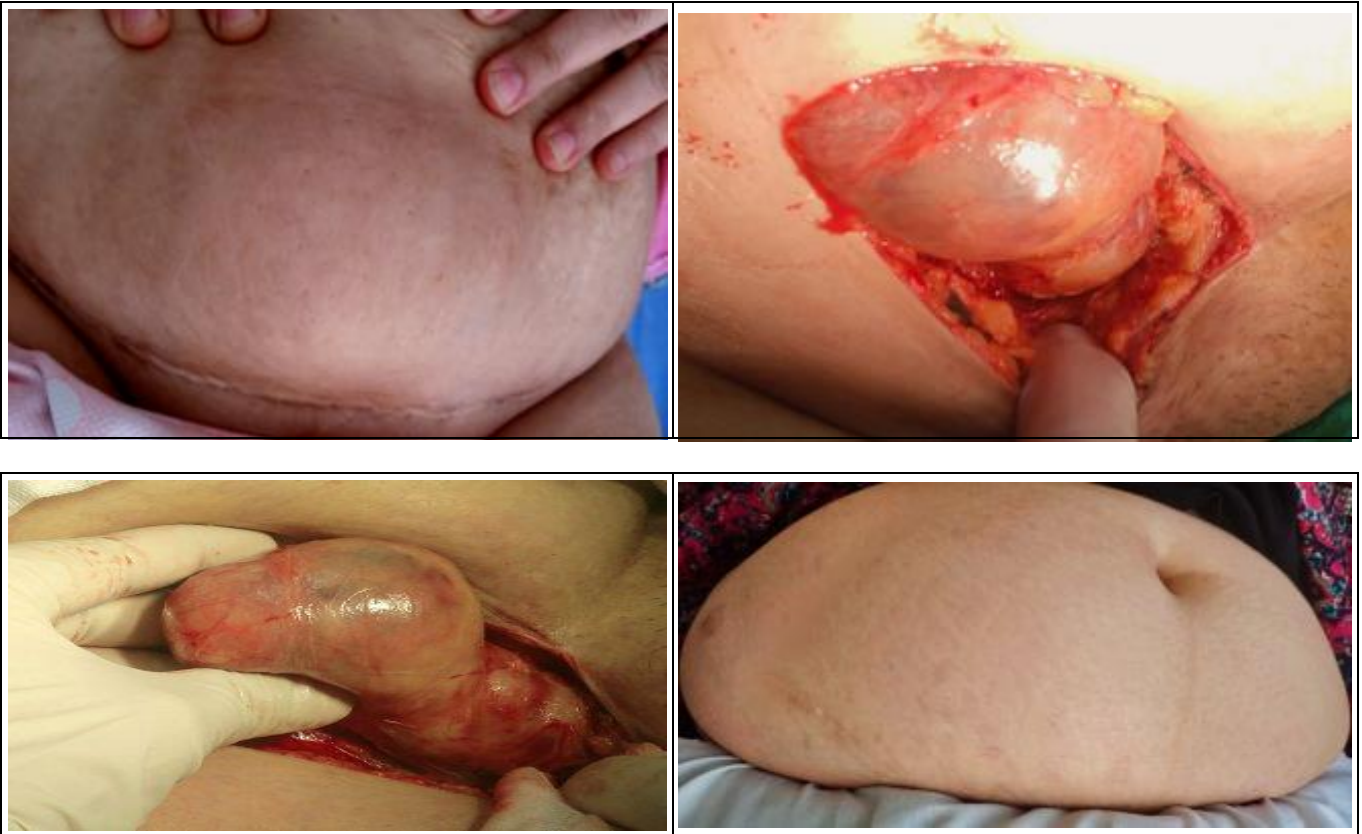

Figure (1): Hernioplasty for incisional hernia post pfannenstiel incision, in female with pendulous abdomen.

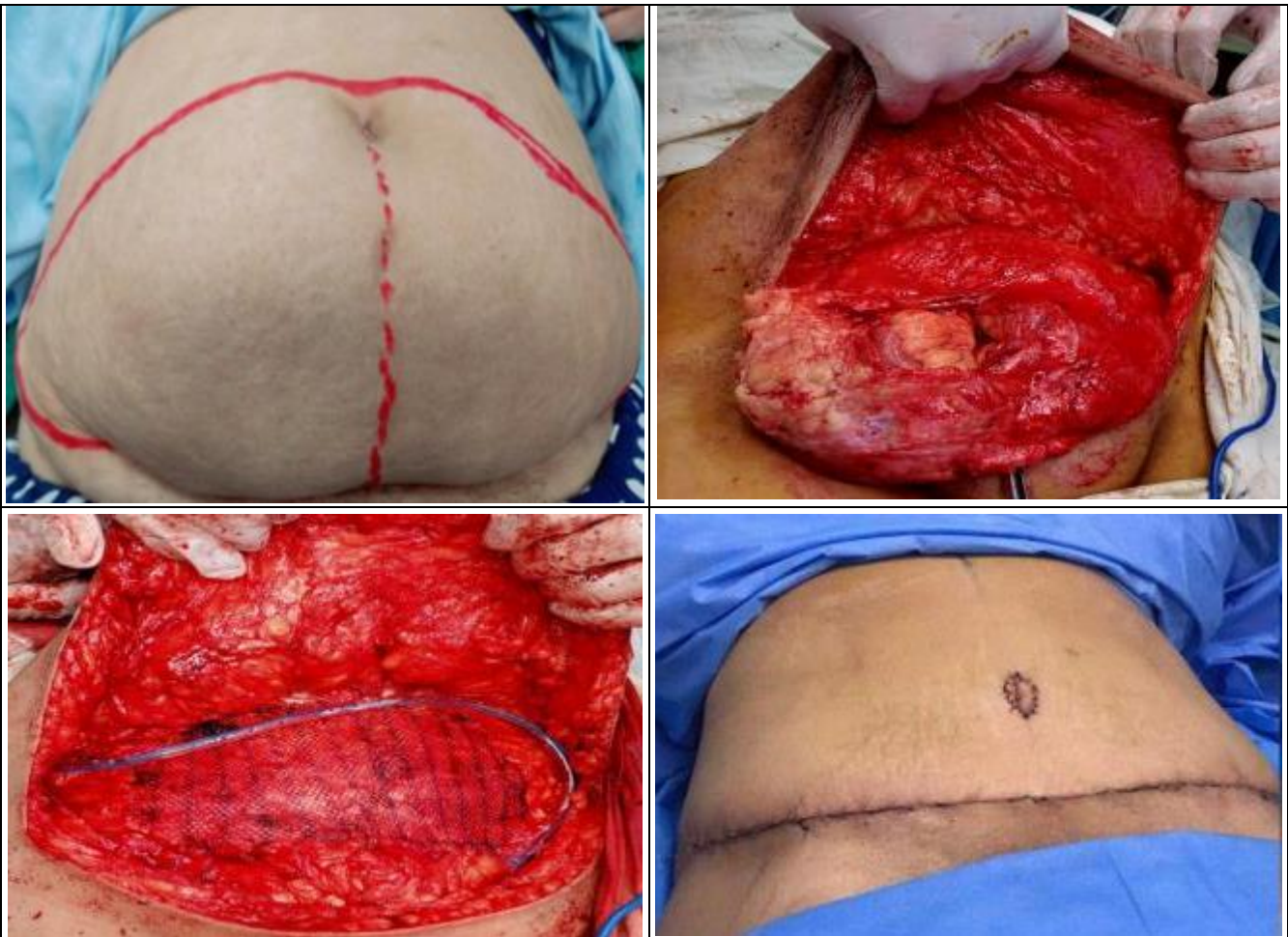

Figure (2): Hernio-abdominoplasty with preserving belly button for huge incisional hernia post lower midline laparotomy in female with pendulous abdomen.

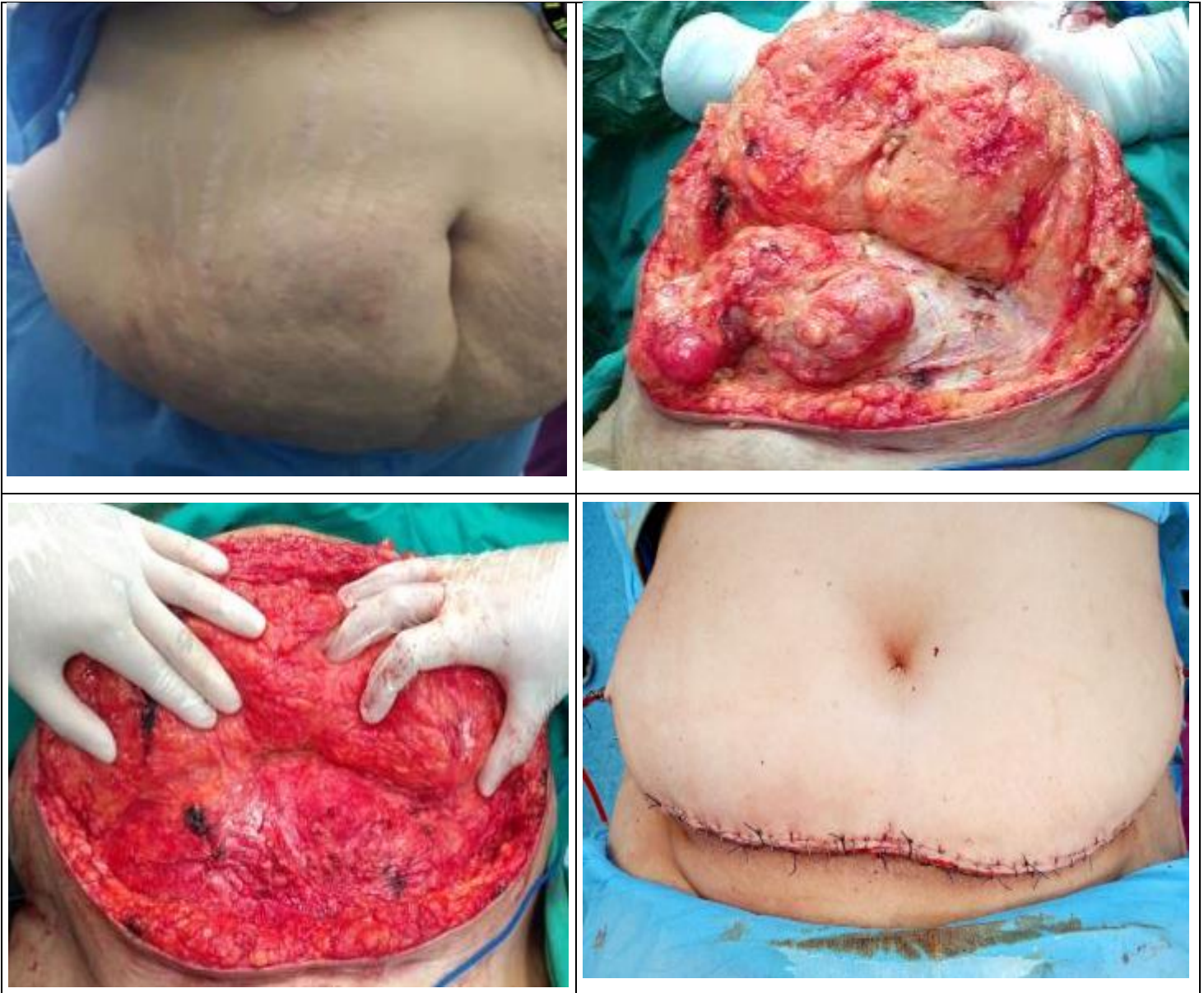


Figure (3): Hernio-abdominoplasty with newly performed umbilicus, for huge incisional hernia post lower midline laparotomy.

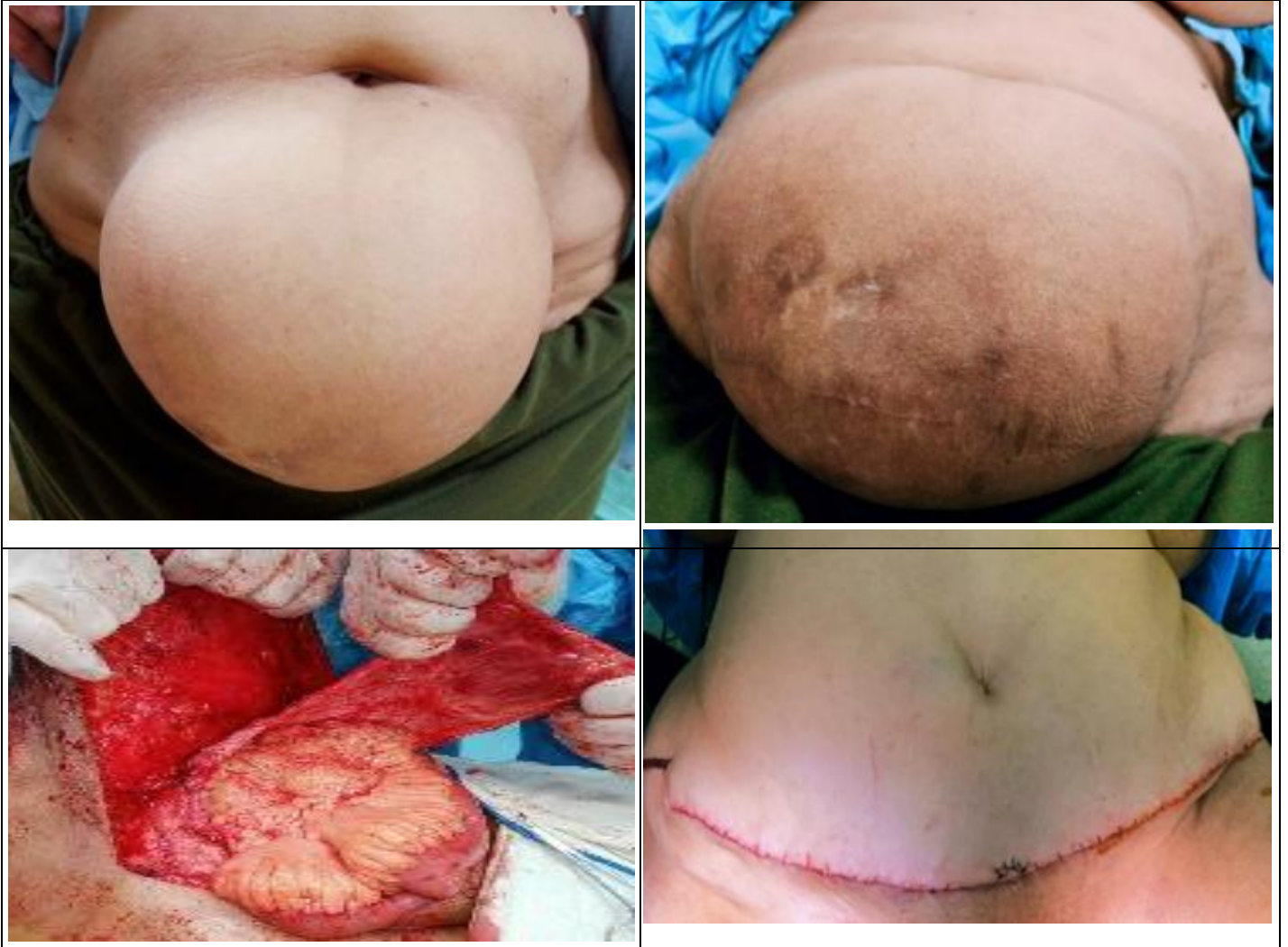

Figure (4): Huge incisional hernia with pendulous abdomen post pfannenstiel incision, operated by hernio-abdominoplasty with creation of new umbilicus.

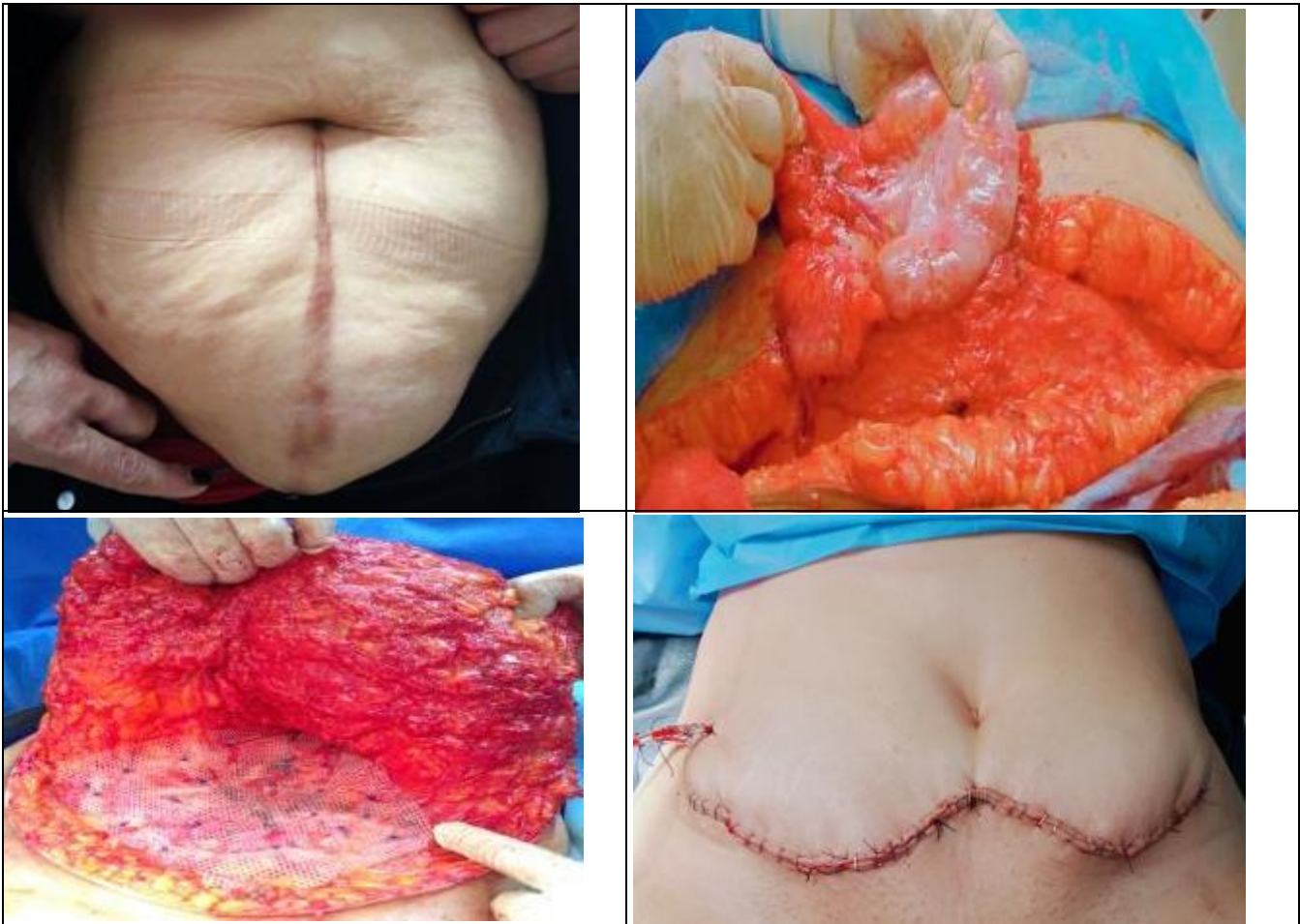


Figure (5): Huge incisional hernia with pendulous abdomen post laparotomy, operated by hernio-abdominoplasty with newly umbilicus creation.

Statistical analysis

The collected data were coded, processed and analyzed using the SPSS (Statistical Package for Social Sciences) version 22 for Windows® (IBM SPSS Inc, Chicago, IL, USA). Data were tested for normal distribution using the Shapiro Walk test. Qualitative data were represented as frequencies and relative percentages. Chi square test (χ^2) to calculate difference between two or more groups of qualitative variables. Quantitative data were expressed as mean \pm SD (Standard deviation). Independent samples t-test was used to compare between two independent groups of

normally distributed variables (parametric data). P value < 0.05 was considered significant.

RESULTS

The present study was conducted on **80** female patients had incisional hernia, associated with pendulous abdomen. They were divided randomly into two equal groups: **Group (A)** (40), we did hernioplasty alone, **Group (B)** (40), but we did combined hernio-abdominoplasty (**table 1**).

Table (1): General characteristics of studied groups.

	Group I(A) N=40	Group II(B) N=40	t-test	P value
Age Mean ± SD Range	39.45 ± 7.09 (30 – 54)	45.15 ± 7.41 (35 – 57)	-2.485	0.017 S
Sex: Female, N (%)	40 (100%)	40 (100%)	----	-----
BMI (kg/m2) Mean ± SD Range	32.25 ± 3.65 (26 – 38)	31.70 ± 5.68 (27 – 44)	0.364	0.718 NS

NS: P-value>0.05 is not significant

Table (1) shows that, both groups were matched regarding basic data, sex and BMI, with no statistically significant difference between them. However, the age shows significant difference between both groups.

Table (2): Types of incisional hernias presented among both studied groups.

Types	Group I (A) N=40 N (%)	Group II (B) N=40 N (%)	X ²	P value
Post lower midline laparotomy	10 (25%)	20 (50%)		0.02
Post pfannenstiell incision	30 (75%)	20 (50%)	5.33	S

S: P-value<0.05 is significant

Table (2) shows that 75% of patients suspected for hernioplasty alone, had incisional hernias post pfannenstiell incision. And 10% only with incisional hernia post lower midline laparotomy, versus (50% and 50% of group B patients), there was statistically significant difference between our groups.

Table (3): Operative data among both studied groups.

	Group I (A) N=40	Group II (B) N=40	t-test\ MW*	P value
Operative time\ minutes Mean ± SD	87.5 ± 11.2	95.6 ± 5.57	4.14	<0.001 HS
Hospital stay\ days Median (range)	1 (1 – 2)	2 (1 – 2)	2.48*	0.01 S

S: P-value <0.05 is significant

HS: P-value <0.001 is high significant

* Mann-whitney test

Table (3) shows that patients of group (B), had longer operative time and post-operative hospital stay, with statistical significant difference among both groups.

Table (4): Outcome and complications among both studied groups.

	Group I (A) N=40, N (%)	Group II (B) N=40, N (%)	P value#
Recurrence	7 (17.5%)	0 (0.0%)	0.006 S
Hematoma	3 (7.5%)	5 (12.5%)	0.46 NS
Seroma	3 (7.5%)	5 (12.5%)	0.46 NS
Wound infection	5 (12.5%)	3 (7.5%)	0.46 NS
Flap necrosis	0 (0.0%)	0 (0.0%)	-----
Intertrigo	20 (50%)	0 (0.0%)	<0.001 HS
Abdominal deformity	18 (45%)	0 (0.0%)	<0.001 HS
Need for re-fashioning	18 (45%)	0 (0.0%)	<0.001 HS
Improvement of quality of life	22 (55%)	40 (100%)	<0.001 HS
Improvement of lower back pain	0 (0.0%)	30 (75%)	<0.001 HS

NS: P-value>0.05 is not significant

HS: P-value <0.001 is high significant # Fisher exact test of significance is used.

Table (4) shows that prevalence of recurrence that is more in group (A) significantly, however hematoma and seroma complicate group (B) more than group (A), but with no significant difference. Wound infection complicates group (A) more than group (B) but with no significant difference. Flap necrosis didn't complicate any patient of either group. Intertrigo, abdominal deformity, need for re-fashioning and improvement of quality of life, all are more common in group (A) than group (B), and showed highly significant difference between the two groups.

DISCUSSION

Abdominoplasty is one of the Tummy Tuck procedures performed for strengthening and recontouring the abdominal trunk⁽¹²⁾. It has two aims, the first concerning with creation of a new harmony between the abdomen and the rest of the body, while the second aim to reinforce lax and weak abdominal wall musculature⁽¹³⁾. It can also relieve back pain in most cases⁽¹⁴⁾, improves both physical and sexual activities⁽¹⁵⁾, and relieves intertrigo acquired by fungal infection⁽¹⁶⁾. Hernio-abdominoplasty gives the best cosmetic result as the final scar hidden behind the bikini⁽¹⁸⁾.

In our study, the age of group (A) ranged between 30 and 54 years, the Mean \pm SD was (39.45 \pm 7.09), while the age of group (B), ranged from 35-57 years with Mean \pm SD (45.15 \pm 7.41), there was a significant difference between them. Unlikely, study carried out by **Moreno-Egea et al.**⁽¹⁹⁾, the mean age was (64 \pm 7 years) and (66 \pm 8 years), for the group operated by incisional hernioplasty and the group operated by combined hernio-abdominoplasty respectively, with no significant difference between them.

Our study showed that, the range of BMI (kg/m²) fallen between 26 and 38, its mean was (32.25 \pm 3.65) in group (A), while it ranged between 27 and 44, and its mean was (31.70 \pm 5.68) in group (B), with no significant difference was detected. It goes with study carried out by **Wagdi et al.**⁽²⁰⁾, in which BMI was 26-38 with a mean equal \pm SD 32.25 \pm 3.65, in the group operated by hernioplasty. While in the group operated by abdominoplasty or mini-abdominoplasty, BMI ranged between 27 and 44, and the mean was 31.70 \pm 5.68.

As regard to mean time of the operation, it was found that it was significantly longer in the group corrected by concomitant hernio-abdominoplasty (76 minutes versus 187 minutes)⁽²⁰⁾. Correlates with our study, as the mean operative time in group (A) was (87.5 \pm 11.2) ranged between 60-100 min. While it ranged between 90-110 min, with a mean equal (95.6 \pm 5.57) in group (B). There was highly significant difference between both our groups.

The current study showed that, the mean hospital stay in group (A) was one day (1-2), and 2 days (1 – 2) in group (B), with significant p-value (0.01). While **Hussain et al.**⁽²¹⁾, reported that postoperative hospital stay was (1.95 vs 2 days) with no significant difference between hernia repair with and without abdominoplasty.

As regard to postoperative complications, recurrence rate in our study was 7 (17.5%) patients of the first group and no recurrent cases was detected in the second group, and the difference was significant. Recurrent cases observed through 6 months of follow up period, were re-corrected by combined hernio-abdominoplasty. Study carried by **Carbajo et al.**⁽²²⁾, **Le Black et al.**⁽²³⁾ and **Heniford et al.**⁽²⁴⁾, reported that, the recurrence rate was 4.4%, 6.5% and 4.7% respectively.

Hematoma, was detected in study⁽²⁰⁾, in (10%) of patients managed by hernio-abdominoplasty, and no detected cases in the group managed by hernioplasty. Go with our study, as hematoma and seroma were more detected in group (B) (12.5%) versus 7.5% in group (A), but without significant difference. Our patients complicated by hematoma and seroma, were managed by frequent aspiration, and compression, till all case improved with no need for reoperation. Study performed by **Von Sperling et al.**⁽²⁵⁾, reported seroma in 4.7%-7.14% of patients corrected by hernio-abdominoplasty.

In the present study, wound infection complicated 5 patients (12.5%) of the first group and 3 patients (7.5%) of the second group, no significant difference was detected between them. Patients with wound infection were treated conservatively by repeated dressing and strong systemic antibiotics, there was no need for mesh removal. **Hawaz**⁽⁴⁾ observed wound infection post dermolipectomy in 1%. While **Heniford et al.**⁽²⁴⁾ detected infection post hernioplasty in 3-18% of their patients.

Flap necrosis not detected in any patient of both our groups. However, **Gado et al.**⁽¹²⁾ reported flap necrosis in (6.9%) of cases.

Intertrigo complicated 20 (50%) of our group (A) only, hernio-abdominoplasty significantly improved fungal skin infection, patients complicated by intertrigo managed by local antifungal and skin sterilization with the skin kept always dry. Matches with **Aamer et al.**⁽¹¹⁾ who reported that, redundant moist skin with difficult hygiene, has been susceptible for intertrigo.

In our study, abdominal deformity was observed in 18 (45%) of group (A) only with highly significant difference in between our groups. Three patients of them re-operated again by hernio-abdominoplasty, while the others refused reintervention. Study carried by **Gado et al.**⁽¹²⁾ found that 10 percent of their patients suffered from postoperative existing deformity, and were in need for re-correction.

We detected significant improvement of patients life quality in 40 (100%) of group (B), versus 22 (55%) of group (A). Correlates with **Nagamallesh et al.**⁽²⁶⁾ who recorded that, 80% of their patients were satisfied with improved quality of life and cosmetic result after incisional hernio-abdominoplasty.

Back pain constantly improved in more than 70% by associated hernio-abdominoplasty⁽²⁾. Also, **Roucher et al.**⁽¹⁴⁾ found that, all patients complaining of preoperative back pain, have been optimised by combined hernio-abdominoplasty trial. Matches with our study, as our patients with back pain in the second group only, had been significantly improved by 75%.

CONCLUSION

Combined hernio-abdominoplasty, for management of incisional hernia in multiparous female

with pendulous abdomen, is a simple safe procedure. With better satisfying functions and esthetic results, as well as, it decreases the expected postoperative complications.

Financial support and sponsorship: Nil.

Conflict of interest: Nil.

REFERENCES

1. **Bougard H, Coolen D, Beer R et al. (2016):** The Hernia Interest Group (HIG) of the South African Society of Endoscopic Surgeons (SASES) HIG (SA) Guidelines for the Management of Ventral Hernias. SAJS., 54(3): 1-4.
2. **Sakr M, Habib M, Hamed H et al. (2019):** Outcome of Combining Ventral Hernia Repair with Abdominoplasty or Mesh-abdominoplasty in Multiparous Women. Glob J Surg., 7: 5-11.
3. **Cheesborough J, Gregory A, Dumanian G (2015):** Simultaneous Prosthetic Mesh Abdominal Wall Reconstruction with Abdominoplasty for Ventral Hernia and Severe Rectus Diastasis Repairs. Plast Reconstr Surg., 2015; 135(1): 268-276.
4. **Hawaz M (2007):** Factors influencing post-operative complication after prosthetic "Mesh" repair of Incisional hernia (A prospective study). Bas J Surg., 13: 1-3.
5. **Roshdy H, Ali Y, Askar W et al. (2011):** Combined Abdominal Dermolipectomy-Hernioplasty in Obese Patients and after Bariatric Surgery Egypt. J Plast Reconstr Surg., 35: 167-173.
6. **Ismaeil A (2018):** Mesh repair of paraumbilical hernia, outcome of 58 cases. Ann Med Surg., 30: 28-31.
7. **Suhas K, Mahesh A, Praneeth N et al. (2017):** a comparative study between surgical procedures performed for Incisional hernia in obese patients. Internat J Sci Res., 6: 93-98.
8. **Van Geffen H, Simmermacher R (2005):** Incisional hernia repair abdominoplasty tissue expansion and methods of augmentation world. J Surg., 29: 1080-1085.
9. **Sakr M, Habib M, Hamed H et al. (2019):** Outcome of combining ventral hernia repair with abdominoplasty or mesh-abdominoplasty in multiparous women. Glob J Surg., 7:5-11.
10. **Shipkov H, Mojallal A, Braye F (2017):** Simultaneous Abdominoplasty and Umbilical Hernia Repair via Laparoscopy: a Preliminary Report. Folia Medica , 59 (2): 222-227.
11. **Aamer M, Eskandaros M, Nagy Gerges B (2018):** Formal Abdominoplasty versus Mini-Abdominoplasty Post Laparoscopic Sleeve Gastrectomy. Egypt J Hosp Med., 72(10): 5455-5560.
12. **Gado W, Elmorsy M, Elsayed Y et al. (2020):** Clinical Outcome of Abdominoplasty Techniques for Abdominal Wall Deformities: Comparative Study. J Surg., 5: 1278. DOI: 10.29011/2575-9760.001278
13. **Ghnam W (2009):** Abdominoplasty for Ventral Abdominal Hernia Mesh Repair. JMJ., 9: 211-214.
14. **Roucher F, Drevet J, Auberge T (1990):** Breast reduction and abdominoplasty: preventive and therapeutic effect on back pain in women. Ann Chir Plast Esthet., 35: 228-232.
15. **Bolton M, Pruzinsky T, Cash T et al. (2003):** Measuring outcomes in plastic surgery: Body image and quality of life in abdominoplasty patients. Plast Reconstr Surg., 112: 619-625.
16. **El-Khatib H, Bener A (2004):** Abdominal dermolipectomy in an abdomen with pre-existing scars: A different concept. Plast Reconstr Surg., 114: 992-997.
17. **Fotopoulos L, Kehagias I, Kalfarentzos F (2000):** Dermolipectomies following weight loss after surgery for morbid obesity. Obesity Surgery, 451-459.
18. **Ortega J, Navarro V, Cassinello N et al. (2010):** Requirement and postoperative outcomes of abdominal panniculectomy alone or in combination with other procedures in a bariatric surgery unit. Am J Surg., 200(2): 235-40.
19. **Moreno-Egea A, Campillo-Soto A et al. (2016):** Does Abdominoplasty Add Morbidity to Incisional Hernia Repair? A Randomized Controlled Trial. Surgical Innovation, 23(5):474-80.
20. **Wagdi H, Mohamed M, Aboul Naga M et al. (2018):** Incisional Hernia Repair with Abdominoplasty. Egypt J Hosp Med., 72(6): 4715-4724.
21. **Hussain S, Malik F, Zulfiqar F (2020):** Morbidity Related to Incisional Hernia Repair with Abdominoplasty. Med Forum., 31(7): 1-3.
22. **Carbajo M, Martp Del Olmo J, Blanco J et al. (2003):** Laparoscopic approach to incisional hernias. Surg Endosc., 17: 118-122.
23. **Le Blanc K, Whitaker J, Bellanger D et al. (2004):** Laparoscopic Incisional and ventral hernioplasty: Lessons from 200 patients. Hernia, 7: 118-124.
24. **Heniford B, Park A, Ramshaw B et al. (2003):** Laparoscopic repair of ventral hernias: Nine years experience with 850 consecutive her-nias. Ann Surg., 238: 391-400.
25. **Von Sperling M, Hoimyr H, Finnerup K et al. (2011):** Chronic postoperative pain and sensory changes following reduction. Scand J Pain, 2:57-61.
26. **Nagamallesh C, Nandini S, Tanwar F et al. (2021):** Tucked and treated- a case series on outcome of meshplasty with abdominoplasty for incisional hernia. Int Surg J., 8(11):3421-3425.