

Evaluation of Intradural Extramedullary Spinal Tumors Management: Single Institutional Experience

Ahmed A. Arab, Mohamed H. Eltantawy, Mohamed M. Elmaghrabi*

Department of Neurosurgery, Faculty of Medicine, Benha University, Egypt

*Corresponding author: Mohamed M. Elmaghrabi, Mobile: (+20) 01222751406, E-Mail: dr_elmaghrabi@yahoo.com

ABSTRACT

Background: Surgical treatment of Symptomatic intradural extramedullary spinal (IDEM) tumors is the most effective treatment. The development in diagnostic and surgical techniques helped for early diagnosis and excellent surgical results. The aim of the present study is to overview the management experience of IDEM spinal tumor cases in our university hospital for upgrading our competency and sharing it with other institutions.

Patients and methods: A retrospective study was conducted in which the medical records of patients who had surgical treatment for IDEM spinal tumors in between the periods from May 2015 to May 2020 in Benha University hospitals were evaluated and reviewed.

Results: A total of 23 patients, 11 males and 12 females were included with a mean age of 41.04 (SD 10.32) years and mean follow up of 22.9 (SD 7.52) months. Nerve sheath tumor (neurofibromas and schwannomas) accounted for most of tumors (52.2%) followed by meningiomas (34.8%). The 6 cases managed using IONM had excellent outcome. hemilaminectomy was done in 4 (17.4%) patients, and fusion was needed in 4 (17.4%) patients. Patients' functional outcome was assessed using Frankel grades; we had postoperative 8E, 4D, and 1C grades compared to 7E, 8D, 5C, and 3B preoperatively, and 22 (95.7%) patients had improvement. VAS showed significant from 8.57 (SD 1.21) preoperatively to 1.33 (SD 1.39) at last follow up visit (P value <0.001).

Conclusion: Surgical treatment of symptomatic an IDEM spine tumor is successful and safe with good functional outcome and pain improvement. Most tumors are benign. Use of IONM is helpful and small unilaterally located tumor can be approached via hemilaminectomy.

Keywords: Intradural, Extramedullary, Spinal tumors, Retrospective study.

INTRODUCTION

Primary spinal tumors represent 4.5% of primary central nervous system tumors, and intradural extramedullary (IDEM) spinal tumors constitutes 70 to 80% of all primary spinal cord tumors^(1,2). Most of the IDEM tumor are benign tumor (WHO grade I) as meningioma, schwannoma, and neurofibroma which had similar incidence^(3,4), other IDEM include metastasis, lipomas, nerve sheath tumor, paraganglioma and vascular tumor⁽⁵⁾.

The surgical treatment aims to complete and radical excision is the treatment of choice and offers the best results, but as these tumors are considered rare, there is no specific treatment guidelines and usually surgery is tailored for each tumor to obtain complete excision^(6,7), surgery also aims to achieve good functional outcome, and preserves spinal stability and preoperative neurological status⁽⁸⁾.

Different surgical techniques are used for excision of IDEM spinal tumors. Laminectomy has been the classic approach and also hemilaminectomy and they are still used for that despite the development of minimally invasive technique that aim to avoid potential complication of the classic approach, the laminectomy allows for better exposure, convenient work, and continue to be the preferred method for resection of large tumors with complex morphology⁽⁹⁾.

In the last years, surgical excision offered good result with the presence of operating microscope, microsurgical instrument, improved surgical techniques, intraoperative neuromonitoring and proper preparation by improved diagnostic tools as MRI and

CT that helped for a clear understanding of anatomical structure^(10,11). The real clinical benefits of use of improved and minimally invasive techniques, and neuromonitoring are still debatable⁽¹²⁾.

The aim of the present study is to overview the management experience of IDEM spinal tumor cases in our university hospital for upgrading our competency and sharing it with other institutions.

PATIENTS AND METHODS

This is a retrospective study that was conducted on 23 patients with spinal intradural extramedullary tumors who had underwent surgical treatment through the period from May 2015 to May 2020 in Benha University hospitals, their data was extracted from patients' files and follow up cards. The patients' clinical data was reviewed as regarding the presence of motor weakness, sensory deficit and symptoms, sphincteric disturbance, and back pain, and radicular pain. Radiological data included magnetic resonance imaging (MRI) with contrast preoperatively \pm computerized tomography (CT) for surgical preparation, and all cases had routine X-ray done preoperatively. Patients were prepared for surgery as regard anesthesia so they did full laboratory investigations to evaluate their surgical fitness.

Surgical technique:

After anesthesia, patients were operated upon in a prone position; spinal level was checked with fluoroscopy before skin sterilization and just before starting laminectomy. Patients were operated with the

standard posterior approach, 19 patients had complete laminectomy and 4 patients had only unilateral hemilaminectomy. After laminectomy dural opening was done and dural edges were hanged with sutures, excision was done using micro instruments, and surgical microscope. Intraoperative neuromonitoring was used in 6 cases. After tumor excision, hemostasis was ensured and dural closure was done in water tight fashion, a drain was left submuscular and closure was done tightly in layers.

Follow up was done by clinical examination and radiological investigations.

Postoperative follow up period of our cases for clinical and radiological evaluation ranged from 12 to 38 months. Patients were evaluated for improvement of pain using Visual Analogue Score VAS pre and post operatively, and functional outcome was evaluated using Frankel grade (table 1).

Grade	Expression	
A	Complete neurological injury	No motor or sensory function detected below level of lesion
B	Preserved sensation only	No motor function below level of lesion, some sensory function below level of lesion detected
C	Preserved motor, non-functional	Some voluntary motor function preserved below level of lesion but too weak to serve any useful purpose, sensation may or may not be preserved
D	Preserved motor, functional	Functional useful voluntary motor function below level of lesion
E	Normal motor function	Normal motor and sensory function below level of lesion, abnormal reflexes may persist

Ethical consent:

An approval of the study was obtained from Benha University Academic and Ethical Committee. Each patient or first degree relative signed a written informed consent after explaining all steps of this surgery and the surgical steps, benefits and complications which were clearly explained to them. This work has been carried out in accordance with The Code of Ethics of the World Medical Association (Declaration of Helsinki) for studies involving humans.

Statistical analysis

The collected data were coded, processed and analyzed using the SPSS (Statistical Package for Social Sciences) version 20 for Windows® (IBM SPSS Inc, Chicago, IL, USA). Quantitative data were analyzed

using mean, standard deviation (SD), while frequency and percentage were used with qualitative data. Fischer exact test was used to compare frequencies between outcome groups, while paired t test was used to compare mean of VAS pre and post-operative. P-value ≤ 0.05 was considered significant.

RESULTS

A total of 23 of patients, 11 (47.8%) males and 12 (52.2%) females were included in this study. Table 2 summarizes the sociodemographic data of the patients.

23 patients		
Number of patients		
Age	Range	23 – 58 years
	Mean	41.04 years \pm 10.32
Gender	Male	11 (47.8%)
	Female	12 (52.2%)
Follow up period	Range	12 – 38 months
	Mean	22.9 \pm 7.52 months

Table 2 summarizes the presenting symptoms of the patients.

Clinical Presentation		
Back pain	12	52.2%
Radicular pain	14	60.8%
Motor weakness	12	52.2%
Sensory deficit	10	43.5%
Sphincteric troubles	8	34.8%
Tumor Type		
Meningioma	8	34.8%
Schwanoma	7	30.5%
Neurofibroma	5	21.7%
Ependymoma	2	8.7%
Arachnoid cyst	1	4.3%
Fusion		
Yes	4	17.4%
No	19	82.6%
Level of Tumor		
Cervical	2	8.7%
Dorsal	13	56.5%
Lumbar	8	34.8%
Use of IONM		
Yes	6	26.1%
No	17	73.9%
Surgical Approach		
Laminectomy	19	82.6%
Hemilaminectomy	4	17.4%

Radiologically, most tumors were located in the dorsal region accounting for 13 (56.5%) patients, 8

(34.8%) tumors were located in the lumbar region, and there were 2 (8.7%) tumors in the cervical region.

As regard surgery, laminectomy (**Figure 1**) was performed in 19 (82.6%) patients, and 4 (17.4%) patients were done with hemilaminectomy all of them were in the lumbar region. Intraoperative neuromonitoring (IONM) was used in 6 patients, fusion was needed in 4 patients in this study (**Figure 2**). Complications included cerebrospinal fluid leakage in 4 (17.4%) patients, 2 (8.7%) patients had temporary sphincter dysfunction and other 5 (21.7%) patients had

increased pain and paresthesia, and 2 of them had persistent moderate degree that needs pain medications. Pathologically, the commonest tumor type was the nerve sheath tumors (neurofibroma and schwannoma) 12 (52.2%) patients including 7 schwannomas and 5 neurofibroma representing 30.5% and 21.7% respectively, followed by meningiomas in 8 (34.8%) patients, we had 2 (8.7%) ependymoma, and 1 (4.3%) arachnoid cyst.

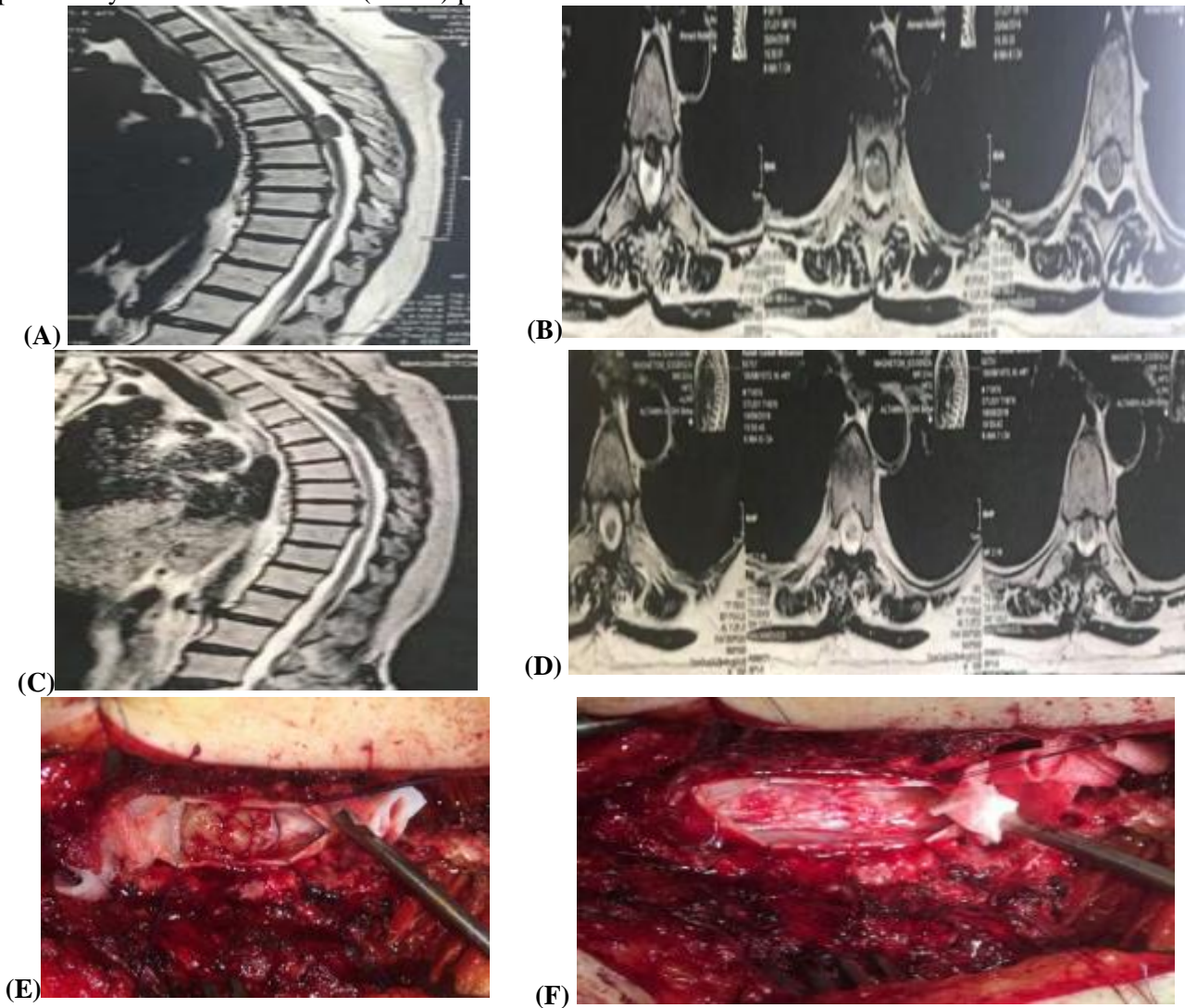


Figure (1): A 48 years old female patient who had surgery for lumbar spondyloleithesis, she had initial improvement before she developed new symptoms after 1 year of surgery. She had recurring severe lower back pain (VAS 10) but with LL spasticity and hyperreflexia, then she had progressive LL weakness to grade 3 right side and grade 4- left side (Frankel grade C) and sphincteric dysfunction. MRI thoracic spine revealed IDEM tumor at D6 level with severe cord compression. Surgery was done with laminectomy, complete tumor excision was done. Postoperatively, patient had improved to full power bilaterally (Frankel grade E). she had full sphincteric control, and the lower back pain improved to VAS 1. [A-D: MRI dorsal spine, pre-operative (A, B) and post-operative (C, D), E, F: intra-operative images show pre IDEM tumor excision (E) and post excision (F)].

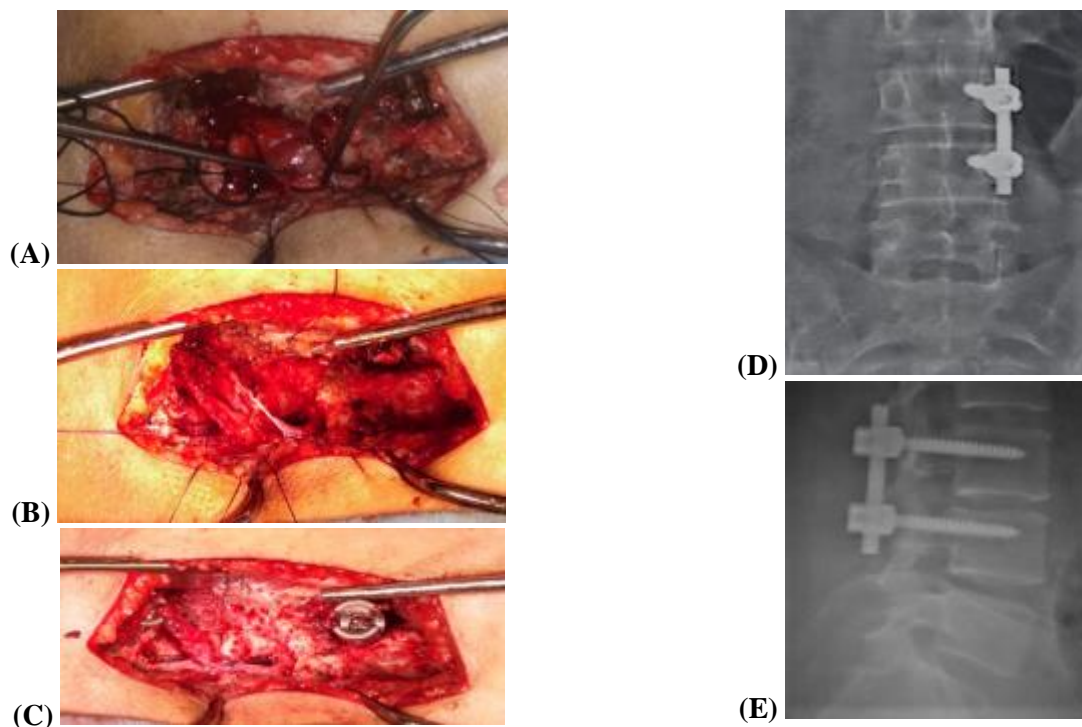


Figure (2): A case of intradural extramedullary mass towards the left side of the dural sac opposite L3 level and extending through the neural foramen at L3, L4 level. A patient 32 years old, presented with severe radicular pain and LBP (VAS 10) with no weakness. Left hemilaminectomy was done and the neural foramen was deroofed, dural opening done at lateral side and extended through the L3 root, complete excision was done and unilateral pedicle instrumentation. Postoperatively her pain subsided completely (VAS 0). A, B, C: intra-operative tumor excision and dural repair D&E: post-operative X-ray.

As regarding to surgical outcome, pain improved in all cases except 2 patients who had moderate degree of paresthesia, 91.3% had improvement, VAS improved from 8.57 (SD 1.21) preoperatively to 1.33 (SD 1.39) postoperatively that was statistically significant (P value <0.001). Functional outcome on Frankel grade, **table 4**, showed also improvement in all case except 1 case that had the same grade as preoperative. We had postoperative 8E, 4D, and 1C grades compared to 7E, 8D, 5C, and 3B preoperatively, and 22 (95.7%) cases had improvement.

Frankel Grade	Pre-operative	Post-operative	Prognosis
A	0	0	Bad
B	3	0	
C	5	1	fair
D	8	4	Good
E	7	18	Excellent
FET	7.58		
P value	0.055 (non-significant)		

DISCUSSION

Primary spinal tumors represent 4.5% of primary central nervous system tumors, and IDEM spinal tumors constitutes 70 to 80% of all primary spinal cord

tumors^(1,2). More than 50% of spinal tumors are located in the dorsal spine; they occur in the lumbosacral and cervical spine at a similar rate 18% and 22%, respectively⁽¹³⁾.

Song et al.⁽¹⁴⁾ found that the commonly seen IDEM tumors are schwannomas, neurofibromas, and meningiomas. Less common tumors are paragangliomas, metastatic tumors, lipomas, nerve sheath tumors, and vascular tumors. In this study on 23 patients, nerve sheath tumors (schwannoma and neurofibroma) accounted for most of the cases (52.2%), followed by meningiomas (34.8%) this was similar to many series done on small and large number of cases^(12,14-17).

We had 2 other tumors types in this study, 2 cases of Ependymoma and 1 case of arachnoid cyst.

Clinically, IDEM spinal tumors has symptoms related to spinal cord and/or root compression, so patients commonly present with local pain and/or radicular pain, also they are presented with motor and sensory deficits, motor deficit ranges from muscle group weakness to mono, hemi, para, and quadriplegia. Sphincteric dysfunction can also develop with cord compression and also with involvement of the cauda equine at lumbar level^(18, 19, 20). The patients in this study had different presentations according to location, size of the tumor, and degree of neural compromise. The most common presenting symptom in this study was localized back pain and radicular pain in 52.2% and

60.8%, respectively, followed by different degrees of motor weakness in 52.2%, sensory deficits in 43.5%, and sphincteric dysfunction in 34.8%. This was similar to results in other series (14,16,17).

As clinical presentation could arise from different spinal pathological conditions, clinical evaluation could help to establish the diagnosis and investigations required. For patients with mild and recent symptoms

Table (5): Comparison of outcome to some recent studies

Study	Number of patients	recovery	Excellent	Grade name
Song <i>et al.</i> 2009 ¹⁴	11	91.7%	75%	Frankel
Sharma <i>et al.</i> 2016 ¹⁷	65	95%	92.3%	McCormick
Nizami <i>et al.</i> 2017 ³⁰	23	82.6%	73.9%	Frankel
Joshi <i>et al.</i> 2019 ¹¹	19	91.6%	84.2%	ASIA
Petal <i>et al.</i> 2021 ³¹	31	100%	86.6%	Frankel
Current study	23	95.7%	78.3%	Frankel

X-ray might be the primary tool, X-ray could provide some clues to the presence of spinal tumors as pedicle erosion, foraminal widening, vertebral body erosion, but magnetic resonance imaging MRI is the gold standard imaging study in diagnosing spinal tumors as it assesses the size, location, shape, anatomical relation and adjacent structure, this is of great value in defining treatment guidelines and surgical approach (21, 22). Nowadays the availability of MRI had made it the first diagnostic investigation done in patient with suspected neurological condition. X-ray and computed tomography CT and other radiological studies are usually done complementary as needed for further confirmation and for surgical planning.

The posterior laminectomy has been the favored approach for intradural spinal tumor exposure (23). Hemilaminectomy was reported to be effective to decrease the impact of surgery and the risk of spinal instability (24), also, better perioperative results was described in hemilaminectomy vs. standard bilateral laminectomy (25), but with no difference in neurologic outcome. Usually choice of approach and type of laminectomy was related to surgeon's experience and his ability to approach, excise, repair, and close through narrow surgical corridor, functional neurological outcome was not different in different approaches (12). Of course, large lesions, bilaterally oriented, and lesion

with unclear borders are contraindications for hemilaminectomy (25). We had 4 cases in this study done via hemilaminectomy, in these cases tumors were small size, laterally oriented with radiological clear borders or related to the root through the foramina. A total of 19 tumors were excised by the standard laminectomy approach for better view and as surgeon preference. Instrumentation and fusion was done in 4 cases that had extensive exposure with possibility for instability.

During surgery defining the level of the tumor was mandatory to limit the laminectomy done to the site of the tumor, thus, in all surgeries done, level was checked with C-arm to define the skin incision and a second time just before laminectomy. Ultra-sonography U/S also could be used to locate the tumor (26). Microscopic excision aiming for total removal of the tumor while preserving the neural tissues to obtain excellent outcome is the standard goal of surgery (19, 27).

Intraoperative neurophysiologic monitoring IONM use during surgery for intradural tumors is helpful to avoid neural tissue damage and decrease postoperative morbidity (28), and it allows the surgeon to modify manipulation and perform a wise stop and wait strategy (29). We used IONM in 6 cases and it was very helpful, and all cases done with it had excellent improvement. Generally, most series on IDEM had reported encouraging outcome (Table 5). There was excellent result ranging from 75% to 92.3% and overall improvement ranging from 82.6% to 100% (11,14,17,30,31) this was also quite similar to our results.

CONCLUSION

Surgical treatment of symptomatic an IDEM spine tumor is successful and safe with good functional outcome and pain improvement. Most tumors are benign. Use of IONM is helpful and small unilaterally located tumor can be approached via hemilaminectomy.

Conflict of interest: The authors declare no conflict of interest.

Sources of funding: This research did not receive any specific grant from funding agencies in the public, commercial, or not-for-profit sectors.

Author contribution: Authors contributed equally in the study.

REFERENCES

1. Aghayev K, Vrionis F, Chamberlain M (2011): Adult intradural primary spinal cord tumors. J Natl Compr Canc Netw., 9:434-47
2. Bhat A, Kirmani A, Wani M *et al.* (2016): Incidence, histopathology, and surgical outcome of tumors of spinal cord, nerve roots, meninges, and vertebral column – data based on single institutional (Sher-i-Kashmir institute of medical science) experience. J Neurosci Rural Pract., 2016 7:381-91.
3. Engelhard H, Villano J, Porter K *et al.* (2010): Clinical presentation, histopathology, and treatment in 430 patients with primary tumors of the spinal cord, spinal

- meninges, or cauda equine. *J Neurosurg Spine*, 13(1):67-77.
4. **Klekamp J, Samii M (2007):** Surgery of spinal tumors: Mit 105 Tabellen. Berlin: Springer, Pp. 143-162. https://primo.qatar-weill.cornell.edu/discovery/fulldisplay/alma991000116319706691/974WCMCIQ_INST:VU1
 5. **Abul-Kasim J, Thurnher M, Mckeever P et al. (2008):** Intradural spinal tumors: Current classification and MRI features. *Neuroradiology*, 50(4):301-14.
 6. **Ottenhausen M, Ntoulas G, Bodhinayake I et al. (2019):** intradural spinal tumors in adults-update on management and outcome. *Neurosurg Rev.*, 42:371-8.
 7. **Tredway T, Santiago P, Hrubes M et al. (2006):** Minimally invasive resection of intradural-extramedullary spinal neoplasms. *Neurosurgery*, 58(1):52-8.
 8. **Mannion R, Nowitzke A, Efendy J et al. (2011):** Safety and efficacy of intradural extramedullary spinal tumor removal using a minimally invasive approach. *Neurosurgery*, 689(1):208-16.
 9. **Goodarzi A, Clouse J, Capizzano T et al. (2020):** the optimal surgical approach to intradural spinal tumors: Laminectomy or hemilaminectomy? *Cureus*, 12(2):e7084. doi: 10.7759/cureus.7084
 10. **Parsa A, Lee J, Parney I et al. (2004):** Spinal cord and intradural-extraparenchymal spinal tumors: current best care practices and strategies. *J Neurooncol.*, 69(1-3):291-318.
 11. **Joshi G, Bijukachhe B, Khan J (2019):** Surgical outcome of intradural extramedullary spinal cord tumors – our experience at a tertiary health care center. *Grand Medical Journal*, 1(2):103-109.
 12. **Cofano F, Giambra C, Costa P et al. (2020):** Management of extramedullary intradural spinal tumors: The impact of clinical status, intraoperative neurophysiological monitoring and surgical approach on outcomes in a 12-years double-center experience. *Front. Neurol.*, 11:598-619.
 13. **Tsai E, Butler J, Benzel E (2009):** Spinal meningiomas. In *Meningiomas*, Springer-Verlag London. Pp. 529-39.
 14. **Song K, Shin S, Lee J et al. (2009):** Surgical results of intradural extramedullary tumors. *Clinics in Orthopedic Surgery*, 1(2):74-80.
 15. **Prevedello D, Koerbel A, Tatsui C et al. (2003):** Prognostic factors in the treatment of the intradural extramedullary tumors: A study of 44 cases. *Arq Neuropsiquiatr.*, 61(2A):241-7.
 16. **Elzoghby M, Abdelbaky A (2015):** Functional outcomes following surgical management of intradural extramedullary spinal cord tumors. *Egy Spine J.*, 16:14-21.
 17. **Sharma G, Jha R, Poudel P et al. (2016):** Functional outcome of intradural extramedullary spinal tumors after surgical resection. *Nepal Journal of Neuroscience*, 13:73-80.
 18. **Arnautovic K, Arnautovic A (2009):** Extramedullary intradural spinal tumors: a review of modern diagnostic and treatment options and a report of a series. *Bosn J Basic Med Sci.*, 9(1):40-5.
 19. **Nair S, Menon G, Rao R et al. (2009):** Essential practice of neurosurgery. Kalangu K, Kato Y, Dechambenoit G (eds). Spinal tumors. Access publishing Co. Ltd, Nagoya, Japan. Pp. 1967-71. <https://www.worldcat.org/title/essential-practice-of-neurosurgery/oclc/703359565>
 20. **Stein B, McCormick P (1996):** Spinal intradural tumors. In: *Neurosurgery*; Wilkins R, Rangachary S (eds). 2nd ed. McCraw hill, New York. pp. 1769-81.
 21. **Gu R, Liu J, Zhang Q et al. (2014):** MRI diagnosis of intradural extramedullary tumors. *J Cancer Res Ther.*, 10:927-31.
 22. **Schroth G, Thorn A, Guhl L et al. (1987):** Magnetic resonance imaging of spinal meningiomas and neurinomas. Improvement of imaging by paramagnetic contrast enhancement. *J Neurosurgery*, 66:695-700.
 23. **Lee S, Jahng T, Kim H (2015):** Different surgical approaches for spinal schwannomas: a single surgeon's experience with 49 consecutive cases. *World Neurosurg.*, 84:1894-902.
 24. **Naganawa T, Miyamoto K, Hosoe H et al. (2011):** Hemilaminectomy for removal of extramedullary or extradural spinal cord tumors: medium to long-term clinical outcomes. *Yonsei Med J.*, 52:121-9.
 25. **Iacoangeli M, Gladi M, Di Rienzo A et al. (2012):** Minimally invasive surgery for benign intradural extramedullary spinal meningiomas: experience of a single institution in a cohort of elderly patients and review of the literature. *Clin Interv Aging*, 7:557-64.
 26. **Prada F, Vetrano I, Filippini A et al. (2014):** Intraoperative ultrasound in spinal tumor surgery. *J Ultrasound*, 17(3):195-202.
 27. **Ogden A, Schwartz T, McCormick P (2011):** Spinal cord tumors in adult. In. *Youmans Neurological Surgery*. Winn H (ed). Vol 3. 6th ed. Elsevier Saunders, Philadelphia, USA. pp. 3131-3153. <https://www.elsevier.com/books/youmans-and-winn-neurological-surgery/978-0-323-66192-8>
 28. **Korn A, Halevi D, Lidar Z et al. (2015):** Intraoperative neurophysiological monitoring during resection of intradural extramedullary spinal cord tumors: experience with 100 cases. *Acta Neurochir.*, 157:819-30.
 29. **Sala F, Bricolo A, Faccioli F et al. (2007):** Surgery for intramedullary spinal cord tumors: the role of intraoperative (neurophysiological) monitoring. *Eur Spine J.*, 16(2):130-9.
 30. **Nizami F, Mustafa S, Nazir R et al. (2017):** Intradural extramedullary spinal cord tumors: surgical outcome in a newly developed tertiary care hospital. *International Journal of Scientific Study*, 5(9):48-53.
 31. **Patel P, Mehendiratta D, Bhambhu V et al. (2021):** Clinical outcome of intradural extramedullary spinal cord tumors: A single-center retrospective analytic study. *Surg. Neurol Int.*, 12:145. doi: 10.25259/SNI_839_2020.