

# EVALUATION OF MELATONIN AND HYALURONIC ACID IN MAXILLARY SINUS AUGMENTATION (A RANDOMIZED CONTROLLED CLINICAL TRIAL)

Maria R. Gendi<sup>1\*</sup> BDS, Mervat M. Khalil<sup>2</sup> PhD, Gaafar N. El Halawani<sup>3</sup> PhD

## ABSTRACT

**INTRODUCTION:** Rehabilitation of maxillary posterior region with endosseous implants is complicated in the presence of insufficient residual alveolar ridge and maxillary sinus pneumatization. New bone formation without any bone grafting materials has achieved promising results in sinus augmentation. Melatonin and hyaluronic acid suggest satisfying results in enhancing bone defect repair, osseointegration of dental implants.

**OBJECTIVES:** To evaluate the effectiveness of melatonin and hyaluronic acid combination on bone regeneration in maxillary sinus augmentation.

**MATERIALS AND METHODS:** 16 patients with missed maxillary posterior teeth indicated for sinus augmentation were divided equally into; group I, received melatonin and hyaluronic acid after sinus membrane elevation with simultaneous implant placement, and group II, did not receive any materials after the procedure. Clinical evaluation were done for pain, swelling, complications, and implant stability and radiographically for vertical bone height gain, bone density, and marginal bone level.

**RESULTS:** There was a significant increase in bone density on the 1st and 6th months postoperatively in each group and between both groups ( $p \leq 0.05$ ). Regarding vertical bone height gain and implant stability, there was significant increase in each group, whereas the increase was insignificant between both groups. Marginal bone level difference between both groups was insignificant. Sinus membrane perforation occurred in one case only which did not affect the procedure completion; and there was no failure or complications along the follow up periods.

**CONCLUSION:** Melatonin and hyaluronic acid could have a considerable properties regarding bone density in sinus augmentation without complications.

**KEYWORDS:** Melatonin; Hyaluronic acid; Sinus augmentation.

**RUNNING TITLE:** Melatonin and hyaluronic acid in maxillary sinus augmentation.

1 BDS, 2013, Faculty of Dentistry, Alexandria University, Egypt.

2 Professor of Oral and Maxillofacial Surgery, Department of Oral and Maxillofacial Surgery Faculty of Dentistry, Alexandria University, Egypt.

3 Lecturer of Oral and Maxillofacial Surgery, Department of Oral and Maxillofacial Surgery Faculty of Dentistry, Alexandria University, Egypt.

\* Corresponding Author:

E-mail: [doctor.maria@yahoo.com](mailto:doctor.maria@yahoo.com)

## INTRODUCTION

Restoring the posterior maxilla with successful dental implants is controversial, because of inadequate residual bone dimensions and maxillary sinus pneumatization (1). Therefore, sinus augmentation is considered an option to overcome such problems (2).

Maxillary sinus augmentation could be done through either lateral window or trans-crestal approaches (3). Superior results were reported for the lateral window approach including a wider range of indications and more advanced biological examination of the variables affecting the newly formed bone which can reach a higher average of bone gain as 6.2 mm (4). Regarding intraoperative complications, the piezoelectric bone-cutting instrument and the lateral trap-door window approach together with a simultaneous implant placement can reduce the possibility of occurrence (5, 6).

Maxillary sinus augmentation with simultaneous implant placement could be performed either by grafting or graftless techniques. In the graftless technique, the formation of the new bone depends on two main factors: a stable blood clot of the space left after sinus membrane elevation and the osteogenic potentiality of the sinus membrane. Although the graftless technique suggests reduced cost, less morbidity with

minimum infection rates compared with the grafted technique, other studies reported superior results for the grafting technique regarding implant stability, bone height, and bone density (7, 8). So, to improve the quality and the survival rate of the newly formed bone in the graftless-technique, different biomimetic agents were suggested such as enamel matrix derivatives, platelet-rich fibrin (PRF), melatonin, and others (9, 10).

Melatonin, or N-acetyl 5 methoxytryptamine, is a hormone synthesized and secreted mainly in the pineal gland (11). It is a biomimetic agent that has the ability to promote angiogenesis during bone defects repair (10, 12). Moreover, melatonin has an antioxidant and direct free radical scavenging actions that can inhibit bone resorption by interfering with the osteoclastic activity, besides the downregulation of the receptor activator of nuclear factor- $\kappa$ B ligand (RANKL)-mediated osteoclast formation and activation. On the other hand, melatonin helps in the bone formation process in several actions like promoting the osteoblast cell differentiation through stimulation of proliferation and synthesis of collagen type I, other bone matrix proteins, and bone markers such as osteocalcin as well as minimizing the period of cells differentiation from 21 to 12 days (13, 14). Also, it can enhance the implant stability in the posterior maxilla with better osseointegration (15).

However, melatonin needs a carrier to increase its half-life in circulation for a longer circulating period in tissues (16). Hyaluronic acid is an ideal carrier material for bone regeneration materials with sinus augmentation procedures. Hyaluronic acid (HA) or Hyaluronan is a naturally occurring high molecular weight linear polysaccharide. It is an unsulfated glycosaminoglycan formed of repeating units of d-glucuronic acid and N-acetyl-d-glucosamine that is synthesized in the extra-cellular matrix of connective tissue, synovial fluid, skin, and other tissues.

With cellular and extracellular interactions, interactions with growth factors and osmotic pressure regulation, and tissue lubrication, HA preserves the structural and homeostatic integrity of the tissues. Thus, it is regarded as an ideal biomaterial for different medical applications (17).

Owing to its manipulability, thickness, and biocompatibility, HA can support the regeneration material without displacement, and can increase the new osteoblasts' count (18). In addition, HA can induce bone formation with osteogenic substances such as bone morphogenetic protein-2 and osteopontin. Thus, bone deposition and remodeling in bone regeneration processes are accelerated in lesser time when added to autologous cortical bone (19, 20); Also, bone density was observed to be positively affected by HA (21). Recently, a mixture of melatonin and hyaluronic acid has been evaluated with favorable results observed related to its components' characteristics (22).

Therefore, in this study, the aim was to evaluate the clinical and radiographic effects of melatonin and hyaluronic acid mixture on bone formation in maxillary sinus augmentation.

## MATERIALS AND METHODS

Appropriate Institutional ethical clearance was obtained from the Research Ethical Committee, Faculty of Dentistry, Alexandria University. All participants were asked to sign a written informed consent after explaining the surgical and postoperative study protocol.

### Patients' Selection and Evaluation

#### Sample Size Calculation

Using PASS program version 20, a minimal hypothesized total sample size of 16 participants admitted to the outpatient clinic of Oral and Maxillofacial Surgery Department, Faculty of Dentistry, Alexandria University. The participants, who were divided into 2 groups, 8 per group, were needed to detect an assumed average proportional difference in the progress in osseointegration using the ISQ scale (Implant Stability Quotient) after using melatonin and hyaluronic acid in maxillary sinus augmentation (Study Group) compared to the (Control Group) taking in consideration 5% level of significance and 1% precision using Chi Square-test.

#### Randomization Technique and Allocation

The participants were randomly assigned using an online randomizer with a computer-generated list of random numbers to either test or control group. The allocation was performed by a trial independent individual and the allocation ratio was intended to be equal.

The inclusion criteria were: Patients age between (30 – 50) years, having an edentulous area with one or more posterior teeth with a residual bone height  $\geq 5$  mm, and adequate inter-occlusal space  $\geq 8$  mm.

The exclusion criteria were: Maxillary sinus diseases, previous sinus surgery like the Caldwell–Luc operation, history of chemotherapy or radiotherapy to the maxilla, presence of

Underwood's septa/severe sinus floor convolutions, a systemic disease affecting bone metabolism like uncontrolled diabetes mellitus, heavy smokers, and parafunctional habits.

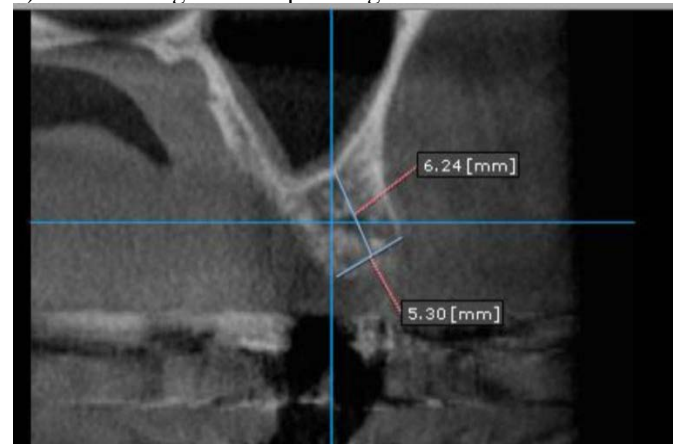
## Materials

1. Dentium super line implant system (Super Line dental implant, #214, 501 Gyeonggi R&DB Center, 105 Gwanggyo-ro) is a titanium implant with rounded apex consisting of the internal hex part to be coupled to the superstructure and the tapered Hybrid Double Thread™ part to be fixed to the bone.
2. Satelec Piezotome Cube with SL1 diamond tip from the Sinus Lift (SL) kit (ACTEON® group satalec, Merignac, France) is a piezoelectric device that uses a piezoelectric ceramic transducer to convert the electrical signal with frequency ranging from 28 to 36 kHz into ultrasonic mechanical micro-vibrations transmitted to a tip attached to the ultrasonic hand-piece under a continuous sterile cooling system with an irrigating solution (sterile saline) to allow bone cutting precisely at a frequency close to its relaxation frequency and minimize the injury possibility to the associated vessels and nerves.
3. Dentium Advanced Sinus Kit manual elevators from (DASK) system ( Dentium Advanced Sinus Kit,#214, 501 Gyeonggi R&DB Center, 105 Gwanggyo-ro, Yeongtong-gu, Suwon-si, Gyeonggi-do, Korea).
4. Melatonin 3 mg (Puritan's Pride Egypt).
5. 0.2% hyaluronic acid gel (Gengigel® Ricerfarma, Milano, Italy).
6. Bio-resorbable Collagen membrane (T-Gen, Alpha-Bio Tec Ltd., Korea).

## Methods

### Pre-operative Phase

Patients' history was checked in detail including personal data, medical and dental history. The edentulous area was examined for any horizontal or vertical defects as well as evaluating the overlying soft tissue. Primary alginate impressions were taken to record the jaw relationship and the inter-occlusal space on the study casts. A pre-operative Cone Beam Computed Tomography (CBCT) scan was taken to measure the distance between the alveolar crest and the sinus floor, ridge width, planning of implant size and position as well as detecting any sinus pathology, as shown in (Figure 1). Then scaling and root planning was done.



**Figure (1):** Preoperative CBCT (coronal cut) showing maxillary posterior alveolar ridge height and width.

### Surgical Phase

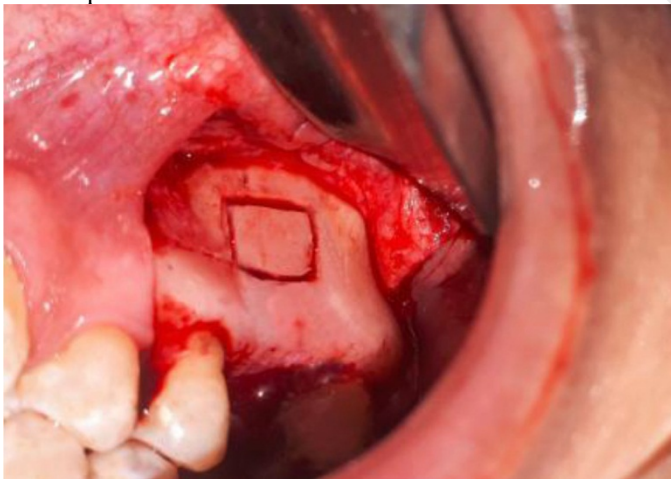
Before surgery, a 30-second rinsing with chlorhexidine gluconate 0.125% mouth wash (Hexitol mouthwash, Arab Drug Company, Cairo, Egypt) was performed.

All patients were operated on under local anesthesia using maxillary vestibular and palatal infiltration. Anterior vertical incision of at least 10–15 mm anterior to the wall of the sinus was done with a mid-crestal ridge incision using Bard-Parker blade number 15, and then reflection of a trapezoidal full-thickness mucoperiosteal flap was done.

A piezoelectric diamond-coated tip SL1, was attached to an ultrasonic piezoelectric hand-piece of the piezoelectric device to create the lateral trap-door window. The window outlines were determined as follows: the coronal outline depended on the implant length and the position of the posterior superior alveolar artery, the apical outline was about 3 mm above the sinus floor, the mesial outline was 2 mm distal to the anterior wall, and the distal outline followed the future implants number.

Sinus membrane elevation was performed using Dentium sinus lift kit manual elevators. The membrane elevation started from the sinus floor, posterior wall, anterior wall, and finally to the superior wall, with a slight elevation that keeps it attached to the underlying Schneiderian membrane to prevent any escape of the trap-door window into the sinus cavity. Also, manual elevators were used to guard and protect the membrane during drilling when implant osteotomies were done following the standard protocol, as shown in (Figure 2).

Then the selected implant was carried in place, and a titanium cover screw was inserted after measuring the implant stability with the Osstell ISQ using a smart peg that was matched with each implants size.

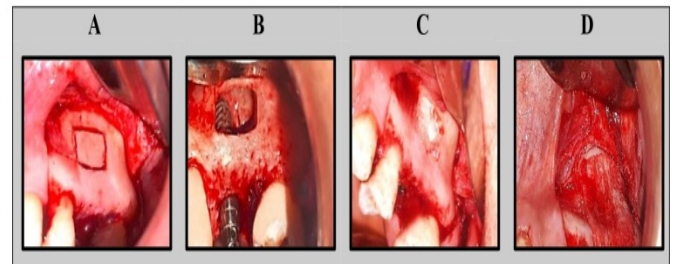


**Figure (2):** Showing DASK manual elevator guard during drilling.

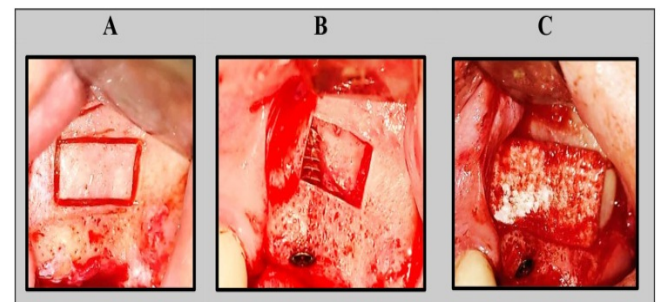
In group I, a 3 mg-melatonin tablets were crushed into powder and a 0.2%-hyaluronic acid gel was added to form a suitable mix. The mix was injected via a plastic syringe to fill the sinus space and around implant apex, whereas in group II the sinus space was left without placing any materials.

Moreover for both groups a bioresorbable collagen membrane (collagen membrane adheres directly over the bone without fixation screws) was used to close the window. The flap was

sutured at the end of the procedure with interrupted horizontal mattress sutures using 4/0 resorbable vicryl suturing material (ETHICON, Johnsons-Johnsson International, Belgium).( Figures 3, 4).



**Figure (3):** Showing study group: (A): lateral window outlines, (B): Implant in place with trap-door window, (C): Melatonin and hyaluronic acid mix in place, and (D): A bio-resorbable collagen membrane in place with self-adherence with no fixation aids.



**Figure (4):** Showing control group: (A): lateral window outlines, (B): Implant in place with trap-door window, and (C): A bio-resorbable collagen membrane in place with self-adherence with no fixation aids.

### Postsurgical Phase

All patients were advised to apply ice packs over the face for 10 min on and 10 min off a long the first 24 hours after surgery, elevate their head on 2 or more pillows on the first night of surgery. The diet was liquid only for 2 days then a soft diet for 14 days. Also, they were instructed to avoid chewing on the surgical site, blowing the nose, smoking, balloon blowing, sucking liquid with straw, flying in pressured aircraft or scuba diving, carbonated drinks (3 days), lifting of heavy weights during the first week after surgery, and to open the mouth during sneezing.

Postoperative medications were administrated as following: Amoxicillin 875 mg + Clavulanic acid 125 mg (Augmentin: Amoxicillin 875 mg + Clavulanic acid 125 mg: GlaxoSmithKline, UK) every 12 hours for 7 days, Diclofenac potassium 50 mg ( Cataflam: Diclofenac Potassium 50mg: Novartis-Switzerland) every 8 hours for 5 days, Chlorhexidine antiseptic mouth wash (Hexitol: Chlorhexidine 125mg/100ml, concentration 0.125%: Arabic drug company, ADCO, Cairo, Egypt), started on the second day 2 times daily for 14 days. Xylometazoline HCL 15 ml nasal spray every 8 hours for 7 days, and Otrivin: Xylometazoline HCL spray/nasal Drops 10 ml, Novartis Pharma AG, Basle, Switzerland).

## Post-operative Evaluation

### 1. Pain

Patients were evaluated clinically along the first week after surgery to assess pain using the 4 points of verbal descriptive scale including: no pain, mild, moderate, and severe (23).

### 2. Swelling

Patients were evaluated clinically along the first week after surgery to assess swelling as following: none (no inflammation), mild (intra-oral swelling confined to the surgical field), moderate (extra-oral swelling in the surgical zone) and severe (extra-oral swelling spreading beyond the surgical zone) (23).

### 3. Implant stability

Implant stability was recorded immediately and 6 months postoperatively using the Resonance Frequency Analysis via the Osstell ISQ system (Osstell®, integration Diagnostics AB, Goteborg, Sweden.).

### 4. Intra and post-operative complications

Any complications were identified and managed such as bleeding and sinus membrane perforation.

### Radiographic evaluation

It was done immediately, 1<sup>st</sup>, and 6<sup>th</sup> month postoperatively using Cone-beam computed tomography (On Diamond 3D App-DBM software system (Cybernet, Korea)) to measure:

#### 1. The vertical bone height gain

From the toolbar, the ruler was selected from the measurement section. From the cross-sectional view, the distance from the crestal bone at the implant platform and the bone apical to the implant apex (sinus floor) was calculated. Then, values of the native bone height were subtracted from that taken at the 1<sup>st</sup> and 6<sup>th</sup> months to reach the amount of bone height gain for each implant.

#### 2. The bone density in Hounsfield Unit (HU)

Three different cross-sections passing through each implant were taken, density values were measured within a predetermined fixed area within the newly formed bone, then the average density values were taken for each implant with bone density in a known measurement in Hounsfield Unit (HU).

#### 3. The marginal bone level

A standard implant length (10 mm) was used as a reference by adjusting the cross-sectional and panoramic long axis in the center of the implant and bisecting it (showing the buccolingual and mesiodistal dimensions). Mean, standard deviation, minimum and maximum readings were automatically displayed by the system.

As shown in (Figure 5, 6).

### Prosthetic Phase

After 6 months, the final abutment was placed, then a porcelain fused to metal restorations were cemented.

### Statistical analysis of the data (24)

Data were fed to the computer and analyzed using IBM SPSS software package version 20.0. (Armonk, NY: IBM Corp) Qualitative data were described using number and percent. The Kolmogorov-Smirnov test was used to verify the normality of distribution Quantitative data were described using range (minimum and maximum), mean, standard deviation, median and interquartile range (IQR). The Chi-square test was used to compare between two groups with

categorical variables, while the Fisher's Exact was used to correct for chi-square when more than 20% of the cells have expected count less than 5. With normally distributed quantitative variables, the Student t-test was used to compare between two studied groups, the Paired t-test was used to compare between two periods, the ANOVA with repeated measures to compare between more than two periods or stages, and Post Hoc test (Bonferroni adjusted) for pairwise comparisons. The significance of the obtained results was judged at the 5% level.

## RESULTS

In this study, 16 sinus augmentation procedures were done for 16 patients and equally divided into 2 groups, study and control groups. All patients were females between 30-50 years. Implants sites were: the first premolar, first molar, and maxillary second molar areas in both groups. in group I, 9 implants were placed in the study and in group II, 8 implants were placed. A standard implant length of 10 mm and a diameter range between 3.6 and 4 mm for both groups. Clinical and radiographic follow up for 6 months were done for all patients.

Only one case in group I had a sinus membrane perforation of < 2 mm which did not affect the procedure completion.

The mean height of the alveolar ridge from the marginal crest to the maxillary sinus floor in group I was  $5.44 \pm 0.47$  mm (Range 5.02 – 6.27 mm), while in group II, the mean height of the alveolar ridge from the marginal crest to the maxillary sinus floor was  $5.51 \pm 0.40$  mm (Range 5.07 – 6.24 mm).

### I. Clinical Evaluation

#### 1. Pain

For both groups, the pain was evaluated daily for seven days after surgery.

In **group I**, on the 1<sup>st</sup> day postoperatively, 7 patients experienced moderate pain, except for one patient who experienced severe pain. On the 2<sup>nd</sup>, 3<sup>rd</sup>, and 4<sup>th</sup> days, the experience of moderate pain decreased by 8, 3, and 0 patients respectively. Mild pain started from the 3<sup>rd</sup> day and lasted till the 6<sup>th</sup> day and was experienced by 3 patients on the 3<sup>rd</sup> day and decreasing from 8, 3, and 1 patient on the 4<sup>th</sup>, 5<sup>th</sup>, and 6<sup>th</sup> days respectively. On the 6<sup>th</sup> and 7<sup>th</sup> days, no patients experienced any pain, except for one who still experiencing mild pain till the 6<sup>th</sup> day.

In **group II**, on the first two days, all patients experienced moderate pain and only 2 patients continued to have moderate pain till the 3<sup>rd</sup> day. Mild pain was experienced by 6, 8, and 2 patients on the 3<sup>th</sup>, 4<sup>th</sup>, and 5<sup>th</sup> respectively. From the 5<sup>th</sup> day, 6 patients experienced no pain then nobody experienced any pain on the 6<sup>th</sup> and 7<sup>th</sup> days respectively.

#### 2. Swelling

For both groups, the swelling was evaluated daily for seven days after surgery.

In **group I**, on the first two days, all patients experienced moderate swelling and only 3 patients continued to have moderate swelling till the 3<sup>rd</sup> day. Mild swelling was experienced by 5 patients on the 3<sup>rd</sup> day, while in the 4<sup>th</sup> and 5<sup>th</sup> days it was experienced by all patients. On the 6<sup>th</sup> and 7<sup>th</sup> days,

all patients experienced no inflammation except for one patient who continued to have mild swelling till the 6<sup>th</sup> day.

In **group II**, on the first two days, all patients experienced moderate swelling and only 2 patients continued to have moderate swelling till the 3<sup>rd</sup> day. Mild swelling was experienced by 6 patients on the 3<sup>rd</sup> day, while in the 4<sup>th</sup> and 5<sup>th</sup> days it was experienced by all patients. On the 6<sup>th</sup> and 7<sup>th</sup> days, all patients experienced no inflammation.

For pain and swelling, there was no significant differences between both groups.

**3. Intra and Post-operative Complications**

No intra-operative complications were recorded regarding bleeding. Sinus membrane perforation occurred only in one case which did not affect the procedure completion. No post-operative complications were observed.

**4. Implant Stability**

In **group I**, the mean implant stability quotient (ISQ) was 56.13 ± 5.87 immediately postoperative and 74.63 ± 9.10 after 6 months.

In **group II**, the mean ISQ was 57.38 ± 5.24 immediately postoperative and 74.38 ± 7.61 after 6 months.

The increase in ISQ after 6 months in each group was statistically significant, but it was insignificant between both groups, as shown in (Table 1).

**Table (1):** Comparison between the two studied groups according to ISQ

ISQ	Group I (n = 8)	Group II (n = 8)	t	p
<b>Immediately postop</b>				
Min. – Max.	51.0 – 67.0	52.0 – 68.0		
Mean ± SD.	56.13 ± 5.87	57.38 ± 5.24	0.450	0.660
Median (IQR)	53.50 (51.5 – 60.5)	56.0 (53.50 – 60.0)		
<b>After 6months</b>				
Min. – Max.	63.0 – 87.0	65.0 – 86.0		
Mean ± SD.	74.63 ± 9.10	74.38 ± 7.61	0.060	0.953
Median (IQR)	73.0 (67.0 – 83.50)	71.0 (70.0 – 81.0)		
<b>p0</b>	<b>&lt;0.001*</b>	<b>&lt;0.001*</b>		

t: Student t-test

IQR: Inter quartile range

p: p value for comparing between the studied groups

p0: p value for **Paired t-test** for comparing between the studied periods

\*: Statistically significant at p ≤ 0.05

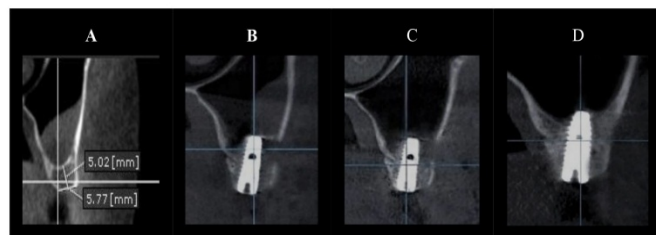
**II. Radiographic Evaluation (Figures 5, 6).**

**1. Vertical Bone Height Gain (VBHG)**

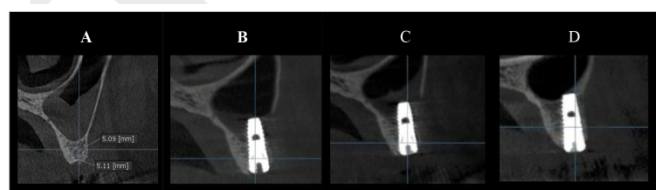
In **group I**, the mean increase in VBHG was (0.61 ± 0.17 mm) after 1 month and (5.05 ± 0.37 mm) after 6 months.

In **group II**, the mean increase in VBHG was (0.54 ± 0.10 mm) after 1 month and (5.04 ± 0.47 mm) after 6 months.

The increase in VBHG from the immediate postoperative (baseline), after 1 month and after 6 months was statistically significant in each group, but it was insignificant between both groups, as shown in (Table 2).



**Figure (5):** Showing CBCT (coronal cut) in study group: (A): Preoperative, (B): Immediate, (C): After 1 month, and (D): After 6 months postoperatively.



**Figure (6):** Showing CBCT (coronal cut) in control group: (A): Preoperative, (B): Immediate, (C): After 1 month, and (D): After 6 months postoperatively.

**Table (2):** Comparison between the different studied periods according to bone height gain in each group

Bone height gain	Immediate postop. (Baseline)	After 1 month	After 6 months	F	p
<b>Group I (n = 8)</b>					
Min. – Max.	5.09 – 6.83	5.65 – 7.58	9.82 – 12.37		
Mean ± SD.	5.84 ± 0.67	6.45 ± 0.76	10.89 ± 0.92	1105.38*	<0.001*
Median (IQR)	5.77 (5.25 – 6.39)	6.33 (5.79 – 7.06)	10.94 (9.98 – 11.54)		
<b>Sig. bet. periods</b>	p1<0.001*,p2<0.001*,p3<0.001*				
<b>Increase from Bas.</b>		<b>0.61 ± 0.17</b>	<b>5.05 ± 0.37</b>		
<b>Group II (n = 8)</b>					
Min. – Max.	5.0 – 6.40	5.59 – 6.93	9.94 – 11.50		
Mean ± SD.	5.66 ± 0.52	6.20 ± 0.49	10.70 ± 0.57	875.913*	<0.001*
Median (IQR)	5.67 (5.23 – 6.05)	6.12 (5.87 – 6.57)	10.67 (10.25 – 11.17)		
<b>Sig. bet. periods</b>	p1<0.001*,p2<0.001*,p3<0.001*				
<b>Increase from Bas.</b>		<b>0.54 ± 0.10</b>	<b>5.04 ± 0.47</b>		
<b>p0</b>		<b>0.339</b>	<b>0.963</b>		

F: F test (ANOVA) with repeated measures, Sig. bet. periods was done using Post Hoc Test (adjusted Bonferroni) IQR: Inter quartile range

p: p value for comparing between the studied periods

p0: p value for **Student t-test** for comparing between the studied groups

p1: p value for comparing between **Baseline** and **After 1 month**

p2: p value for comparing between **Baseline** and **After 6 months**

p3: p value for comparing between **After 1 month** and **After 6 months**

\*: Statistically significant at p ≤ 0.05

## 2. Bone Density (BD)

In **group I**, the mean increase in BD was ( $187.1 \pm 76.01$  HU) after 1 month and ( $343.6 \pm 39.40$  HU) after 6 months.

In **group II**, the mean increase in BD was ( $99.94 \pm 12.02$  HU) after 1 month and ( $166.4 \pm 35.64$  HU) after 6 months.

The increase in BD from the immediate postoperative (baseline) after 1 month and after 6 months was statistically significant in each group, also the difference in BD increase was statistically significant between both groups ( $p \leq 0.05$ ), with superior results regarding group I, as shown in (Table 3).

**Table (3):** Comparison between the different studied periods according to bone density in each group

Bone density	Immediate postop. (Baseline)	After 1 month	After 6 months	F	p
<b>Group I (n = 8)</b>					
Min. – Max.	303.8 – 539.8	394.8 – 810.4	620.0 – 850.1		
Mean $\pm$ SD.	420.2 $\pm$ 95.40	607.0 $\pm$ 154.2	763.9 $\pm$ 95.75	100.653*	<0.001*
Median (IQR)	411.4 (333.3–514.5)	619.8 (469.0–736.6)	795.3 (676.9–848.1)		
<b>Sig. bet. periods</b>	p1=0.001*,p2<0.001*,p3=0.003*				
<b>Increase from Bas.</b>		<b>187.1 <math>\pm</math> 76.01</b>	<b>343.6 <math>\pm</math> 39.40</b>		
<b>Group II (n = 8)</b>					
Min. – Max.	307.9 – 749.1	428.5 – 832.8	492.9 – 857.0		
Mean $\pm$ SD.	435.1 $\pm$ 139.6	535.1 $\pm$ 133.6	601.5 $\pm$ 122.0	152.151*	<0.001*
Median (IQR)	388.7 (363.7–459.6)	483.5 (463.8–562.3)	565.0 (522.8–643.1)		
<b>Sig. bet. periods</b>	p1<0.001*,p2<0.001*,p3=0.001*				
<b>Increase from Bas.</b>		<b>99.94 <math>\pm</math> 12.02</b>	<b>166.4 <math>\pm</math> 35.64</b>		
<b>p0</b>		<b>0.014*</b>	<b>&lt;0.001*</b>		

**F:** F test (ANOVA) with repeated measures, Sig. bet. periods was done using **Post Hoc Test (adjusted Bonferroni)**  
**IQR:** Inter quartile range

p: p value for comparing between the studied periodss

p0: p value for **Student t-test** for comparing between the studied groups

p1: p value for comparing between **Baseline** and **After 1 month**

p2: p value for comparing between **Baseline** and **After 6 months**

p3: p value for comparing between **After 1 month** and **After 6 months**

\*: Statistically significant at  $p \leq 0.05$

## 3. Marginal Bone Level (MBL)

The amount of MBL was evaluated by comparing the 1st month and 6th month postoperative periods after subtracting from the standard used implant length (10 mm).

In **group I**, the mean difference was ( $0.35 \pm 0.15$  mm) after 1 month and was ( $0.68 \pm 0.21$  mm) after 6 months

In **group II**, the mean difference was ( $0.35 \pm 0.16$  mm) after 1 month and was ( $0.72 \pm 0.24$  mm) after 6 months.

These differences were statistically significant in each group, but were insignificant between both groups.

## DISCUSSION

In this study, 16 patients with missed maxillary posterior teeth with insufficient vertical ridge height were selected to perform graftless sinus augmentation procedure using piezo-surgery with immediate implant placement, where melatonin and hyaluronic acid were used as a filling material to evaluate their effects on the bone regeneration procedure.

The minimum residual ridge height in our study was 5 mm which coincides with Mardinger et al study (25) that reported a greater success rates more than 98.7% when the remaining ridge height is  $> 4$  mm compared to lesser success rates as 92% for ridge height  $< 4$  mm.

Along the first week postoperatively, pain and swelling decreased significantly in each group, however there was no significant difference between the study and the control groups. This may be due to the use of piezo-surgery. These results match with Delilbasi et al (26) in 2013 who also reported less postoperative pain and swelling when compared between the piezo-surgery and the conventional rotary technique in a direct sinus lifting.

On the other hand, when compared with other studies, it was found to be controversial between studies regarding the hyaluronic acid effect on minimizing pain and swelling. Yilmaz et al (27) evaluated the effectiveness of 0.8% HA (Gengigel®) local application in impacted third molar sockets and measured pain, swelling, and trismus along the first week postoperatively. They found no significant difference between the study and the control groups in facial swelling. However, the amount of pain significantly reduced in HA groups. On contrast, in another study it was reported that 0.8% HA had an anti-inflammatory effect when it was applied immediately after third molar extraction. However, the clinical outcomes regarding pain has no significant differences between the study and control groups after one week (28).

In the present study, only one case exhibited a sinus membrane perforation in group I. It was  $< 5$  mm and represented (6.25%) of all cases. A bio-resorbable collagen membrane was used to repair the perforation with no complications signs along the next 6 months. Moutamed in 2017 (29) reported similar results when compared the sinus membrane perforation in maxillary sinus lifting surgery between the ultrasound and the conventional rotary technique. They reported less membrane perforations rates 9% with piezo-surgery compared to 18% with the conventional rotary DASK technique where a properly integrated implants with no future complications were observed.

In our study, the implant stability was measured using the Resonance Frequency Analysis (RFA) via the Osstell ISQ system, and there was a significant increase ISQ after 6 months for each group. This was explained by new bone apposition at the implant-bone interface (30).

On the contrary, there was no significant difference between both groups regarding implant stability, which means that the implants' primary stability was not affected by the melatonin and hyaluronic acid. In 2016, El Gammal et al (15) evaluated the local application of 1.2 mg/ mL of melatonin gel in the osteotomy site with immediate-loaded implants. The same results were reported regarding melatonin when compared between the melatonin group and the control group after 3, 6,

and 12 months and no significant difference was observed along these periods between groups.

As regarding hyaluronic acid, Taman et al (31) evaluated the effect of hyaluronic acid (Hyadent™) when mixed with autogenous bone graft in alveolar socket preservation, and reported that the ISQ intra-operatively and after 2 months did not affect by hyaluronic acid.

Vertical bone height gain increased significantly in each group after 1 and 6 months. However, there was no significant difference between the two groups. Lundgren et al in 2019 (32) explained the same findings when they evaluated the long-term effects of implants placed with graft-less sinus lifting, and concluded that the length of the implant protruding into the sinus cavity is the main factor that determine the amount of bone gain in graft-less technique, recording 10 times stronger than other significant variables.

Bone density in this study also showed a significant increase in each group along the follow-up periods, after 1 month and 6 months postoperatively.

Different studies discussed the bone density regarding melatonin and HA. Ramírez-Fernández, et al in 2013 (12) studied the radiological and histomorphometric effects of 1.2 mg lyophilized powder of melatonin (Sigma-Aldrich™-M5250) on angiogenesis during bone defect repair of rabbit tibiae. They found a higher density of the newly formed bone for the melatonin group on the histomorphometric analysis at 4 weeks and a total repair of the bone defects in rabbit tibiae radiographically. Also, in 2018, Alcântara et al (33) evaluated the effects of 1% HA gel on bone repair of human dental sockets and observed a significant difference in bone density between the HA-treated sockets and the control groups after 30 days of extraction.

Furthermore, our results were also in agreement with Taman et al (31) who revealed statistically significant radiographic bone density changes between the two studied groups after 2 months and concluded that hyaluronic acid was more efficient in osteoconduction when compared with autogenous bone graft alone in post-extraction socket preservation. On the contrast, Alcântara et al revealed that HA has no significant difference between the studied groups at 90 days effect of HA when compared the bone density of the extraction sockets using HA gel only (33). The conflict in this study is not an actual one because it only used HA without any other material, hence the results are not comparable to our study that supposes an important role of the association between HA and another material to increase the BD more than one month.

The significant increase found in group II on the 1st and 6th months were supported by the results of Altintas et al in 2013 (34) who examined the density of the newly formed bone after sinus membrane elevation, with and without bone grafting where the bone density in the non-grafted group showed significant differences starting from 1<sup>st</sup> week to 6<sup>th</sup> month postoperatively.

Bone density measurements have shown a remarkable scores with a significant difference between both groups at ( $p \leq 0.05$ ) along the follow up intervals where the superior results were reported for the study group.

The inferior results in group II regarding the increase in BD in our study was in agreement with Fouad et al., (8) who evaluated the difference between the use of xenograft and graftless tenting technique after sinus lift procedure with simultaneous implant placement, and they reported better results in the grafted group when compared with the graftless group; however, the graftless-technique is considered a reliable procedure for sinus lifting with simultaneous implant placement.

To the best of our knowledge, melatonin and hyaluronic acid effects on bone density after 6 months were not studied before. So, we suggest more clinical and radiographic studies especially on bone density for a longer follow-up periods.

MBL changes in this study after 6 months were ( $0.68 \pm 0.21$  mm) in group I and were ( $0.72 \pm 0.24$  mm) in group II. These results were supported by Galindo-Moreno et al (35) whose study was to evaluate MBL rates around implants to find the difference between physiological bone loss and to peri-implantitis' bone loss. They found that despite the reported survival rates of dental implants, there is range of a bone loss around implants from 1.5 to 2 mm during the first year of functional loading.

## CONCLUSION

Within the limited sample size of this study, melatonin and hyaluronic acid mixture may not share any superior effects as a filling material in maxillary sinus augmentation procedure regarding pain, swelling, implant stability, alveolar bone height gain, and marginal bone level. However, this mixture suggest promising effects that can highly enhance bone density without any complications.

### Conflict of interest

The authors declare that they have no conflicts of interest.

### Funding

The authors received no specific funding for this work.

## REFERENCES

1. Irinakis T. Efficacy of injectable demineralized bone matrix as graft material during sinus elevation surgery with simultaneous implant placement in the posterior maxilla: clinical evaluation of 49 sinuses. *J Oral Maxillofac Surg.* 2011;69:134-41.
2. Bechara S, Kubilius R, Veronesi G, Pires JT, Shibli JA, Mangano FG. Short (6-mm) dental implants versus sinus floor elevation and placement of longer ( $\geq 10$ -mm) dental implants: a randomized controlled trial with a 3-year follow-up. *Clin Oral Implants Res.* 2017;28:1097-107.
3. Stern A, Green J. Sinus lift procedures: an overview of current techniques. *Dent Clin North Am.* 2012;56:219-33.
4. Parra M, Atala-Acevedo C, Fariña R, Haidar ZS, Zaror C, Olate S. Graftless Maxillary Sinus Lift Using Lateral Window Approach: A Systematic Review. *Implant Dent.* 2018;27:111-8.
5. Kao SY, Lui MT, Cheng DH, Chen TW. Lateral trap-door window approach with maxillary sinus membrane lifting for dental implant placement in atrophied edentulous alveolar ridge. *J Chin Med Assoc.* 2015;78:85-8.

6. D'Amato S, Sgaramella N, Tartaro G, Santagata M. A modified graftless sinus lift: case report. *J Osseointegr*. 2019;11:7-10.
7. Cara-Fuentes M, Machuca-Ariza J, Ruiz-Martos A, Ramos-Robles MC, Martínez-Lara I. Long-term outcome of dental implants after maxillary augmentation with and without bone grafting. *Med Oral Patol Oral Cir Bucal* 2016;21:e229-35.
8. Fouad W, Osman A, Atef M, Hakam M. Guided maxillary sinus floor elevation using deproteinized bovine bone versus graftless Schneiderian membrane elevation with simultaneous implant placement: Randomized clinical trial. *Clin Implant Dent Relat Res*. 2018;20:424-33.
9. Amaral FGD, Cipolla-Neto J. A brief review about melatonin, a pineal hormone. *Arch Endocrinol Metab* 2018;62:472-79.
10. Yousef DA, Al Hessy AA, Saeed AA, El Shamy ES. Nanohydroxyapatite versus melatonin loaded on nanohydroxyapatite and nanohydroxyapatite with platelet rich fibrin on the treatment of intrabony defects. *Tanta Dent J*. 2018;15:148-63.
11. Tan DX, Manchester LC, Terron MP, Flores LJ, Reiter RJ. One molecule, many derivatives: a never-ending interaction of melatonin with reactive oxygen and nitrogen species? *J Pineal Res*. 2007 Jan;42:28-42.
12. Ramírez-Fernández MP, Calvo-Guirado JL, de-Val JE, Delgado-Ruiz RA, Negri B, Pardo-Zamora G, et al. Melatonin promotes angiogenesis during repair of bone defects: a radiological and histomorphometric study in rabbit tibiae. *Clin Oral Investig*. 2013;17:147-58.
13. Permuy M, López-Peña M, González-Cantalapiedra A, Muñoz F. Melatonin: A Review of Its Potential Functions and Effects on Dental Diseases. *Int J Mol Sci* 2017;18:865.
14. López-Martínez F, Olivares Ponce PN, Guerra Rodríguez M, Martínez Pedraza R. Melatonin: Bone metabolism in oral cavity. *Int J Dent* 2012;2012:628406.
15. El-Gammal MY, Salem AS, Anees MM, Tawfik MA. Clinical and Radiographic Evaluation of Immediate Loaded Dental Implants With Local Application of Melatonin: A Preliminary Randomized Controlled Clinical Trial. *J Oral Implantol*. 2016;42:119-25.
16. Muñoz F, López-Peña M, Miño N, Gómez-Moreno G, Guardia J, Cutando A. Topical application of melatonin and growth hormone accelerates bone healing around dental implants in dogs. *Clin Implant Dent Relat Res*. 2012;14:226-35.
17. Dahiya P, Kamal R. Hyaluronic Acid: a boon in periodontal therapy. *N Am J Med Sci* 2013;5:309-15.
18. Claar M. Hyaluronic acid in oral implantology. *EDI Case Studies* 2013;4:64-8.
19. Ballini A, Cantore S, Capodiferro S, Grassi FR. Esterified hyaluronic acid and autologous bone in the surgical correction of the infra bone defects. *Int J Med Sci*. 2009;6:65-71.
20. Zaffe D, D'Avenia F. A novel bone scraper for intraoral harvesting: a device for filling small bone defects. *Clin Oral Impl Res* 2007;18:525-33.
21. Gontiya G, Galgali S. Effect of hyaluronan on periodontitis: Clinical and histological study. *J Indian Soc of Periodontol* 2012;16:184-92.
22. Cristiche CM, Totu EE, Cristache G, Nechifor AC, Pintilie II. Melatonin and Hyaluronic Acid in Periodontal Disease. *Rev Chim (Bucharest)*. 2019;70:1089-93.
23. Penarrocha M, Garcia B, Marti E, Balaguer J. Pain and inflammation after periapical surgery in 60 patients. *J Oral Maxillofac Surg*. 2006;64:429-33.
24. Kotz S, Read CB, Vidakovic B, Balakrishnan N. *Encyclopedia of statistical sciences*. 2<sup>nd</sup> ed. Hoboken, N.J.: Wiley-Interscience; 2006.
25. Mardinger O, Chaushu G, Sigalov S, Herzberg R, Shlomi B, Schwartz-Arad D. Factors affecting changes in sinus graft height between and above the placed implants. *Oral Surg Oral Med Oral Pathol Oral Radiol Endod*. 2011;11:6-11.
26. Delilbasi C, Gurler G. Comparison of Piezosurgery and Conventional Rotative Instruments in Direct Sinus Lifting. *Implant Dent*. 2013;22:662-5.
27. Yilmaz N, Demirtas N, Kazancioglu HO, Bayer S, Acar AH, Mihmanli A. The efficacy of hyaluronic acid in postextraction sockets of impacted third molars: A pilot study. *Niger J Clin Pract*. 2017;20:1626-31.
28. Gocmen G, Gonul O, Oktay NS. The antioxidant and anti-inflammatory efficiency of hyaluronic acid after third molar extraction. *J Craniomaxillofac Surg* 2015;43:1033-7.
29. Moutamed GM. Prevalence of schneiderian membrane perforation during maxillary sinus augmentation procedures using ultrasound versus rotary techniques. *Egypt Dent J*. 2017;36:1321-32.
30. Sim CP, Lang NP. Factors influencing resonance frequency analysis assessed by Osstell mentor during implant tissue integration: I. Instrument positioning, bone structure, implant length. *Clin Oral Implants Res*. 2010;21:598-604.
31. Taman RA, Fahmy MH, Karam SS, EL Ashwah AA. Post-extraction socket preservation with autogenous bone graft and hyaluronic acid followed by delayed implant placement. *Alex Dent J*. 2017;42:170-6.
32. Lundgren S, Johansson AS, Cricchio G, Lundgren S. Clinical outcome and factors determining new bone formation in lateral sinus membrane elevation with simultaneous implant placement without grafting material: A cross-sectional, 3-17 year follow-up study. *Clin Implant Dent Relat Res*. 2019;21:827-34.
33. Alcântara CEP, Castro MAA, Noronha MS, Martins-Junior PA, Mendes RM, Caliari MV, et al. Hyaluronic acid accelerates bone repair in human dental sockets: a randomized triple-blind clinical trial. *Braz Oral Res*. 2018;32:e84.
34. Altintas NY, Senel FC, Kayıpmaz S, Taskesen F, Pampu AA. Comparative radiologic analyses of newly formed bone after maxillary sinus augmentation with and without bone grafting. *J Oral Maxillofac Surg*. 2013;71:1520-30.
35. Galindo-Moreno P, Leon-Cano A, Ortega-Oller I, Monje A, F OV, Catena A. Marginal bone loss as success criterion in implant dentistry: beyond 2 mm. *Clin Oral Implants Res*. 2015;26:28-34.