

COMPUTER GUIDED INFERIOR ALVEOLAR NERVE LATERALIZATION AFTER REPOSITIONING OF THE BONE WINDOW VERSUS STICKY BONE AUGMENTATION (A RANDOMIZED CLINICAL TRIAL)

Dina M.N. Metawie^{1*} Msc, Nagy H. Elprince² PHD, Mageud H. Fahmy² PHD, Riham M. Eldibany², Ibrahim K. Ibrahim³

ABSTRACT

INTRODUCTION: Atrophy of the posterior mandible present a challenge due to the existence of inferior alveolar nerve. Nerve lateralization is one of the options that allow placement of the implants without augmentation. Modifications to decrease the incidence of neurosensory disturbances has been attempted.

OBJECTIVES: The primary outcome was to evaluate the recovery of the sensation following computer guided nerve lateralization with two modifications. In addition, implant success was secondarily evaluated.

MATERIALS AND METHODS: A randomized clinical trial conducted on a sample of twenty patients. Ten were treated via computer guided lateralization with repositioning the osteotomy window. The other ten via computer guided nerve lateralization with sticky bone augmentation around the implants and the nerve. Postoperative patient evaluation was performed with specific attention paid towards objective and subjective testing of the neurosensory disturbance following surgery as well as implant clinical and radiographic success.

RESULTS: All patients in both groups reported neurosensory disturbance as revealed by subjective and objective testing which were all temporary with 100% recovery after 6 months regardless of whether the window was placed or grafting around the implant with sticky bone. Clinical and radiographic evaluation of implants revealed success in terms of implant stability, probing depth, bleeding on probing.

CONCLUSION: Neurosensory recovery and Implant success is observed whether sticky bone is used around the implant or after repositioning the bone window. Blink reflex is a useful objective non-invasive modality. Professionals should be aware that the technique is very sensitive and requires gentle manipulation and good experience of the anatomy in order to avoid permanent damage to the nerve.

KEYWORDS: Inferior Alveolar nerve, lateralization, sticky bone, computer guided surgery.

1 Assistant Lecturer of Oral and Maxillofacial Surgery, Faculty of Dentistry, Alexandria University.

2 Professor of Oral and Maxillofacial Surgery, Faculty of Dentistry, Alexandria University.

3 Professor of Physical Medicine Department, Faculty of Medicine, Alexandria University.

*Corresponding Author:

dina.nader@alexu.edu.eg

INTRODUCTION

Management of posterior mandibular atrophy have been described in literature by several techniques. Techniques that augment the remaining bone such as; onlay block grafting(1), guided bone regeneration (GBR)(2) and distraction osteogenesis.(3) On the other hand, techniques utilizing the pristine remaining bone such as the usage of short implants(4) and nerve repositioning procedures(5) have been described as well. Each technique has its for and against with no single technique proofing to be superior over the other according to a recent systematic review.(6)

Inferior alveolar nerve repositioning (IAN) is a surgical technique that allows for the placement of dental implants in severely atrophied posterior mandible. It has been used for rehabilitation of posterior atrophic mandible as an alternative to short implants or bone grafts.(7) It can be performed by either of these two techniques: lateralization and transposition. In lateralization, the nerve is exposed via a bone window osteotomized posterior to the mental foramen to allow for mobilization of the nerve from the canal, while with the transposition technique, an additional osteotomy around the mental foramen is done, then sectioning

the incisive branch to allow mobilization of both alveolar and mental nerves.

Nerve lateralization has an advantage of; allowing for the placement of longer implants which will be able to engage the two cortices, thus, greater primary stability is achieved. The immediate placement of implants during the procedure allows for a reduction in the treatment time. In addition, using longer fixture have a biomechanical advantage; allowing good proportions between the prosthesis and the implant as well as increased resistance to occlusal forces.(8)

On the other hand, the major deficiency is its high risk for sensory disturbances as well as temporarily mandibular weakening increasing the risk of its fracture. (9)

Several modifications have been advocated to decrease the incidence of the neurosensory disturbances occurring after the procedures. The use of cone-beam computed tomography (CBCT) imaging helps to diagnose and treat bone deficiency and idealize implant positioning thereby, Atef et al (2018) introduced a novel method for IAN lateralization by using a customized 3D printed surgical guide. This allows for an easier, less invasive, more accurate surgical technique, that will preserve the bone height for implant placement.(10)

Another controversial topic is the interface between the nerve and the implant. The use of a barrier such as a collagen membrane or bone graft at the nerve – implant interface to avoid the nerve intimate contact with the threads of an implant have been recommended.(11) According to our knowledge the literature is inconclusive about their effect on neurosensory disturbances.

In addition, some studies argued about the effect of repositioning and fixation of the osteotomized bone window as it may cause compression on the neurovascular bundle. They recommended to place it passively, without any fixation.(12)

Among the modifications done in search for a way to minimize the post- surgical neurosensory complications is the adjuvant use of regenerative techniques. Recently, it has been reported the promising effects of growth factors on promoting nerve regeneration and healing. (13) Sticky bone is obtained by mixing autologous fibrin glue (AFG) prepared from the patient's own blood with a bone graft. The resultant solidified bone graft entraps platelets within its fibrin network which are rich in growth factors. (14)

In recent literature, there is no evidence of an agreement for a standardized testing method of IAN injury. Several studies report the use of clinical neurosensory tests (CNT); however, the number of tests used and the methods vary widely in the reported literature.(15)

The CNT, in most of the studies, is considered "objective", although in reality, they are "subjective" requiring a patient response. In contrast, few purely objective tests have shown to have high sensitivity in grading and diagnosing inferior alveolar nerve injuries these include; neurophysiologic tests such as nerve conduction study and mental nerve blink reflex and thermal quantitative sensory testing QST. Also, there are little data on the patterns of responses to these objective tests based on specific types of nerve injuries.(15,16)

In this study an objective tool along with clinical neurosensory testing, the mental nerve blink reflex (MNBR), is utilized as an objective tool to quantify the amount of neurosensory recovery after each lateralization process.

Our study was focused on evaluation of the neurosensory recovery following IAN lateralization done by two different modifications which are; repositioning the bone block versus grafting the site with sticky bone. The secondary aim was to evaluate the clinical and radiographic success of the implants placed using these two modifications.

MATERIALS AND METHODS

Study design: A prospective randomized clinical trial performed from October 2018 to December 2020 according to the CONSORT guidelines. The study was registered in clinicaltrials.gov (ClinicalTrials.gov Identifier: NCT04590339). The clinical part of the study commenced after the ethical clearance from the Research Ethics Committee, Faculty of Dentistry, Alexandria University (Protocol ID: 0010556-IORG 00088390). All patients were informed of the risk of postoperative neurosensory disturbance with alteration of sensation in the lower lip and /or the chin post-operatively. All patients signed an Informed Consent Form before undergoing the operation.

Twenty patients underwent this study. The sample size of 10 patients per group (total sample size =20) was the enough required sample for the study, as a statistical significance with 80% power ($\beta=20\%$) and at a significance level of 95% ($\alpha=0.05$) with no need to be increased to control for attrition bias.(17)

Participants were selected from the the Out-Patient Clinic of the Oral and Maxillofacial Surgery Department, Faculty of Dentistry, Alexandria University. All patients were operated upon under General Anaesthesia in the Oral and Maxillofacial Surgery Department, Faculty of Dentistry, Alexandria University.

Inclusion criteria: All patients aged between 25 to 60 years presented with posterior atrophic mandibular edentulism, having < 8 mm of

bone above the mandibular canal and > 4 mm of ridge width were included in this study.

Exclusion criteria: Patients were excluded if they have any absolute contraindication for implant surgery such as uncontrolled diabetes mellitus, blood and/or bleeding disorders, serious osseous defects, patients suffering from relevant systemic disease directly affecting bone metabolism and healing or have a history of any grafting procedure at the designated area and patient with thick cortical bone buccally and a thin neurovascular bundle.

After sample selection according to the inclusion and exclusion criteria; the patients were randomly allocated by a web-based software (www.randomizer.at)(18) into two groups each group consisting of 10 patients: group I (10 patients) underwent computer guided inferior alveolar nerve lateralization and implant placement with subsequent repositioning of the osteotomized bone window and group II (10 patients) underwent computer guided inferior alveolar nerve lateralization and implant placement with grafting around the implant using sticky bone.

Presurgical Phase

Clinical examination

A complete history was taken for all the patients including all personal information, chief complain, medical and dental histories.

Local visual examination, palpation of the entire oral tissues and evaluation of the implant receiving site were performed to ensure right selection of the patient.

Radiological examination

Cone beam computed tomography (CBCT) was done for every patient pre-operatively to measure; the alveolar bone height superior to the mandibular canal, the distance from alveolar crest to the upper border of the canal and the alveolar bone width measured at the upper part of the alveolar bone.

Construction of the surgical guide Fig.(1)

The Dicom files for each patient were imported into a surgical planning computer software (Blueskybio). Nerve localization and tracing was done followed by prosthetically driven planning for the implant in all 3 planes on the blueskybio software.

The STL files were imported into a computer-aided design software (3Matic, Materialise) to create the design of the surgical guide. The outline for the guide was drawn on the surface of the posterior mandibular region. The superior and inferior osteotomy channels were drawn to be 2 mm above and 2 mm below the traced nerve and then were subtracted from the virtual guide body. The position of the implants was designated by guiding channels constructed on the same guide.

Stereolithography technology was used for fabrication of the surgical guide. The STL files

were sent to a 3D printing lab for manufacturing using a fused deposition modeling machine from a sterile plastic material.

Surgical technique fig(2)

All patients were operated under general anesthesia using nasal Intubations

A para-crestal incision was done and a mucoperiosteal flap was reflected exposing the alveolar ridge and the buccal cortex. The incision extending beyond the anticipated site of the osteotomy with at least 1 cm, dissection below the neurovascular bundle was performed to increase the flap relaxation and improve exposure.

The surgical guide was fitted in place and the outline of the window was done guided by the surgical guide using the piezotome. The bone surgery kit was used for the osteotomy of the window, Once the osteotomy is completed and the bone window was mobilized for exposure of the neurovascular bundle. The diamond tips were used for removal of any remaining bone around the nerve.

The surgical guide was reinserted in place for implant site preparation with the nerve retracted using a special retractor.

The implant site was prepared by sequential drilling with each drill through its own sleeve. Followed by insertion of the implant fixture. The primary stability of each implant was measured using Resonance Frequency Analyzer (RFA) Osstell ISQ, Göteborg, Sweden.

For group (A) Fig(3)

After implant placement, a piece of a thin collagen membrane was placed between the implant surface and the nerve bundle.

The bone window was reduced from inside to avoid exerting pressure on the nerve. The scrapped bone is placed around the implant.

The bone window was then repositioned in place, then the flap was repositioned and sutured.

For group (B) Fig(4)

A bone graft (Biphasic calcium phosphate bone graft (OVIS Bone BCP, DENTIS Co., USA) along with the bone scraped from the bone window is then mixed with autologous fibrin glue (AFG) for preparation of sticky bone, which was prepared as follows;

- 20 cc of the patient venous blood was collected and put into non-coated test tubes.
- The blood was centrifuged at 2700 rpm for 3 minutes.
- The tube showed 2 different layers. The upper layer is autologous fibrin glue (AFG) layer which was obtained with syringe and mixed with particulate bone and left for 5-10 minutes for polymerization in order to produce sticky bone, the bottom layer of red blood cell was discarded.
- The bone graft was placed around the implant, the nerve was repositioned and the rest of the bone graft was added to restore the contour of the

mandible and covered by the collagen membrane then, the flap was repositioned and sutured.

Post-operative instructions

The patients were admitted for 24 hour observation and were discharged the following day. Cold compression was applied for 20 min every hour for 24 hours to control the edema.

Postoperative medications including antibiotic Amoxicillin + clavulanate 1 gm every 12 hours for 1 week (Augmentin, GlaxoSmithKline, UK), Ibuprofen 400 mg every eight hours (Brufen, Kahira Pharm. & Chem. Ind. Co., Egypt) and chlorhexidine hydrochloride 125mg oral rinse three times daily for 2 week (Hexitol, Arab drug Co., Egypt)

Long acting corticosteroid methylprednisolone 8mg/ml given IM every 12 hours in the first 24 hours then half the dose in the next 24 hours (Dexamethasone, Sigmatec, Egypt). Then, Chymotrypsin (Alphintern, Amoun Pharmaceutical Company, Egypt) every eight hours before meal for 1 week.

Patients were kept on a fluid diet for the first 24 hours, and then a soft diet for the following two weeks with activity restrictions to avoid any trauma to the mandible.

Post-operative evaluation

Evaluation of the implant success and survival
Monitoring the success of the implant was done clinically by mean of;

Assessment of implant stability using osstell device. For each implant, the stability was measured by means of the osstell device to obtain an Implant stability quotient (ISQ) value, immediately after implant placement, then at 3 and 6 months. A measurement scale for Implant stability quotient (ISQ) from 1-100 is used, in which, $ISQ \leq 60$ low stability, $ISQ 60-69$ medium stability and $ISQ \geq 70$ High stability.

Peri-implant probing depth according to Glavind and Loe (19). The probing depth was measured in mm using a periodontal probe at 3 and 6 months.

Modified Gingival Index according to Mombelli et al.(20) Assessment of the marginal mucosal condition around the implants was done by using the modified gingival index (mGI) at 3 and 6 month.

When more than one implant was placed, the mean of both readings was taken.

Monitoring the success of the implant was done radiographically by mean of;

The marginal bone level and the bone density which were assessed from a cone beam computed tomography done post-operatively at 3 and 6 months with postoperative CBCT as a base line.

Assessment of the neurosensory recovery

A series of Subjective and objective tests were performed to evaluate the recovery of sensation.

Clinical Neurosensory Testing CNT

CNT of the IAN function was performed post-operatively, 1 week after surgery, one month, 3 month and 6 months.

Four tests were made which are; Static light touch test, brush stroke directional test, Pin prick test and two-point discrimination test. Patients were seated comfortably in a quiet room with their eyes closed throughout the procedures. The affected area was outlined, and the degree of involvement within the affected area was tested with normal side taken as a control. Fig (5) The patients were asked about the resolution of tingling or numbness sensations, their distribution and duration. The scale used for static light touch, brush stroke and pain tests ranged from 0-2, where 0= no sensation 1= decreased sensation and 2= normal sensation. For two-point discrimination, scoring from 0-2 in which; 0=>15 mm, 1= 8-15 mm and 2= < 8 mm.

The test results were correlated to The modified Medical Research Council (MRC) scale Table(1). (21) which can measure recovery of nerve function. The scale ranges from a score of S0 (no improvement) to S4 (complete recovery). For peripheral nerve injuries, a score of S3 or higher has been defined as "useful sensory function" (USF).

Objective testing

Mental nerve blink reflex (MN BR) is a brainstem reflex evoked with stimulation of different branches of the trigeminal nerve resulting in contraction of the eye closing muscles on both sides. It has been proposed as a method for evaluating trigeminal (V) nerve. It was used as an objective test for the nerve function and was used to evaluate the progress of sensory gain post-operatively. In the present study, the responses to an electrical stimulus given to the center of the mental nerve distribution with a small bipolar stimulating electrode were recorded bilaterally using NIHON KOHDEN apparatus for electrophysiological studies (neuropack2 MEP-7102K, Japan) with surface electrodes on the orbicularis oculi muscles pre-operatively as a baseline and postoperatively after 1 month, 3 months and 6 months. The results were obtained in terms of amplitude and latency and were tabulated and compared to pre-operative values.

Statistical analysis of the data

Data were analyzed using IBM SPSS software package version 20.0. (Armonk, NY: IBM Corp) Qualitative data were described using number and percent. The Kolmogorov-Smirnov test was used to verify the normality of distribution Quantitative data were described using range (minimum and maximum), mean, standard deviation, median and interquartile range (IQR). Significance of the obtained results was judged at the 5% level.

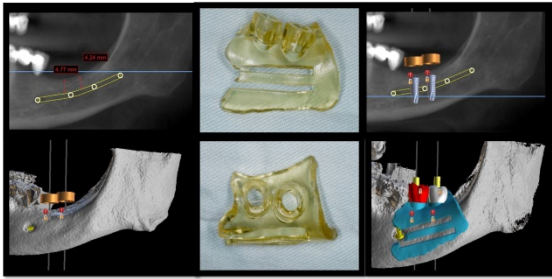


Fig (1) Construction of the Surgical guide

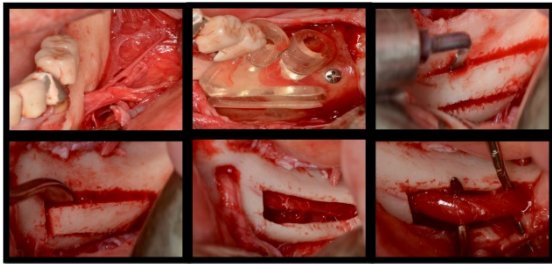


Fig (2) Surgical technique

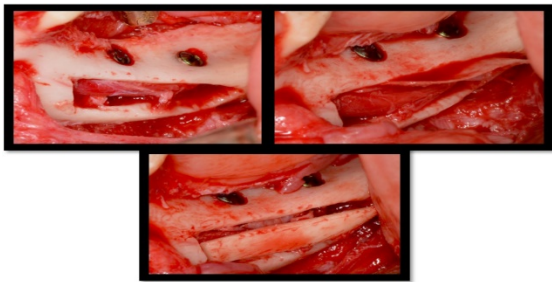

Fig (3) Procedures done in group I

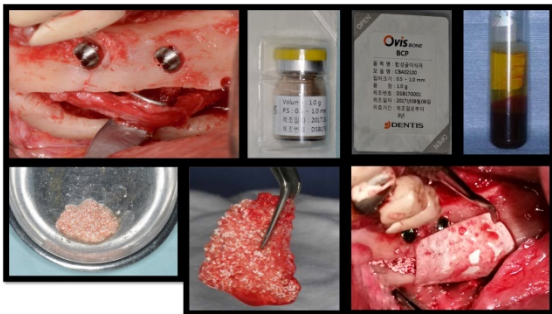

Fig (4) Procedures done for group II

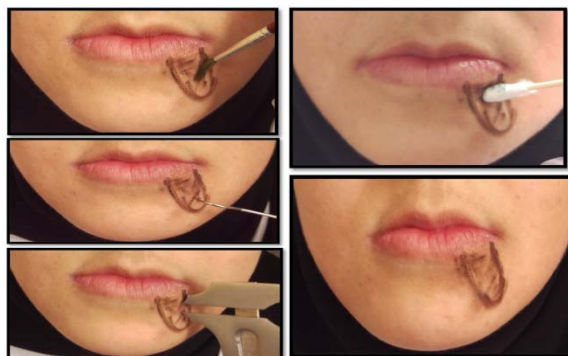

Fig (5): Clinical Neurosensory testing

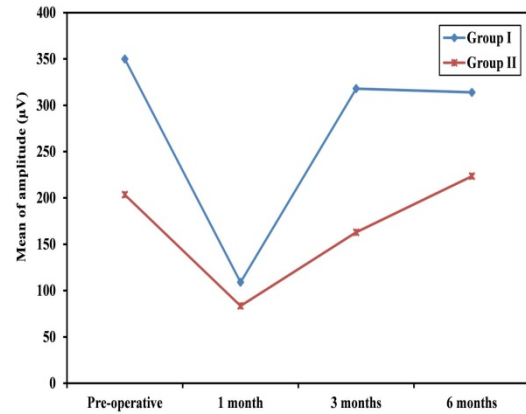


Fig (6): Comparison between the different studied periods according to amplitude in each group

Table (1) Medical Research Council scale for . Grades S3, S3+, and S4 indicate useful sensory recovery. Data from Birch R, Bonney G, Wynn-Parry CB. Surgical disorders of the peripheral nerves. Philadelphia: Churchill Livingstone, 1998: 405–414.

S0	GRADE	DESCRIPTION
		NO SENSATION
S1		DEEP CUTANEOUS PAIN IN AN AUTONOMOUS ZONE
S2		SOME SUPERFICIAL PAIN AND TOUCH SENSATION
S2+		SUPERFICIAL PAIN AND TOUCH SENSATION PLUS HYPERESTHESIA
S3		SUPERFICIAL PAIN AND TOUCH SENS HYPERESTHESIA; POINT DISCRIMINATION >15 mm
S3+		SAME AS S3 WITH GOOD STIMULUS LOCALIZATION AND STATIC TWO POINT DISCRIMINATION 7-15 mm
S4		SAME AS S3 AND TWO POINT DISCRIMINATION OF 2-6 mm

RESULTS

The current study was conducted on 20 patients 7 males and 13 females with age range from 25-59 years. All patients had a posterior atrophic mandibular ridge with alveolar height ≤ 8 mm above the level of the inferior alveolar canal. Group I contained 10 patients 3 males and 7 females with average age of 44.50 ±10.88. Group II had 10 patients 4 males and 6 females with average age of 45.40 ±10.04 with no statistically significant

difference between both groups with regards to demographic data.

Evaluation of the implant success and survival

Clinical implant evaluation

All implants placed by this technique showed high primary stability Table (2) with a mean value of 69.5 ± 5.06 , 68.7 ± 3.71 for group I and II respectively. Statistically significant increase was found between the primary stability and the stability on 6 months (73.7 ± 4.83 , 72.9 ± 3.87) for both groups. ($P < 0.001$, $P = 0.009$ for group I and II respectively).

Statistically significant decrease in the mean probing depth readings on the third and the sixth month ($p = 0.005$, $p = 0.007$ for group I and II respectively) while no statistical significance between the third and sixth month with regards to gingival index scores for both groups ($P > 0.05$) indicating good peri-implant tissue with proper adaptation to the installed abutment.

No significant difference between both studied groups along the studied periods with regards to; implant stability, mean probing depth and gingival index scores which reflects good implant survival and success when using both modifications.

Radiographic implant evaluation

Regarding the bone density, a statistically significant increase in bone density readings on the third and the sixth month for both groups when compared to the immediately post-operative value ($P < 0.001$) which denotes proper healing and bone formation around implants placed in both groups.

Regarding the marginal bone level scores, significant change between the scored readings on the sixth month compared to preoperative reading in both groups ($P > 0.05$). This denotes remodeling and formation of bone around the placed implant.

Although restoration of the bone contour is noticed in the second group to be better than group I, no significant difference was found between the two groups regarding the bone density and the marginal bone level in both follow up phases.

Assessment of the neurosensory recovery

Clinical neurosensory testing results

The onset of symptoms differed from one patient to another. In most of the patients it became apparent on the day after the surgery. None of the cases had complete anesthesia or hyperesthesia, and the neurosensory disturbance did not increase since the time of the surgery and did not seem to affect the patients' daily life. Only one of the patients had prolonged alteration of sensation in the first group although the clinical neurosensory testing revealed normal. This patient, therefore, had a sensory defect which was an inadequate quality of sensation rather than complete loss of sensation.

Regarding the clinical neurosensory testing, four tests were done (static light touch, brush stroke, pain test and two-point

discrimination). The results revealed; in the first week, all the patients in both groups had impaired sensation. By the first month, 20% of the patients has gained their sensation back in group II only. In the third month, 90% (9/10) in the patients of group I had regained their sensation while in group II, 80% (8/10) had regained their sensation. By the 6 months, all patients (100%) in both groups had normal sensation.

Medical Research Council Scale (MRCs)

Table(3)

Recovery from the injury in the present study took about 3 months in majority of the cases. According to the modified MRCs a score of S3 or above indicates useful sensory function. In the first week, 30% of the patients in both groups had useful sensory function (score S3).

By the first month, all patients (100%) in group I had useful sensory function (scored S3), while in group II, 80% scored S3 and 20% of the patients scored S3+. In the third month, 90% in the patients of group I scored S3+ and 10% scored S3. In group II, 80% scored S3+ while 20% scored S3. By the sixth months, all patients (100%) in both groups had a score of S3+.

The results revealed that group II recovery was faster in the first month with statistically significant difference between 1 week and 1 month ($p = 0.038$). While in group I, the recovery took 3 months to be significant ($p = 0.009$). At 3 and 6 months both groups showed significant improvement of sensation compared to 1 week post-operative ($p < 0.001$)

Mental Nerve Blink Reflex results (MNBR)

The results of the blink reflex are tabulated in terms of amplitude and latency. Fig (6) Regarding the amplitude, by 1 month post-operative, statistically significant decrease in amplitude is seen in both groups compared to the pre-operative value. By 3 months both groups showed no significant difference compared to preoperative values.

Regarding the latency, significant increase in latency is seen in both groups at 1 months compared to the pre-operative value ($p < 0.001$, $p = 0.005$). By 3 months both groups showed no significant difference compared to preoperative values ($P > 0.05$).

This indicates that both groups had impaired sensation seen as decrease in the amplitude and increase in latency by 1 month, regain of sensation seen as normalization of the amplitude and latency by 3 months in group I and group II.

Table (2): Comparison between the three studied periods according to implant stability in each group

Implant stability	Primary	3 months	6 months	F	p
Group I (n = 10)					
Min. –	63.0 –	67.0 –	69.0 –		
Max.	80.0	80.0	84.0		
Mean ± SD.	69.50 ± 5.06	71.40 ± 4.55	73.70 ± 4.83	51.258*	<0.001*
Median (IQR)	68.50 (67.0 – 70.0)	70.0 (69.0 – 72.0)	72.0 (70.0 – 75.0)		
Sig. bet. periods	p ₁ =0.004*, p ₂ <0.001*, p ₃ <0.001*				
Group II (n = 10)					
Min. –	63.0 –	67.0 –	65.0 –		
Max.	75.0	76.0	79.0		
Mean ± SD.	68.70 ± 3.71	70.50 ± 3.10	72.90 ± 3.87	12.258*	<0.001*
Median (IQR)	69.0 (66.0 – 72.0)	69.50 (68.0 – 73.0)	74.0 (70.0 – 75.0)		
Sig. bet. periods	p ₁ =0.056, p ₂ =0.009*, p ₃ =0.049*				

IQR: Inter quartile range

SD: Standard deviation

F: F test (ANOVA) with repeated measures, Sig. bet. periods were done using Post Hoc Test (Bonferroni)

p: p value for comparing between the studied periods

p₁: p value for comparing between primary and 3 months

p₂: p value for comparing between primary and 6 months

p₃: p value for comparing between 3 months and 6 months

*: Statistically significant at p ≤ 0.05

Table (3): Comparison between the different studied periods according to MRC in each group

	1 week		1 month		3 months		6 months		Fr	p
	No.	%	No.	%	No.	%	No.	%		
Group I (n = 10)										
S0	4	40.0	0	0.0	0	0.0	0	0.0	28.241*	<0.001*
S2	3	30.0	0	0.0	0	0.0	0	0.0		
S3	3	30.0	10	100.0	1	10.0	0	0.0		
S3+	0	0.0	0	0.0	9	90.0	10	100.0		
p ₀			0.194		<0.001*		<0.001*			
Sig. bet. period			p ₁ =0.009*, p ₂ =0.004*, p ₃ =0.795							
Group II (n = 10)										
S0	5	50.0	0	0.0	0	0.0	0	0.0	26.422*	<0.001*
S2	2	20.0	0	0.0	0	0.0	0	0.0		
S3	3	30.0	8	80.0	2	20.0	0	0.0		
S3+	0	0.0	2	20.0	8	80.0	10	100.0		
p ₀			0.038*		<0.001*		<0.001*			
Sig. bet. period			p ₁ =0.100, p ₂ =0.030*, p ₃ =0.603							

Fr: Friedman test, Sig. bet. periods were done using Post Hoc Test (Dunn's)

p: p value for comparing between the studied periods

p₀: p value for comparing between 1 week and each other periods

p₁: p value for comparing between 1 month and 3 months

p₂: p value for comparing between 1 month and 6 months

p₃: p value for comparing between 3 month and 6 months

*: Statistically significant at p ≤ 0.05

DISCUSSION

Posterior atrophic mandible has been always a challenging situation. The continuous and irreversible process of bone resorption results in inadequate height to prosthetically rehabilitate by dental implants due to the close proximity of the inferior alveolar nerve. Nerve repositioning procedure is a technique which allows for implant placement utilizing the remaining bone in such cases.

Nerve Repositioning have been used as an alternative to bone grafting procedures and to short implants as it allows for the insertion of longer implants. According to a systematic review, the two cortices are engaged for better primary stability. This results in the reduction of the overall treatment time, cost and less patient morbidity. In addition to favorable biomechanics as it improves the overall strength of the prosthesis with good proportions between the implant and the crown.(8)

In the present study, all inserted implants in both groups showed to be clinically and radiographically stable throughout the study period, showing 100% survival rate. This is consistent with the results obtained by many authors that implants placed by lateralization technique show high success and survival rates ranging from 94.56-100% with a mean of 98.2%.(9,22–25)

On the other hand, the major risk of the procedure is the associated neurosensory disturbances that occur due to manipulation of the nerve. Injury to the neurovascular bundle can occur at different instances of the lateralization technique; during flap reflection, during osteotomy to access the canal, while removing the nerve from the canal, during lateralization upon preserving the nerve outside the canal while drilling and inserting the implant and finally after repositioning the bundle inside the canal. (11)

Efforts in the present study to decrease the incidence of the neurosensory disturbances had been endeavored in an attempt to improve the results. First, a para-crestal incision was used with an anterior releasing incision mesial to the canine to diminish the chance of injury to the mental nerve during flap reflection. This is consistent with the modification done by Barbu et al in their study by using a lingual approach for the incision for the

same reason as well as provide the area with more keratinized tissue on the remaining basal bone. (22) In addition, the present study used the piezoelectric device for the osteotomy. As reported by various authors, a more precise, clean cut and a field relatively free of blood was obtained. In addition, the adherent risk of accidental injury to the IAN is minimized since the soft tissues are cut at frequencies above 50 kHz. (26,27)

A patient specific 3D printed guide constructed from the patients' own CBCT was used for guiding the osteotomy of the window as well as for implant positioning. The result is a smaller window to expose the nerve, thus, less bone removal decreasing the possible complication of weakening the mandible. This was in accordance with the study done by Atef et al who used a costume made guide for osteotomy and found that it has enhanced the process of identification of the nerve as well as decreased the intraoperative time, with less risk of nerve injury and mandibular fracture.(10)

Another possible cause of nerve injury is the nerve implant interface which has gained little attention in literature with a lot of controversies in this regard. Some authors suggested interposing a biologic barrier such as a bone graft at the implant nerve interface postulating that nerve injury may occur as a result of direct contact with the sharp implant threads.(5,11,28) Others have suggested the use of a collagen membrane or platelet concentrates. (7,29,30) Some other authors considered that healing will be much quicker without such barriers, one study recommended the use of non-threaded implants. (31) Hassani et al suggested the use of bone rather than membrane to increase the contact surface area between the implant and the bone. (11)

Some animal studies in this respect found no difference after placing and not placing a membrane at the implant-nerve interface.(32,33) However, in animal studies only microscopic evaluation is feasible while clinical signs and symptoms of nerve injury cannot be assessed.

In the present study, 100% of the patients in both groups presented with altered sensation post-operatively. Most of the patients had hypothesia or decreased sensation of the area supplied by the mental nerve rather than complete loss of sensation. The period during which most of the patients recovered their sensation was between 1 and 3 months with complete recovery of all patients by the sixth month indicating the temporary nature of the injury given that meticulous surgical technique was used.

These results are in accordance with those observed by earlier authors who stated a 100% incidence of neurosensory disturbances who also stated neurosensory recovery within 6 months of the surgery.(7,34,35)

It was found that interposing a membrane (in group I) and the bone graft (sticky bone) in group II between the nerve and the implant did not prevent the occurrence of the altered sensation post-operatively. It may have shortened the recovery time as seen in the results in which, 100% of the patients in group I and II respectively had useful sensory function after 1 month.

Campos et al in their study compared the recovery of sensation with and without an interposed bone graft between the nerve and the implant. They found that interposing a bone graft did not affect the mean recovery time which was 3.95 ± 2.33 months in control group and 4.11 ± 4.68 months in the bone graft group. They also demonstrated in their study that they did not put any barrier between the nerve and the implant in the control group. (28)

Castellano-Navarro J. et al used fibrin glue (Tissucol) in 14 cases and found no differences in the neurosensory recovery, postulating that using fibrin glue did not help in preventing nerve disturbances.(24)

Rathod M. et al in their study (36) used the autogenous bone-graft obtained from the osteotomy mixed with Tricalcium phosphate hydroxyapatite crystals to fill the defect. They evaluated 10 patients enrolled in the study at 1 day, 1 week then every month post-operative. The results showed 100% incidence of neurosensory disturbances on the post-operative day. By one week patient ranged from loss of protective sensation to diminished light touch. By the end of the fourth month 100% of the patients had neurosensory recovery. The mean time for recovery was 3 months with a minimum of 2 months and a maximum of 4 months.

Although results revealed uneventful recovery in both groups by the end of the follow up period, group II recovery was earlier in the first month with statistically significant difference between 1 week and 1 month. This may be attributed to the presence of growth factors within the sticky bone mix which have proven to accelerate nerve healing in several studies in addition, the contour of the mandible was seen to be restored better in group II patients.(29,30).

The recovery of sensation is monitored by a wide variety of protocols in the literature. The purpose of sensory diagnostic evaluation is to document the neurosensory disturbance if it exists, quantify the disturbance, monitor sensory recovery and determine if micro-reconstructive surgery may be indicated. The present study used the clinical neurosensory testing (CNT), a group of tests that are used to assess different types of nerve fibers within the inferior alveolar nerve bundle. They have been used in other studies to monitor the recovery of sensation following lateralization.(5,25,37) Although these tests are considered objective they

are in reality “subjective” in nature because the symptoms are self-reported.

To increase the diagnostic accuracy of the testing and to detect different types of damage in different nerve fiber populations, a combination of different sensory and electrophysiologic tests is recommended.(38) Accordingly, the neurophysiological test Mental Nerve Blink reflex (MN BR) was used along with the CNT. The MNBR is used to evaluate the function of A-beta sensory fiber which constitute the majority of the nerve population within the inferior alveolar nerve fascicle. All patients had impaired sensation by 1 months seen as significant decrease in amplitude and prolonged latency when compared to pre-operative values. Normalization of the amplitude and latency was seen in both groups by the third month follow up with no significant difference between when compared to pre-operative values. It was found that the CNT revealed early impairment of the nerve function but the blink reflex was more sensitive in detecting existing nerve impairment until complete recovery that took 6 month. This is consistent with the results showed by Teerijoki-Oksa et al that CNT had the best early positive predictive values, While the mental nerve blink reflex had higher negative predictive values compared to clinical tests. (39)

Therefore, it is concluded that neurosensory changes occurring after the nerve repositioning procedure is considered a normal consequence rather than a complication or an adverse sequela. However, the altered sensation is usually temporary and well tolerated by the patients given that proper technique, done meticulously by an experienced surgeon.

CONCLUSION

Restoration of sensation was warranted using both modifications thus, altered sensation following nerve lateralization should be considered a normal consequence rather than a complication with neurosensory recovery accomplished using both modifications of the technique. Implants placed by the inferior alveolar nerve show clinical and radiographic success whether a bone graft is used around the implant or after repositioning the bone window. Blink reflex is a useful objective non-invasive modality that can be effectively used for evaluation of the patient’s neurosensory recovery. On the other hand, professionals should be aware that the technique is very sensitive and requires gentle manipulation and good experience of the anatomy to avoid permanent damage to the nerve. The authors declare that they have no conflicts of interest.

The author received no specific funding for this work.

REFERENCES

1. Barone A, Toti P, Menchini-Fabris GB, Felice P, Marchionni S, Covani U. Early volumetric changes after vertical augmentation of the atrophic posterior mandible with interpositional block graft versus onlay bone graft: A retrospective radiological study. *J Cranio-Maxillofac Surg* . 2017;45:1438–47.
2. Wessing B, Lettner S, Zechner W. Guided Bone Regeneration with Collagen Membranes and Particulate Graft Materials: A Systematic Review and Meta-Analysis. *Int J Oral Maxillofac Implants*. 2018;33:87–100.
3. Toledano-Serrabona J, Sánchez-Garcés MÁ, Sánchez-Torres A, Gay-Escoda C. Alveolar distraction osteogenesis for dental implant treatments of the vertical bone atrophy: A systematic review. *Medicina Oral Patologia Oral y Cirugia Bucal. Medicina Oral S.L.*; 2019;24:e70–5.
4. De FJ, Pecorari VGA, Martins CB, Del Fabbro M, Casati MZ. Short implants versus bone augmentation in combination with standard-length implants in posterior atrophic partially edentulous mandibles: systematic review and meta-analysis with the Bayesian approach *Int J Oral Maxillofac Surg*. 2019;48:90–6.
5. Sethi A, Banerji S, Kaus T. Inferior alveolar neurovascular bundle repositioning: a retrospective analysis. *Int J Oral Maxillofac Surg*. 2017;46:518–23.
6. Elnayef B, Monje A, Albiol G, Galindo-Moreno P, Wang H-L, Hernández-Alfaro F. Vertical Ridge Augmentation in the Atrophic Mandible: A Systematic Review and Meta-Analysis. *Int J Oral Maxillofac Implants*. 2017;32:291–312.
7. Lorean A, Kablan F, Mazor Z, Mijiritsky E, Russe P, Barbu H, et al. Inferior alveolar nerve transposition and reposition for dental implant placement in edentulous or partially edentulous mandibles: A multicenter retrospective study. *Int J Oral Maxillofac Surg* 2013;42:656–9.
8. Abayev B, Juodzbaly G. Inferior Alveolar Nerve Lateralization and Transposition for Dental Implant Placement. Part I: a Systematic Review of Surgical Techniques. *J Oral Maxillofac Res*. 2015;6:1–13.
9. Palacio García-Ochoa A, Pérez-González F, Negrillo Moreno A, Sánchez-Labrador L, Cortés-Bretón Brinkmann J, Martínez-González JM, et al. Complications associated with inferior alveolar nerve reposition technique for simultaneous implant-based rehabilitation of atrophic mandibles. A systematic literature review. *J Stomato Oral Maxillofac Surgery*. 2020;121:390–6.
10. Atef mohamed, Mounir mohamed. Computer-Guided Inferior Alveolar Nerve

- Lateralization with simultaneous implant placement: A preliminary Report. *J Oral Implantol* 2018;17-00141.
11. Hassani A, Saadat S, Moshiri R, Shahmirzad S, Hassani A. Nerve retraction during inferior alveolar nerve repositioning procedure: A new simple method and review of the literature. *J Oral Implant.* 2015;41:391–4.
 12. Kumar Biswas B, Das B, Chakrabarty A. Repositioning of inferior alveolar nerve and implant placement in atrophic mandible -How far justified? *J Oral Med Oral Surg Oral Pathol Oral Radiol.* 2020;5:106–11.
 13. Bastami F, Vares P, Khojasteh A. Healing effects of platelet-rich plasma on peripheral nerve injuries. *J Craniofac Surg* . 2017;28:e49–57.
 14. Sohn D, Huang B, Kim J. Utilization of Autologous Concentrated Growth Factors (CGF) Enriched Bone Graft Matrix (Sticky Bone) and CGF-Enriched. *J Implant Adv Clin Dent.* 2015;7:11–29.
 15. Devine M, Hirani M, Durham J, Nixdorf DR, Renton T. Identifying criteria for diagnosis of post-traumatic pain and altered sensation of the maxillary and mandibular branches of the trigeminal nerve: a systematic review. *Oral Surg Oral Med Oral Pathol Oral Radiol.* 2018;125:526–40.
 16. Teerijoki-Oksa T, Forssell H, Jääskeläinen SK. Validation of diagnostic methods for traumatic sensory neuropathy and neuropathic pain. *Muscle and Nerve.* 2019;59:342–7.
 17. Wayne W. Daniel CLC. *Biostatistics: A Foundation for Analysis in the Health Sciences.* Wiley-Blackwell; 2018
 18. Randomizer: A Randomization (Randomisation) Service for Multicenter Clinical Trials. [cited 2021 Apr 10]. Available from: <https://www.randomizer.at>
 19. Glavind L, Løe H. Errors in the clinical assessment of periodontal destruction. *J Periodontal Res* . 1967;2:180–4.
 20. Mombelli A, van Oosten MAC, Schürch E, Lang NP. The microbiota associated with successful or failing osseointegrated titanium implants. *Oral Microbiol Immunol.* 1987;2:145–51.
 21. Nerve Evaluation Protocol. California Association of Oral and Maxillofacial Surgeons. 2014 [cited 2020 Oct 13]. Available from: https://www.calaoms.org/Portals/0/Documents/nerve_evaluation_protocol_2014.
 22. Barbu HM, Levin L, Bucur MB, Comaneanu RM, Lorean A. A modified surgical technique for inferior alveolar nerve repositioning on severely atrophic mandibles: Case series of 11 consecutive surgical procedures. *Chir.* 2014;109:111–6.
 23. Martínez-Rodríguez N, Barona-Dorado C, Cortes-Breton Brinkmann J, Martín-Ares M, Leco-Berrocal MI, Prados-Frutos JC, et al. Implant survival and complications in cases of inferior alveolar nerve lateralization and atrophied mandibles with 5-year follow-up. *Int J Oral Maxillofac Surg.* 2016;45:858–63.
 24. Castellano-Navarro JM, Castellano-Reyes JJ, Hirdina-Castilla M, Suárez-Soto A, Bocanegra-Pérez S, Vicente-Barrero M. Neurosensory issues after lateralisation of the inferior alveolar nerve and simultaneous placement of osseointegrated implants. *Br J Oral Maxillofac Surg.* 2019;57:169–73.
 25. Al-Almaie S, Kavarodi A, Al Faidhi A, Alorf A, Alzahrani S. Incidence of neurosensory disturbance and success rates of solid-screw implants placed in conjunction with inferior alveolar nerve transposition. *Ann Maxillofac Surg.* 2020;10:80–7.
 26. Naves Freire AE, Iunes Carrera TME, Rodriguez LS, Lara De Carli M, Filho AP, Costa Hanemann JA, et al. Piezoelectric Surgery in the Inferior Alveolar Nerve Lateralization with Simultaneous Implant Placement: A Case Report. *Implant Dent.* 2019;28:86–90.
 27. De Vicente JC, Peña I, Braña P, Hernández-Vallejo G. The use of piezoelectric surgery to lateralize the inferior alveolar nerve with simultaneous implant placement and immediate buccal cortical bone repositioning: A prospective clinical study. *Int J Oral Maxillofac Surg.* 2016;45:851–7.
 28. de Campos C, Francischone C, Assis N, Devito K, Sotto-Maior B. Neurosensory Function and Implant Survival Rate Following Implant Placement With or Without an Interposed Bone Graft Between the Implant and Nerve: Prospective Clinical Trial. *Int J Oral Maxillofac Implants.* 2019;33:1450–56.
 29. Khojasteh A, Hosseinpour S, Nazeman P, Dehghan MM. The effect of a platelet-rich fibrin conduit on neurosensory recovery following inferior alveolar nerve lateralization: a preliminary clinical study. *Int J Oral Maxillofac Surg* . 2016;45:1303–8.
 30. Anitua E, Alkhraisat MH. The adjuvant use of plasma rich in growth factors in the inferior alveolar nerve repositioning technique. *Heliyon.* 2019;5:e02965.
 31. Peleg M, Mazor Z, Chaushu G, Garg AK. Lateralization of the Inferior Alveolar Nerve with Simultaneous Implant Placement: A Modified Technique. *Int J Oral Maxillofac Implant.* 2002;17:101–6.
 32. Yoshimoto M, Watanabe I, Martins MT, Salles MB, Ten Eyck GR, Coelho PG. Microstructural and ultrastructural assessment of inferior alveolar nerve damage following

- nerve lateralization and implant placement: an experimental study in rabbits. *Int J Oral Maxillofac Implants*. 2009;24:859–65.
33. Yoshimoto M, König B, Allegrini S, Lopes CDC, Carbonari MJ, Liberti EA, et al. Bone healing after the inferior alveolar nerve lateralization: A histologic study in rabbits (*Oryctolagus cuniculus*). *J Oral Maxillofac Surg*. 2004 ;62:131–5.
 34. Khajehahmadi S, Rahpeyma A, Bidar M, Jafarzadeh H. Vitality of intact teeth anterior to the mental foramen after inferior alveolar nerve repositioning: Nerve transpositioning versus nerve lateralization. *Int J Oral Maxillofac Surg*. 2013;42:1073–8. 36.
 35. Vetromilla BM, Moura LB, Sonogo CL, Torriani MA, Chagas OL. Complications associated with inferior alveolar nerve repositioning for dental implant placement: A systematic review. *Int J Oral Maxillofac Surg*. 2014;43:1360–6.
 36. Rathod M, Kshirsagar RA, Joshi S, Pawar S, Tapadiya V, Gupta S, et al. Evaluation of Neurosensory Function Following Inferior Alveolar Nerve Lateralization for Implant Placement. *J Maxillofac Oral Surg*. 2019;18:273–9.
 37. Ferrigno N, Laureti M, Fanali S. Inferior alveolar nerve transposition in conjunction with implant placement. *Int J Oral Maxillofac Implant*. 2005;20:610-20.
 38. Teerijoki-Oksa T, Jääskeläinen S, Forssell K, Virtanen A, Forssell H. An evaluation of clinical and electrophysiologic tests in nerve injury diagnosis after mandibular sagittal split osteotomy. *Int J Oral Maxillofac Surg*. 2003;32:15–23. Teerijoki-Oksa T, Jääskeläinen SK, Forssell K, Forssell H. Recovery of nerve injury after mandibular sagittal split osteotomy. Diagnostic value of clinical and electrophysiologic tests in the follow-up. *Int J Oral Maxillofac Surg*. 2004;33:134–40.