

EFFECTIVENESS OF INTRAOSSEOUS INJECTION OF DEXAMETHASONE FOLLOWING IMPACTED MANDIBULAR THIRD MOLAR REMOVAL (RANDOMIZED CONTROLLED CLINICAL TRIAL)

Nancy A.Oda^{1*} BDS, Nevien Shawky² PhD, Mohamed M. Shokry³ PhD.

ABSTRACT

INTRODUCTION: Impacted mandibular third molar surgery is a common oral surgical procedure. Swelling, trismus and pain are among the sequelae that occur after surgery due to inflammatory response. Dexamethasone is one of the corticosteroid medications used to relieve the postoperative inflammation. Submucosal injection (SM) and intraosseous injection (IO) are different routes of administration.

OBJECTIVES: To evaluate the effectiveness of intraosseous dexamethasone injection following the surgical removal of impacted lower third molar.

MATERIALS AND METHODS: 38 patients were randomly divided into IO and SM injection groups. Postoperative pain was assessed immediately after surgery and on 1, 3, and 7 postoperative days. Swelling and mouth opening were assessed just before the surgery and on postoperative days 1, 3, and 7. Early healing of periodontal soft tissue wound was assessed on 1, 7, and 14 postoperative days.

RESULTS: The effectiveness of IO injection technique in reduction of pain and control of trismus was significantly lower than that of SM injection. However, no significant difference between IO and SM injection techniques regarding swelling and early healing of periodontal soft tissue wound at any follow up point.

CONCLUSION: Both techniques had the same effect on early healing of periodontal soft tissue wound that was first addressed in our study. SM injection had a significant effect on reduction of pain compared to a similar study that showed no significant difference between both techniques. Similar to a previous study, SM injection was superior in controlling of trismus, however both techniques were the same in controlling of swelling.

KEY WORDS: Dexamethasone; submucosal injection; intraosseous injection; mandibular third molar.

1Master student at the Oral and Maxillofacial Surgery Department, Faculty of Dentistry, Alexandria University, Alexandria Egypt

2Professor of Oral and Maxillofacial Surgery Department, Faculty of Dentistry, Alexandria University, Alexandria Egypt

3Assistant Professor of Oral and Maxillofacial Surgery Department, Faculty of Dentistry, Alexandria University, Alexandria Egypt

**Corresponding author:*

Email: nancyahmed15574@gmail.com

INTRODUCTION

Extraction of impacted mandibular third molar tooth is one of the most common oral surgical procedures that are considered the most painful among dental treatments. In addition to pain, swelling and trismus are among the sequelae that may be transitory or permanent after surgery (1, 2). An inflammatory reaction occurs after surgical procedure following damage to soft and hard tissues. It leads to vasodilation and release of endogenous biological mediators, including histamine, serotonin, kinin, and prostaglandin, from damaged tissue and the blood cells that are responsible for these sequelae (3-5). Moreover, the oral health-related quality of life will be affected in

the postoperative period following third molar surgery (6).

Corticosteroids are commonly used to decrease the inflammatory response as they have strong anti-inflammatory activity. They act by inhibiting the body's inflammatory response to injury, with a reduction of fluid transudation and, therefore, edema. Dexamethasone is used to decrease the postoperative inflammation after surgical trauma in oral and maxillofacial surgery (7).

Many routes are available for dexamethasone administration after impacted mandibular third molar surgery; intramuscular, submucosal, intravenous, intra-alveolar powders, and oral tablets. Submucosal injection (SM) is

considered a common and simple route in the clinical setting (8). In a recent meta-analysis, SM dexamethasone injection was found to reduce early trismus, as well as early and late swelling (9). However, it didn't show significant effect on reducing pain.

Intraosseous injection (IO) is a direct injection through the bone marrow. Drinker and colleagues was the first one to report this route in 1922. Since the 1980s, it has been used alternatingly with peripheral intravenous injection. Recently, this method has been used to establish an access in emergency situations for the rapid infusion of drugs, fluids, and blood products. In dentistry, intraosseous anesthesia is a technique that uses intraosseous injection as a route of application of local anesthetic. It has been reported that the IO dexamethasone reduces the pain in irreversible pulpitis (10-12). Moreover, one study (13) showed that it was effective in reducing pain and swelling after impacted mandibular third molar tooth extraction, relatively comparable to that of SM injection. However, SM injection showed significantly higher efficacy in controlling trismus on postoperative day 3.

The null hypothesis of this study is that there was no difference between intraosseous and submucosal dexamethasone injection in reducing swelling, pain, and trismus and improvement of healing of periodontal soft tissue after impacted mandibular third molar removal.

Aim of this study is to assess the effectiveness of intraosseous dexamethasone injection after extraction of impacted mandibular third molar.

MATERIALS AND METHODS

A randomized controlled clinical trial was conducted in the Faculty of Dentistry, Alexandria University after approval of the Research Ethics Committee.

An Informed Consent Form was given and signed by all patients before the surgical procedure to ensure and confirm their understanding of the outcome of the operation and the risks they might be subjected to during the intervention.

Patients

In the period from October 2020 to March 2021, 38 patients having impacted third mandibular molar were seen in the Outpatient Clinic of Oral and Maxillofacial Department in Alexandria. The patients were divided equally into a study group (19 patients) who had intraosseous injection of dexamethasone and a control group (19 patients) who received submucosal injection of dexamethasone.

Inclusion criteria for selection were patients having impacted mandibular third molar (mesioangular or horizontal, according to the Pell and Gregory classification 1933) (13), without any

local inflammation or pathology, healthy patients (American society of anesthesiologists class I status) (13), 18 to 40 years of age, and competent patients. The exclusion criteria were breast-feeding or pregnant women, patients who had taken anti-inflammatory medications within 2 weeks prior to the procedure, previous radiotherapy or chemotherapy, heavy smokers (people smoking 25 cigarettes a day or more) (14) or alcoholic patients, allergy to dexamethasone, paracetamol, ibuprofen or co-amoxiclav, and patients on anticoagulant or corticosteroid therapy.

Materials

Hand piece with surgical bur of an ideal length of 7 mm and diameter of 1.5 mm, cartridge syringe, minnesota retractor, scalpel handle #3, bard parker blade #15, periosteal elevator, needle holder, scissor, forceps, elevator, dental probe, periodontal probe, surgical curette, bone file, rubber stopper, local anesthesia (2% Mepivacaine HCl with 1:20,000 Levonordefrin; Mepacaine-L, Alexandria), needle for application of local anesthetic solution (46, choburo, Mohyeon-myeon, Cheoin-gu, Yongin-si, Gyeonggi-do, 17037, Korea), dexamethasone 4 mg (Amriya for pharmaceutical industries, Alexandria, Egypt), a 0.8 mm fissure bur (OKO DENT, Germany), plastic syringe 3ml with A 20 gauge needle (The Egyptian Saudi Co. for Medical Manufacturing (Masco-Mid)), 3/0 Prolene suture material (SURGIMEDIC, 106 A6 Industrial Zone, 10th of Ramadan, Egypt) and a digital vernier caliper (150 mm Electronic Digital Vernier Caliper/ Stainless Steel/ Micrometer Gauge).

Methods

I) Pre-operative assessment and examinations^[1,2]

A detailed history taking was performed to collect details of the patients, their past medical history and drug history and allergies. Additionally, a thorough clinical examination followed to record buccal bone deformity, swelling and any tenderness related to the impacted lower third molar.

For all patients in two groups, facial swelling and mouth opening were assessed pre-operatively to be used as a baseline for further comparison following the surgical procedures and the administration of 4 mg dexamethasone.

Cone beam computed tomography (CBCT) and panoramic x-ray were taken for each patient to assess third molar eruption, angulations versus the adjacent second molar, to show the amount of bone covering the lower third molar, to classify the type of impaction and the relationship between the inferior alveolar canal and the roots of lower third molar.

II) Surgical procedure

Oral hygiene measures were done to the patients which include; scaling, brushing, flossing, and mouth rinsing by Chlorhexidine (Hexitol: Chlorohexidine

125mg/100ml, concentration 0.125%: Arabic drug company, ADCO) mouth wash. No preoperative drugs were given in any patients. All surgical procedures were done by the same surgeon who completed the required training to perform the same procedure independently and safely with the help of the same assistant. The procedure was done under local anesthesia using 2% mepivacaine HCl with 1:20,000 levonordefrin for inferior alveolar nerve block, lingual nerve block and long buccal nerve infiltration.

An extended buccal mucoperiosteal flap was done starting from the anterior border of mandibular ramus distally just lingual to the external oblique ridge, then a buccal sulcular incision around the third and second molars, and finally a releasing vertical incision 45° with continuous contact with the bone to the depth of the vestibule including inter dental papilla between the second and first molars. A full-thickness flap was reflected to gain access to the underlying bone.

Bone guttering was done for exposure of the crown of impacted tooth performed distal to the second molar around the impacted tooth.

Then tooth sectioning was done in mesioangular impaction cases and decapitation was done in horizontal impaction cases then the tooth was carefully elevated from the socket.

After removal of the impacted mandibular third molar, wound debridement, trimming and filling of the irregular bony edges were done then the wound was irrigated with saline.

In study group (IO group), a 0.8 mm diameter fissure bur was used to drill at the buccolingual plane in the middle point about 5 mm away from the socket wound (this distance was determined using a periodontal probe). If any communication between the socket wound and the drill hole was detected using the dental probe, drilling was performed more distally.

The distance between the inferior alveolar canal and the point of the drilling was determined using CBCT and a rubber stopper was placed on the fissure bur to limit the depth of the drilling to be 2 mm or more away from inferior alveolar canal. (Figure 1)

Then, injection of dexamethasone 4 mg using 3 ml plastic syringe and a 20-gauge needle was done into the medullary bone. (Figure 2)

The flap is then returned to its position and closure of the wound was done with 3/0 prolene suture material and a pressure pack was applied.

In control group (SM group), injection with the 3 ml plastic syringe containing dexamethasone 4 mg was done at the mucobuccal fold opposite to the surgical site of lower third molar removal immediately after suturing. (Figure 3)

III) Postoperative phase

All patients were advised to apply an ice pack extra-orally for the first 24 hours after surgery, then hot fomentation starting from second day till the end of the week. A mouth wash was used the next day till the end of the week and oral hygiene instructions were given. All patients were given oral antibiotics in the form of Amoxicillin 875 mg + Clavulanic acid 125 mg (Augmentin 1gm; GlaxoSmithKline, UK) daily every 12 hours for 5 days after surgery. Paracetamol 1 gm tablet (Novaldol, SANOFI Egypt s.a.e.El Sawah, El Amiriya) was prescribed every 6 hours for 3 days. Chlorhexidine warm mouthwash especially after meals was started from the second postoperative day. Ibuprofen 600 mg (Abbott house, Co, Egypt) was taken if needed and the patients were asked to record the total number of tablets taken during the 7 days postoperative.

IV. Clinical Follow-up phase

A postoperative clinical evaluation for pain was assessed immediately after surgery and on postoperative days 1, 3, and 7 by visual analogue scale (13). The patients were asked about the total number of ibuprofen tablets in the 7 days following surgery. Facial swelling was assessed just before the surgery and on postoperative days 1, 3, and 7 by measuring two linear references through use of a digital vernier caliper: horizontal reference between the mouth corner and the ear tragus and vertical reference between the lateral canthus and the mandibular angle. The sum of the two references represented the outcome (13). The difference between the baseline and postoperative measurement indicated the facial swelling. Mouth opening was evaluated just before surgery and on 1, 3, and 7 days postoperatively by measuring maximum inter-incisal distance in mm by using a digital vernier caliper. Early healing of periodontal soft tissue wound was assessed on postoperative days 1, 7, and 14 by using Early Wound Healing Score (EHS) (15).

The EHS is composed of 3 parameters:

1. Clinical signs of haemostasis (CSH).
2. Clinical signs of re-epithelization (CSR).
3. Clinical signs of inflammation (CSI).

The summation of the points of these 3 parameters generated the EHS. (Table 1)

Statistical analysis

Data was analyzed using IBM SPSS statistical software (version 25). Normality of the quantitative data was checked using descriptive statistics, plots (histogram and box plot) and Shapiro Wilk test. Age, Pain scores, Swelling in mm, EHS, mouth opening in mm were presented using mean, median, standard deviation and minimum and maximum. All qualitative variables were presented using count and percentage.

Pain scores and EHS were compared between groups using Mann Whitney U test and changes across time within group were assessed using Friedman test. Age, facial swelling and

mouth opening were compared using independent t test. Differences within each group regarding facial swelling and mouth opening were compared using One Way Repeated Measures ANOVA. Gender was compared using Chi Square test. Percent change was calculated using the following formula: [(New value-original value)/original value] X100. Significance level was set at 0.05.

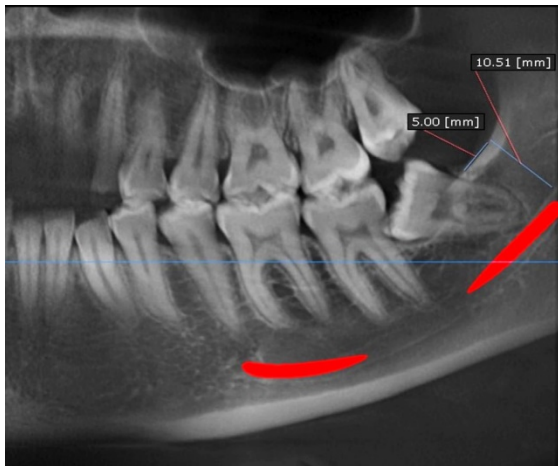


Figure 1: CBCT panoramic view showing the distance of the point of drilling away from inferior alveolar canal.

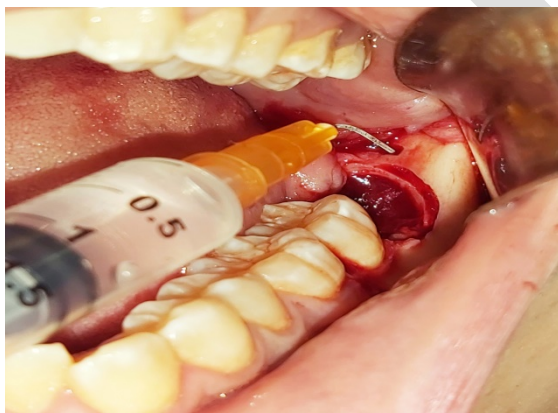


Figure 2: Intraosseous injection of 4 mg dexamethasone using 3 ml plastic syringe.

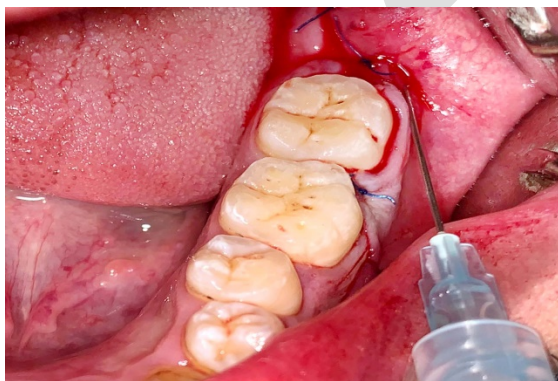


Figure 3: Submucosal injection of 4 mg dexamethasone by using 3 ml plastic syringe.

Table 1: Early Wound Healing Score (EHS) description.

Parameter	Description	Points
CSR	Merged incision margins	6
	Incision margins in contact	3
	Visible distance between incision margins	0
CSH	Absence of fibrin on the incision margins	2
	Presence of fibrin on the incision margins	1
	Bleeding at the incision margins	0
CSI	Absence of redness along the incision length	2
	Redness involving < 50% of the incision length	1
	Redness involving > 50% of the incision length and/or pronounced swelling	0
Maximum total score:	10	

EHS: Early Wound Healing Score

CSR: Clinical signs of re-epithelialization,

CSH: Clinical signs of haemostasis

CSI: Clinical signs of inflammation

RESULTS

Demographic data

The patients that were selected according to inclusion criteria included 10 males (52.6%) and 9 females (47.4%) in IO group and 10 males (52.6%) and 9 females (47.4) in SM group and the mean age in IO group was (28.05±6.05), while in SM group the mean age was (28.16 ±7.23).

Clinical data

Post-operative pain was evaluated using the Visual Analog Scale. Immediately after surgery, the mean pain score (IO group) was (3.32±1.33), while the mean pain score (SM group) was (2.37±1.12). After 1 day of surgery, the mean pain score (IO group) was (2.11±1.10), while the mean pain score (SM group) was (1.53± 0.69). After 3 days of surgery, the mean pain score (IO group) was (1.16±0.76), while the mean pain score (SM group) was (1.05 ±0.62). After 7 days of surgery, the mean pain score (IO group) was (0.74± 0.65), while the mean pain score (SM group) was (0.84± 0.50). (Table 2) The mean number of Ibuprofen tablets taken during the 7 days postoperatively in IO group was (3.89±1.19), while in SM group the mean number of Ibuprofen tablets was (0.58±0.69). (Table 3) On comparing the two groups, there was a statistical significant difference between both groups regarding pain immediately after surgery and also in the number of Ibuprofen tablets taken during the 7 days postoperatively.

Post-operative edema developed in all patients with variable degrees. It was evaluated by measuring two linear references. Preoperatively, the mean facial swelling for the IO group was (196.84±16.25), while the mean facial swelling for the SM group was (198.32±16.06). After 1 day of surgery, the mean facial swelling for the IO group was (217.89±16.02), while the mean facial swelling for the SM group was (218.05±15.91). After day 3 of surgery, the mean facial swelling for IO group was (207.53± 0.15.82), while the mean facial swelling for the SM group was (208.37±16.11). After day 7 of surgery, the mean facial swelling for IO group was (200.21±16.35), while the mean facial swelling for the SM group was (200.37±16.149). Neither clinical nor statistical significant difference was reported between the two groups regarding facial swelling at different time intervals. (Figure 4)

Early Wound Healing Score (EHS) was used to evaluate early healing of periodontal soft tissue wound. After 1 day of surgery, the mean EHS (IO group) was (6.57±0.96), while the mean EHS (SM group) was (6.63±0.68). After day 3 of surgery, the mean EHS for IO group was (7.78±0.92), while the mean EHS for the SM group was (7.84±0.95). After day 7 of surgery, the mean EHS for IO group was (8.89±0.56), while the mean EHS for the SM group was (8.94±0.52). Neither clinical nor statistical significant difference was reported between the two groups. (Figure 5)

Clinical evaluation of range of mouth opening was evaluated by measuring maximum inter-incisal distance. Preoperatively, the mean range of mouth opening (IO group) was (45.53±5.54), and was (44.21±5.59) for the SM group. After 1 day of surgery, it was (26.37±3.35) for the IO group and (37.16±5.74) for the SM group. After 3 days of surgery, it was (32.05±2.54) for the IO group and (40.68±5.53) for the SM group. After 7 days of surgery, it was (44.63±5.14) for the IO group and (43.47 ±5.43) for the SM group. On comparing both groups, there was a statistical significant difference between the two groups regarding the range of mouth opening at day 1 and day 3 after the surgery. (Figure 6)

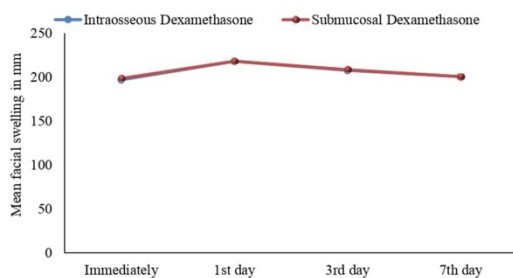


Figure 4: Mean facial swelling in mm among the study participants.

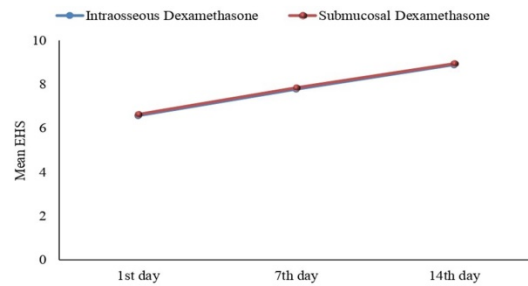


Figure 5: Mean EHS among the study participants.

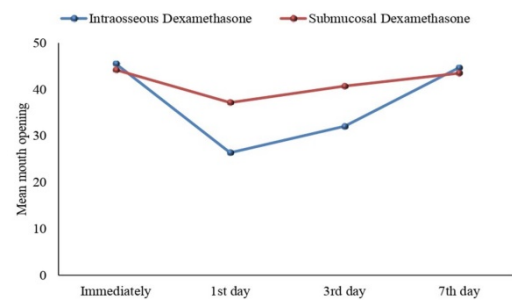


Figure 6: Mean mouth opening in mm among the study participants.

Table 2: Pain scores at different time intervals among the study participants.

		IO Dexamethasone (n=19)	SM Dexamethasone (n=19)	Test	P value
Immediately	Mean (SD)	3.32 (1.33)	2.37 (1.12)	Z=2.28	0.030*
	Median	3.00	2.00		
	Min - Max	1-6	1-5		
1 st day	Mean (SD)	2.11 (1.10)	1.53 (0.69)	Z=1.68	0.138
	Median	2.00	1.00		
	Min - Max	1-4	1-3		
3 rd day	Mean (SD)	1.16 (0.76)	1.05 (0.62)	Z=0.739	0.773
	Median	1.00	1.00		
	Min - Max	0-3	0-2		
7 th day	Mean (SD)	0.74 (0.65)	0.84 (0.50)	Z=0.669	0.583
	Median	1.00	1.00		
	Min - Max	0-2	0-2		

*Statistically significant difference at p value ≤ 0.05.

Table 3: Use of Ibuprofen tablets among the study group during the 7 days postoperatively.

	IO Dexameth asone (n=19)	SM Dexameth asone (n=19)	Test	P value
Mea n (SD)	3.89 (1.19)	0.58 (0.69)	Z=5. 339	<0.00 01*
Medi an	4.00	0.00		
Min - Max	3.89 (1.19)	0 - 2		

*Statistically significant difference at p value \leq 0.05.

DISCUSSION

Corticosteroids are one of the techniques used for reducing the postoperative inflammatory process. They suppress the physiologic processes of local heat, redness, swelling, and tenderness that characterize inflammation (16). Both short-term and single-dose corticosteroid treatment have been found effective in reducing postoperative inflammation (17, 18).

The intraosseous route was chosen in this study because it is a simple and accessible technique for the dentist (13). The intraosseous route is considered an access to the venous circulation through the marrow or medullary cavity, and it has similar onset of action to intravenous drugs (19-21). The prolonged action of some drugs administered via intraosseous route suggests that the marrow cavity may act as a depot (21). The same technique was used by S. Kaewkumnert et al (13) using 4 mg dexamethasone after surgical removal of impacted mandibular third molar. The majority of studies employed a dose of 8 mg dexamethasone. However, positive results were also achieved with a dose of 4 mg (22).

Submucosal injection offers a safe, simple, non-invasive, painless and cost effective therapeutic option for moderate and severe cases (23). According to Moraschini et al., (24) submucosal injection of corticosteroids in the preoperative phase needs larger doses of corticosteroids because the use of a flap and tissue displacement can affect the concentration of the drug and its absorption into the blood stream. Moreover, it was proven that postoperative administration of submucosal dexamethasone has provided less postoperative pain compared to preoperative administration (25).

Pain, oedema, and trismus after wisdom tooth removal are influenced by different factors such as patient age, gender, difficulty of the procedure involved, and surgeon experience (26-29).

All efforts were done to eliminate different kinds of bias in our study. It was a randomized controlled clinical trial with allocation ratio of 1:1. The difference in age and gender between the study and control groups wasn't statistically significant. All procedures were operated by the same surgeon. The same dose of dexamethasone was used in both groups. Patients in two groups underwent surgical extraction of mesioangular or horizontal impacted lower third molars.

In the present study, postoperative pain was compared between two groups using the VAS which is universally accepted (13). Patients were prescribed Ibuprofen 600 mg tablet as an additional pain killer if needed. The number of Ibuprofen tablets taken in the first 7 days postoperatively was recorded as an indication for pain intensity.

It was found that pain scores immediately after surgery and on postoperative day 1 were significantly greater in the IO group. Additionally, the number of Ibuprofen tablets taken during 7 days postoperatively was significantly higher in the IO group and this complies with the results in a similar study. Taking into consideration the high pressure in the medullary cavity in case of IO injection (13) this could explain why it is painful at the injection site. Moreover, it could be related to rapid absorption of dexamethasone through the medullary vein (23).

It is worth mentioning that SM injection of dexamethasone has been effective in controlling postoperative pain after lower third molar surgery and had similar efficacy when compared to intramuscular injection (24, 30, 31). However, it showed less efficacy in controlling postoperative pain when compared to endo-alveolar application of corticosteroids in another study (32).

Two linear facial references were used to assess the facial swelling (33). The difference in swelling between both groups wasn't statistically significant at any follow-up point, but SM injection technique had higher effect on controlling the swelling postoperatively than IO injection technique. A similar study (13) didn't show significant difference in facial swelling between the IO and SM groups on postoperative day 3 or postoperative day 7.

Moraschini et al., (24) reported that SM dexamethasone injection showed a statistically significant effect on swelling control, due to its direct action at the surgical site. Additionally, it was shown that SM injection technique improved quality of life of patients when compared to oral consumption of prednisolone in another study (34). In agreement with the present study, Graziani et al., (26) found that no difference in the severity of edema between intra-alveolar corticosteroid powder and submucosal injection of the drug. It was observed that leakage of small amount of the

dexamethasone from the surgical extraction site after IO administration.

Early Wound Healing Score (EHS) was used to assess periodontal soft tissue wound healing in both groups after surgical extraction of impacted mandibular third molar. Lorenzo Marini et al., (15) used it in a study to assess accurately early healing of periodontal soft tissues by primary intention.

To the far of our knowledge, no previous study discussed the effect of IO injection of 4 mg dexamethasone after surgical extraction of mandibular third molar on periodontal soft tissue healing using EHS. The difference in early healing of periodontal soft tissue wound between both groups wasn't statistically significant at different time intervals. Dexamethasone IO injection may act locally and systemically to reduce inflammation after lower third molar surgery (13) and that may affect the healing process. But it was found that, acute and high dose systemic corticosteroid use doesn't affect wound healing significantly, whereas chronic use of systemic steroids may affect wound healing in susceptible individuals (35).

A digital vernier caliper was used to measure the maximum inter-incisal mouth opening to assess the postoperative trismus. On postoperative days 1 and 3, trismus was significantly greater in the IO group. In a similar study, the mouth opening in the SM group was greater than that in the IO group like our study. Dexamethasone deposited in the medullary bone may not have a direct effect through inhibition of inflammation of the muscles of mastication. Moreover, dexamethasone can be rapidly absorbed from the surgical site (13).

Previous studies have reported that SM dexamethasone injection showed significant reduction of postoperative trismus, like intramuscular injection (23, 36).

CONCLUSION

This study showed that IO injection technique has significantly lower effect on pain reduction and trismus, however both IO and SM injection techniques had almost similar effect on controlling facial swelling and improvement of early healing of periodontal soft tissue wound after surgical extraction of impacted mandibular third molar.

CONFLICT OF INTEREST

The authors declare that they have no conflict of interest.

FUNDING STATEMENT

The authors received no specific funding for this work.

REFERENCES

1. Falci SGM, Lima TC, Martins CC, Santos CRRD, Pinheiro MLP. Preemptive Effect of Dexamethasone in Third-Molar Surgery: A Meta-Analysis. *Anesth Prog*. 2017;64:136-43.
2. Lin S, Levin L, Emodi O, Abu El-Naaj I, Peled M. Etodolac versus dexamethasone effect in reduction of postoperative symptoms following surgical endodontic treatment: a double-blind study. *Oral Surg Oral Med Oral Pathol Oral Radiol Endod*. 2006;101:814-7.
3. Laino L, Menditti D, Lo Muzio L, Laino G, Lauritano F, Cicciù M. Extraoral surgical approach of ectopic mandibular third molar to the lower border of mandible. *J Craniofac Surg*. 2015;26:e256-60.
4. Herrera-Briones FJ, Prados Sánchez E, Reyes Botella C, Vallecillo Capilla M. Update on the use of corticosteroids in third molar surgery: systematic review of the literature. *Oral Surg Oral Med Oral Pathol Oral Radiol*. 2013;116:e342-51.
5. Hall JE GA. Guyton and Hall textbook of medical physiology. 12th ed. Philadelphia: PA: Saunders Elsevier; 2011.
6. McGrath C, Comfort MB, Lo EC, Luo Y. Changes in life quality following third molar surgery--the immediate postoperative period. *Br Dent J*. 2003;194:265-8; discussion 261.
7. Kim K, Brar P, Jakubowski J, Kaltman S, Lopez E. The use of corticosteroids and nonsteroidal antiinflammatory medication for the management of pain and inflammation after third molar surgery: a review of the literature. *Oral Surg Oral Med Oral Pathol Oral Radiol Endod*. 2009;107:630-40.
8. Bhargava D, Sreekumar K, Deshpande A. Effects of intra-space injection of Twin mix versus intraoral-submucosal, intramuscular, intravenous and per-oral administration of dexamethasone on post-operative sequelae after mandibular impacted third molar surgery: a preliminary clinical comparative study. *Oral Maxillofac Surg*. 2014;18:293-6.
9. Chen Q, Chen J, Hu B, Feng G, Song J. Submucosal injection of dexamethasone reduces postoperative discomfort after third-molar extraction: A systematic review and meta-analysis. *J Am Dent Assoc*. 2017;148:81-91.
10. Drinker CK, Drinker KR, Lund CC. The circulation in the mammalian bone-marrow: With Especial Reference to the Factors Concerned in the Movement of Red Blood-Cells from the Bone-Marrow into the Circulating Blood as Disclosed by Perfusion of the Tibia of the Dog and by Injections of the Bone-Marrow in the Rabbit and Cat. *J Am Physiol*. 1922;62:1-92.
11. Isett J, Reader A, Gallatin E, Beck M, Padgett DJ. Effect of an intraosseous injection of depo-medrol on pulpal concentrations of PGE2 and IL-8 in untreated irreversible pulpitis. *J Endod*. 2003;29:268-71.
12. Gallatin E, Reader A, Nist R, Beck M. Pain reduction in untreated irreversible pulpitis using an intraosseous injection of Depo-Medrol. *J Endod*. 2000;26:633-8.
13. Kaewkumnert S, Phithaksinsuk K, Changpoo C, Nochit N, Muensaiyat Y, Wilaipornsawai S, et al. Comparison of intraosseous and submucosal dexamethasone injection in mandibular third molar surgery: a split-mouth randomized clinical trial. *Int J Oral Maxillofac Surg*. 2020;49:529-35.

14. Wilson D, Wakefield M, Owen N, Roberts L. Characteristics of heavy smokers. *Prev Med.* 1992;21:311-9.
15. Marini L, Rojas MA, Sahrman P, Aghazada R, Pilloni A. Early Wound Healing Score: a system to evaluate the early healing of periodontal soft tissue wounds. *J Periodontal Implant Sci.* 2018;48:274-83.
16. Ito U, Reulen HJ, Tomita H, Ikeda J, Saito J, Maehara T. Formation and propagation of brain oedema fluid around human brain metastases. A CT Study. *Acta Neurochir (Wien).* 1988;90:35-41.
17. Mense S. Sensitization of group IV muscle receptors to bradykinin by 5-hydroxytryptamine and prostaglandin E2. *Brain Res.* 1981;225:95-105.
18. Rodrigo MR, Rosenquist JB, Cheung LK. Paracetamol and diflunisal for pain relief following third molar surgery in Hong Kong Chinese. *Int J Oral Maxillofac Surg.* 1987;16:566-71.
19. Tocantns L, O'neill Jf. Infusion of blood and other fluids into the circulation via the bone marrow. *SAGE J.* 1940;45:782-3.
20. Spivey WH, Unger HD, Lathers CM, McNamara RM. Intraosseous diazepam suppression of pentylenetetrazol-induced epileptogenic activity in pigs. *Ann Emerg Med.* 1987;16:156-9.
21. Prete MR, Hannan CJ Jr, Burkle FM Jr. Plasma atropine concentrations via intravenous, endotracheal, and intraosseous administration. *Am J Emerg Med.* 1987;5:101-4.
22. Almeida RAC, Lemos CAA, de Moraes SLD, Pellizzer EP, Vasconcelos BC. Efficacy of corticosteroids versus placebo in impacted third molar surgery: systematic review and meta-analysis of randomized controlled trials. *Int J Oral Maxillofac Surg.* 2019;48:118-31.
23. Majid OW. Submucosal dexamethasone injection improves quality of life measures after third molar surgery: a comparative study. *J Oral Maxillofac Surg.* 2011;69:2289-97.
24. Moraschini V, Hidalgo R, Porto Barboza E. Effect of submucosal injection of dexamethasone after third molar surgery: a meta-analysis of randomized controlled trials. *Int J Oral Maxillofac Surg.* 2016;45:232-40.
25. Mojsa IM, Pokrowiecki R, Lipczynski K, Czerwonka D, Szczeklik K, Zaleska M. Effect of submucosal dexamethasone injection on postoperative pain, oedema, and trismus following mandibular third molar surgery: a prospective, randomized, double-blind clinical trial. *Int J Oral Maxillofac Surg.* 2017;46:524-30.
26. Graziani F, D'Aiuto F, Arduino PG, Tonelli M, Gabriele M. Perioperative dexamethasone reduces post-surgical sequelae of wisdom tooth removal. A split-mouth randomized double-masked clinical trial. *Int J Oral Maxillofac Surg.* 2006;35:241-6.
27. Capuzzi P, Montebugnoli L, Vaccaro MA. Extraction of impacted third molars. A longitudinal prospective study on factors that affect postoperative recovery. *Oral Surg Oral Med Oral Pathol.* 1994;77:341-3.
28. García AG, Sampedro FG, Rey JG, Vila PG, Martin MS. Pell-Gregory classification is unreliable as a predictor of difficulty in extracting impacted lower third molars. *Br J Oral Maxillofac Surg.* 2000;38:585-7.
29. Precious DS, Mercier P, Payette F. [Risks and benefits of removal of impacted third molars: critical review of the literature. 1]. *J Can Dent Assoc.* 1992;58:756-9, 766.
30. O'Hare PE, Wilson BJ, Loga MG, Ariyawardana A. Effect of submucosal dexamethasone injections in the prevention of postoperative pain, trismus, and oedema associated with mandibular third molar surgery: a systematic review and meta-analysis. *Int J Oral Maxillofac Surg.* 2019;48:1456-69.
31. Fernandes IA, de Souza GM, Pinheiro MLP, Falci SGM. Intramuscular injection of dexamethasone for the control of pain, swelling, and trismus after third molar surgery: a systematic review and meta-analysis. *Int J Oral Maxillofac Surg.* 2019;48:659-68.
32. Larsen MK, Kofod T, Christiansen AE, Starch-Jensen T. Different Dosages of Corticosteroid and Routes of Administration in Mandibular Third Molar Surgery: a Systematic Review. *J Oral Maxillofac Res.* 2018;9:e1.
33. Majid OW, Mahmood WK. Use of dexamethasone to minimise post-operative sequelae after third molar surgery: comparison of five different routes of administration. *Oral Surg.* 2013;6:200-8.
34. Ibikunle AA, Adeyemo WL, Ladeinde AL. Oral health-related quality of life following third molar surgery with either oral administration or submucosal injection of prednisolone. *Oral Maxillofac Surg.* 2016;20:343-52.
35. Wang AS, Armstrong EJ, Armstrong AW. Corticosteroids and wound healing: clinical considerations in the perioperative period. *Am J Surg.* 2013;206:410-7.
36. Pappalardo S, Puzzo S, Cappello V, Mastrangelo F, Adamo G, Caraffa A, et al. The efficacy of four ways of administrating dexamethasone during surgical extraction of partially impacted lower third molars. *Eur J Inflamm.* 2007;5:151-8.