

# OSSEODENSIFICATION BY DENSAH BURS VERSUS OSTEOTOME FOR TRANSCRESTAL MAXILLARY SINUS LIFTING WITH SIMULTANEOUS IMPLANT PLACEMENT

Mohamed T. EL-Ghobashy<sup>1\*</sup> *MSc*, Ahmed M. Shaaban<sup>2</sup> *PhD*,  
Lydia N. Fouad Melek<sup>3</sup> *PhD*

## ABSTRACT

**INTRODUCTION:** Implant placement in the posterior maxilla is problematic, not only due to inferior properties of bone but also due to loss of vertical bone height which happens after extraction of posterior teeth. When the required additional height is few millimeters, indirect transcrestal sinus lifting procedures is recommended. This study was carried out to compare clinically transcrestal sinus lifting with Densah burs versus osteotome with simultaneous implant placement.

**MATERIALS AND METHODS:** This study was designed to be randomized clinical trial, a total of 11 patients with missing maxillary premolars or molars and with limited vertical bone height below the maxillary sinus floor (5 to 8 mm) received 12 implants either with osteotome or with osseodensification transcrestal sinus lifting. The 11 patients were divided into 2 groups, group A received osseodensification sinus lifting, group B received osteotome sinus lifting. Clinical follow up was done over 6 months.

**Results:** No significant difference was detected regarding postoperative pain and edema. The P value (0.002\*) showed a statistically significant difference in the operation time between the 2 groups. The mean of primary stability in densah bur group was  $66.17 \pm 9.57$ , while the mean in the osteotome group was  $54.83 \pm 7.19$ . The P value was (0.043\*) showed a significant difference in primary stability between both groups. Also there was a significant difference in secondary stability between the 2 groups.

**CONCLUSION:** Both osseodensification and osteotome technique showed a good clinical outcome in 6 months follow up, with better implant stability in the osseodensification cases.

**KEYWORDS:** Transcrestal, Osteotome, Densah bur, Osseodensification

**RUNNING TITLE:** Osseodensification versus osteotome for transcrestal maxillary sinus lifting

1 Demonstrator of Oral and Maxillofacial Surgery department, Faculty of Dentistry, Alexandria University, Egypt.

2 Professor of Oral and Maxillofacial Surgery. Department of Oral and Maxillofacial Surgery, Faculty of Dentistry, Alexandria University, Egypt.

3 Assistant professor of Oral and Maxillofacial Surgery. Department of Oral and Maxillofacial Surgery, Faculty of Dentistry, Alexandria University, Egypt.

\* Corresponding Author:

E-mail: abotalaat20112371993@gmail.com

## INTRODUCTION

Planning for restoration of edentulous spaces involves dental implant which is the treatment of choice nowadays as proved by several clinical studies. It is superior to fixed bridges due to its direct connection with bone and less injury to adjacent structures (1).

Placing dental implants in the posterior maxillary spaces is a challenging procedure due to maxillary sinus pneumatization which may be physiologic or caused by extraction of teeth (2). Also vertical bone loss after extraction is a major complicating factor which results in decreased vertical bone height. Vertical bone loss can be treated by ridge augmentation but maxillary sinus pneumatization necessitates sinus floor elevation to achieve

minimum length requirement of dental implant (3). Primary Stability of dental implant is an important factor in the success rate and healing of bone around dental implant (osseointegration). The bone in the posterior maxilla is soft and poorly organized so, to increase stability of dental implant in the posterior maxilla, adequate length should be used, so maxillary sinus floor elevation is needed in these situations (4).

The maxillary sinus is the largest paranasal sinus (5). The floor of the sinus is formed by alveolar and palatine processes of the maxilla, it extends from the mesial of the first premolar to the distal of the last molar. The floor of the sinus is separated from molar

dentition by a thin layer of compact bone, roots of the first and second molars are the closest (5).

Maxillary septa are walls of cortical bone within the maxillary sinus, it may be found in the middle region above the first and second molar teeth, it is either physiologic due to development or secondary to pneumatization after extraction of teeth. The surgeon must take care of septa to avoid any complications (6,7).

The maxillary sinus is lined by Schneiderian membrane, it has a mean thickness of 0.94 mm, it may be increased in correlation with septa (8).

Sinus lifting procedures were first performed by lateral window approach, but it was an invasive technique and require other site morbidity to provide a source of grafting by autogenous bone which is the best option, also a 2 step approach is a major disadvantage (9).

Transcrestal approach was first described by Summers in 1994 (10). The crestal approach involves the use of osteotomes to raise the maxillary sinus floor and placement of bone graft to maintain the volume and height reached (10), but paroxysmal positional vertigo is an unusual complication of osteotome mediated sinus lifting which may happen in 2% of treated cases (11).

A novel osseodensification approach was introduced in 2016 by Huwais and Meyer (12). The use of densah burs for preparing implant site had many advantages including the increase of implant bone contact by compaction autografting rather than excavation of bone in conventional drill, this mainly depends on the viscoelastic nature of bone where time dependent stress produces time dependent strain, it also allows for higher insertion torque and increased stability of dental implant (12).

The use of densah burs for maxillary sinus lifting was first introduced by Huwais and Meyer in 2018 (13), utilizing the advantages of the osseodensification approach for elevation of the maxillary sinus floor. The idea of compaction autografting supported by the design of densah burs with specially tapered geometry and specially designed flutes to compact the bone on its walls and apex (13). The idea of this concept is that the special design of flutes in the densifying non cutting mood with counter clockwise motion and presence of irrigation cause a hydraulic wave at the apex of the bur, this wave cause pushing of the sinus membrane upward, also in presence of grafting material cause the same effect and subsequent elevation of the Schneiderian membrane with limited risk of perforation (13). So this approach is suggested to provide a safe technique for maxillary sinus lifting with limited complications as in osteotome or lateral approach, less perforation and less invasiveness (13).

The aim of this study was to compare the effect of Densah burs versus osteotome for transcrestal

maxillary sinus lifting with simultaneous implant placement.

The null hypothesis of this study is that: there is no significant difference between using the Densah burs or the osteotome for transcrestal maxillary sinus lifting with simultaneous implant placement regarding pain ,edema, operation time and implant stability.

## MATERIALS AND METHODS

This study was a randomized controlled clinical trial approved by the Ethics Committee, Faculty of dentistry, Alexandria University. It was registered in clinical trials.gov with the registration ID #NCT04688957. Eleven Patients in need for implant placement for their lost posterior maxillary teeth (premolars and molars) with limited bone height below the floor of the maxillary sinus were enrolled in the study in the period between November 2020 and November 2021. They were divided into 2 groups, each group received 6 implants . The study was performed in the Oral and Maxillofacial Surgery Department, Faculty of Dentistry, Alexandria University.

The criteria of patient selection included (14,15): Patients with missing maxillary premolars and molars, vertical bone height of 5-8 mm, non-smokers and good oral hygiene.

The criteria excluded patients with bad oral hygiene, maxillary sinusitis, presence of infection or periapical lesions in adjacent teeth, bruxism or clenching, alcoholism, multiple sinus septa and patients taking medications or patients with medically compromised conditions that affect the procedure (14,15).

### Preoperative assessment

Full personal history was taken including patient 's name, age, occupation, address, phone number and phone number of a close relative along with past medical and dental history, taken carefully to exclude any medical condition that may affect the implant success. Also the cause of extraction of missing teeth has been monitored.

Clinical examination was performed intraorally and extraorally to exclude any swelling or inflammation with ENT consultation to exclude any sinus pathology.

Before starting, all patients were informed about the benefits and risks of the procedure to ensure their outstanding and safety and then signed an informed consent form.

Panoramic x-ray was taken first to indicate whether the patient needs sinus lifting or not. If needs sinus lifting, then CBCT was taken.

The residual bone height and bone width were measured accurately to choose the most appropriate implant size.

### Surgical technique

All patients underwent full mouth scaling and mouth rinsing with antiseptic mouth wash before

the procedure.

All patients were treated under local anaesthesia using maxillary vestibular and palatal infiltration. A full mucoperiosteal flap was elevated with crestal incision using blade no.15, followed by flap reflection with periosteal elevator. (Figure 1, Figure 2)

Patients were divided into 2 groups:

- Group A received osseodensification sinus lifting
  - Group B received osteotome sinus lifting
- The height to the sinus floor was measured by CBCT. The pilot drill was inserted in cutting mode to 1mm below the maxillary sinus floor, and the position was confirmed by periapical x ray (Figure 1, Figure 2). A paralleling pin was inserted to check parallelity.

#### Group A (13)

The implant motor was adjusted on reverse mode with 800 to 1200 rpm. According to the desired implant dimension, we started with the smallest densah bur ex: 3.3 bur. The first densah bur was advanced in densifying mode with bouncing motion in and out movement with copious irrigation until the haptic feedback of the sinus cortex was felt. The second densah bur was used to pass through the sinus cortex in the same motion. (Figure 1)

When feeling the haptic feedback of the bur reaching the dense sinus floor, pressure was modulated with a gentle pumping motion to advance past the sinus floor in 1 mm increments. Advancement at any stage did not exceed 3 mm. The densah bur pushed autogenous bone apically to increase the residual height by 3 mm without the need for graft. With Densah bur 3.3 diameter we could place implant with width from 4 to 4.3 mm. If a wider diameter was needed, with densah bur 4 mm diameter we could place an implant with width from 4.5 to 4.8 mm. (Figure 1)

#### Group B (10)

The intermediate drill (2.7 mm) was used to the same level as the pilot reached. The first osteotome (3.2 mm) was then inserted in a wedging motion, pushed apically in an in and out motion with 1 mm increments until the sinus floor was breached (Figure 2). The second osteotome (3.8 mm) was inserted in the same motion with gentle pressure apically until the desired length was reached. The desired width was prepared with the corresponding osteotome size.

**For both groups:** Countersink was optional according to the case and density of bone. The integrity of the sinus membrane was checked by depth gauge or injection of saline in the osteotomy site, if it comes back then the membrane was intact. A path pin was inserted for confirmation of parallelity.

The implant (Dentium, Korea) was prepared for insertion, starting with handpiece then completing the insertion manually with the torque wrench. The smartpeg was inserted and tightened it then the stability was measured by the osstel (Stampgatan, Sweden). (Figure 1, Figure 2)

The flap edges were approximated approximated after cover screw placement and sutured with interrupted suture using vicryl 3/0. (Figure 1,

#### Figure 2)

**The operating time** was measured as follow:

For osseodensification cases the operating time was measured starting with the first densah bur used after pilot drill to the final implant insertion. For osteotome cases it was measured starting with the first drill after pilot drill to final implant insertion.

#### Postoperative phase

Patients were instructed to apply cold packs over the cheek for the first 12 hours after the operation, avoid drinking with straws for 10 days and to avoid sneezing and nose blowing. The following medications were prescribed: Amoxicillin clavulanate 1 gm (Augmentin 1 gm, GlaxoSmithKline, UK) twice daily for 5 days, Metronidazole 500mg (Flagyl, GlaxoSmithKline, UK) 3 times daily for 5 days, Diclofenac potassium 50mg (Cataflam Novartis-Switzerland) 3 times daily for 5 days. And Nasal decongestant Xylometazoline (Otrivin, GlaxoSmithKline, UK) 15 ml every 8 hours for 5 days.

#### Clinical follow up

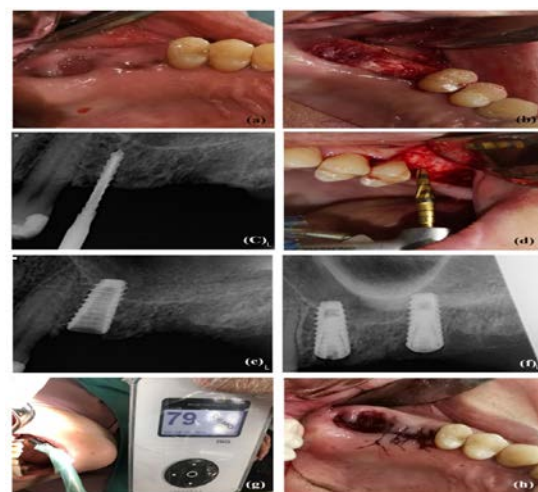
Postoperative Pain: was examined using pain intensity scale (PIS) (16).

Postoperative oedema: was measured by pitting (17). The surgeon finger was pressed in the selected area of the patient skin (cheek) for 5 seconds. The finger will go down into the tissue and leave an impression when it is removed. The pitting is graded on a scale of +1 to +4 as follows:

- +1 (trace) slight dipping rapid return to normal.
- +2 (mild) the dipping returns to normal in a few seconds.
- +3 (moderate) 6 mm dipping return to normal in 10-20 seconds.
- +4 (severe) 8 mm dipping return to normal in more than 30 seconds

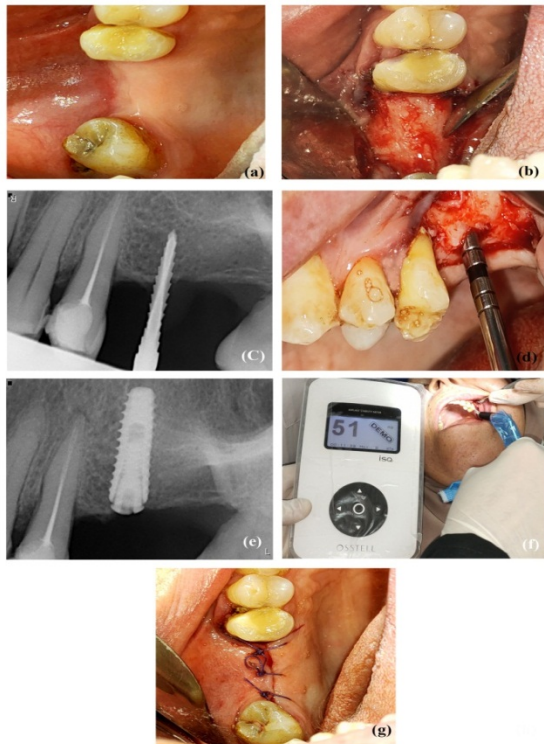
Postoperative pain and edema were measured every 2 days in the first 10 days after operation.

And Implant stability was measured by the Resonance Frequency Analysis using osstel at the time of implant placement as well as after 6 months follow up to assure osseointegration. (Figure 3, Figure 4)

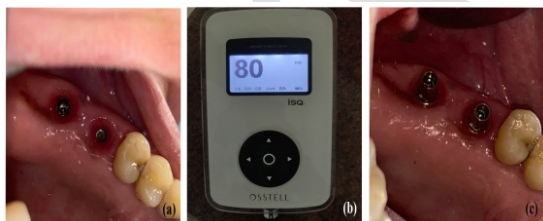


**Figure 1 :** Osseodensification sinus lifting a) Preoperative clinical view. b) Mucoperiosteal flap reflection. c) Periapical x-ray for checking sinus floor position with pilot drill. d) Osseodensification by

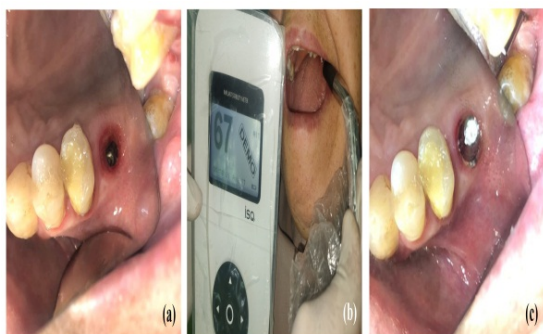
densah bur. **e)** Pariapical x-ray after implant insertion. **f)** Pariapical x-ray after 2 implants insertion. **g)** Measuring the primary stability with the Osstel ISQ. **h)** Flap closure with vicryl 3/0.



**Figure 2:** Osteotome sinus lifting **a)** Peroperative clinical view. **b)** Mucoperioosteal flap reflection. **c)** Periapical x-ray for checking sinus floor position with pilot drill. **d)** Insertion of osteotome for elevating the sinus floor. **e)** Pariapical x-ray after implant insertion. **f)** Measuring the primary stability with the Osstel ISQ. **g)** Flap closure with vicryl 3/0.



**Figure 3:** Osseodensification sinus lifting **a)** Emergence profile after using healing abutment. **b)** Measuring stability after 6 months. **c)** Insertion of dual abutments.



**Figure 4:** Osteotome sinus lifting **a)** Emergence profile after using healing abutment. **b)** Measuring stability after 6 months. **c)** Insertion of dual abutments.

### Statistical analysis

Data were checked for any errors during data entry. Quantitative data were checked for normality using Shapiro Wilk test, descriptives and box plot. Normally distributed variables (Age and implant stability) were presented using mean and standard deviation. Whereas non-normally distributed variables (pain score, edema score, and procedure time) were presented mainly using median and inter quartile range. Between groups comparisons regarding the normally distributed data were done using independent t test or by its non-parametric counterpart, Mann Whitney U test for the non-normally distributed variables. Paired t test or Wilcoxon Sign Rank were used to assess changes within each group in normally and non-normally distributed variables, respectively. Pearson Chi Square test and Fisher's Exact tests were used to compare between groups regarding the qualitative variables. Significance level was set at p value  $\leq 0.05$ .

## RESULTS

### Demographic data

Eleven patients were enrolled in this study, 5 patients for osseodensification group and 6 patients for the osteotome group. In the densah bur group all patients were females, while in the osteotome group there were 3 male and 3 female patients. Patient's age ranged from 35 to 55 years, the mean age for densah bur group was  $38.83 \pm 5.08$  years, while the mean age for osteotome group was  $43.50 \pm 5.32$  years.

No statistically significant difference was found between the 2 groups in terms of gender or age.

### Clinical Evaluation Data

#### 1- Pain and edema scores

In the densah bur group, the mean postoperative pain score was 3.00 with SD  $\pm 2.28$ , the median was 2.50 with inter quartile range (IQR)  $\pm 4.00$ .

In the osteotome group the mean postoperative pain was 4.17 with SD  $\pm 2.31$ , the median was 4.50 with IQR  $\pm 5.00$ . The P value was (Z=0.892) statistically insignificant between the 2 groups in terms of pain.

The mean edema score for densah bur group was 1.33 with SD  $\pm 0.51$ , the median was 1.00 with IQR  $\pm 1.00$ .

In the osteotome group the mean edema score was 2.17 with SD  $\pm 0.98$ , the median was 2.50 with IQR  $\pm 2.00$ . The P value was (Z=1.563) statistically insignificant between the 2 groups in terms of edema. (Table 1)

**2- The operative time**

The mean procedure time for densah bur cases was 7.33 with SD ± 2.18 minutes, the median was 6.84 with IQR ± 3.89 minutes.

The mean operative time for osteotome cases was 14.52 with SD ± 1.45 minutes, the median was 14.80 with IQR ± 2.51 minutes.

The P value (**0.002\***) showed a statistically significant difference in the operation time between the 2 groups in favour of the densah bur group. (Table 2)

**3- Implant stability**

The stability was measured immediately after implant insertion as well as after 6 months of osseointegration.

The mean of primary stability in densah bur group was 66.17 with SD ±9.57, while the mean in the osteotome group was 54.83 with SD ±7.19.

The P value was (**0.043\***) showing a significant difference in primary stability between densah bur group and osteotome group in favour of the densah bur group.

Regarding the secondary stability, the mean in the densah bur group was 77.00 with SD ±3.52, while the mean in osteotome group was 65.17 with SD ±3.06.

The P value was (**<0.0001\***) showing a significant difference in secondary stability between densah bur group and osteotome group in favour of the densah bur group. (Table 3, Figure 5)

**Radiographic Evaluation Data**

**1- Preoperative bone density**

The mean preoperative bone density in the densah bur group was 286.48 ± 204.19 HU, the median was 214.41 ± 387.99 HU.

The mean preoperative bone density in the osteotome group was 342.71 ±161.91 HU, the median was 306.45 ±251.20 HU.

The p value was (0.337) showing no significant difference in preoperative bone density between the two groups .

**Table 1:** Comparison of the pain and edema scores between the study groups

	Densah Bur Group (n=6)		Osteotome Group (n=6)		MWU test (P value)
	Mean (SD)	Median (IQR)	Mean (SD)	Median (IQR)	
Pain score	3.00 (2.28)	2.50 (4.00)	4.17 (2.31)	4.50 (5.00)	Z=0.892 (0.373)
Edema score	1.33 (0.51)	1.00 (1.00)	2.17 (0.98)	2.50 (2.00)	Z=1.563 (0.118)

**Table 2:** Comparison of the operative time between the study groups

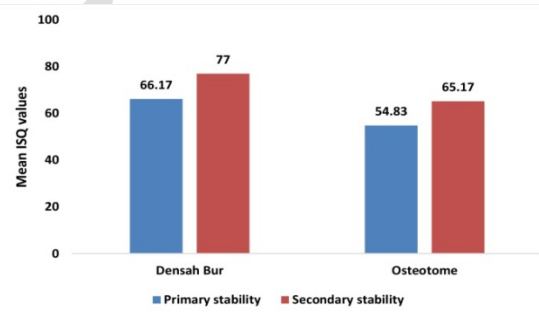
	Densah Bur Group (n=6)		Osteotome Group (n=6)		MWU test (P value)
	Mean (SD)	Median (IQR)	Mean (SD)	Median (IQR)	
Time in min	7.33 (2.18)	6.84 (3.89)	14.52 (1.45)	14.80 (2.51)	Z=2.882 (0.002*)

\*Statistically significant at p value ≤0.05

**Table 3:** Comparison of the implant stability between the study groups

	Densah Bur Group (n=6)	Osteotome Group (n=6)	Independent t Test (P value)
	Mean (SD)		
Primary stability	66.17 (9.57)	54.83 (7.19)	t=2.31 (0.043*)
Secondary stability	77.00 (3.52)	65.17 (3.06)	t=6.21 (<0.0001*)
Paired t Test (P value)	t=3.15 (0.025*)	t=3.55 (0.016*)	

\*Statistically significant at p value ≤0.05



**Figure 5:** Mean primary and secondary ISQ values between Densah bur group and Osteotome group.

**DISCUSSION**

Sinus lifting techniques has been improved all over the years, starting with lateral approach, followed by transcrestal approach and its modifications. Summers was the first to describe transcrestal approach in 1994, several techniques were used in addition to osteotome (18), until 2016 when Hauwis and Meyer introduced the densah burs and introduced using it in sinus lifting (13). In the current study, we compared the effect of densah burs versus osteotome in transcrestal maxillary sinus lifting in 12 patients.

Eleven patients divided into 2 groups. Their age ranged between 35 and 55 year, the mean age for the densah bur group was 38.83 ±5.08 years, while the mean age for the osteotome group was 43.50 ± 5.32 years.

12 implants were inserted, all of the 12 implants were 4 mm in diameter in agreement with Brizuela et al (19) as they used the same standardized diameter. Three osseodensification cases and 5 osteotome cases were 10 mm length as reported by Fernergård and Åstrand in 2016 (20). Two osseodensification cases and 1 osteotome case were 8 mm length as in the study by Nedir et al (21). In our study the implant length was chosen according to the residual bone height, in cases with 5 mm to 6 mm we used 8mm implant length, while in cases with 7 to 8 mm we used implant length 10 mm.

All implants in the 2 groups were successful, no failure was reported according to the criteria of implant success (22).

Postoperative pain was examined using pain intensity scale (PIS) in the first 10 days, the mean pain score in the osseodensification group was 3.00 with SD  $\pm 2.28$ , while in the osteotome group the mean postoperative pain was 4.17 with SD  $\pm 2.31$ . The pain was mild to moderate in the 2 groups in agreement with López-Quiles (23) in 2018.

Postoperative edema was measured by pitting in the first 10 days, the mean edema score for osseodensification group was 1.33 with SD  $\pm 0.51$ , for osteotome group the mean edema score was 2.17 with SD  $\pm 0.98$ , in both groups there was mild postoperative edema groups in agreement with López-Quiles et al (23).

There was no significant difference in pain and edema in the 2 groups. Also no Benign Positional Paroxysmal Vertigo was reported in the osteotome group as we did not use malleting osteotome, so no tapping force was used. The sinus cortex was elevated manually with wedging action the same as scrawable osteotome which is associated with less postoperative pain and edema and more patient acceptance (24).

The most common complication associated with transcrestal maxillary sinus lifting is perforation of the Schneiderian membrane which occurs in 20 % of cases according to Viña-Almunia et al (25). Fortunately, in this study no perforation was reported in any patient of the 2 groups.

The operation time in both groups was measured starting after x ray checking of pilot drill position, the mean operative time for osseodensification cases was 7.33 with SD  $\pm 2.18$ min, while the mean for osteotome cases was 14.52 with SD  $\pm 1.45$ min, the operation time for the densah bur cases was much lesser than for the osteotome cases. In osseodensification, after checking the pilot drill position to be 1 mm below sinus floor, we can only use 2 densah bur drills at speed 800 to 1200 rpm followed by implant insertion directly (13) as with densah bur of diameter 3.3 we can place implant up to 4.3 width.

On the other hand in the osteotome group, after checking the pilot drill position, we used intermediate drill, then we used 2 osteotomes with manual elevation to reach the 4 mm diameter of implant, then the final drill was inserted to assure the final width, so the operation time in the osteotome group was longer than in the osseodensification group.

The increase in bone density around the implant is a major factor in increasing stability of dental implant, where the stability depends on close contact between the implant surface and the surrounding bone (12, 26).

In this study, the mean primary stability in the densah bur group was 66.17  $\pm 9.57$ , the mean in the

osteotome group was 54.83  $\pm 7.19$ . There was a significant difference between the two groups in favour of the osseodensification group in agreement with Arafat et al (14). there was no significant difference in preoperative bone density between the two groups, so the increase in bone density was related to the technique itself. However, this was in contradiction with Hamdi (27), Ahmed et al (28) and Taha (29) in 2019 as they reported no significant difference between the 2 groups concerning primary stability.

Regarding secondary stability, the mean secondary stability in densah bur group was 77.00  $\pm 3.52$ . The mean in the osteotome group was 65.17  $\pm 3.06$ . There was also significant difference in secondary stability between the two groups in agreement with Arafat et al (14) and with Hamdi (27). On the other hand, our results were in contradiction with Ahmed et al (28).

In the osseodensification group, there was a significant difference in the implant stability immediately after implant placement and after 6 months. These results follow the results of Huwais et al (12) in 2017, Lopez et al (30) in 2017 and Huwais et al (13) in 2018.

Also in the osteotome group there was a significant difference in the implant stability immediately after implant placement and after 6 months.

The significant difference in stability between the 2 groups was mostly related to the bone density around the implant and drilling protocol. In the osseodensification group; the motorized expansion of osteotomy site along with the specific characteristics of densah burs increased the bone density around the implant which is more than that seen in the osteotome group as we proved in this study. The spring back effect and elastic recoil of bone on the implant surface after implant insertion also increased the mechanical connection between the implant and surrounding bone, along with the intact, well organized trabecular pattern of bone around the implant which increased the stability of implant primarily, and helped in further healing of bone over the 6 months follow up so the secondary stability also increased (12, 13, 31).

On the other hand, the irregular unorganized bone trabeculae of bone around the implant after using the osteotome lead to less bone quality and even stability than seen in the osseodensification group, as manual expansion of bone with osteotome has some drawbacks on implant stability and bone healing especially after 2 weeks where the osteoclastic activity occurs (32).

## CONCLUSION

From this study we can conclude that osseodensification technique produces better stability for dental implants. However both osseodensification and osteotome technique are successful techniques for maxillary sinus lifting with good clinical results.

**CONFLICT OF INTEREST**

The authors informed that they have no conflict of interest.

**Funding**

The authors received no specific funding for this work.

**REFERENCES**

1. Buser D, Janner SF, Wittneben JG, Bragger U, Ramseier CA, Salvi GE. 10-year survival and success rates of 511 titanium implants with a sandblasted and acid-etched surface: a retrospective study in 303 partially edentulous patients. *Clin Implant Dent Relat Res.* 2012;14:839-51.
2. Sharan A, Madjar D. Maxillary sinus pneumatization following extractions: a radiographic study. *Int J Oral Maxillofac Implants.* 2008;23:48-56.
3. Levi I, Halperin-Sternfeld M, Horwitz J, Zigdon-Giladi H, Machtei EE. Dimensional changes of the maxillary sinus following tooth extraction in the posterior maxilla with and without socket preservation. *Clin Implant Dent Relat Res.* 2017;19:952-8.
4. Monje A, Suarez F, Garaicoa CA, Monje F, Galindo-Moreno P, Garca-Nogales A, et al. Effect of location on primary stability and healing of dental implants. *Implant Dent.* 2014;23:69-73.
5. Whyte A, Boeddinghaus R. The maxillary sinus: physiology, development and imaging anatomy. *Dentomaxillofac Radiol.* 2019;48:20190205.
6. Krennmair G, Ulm C, Lugmayr H. Maxillary sinus septa: Incidence, morphology and clinical implications. *J Cranio-Maxillo-Facial Surg.* 1997;25:261-5.
7. Lee WJ, Lee SJ, Kim HS. Analysis of location and prevalence of maxillary sinus septa. *J Periodontol Implant Sci.* 2010;40:56-60.
8. Rancitelli D, Borgonovo AE, Cicci M, Re D, Rizza F, Frigo AC, Maiorana C. Maxillary Sinus Septa and Anatomic Correlation With the Schneiderian Membrane. *J Craniofac Surg.* 2015;26:1394-8.
9. Wallace SS, Tarnow DP, Froum SJ, Cho SC, Zadeh HH, Stoupel J, et al. Maxillary sinus elevation by lateral window approach: Evolution of technology and technique. *J Evid Based Dent Pract.* 2012;12:161-71.
10. Summers RB. A new concept in maxillary implant surgery: the osteotome technique. *Compendium.* 1994;15:152, 154-6.
11. Di Girolamo M, Napolitano B, Arullani CA, Bruno E, Di Girolamo S. Paroxysmal positional vertigo as a complication of osteotome sinus floor elevation. *Eur Arch Otorhinolaryngol.* 2005;262:631-3.
12. Huwais S, Meyer E. A Novel Osseous Densification Approach in Implant Osteotomy Preparation to Increase Biomechanical Primary Stability, Bone Mineral Density, and Bone-to-Implant Contact. *Int J Oral Maxillofac Implants.* 2017;32:27-36.
13. Huwais S, Mazor Z, Ioannou A, Gluckman H, Neiva R. A Multicenter Retrospective Clinical Study with Up-to-5-Year Follow-up Utilizing a Method that Enhances Bone Density and Allows for Transcrestal Sinus Augmentation Through Compaction Grafting. *Int J Oral Maxillofac Implants.* 2018;33:1305-11.
14. Arafat SW, A Elbaz M. Clinical and radiographic evaluation of osseodensification versus osteotome for sinus floor elevation in partially atrophic maxilla: A prospective long term study. *Egypt Dent J.* 2019;65:189-95.
15. Lpez-Quiles J, Melero-Alarcn C, Cano-Duran JA, Snchez-Martnez-Sauceda EI, Ortega R. Maxillary sinus balloon lifting and deferred implantation of 50 osseointegrated implants: a prospective, observational, non-controlled study. *Int J Oral Maxillofac Surg.* 2018;47:1343-9.
16. Taylor LJ, Harris J, Epps CD, Herr K. Psychometric Evaluation of Selected Pain Intensity Scales for Use with Cognitively Impaired and Cognitively Intact Older Adults. *Rehabil Nurs.* 2005;30:55-61.
17. Larjava H. *Oral Wound Healing: Cell Biology and Clinical Management.* Chichester, West Sussex: John Wiley & Sons; 2012.
18. Lafzi A, Atarbashi-Moghadam F, Amid R, Sijanivandi S. Different techniques in transalveolar maxillary sinus elevation: A literature review. *J Adv Periodontol Implant Dent.* 2021;13:35-42.
19. Brizuela A, Martn N, Fernndez FJ, Larrazbal C, Anta A. Osteotome sinus floor elevation without grafting material: Results of a 2-year prospective study. *J Clin Exp Dent.* 2014;6:e479-84.
20. Fermergrd R, strand P. Osteotome Sinus Floor Elevation without Bone Grafts - A 3-Year Retrospective Study with Astra Tech Implants. *Clin Implant Dent Relat Res.* 2012;14:198-205.
21. Nedir R, Nurdin N, Khoury P, Bischof M. Short Implants Placed with or without Grafting in Atrophic Sinuses: The 3-Year Results of a Prospective Randomized Controlled Study. *Clin Implant Dent Relat Res.* 2016;18:10-8.
22. Papaspyridakos P, Chen CJ, Singh M, Weber HP, Gallucci GO. Success criteria in implant dentistry: A systematic review. *J Dent Res.* 2012;91:242-8.

23. López-Quiles J, Melero-Alarcón C, Cano-Duran JA, Sánchez-Martínez-Sauceda EI, Ortega R. Maxillary sinus balloon lifting and deferred implantation of 50 osseointegrated implants: a prospective, observational, non-controlled study. *Int J Oral Maxillofac Surg.* 2018;47:1343-9.
24. Sammartino G, Mariniello M, Scaravilli MS. Benign paroxysmal positional vertigo following closed sinus floor elevation procedure: mallet osteotomes vs. screwable osteotomes. A triple blind randomized controlled trial. *Clin Oral Implants Res.* 2011;22:669-72.
25. Viña-Almunia J, Peñarrocha-Diago M, Peñarrocha-Diago M. Influence of perforation of the sinus membrane on the survival rate of implants placed after direct sinus lift. Literature update. *Med Oral Patol Oral Cir Bucal.* 2009;14:E133-6.
26. Turkyilmaz I, Tumer C, Ozbek EN, Tözüm TF. Relations between the bone density values from computerized tomography, and implant stability parameters: a clinical study of 230 regular platform implants. *J Clin Periodontol.* 2007;34:716-22.
27. Hamdi AN, Hemd SA. Comparison between osseodensification burs and osteotome technique for closed sinus lift in partially edentulous maxilla (clinical and radiological study). *J Univ Shanghai Sci Tech.* 2021;23:392-411.
28. Ahmed AK. Assessment of dental implants placed in posterior maxillary ridge using densah burs versus standard drills (randomized clinical trial). M.Sc. Thesis. Implantology Department, Faculty of Oral and Dental Medicine, Cairo University. Egypt. 2019.
29. Taha TA, Fahmy AM, Heshmat DA. Evaluation for Primary Stability of Implant in closed sinus lifting cases using Densah bur Versus Osteotome in partially edentulous patients (A randomized Clinical Trial). M.Sc. Thesis. Implantology Department, Faculty of Dentistry, Cairo University. Egypt. 2019. p.1-16.
30. Lopez CD, Alifarag AM, Torroni A, Tovar N, Diaz-Siso JR, Witek L, et al. Osseodensification for enhancement of spinal surgical hardware fixation. *J Mech Behav Biomed Mater.* 2017;69:275-81.
31. Lahens B, Neiva R, Tovar N, Alifarag AM, Jimbo R, Bonfante EA, et al. Biomechanical and histologic basis of osseodensification drilling for endosteal implant placement in low density bone. An experimental study in sheep. *J Mech Behav Biomed Mater.* 2016;63:56-65.
32. Slete FB, Olin P, Prasad H. Histomorphometric comparison of 3 osteotomy techniques. *Implant Dent.* 2018;27:424-8.