



COMPARISON BETWEEN PRP VS IPRF AS AN ADJUNCT THERAPY IN INFRA-BONY POCKET TREATMENT

Abdel-Rahman E Amin¹, Mostafa M. Hosny², Mahmoud T El-Destawy², Mahetab Abdel-Wahab³

ABSTRACT

Objective: The aim of the present study was to adjunct the healing of intra bony periodontal deep pockets using minimal invasive technique and materials (injectable platelet rich fibrin-I PRF-). **Subjects & Method:** A total of 70 medically healthy adult subjects with chronic periodontitis in a randomized controlled clinical trial were divided into 3 groups; PRP group, iPRF group & control group. PRP preparation: Two Acid citric dextrose (ACD) 8.5 ml tubes of whole blood were centrifuged at 2000 rpm for 7 min at room temperature using Heraeus Megafuge 16R centrifuge. IPRF preparation: Two tubes (without anticoagulant) of 10 ml of whole blood were centrifuged at 700 rpm for 3 min at room temperature using Heraeus Megafuge 16R centrifuge. **Results:** Postoperative evaluation: I-PRF group showed the highest reduction of probing depth from baseline, while PRP group came second followed by the control group which had the lowest reduction in probing depth. **Conclusion:** the repeated injection of i- PRF showing a stronger and more durable effect, since it has number of growth factors which are responsible for tissue regeneration capable of inducing fibroblast behavior.

KEY WORDS: PRP, iPRF, CAL, Probing Index

INTRODUCTION

Periodontitis is a multifactorial inflammatory illness characterized by progressive loss of the tooth-supporting apparatus and is linked to dysbiotic plaque biofilms. Clinical attachment loss (CAL), alveolar bone loss, and pocket development are all symptoms of periodontitis⁽¹⁾. The first phase of periodontal treatment mainly aimed at removing local factors through scaling and root planing (SRP), there by assisting in the resolution of inflammation. However,

this treatment decreases probing pocket depth due to shrinkage or development of long junctional epithelium but not often forms a new attachment. At this point, healing outcome looks to be adequate but is susceptible to future disease progression⁽²⁾. Periodontal healing is a organized procedure which includes three phases: inflammation, fibroblastic-granulation ,matrix formation, and remodeling. It involves a biochemical chain of reactions, cellular organization and synthesis of extracellular matrix⁽³⁾. Platelets play a vital role in haemostasis and

1. Master Candidate, MSA graduate,
2. Assistant Professor, Department of Oral Medicine, Periodontology, Diagnosis and Oral Radiology Faculty of Dental Medicine, Al-Azhar University, Boys, Cairo.
3. Lecturer, Department of Periodontology, Faculty of Dentistry, Ain Shams University.

• **Corresponding author:** abdelrahman_elw_amin@hotmail.com

wound healing, as they are reservoir of many growth factors responsible for neovascularization, collagen production, cellular division and differentiation and induction of other cells to the site of wound⁽⁴⁾. Platelet concentrations, which include two generations, are one of these materials. The first generation is platelet rich plasma (PRP), and the second is platelet rich fibrin (PRF). The liquid viscosity of standard PRF is maintained for roughly 15 minutes after centrifugation, making platelet concentrate easier to use in a liquid condition. Injectable PRF (also known as iPRF) is a step forward from regular PRF, which retains its liquid viscosity for around 15 minutes after centrifugation, making platelet concentrate more convenient to utilize in a liquid form.⁽⁵⁾

Platelet concentrates are currently being used to treat periodontal intrabony defects, furcation defects, sinus lift operations, and tissue engineering PRF contains considerable amounts of fibroblast growth factor (FGF), insulin-like growth factor-1 (IGF-1), epidermal growth factor (EGF), platelet-derived epidermal growth factor (PDEGF), vascular endothelial growth factor (VEGF), and transforming growth factor-1 (TGF-1). As a result, provide a more favorable environment for the regeneration and repair of these flaws⁽⁶⁾. PRP has previously been used as a protein covering for implant surfaces in conjunction with dental implants^(5, 6). Injectable PRF is provides the benefits of advanced PRF in the form of a liquid. Injectable PRF, on the other hand, collects a certain number of progenitor cells from the bloodstream. It has shown to be particularly effective in both oral surgery and regenerative medicine. When injectable PRF is inserted into the bone graft, it clots within seconds and encapsulates the particles in a very good manner, allowing the bone graft to be carved and given a compact form⁽⁷⁾.

The main hypothesis behind this work is that Injectable PRF formulation (iPRF) is more better in preparation, manipulation and clinical results than

PRP. This controlled clinical study was designed to compare the clinical outcome of platelet rich plasma to injectable platelet rich fibrin as an adjunct to non-surgical therapy.

SUBJECTS AND METHOD

Study design

The study was designed as a randomized, controlled, single- blind and prospective clinical trial. Fifty patients provisionally diagnosed with periodontitis in stage II to III with grade B to C according to the World Workshop 2017 on the Classification of Periodontal and Peri-Implant Diseases and Conditions⁽¹⁾ were selected from the outpatient clinic, Department of Periodontology, Faculty of Dental Medicine (Boys, Cairo) Al Azhar University. The patients were carefully re-evaluated, and if the periodontitis stage II, III was approved and follow the inclusion criteria, they were completely informed about the objective and the purpose of this study. The inclusion criteria of the patient were as follows: (a) no systemic or immunological disease, (b) non-smoking, (c) presence of bilateral interproximal defect, (d) probing depth ≥ 5 mm on a minimum of two teeth, (e) inter dental clinical attachment level (CAL) 3mm or more than 5mm, (f) without degree II or III of furcation involvement or no tooth mobility, (f) gingival biotype more than 1 mm with enough width of attached gingiva. Non-cooperating patients, pregnant and lactating females, and persons with decision problems (disabled, and mentally retarded, prisoners' patients) were excluded from the study. Patients with systemic medication or antibiotic treatment during the previous 6 months were also excluded. An informed consent was signed by each patient before enrollment.

Patient grouping

The selected patients were received a complete full mouth nonsurgical periodontal treatment, which comprised of supragingival scaling,

subgingival root planning and curettage with ultrasonic instruments and manual instrumentation with Gracey curettes. Patients were advised to perform regular oral hygiene and to use mouthwash with chlorhexidine⁽⁸⁾ twice a day for a week. The patients were informed of the appropriate guidelines for the proper mechanical control of the plaque, which consisted of brushing with a soft toothbrush with a roller technique and cleaning interdentally with dental floss. By split mouth technique, We selected two bilateral interproximal defects of single rooted teeth which selected in the same arch. Then, they were divided into study group 1 and 2. The study groups sites were randomly selected, the autologous PRP was prepared and placed in the periodontal pockets and other site was received by iPRF. Baseline parameters were recorded following complete full-mouth SRP. Then the blinded examiner recorded clinical parameters at 1,2 and 3 months recall visits. The clinical parameter included: Plaque index, bleeding index, gingival index, Probing depth and Clinical attachment loss recorded, six record per tooth. **in Study group1** thirty teeth received a full mouth supra –and subgingival scaling and root planning (SRP) , in addition to PRP application. While **Study group 2** thirty teeth in opposite side received a full mouth supra –and subgingival scaling and root planning, with iPRF application. **Control group** Ten patients received a full mouth supra – and subgingival scaling and root planing only. Figure(1-12) .

Preparation protocol of platelet preparation

Two venous blood samples were collected from each subject, from the antecubital vein. In PRP preparation, Two Acid citric dextrose (ACD) 8.5 ml tubes of whole blood were centrifuged at 2000 rpm for 7 min at room temperature using Heraeus MegafugeTM 16R centrifuge, Thermo scientificTM, USA.

Blood fractionated, PRP is seen on the top right after centrifugation and collected using the sterile plastic syringe. While the red and white blood cells as well as the platelet poor plasma is left at the bottom of the tube⁽⁹⁾. While in Injectable PRF preparation, Two tubes (without anticoagulant) of 10 ml of whole blood were centrifuged at 700 rpm for 3 minutes at room temperature using Heraeus MegafugeTM 16R centrifuge, Thermo scientificTM, USA. The upper liquid layer is collected as iPRF⁽¹⁰⁾. The study sites were cleansed and anaesthetized with Lidocaine topical gel. Then, the platelet preparations (PRP or iPRF) were injected into the gingival sulcus with a microneedle (0.25mm (31G) x 6mm needle, BD GlideTM needle insulin syringe) until the blanching and fullness of gingiva was noted, pressure was applied with a moist gauze on the site for five minutes following the delivery, the injection was repeated at day 1, 14, and 28 days.

Statistical analysis of the data:

Data were fed to the computer and analyzed using IBM SPSS software package version 20.0. (Armonk, NY: IBM Corp). Descriptive statistics like PD, CAL, and CAL in both the control and test sites were documented using mean and standard deviation. The Shapiro-Wilk test was used to verify the normality of distribution Quantitative data were described using range (minimum and maximum), mean, standard deviation and median. Significance of the obtained results was judged at the 5% level. The power analysis was performed according to Mila et al., for adjunctive non-surgical periodontal treatment⁽¹¹⁾. That power analysis was conducted by G power version 3.1 statistical software, Franz Faul, Universität Kiel Germany. The findings indicated a minimum sample size of n = 6 cases, based on an α of 5 % and a power of 80 %. Considering a possible loss of about 10 % of patients, we used 7 samples.

PRP Group

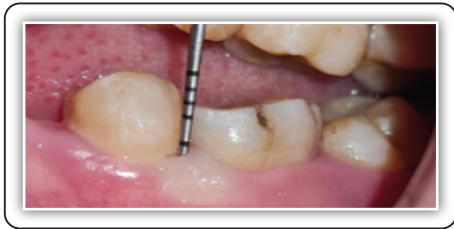

FIG (1) Intraoral photograph of probing depth at time zero showing pocket depth \cong 4mm

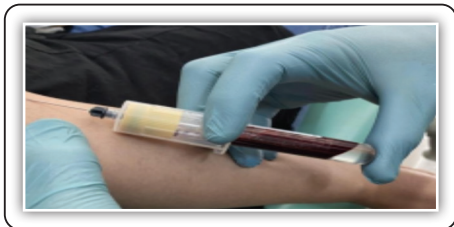

FIG (2): Collecting blood sample via ACD tubes-Acid citric dextrose.



FIG (3): Centrifugation at 2000 RPM For 7 min at room temperature

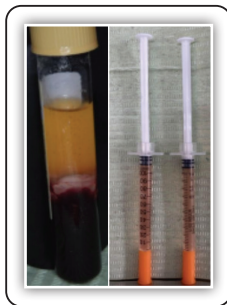


FIG (4): Photograph showing the PRP, the collected PRP in insulin syringes

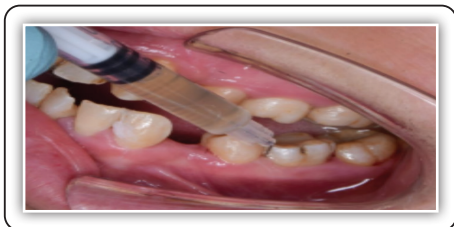

FIG (5): photograph showing the injection of PRP

i-PRF Group

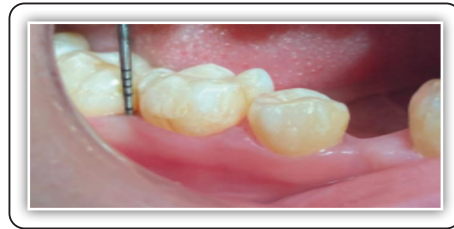

FIG (7) : Intraoral photograph of probing depth at time zero showing pocket depth \cong 4mm

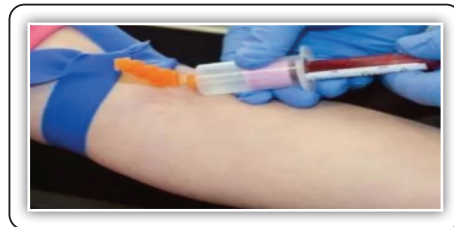

FIG (8): Collecting blood sample via venipuncture



FIG (9) while centrifugation at 700 RPM For 3 min at room temperature

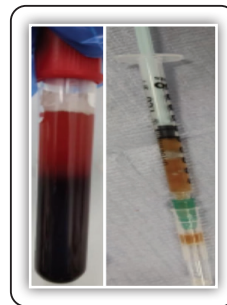

FIG (10): Photograph showing the IPRF, the collected IPRF in insulin syringes

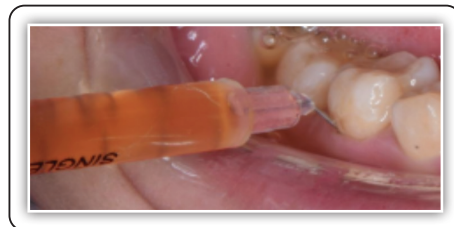

FIG (11): photograph showing the injection of IPRF

PRP Group

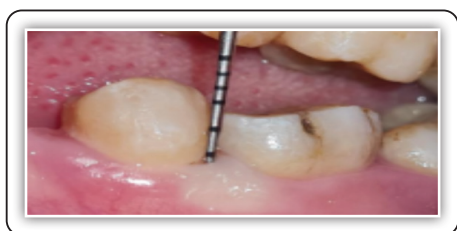

FIG (6): photograph showing the probing depth after 3 month \cong 3 mm

i-PRF Group

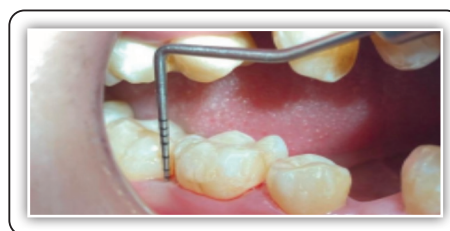

FIG (12): photograph showing the probing depth after 3 months \cong 2 mm

RESULTS

All patients complied with the appointment and dismissal instructions during the 3-month study period. The present study was conducted in thirty patients in the study and ten patients in the control group, The study group contained 16 males and 14 females, whereas the control group had 6 males and 4 females. The mean age of the study population is 34.0 ± 7.95 years and 35.10 ± 7.36 years for the control group. In terms of age and gender distributions, there was no statistically significant difference between the groups. At baseline, no statistical significance was detected in probing depth, clinical attachment level between the control and test groups.

The baseline pocket depth was 3.77 ± 0.75 mm, 4.21 ± 0.78 mm and 4.06 ± 0.89 mm for PRP group, iPRF group and the control group sites, respectively. After 1 month following the intervention, the pocket

depth decreased to 2.41 ± 0.57 mm in the PRP sites, 2.40 ± 0.70 mm in iPRF sites and 3.25 ± 0.97 mm in the test site. After 2 months, the pocket depth in the PRP, iPRF and control site further decreased to 2.09 ± 0.64 mm, 1.99 ± 0.51 mm and 3.27 ± 0.89 mm, respectively. Also, after 3 months, the pocket depth in the PRP, iPRF and control site additional decreased to 1.90 ± 0.62 mm, 1.68 ± 0.44 mm and 2.28 ± 0.77 mm, respectively. In PRP and iPRF and control groups, the difference in pocket depth between baseline and 1 months as well as 2 and 3 months was statistically significant ($p < 0.001$). Therefore, there was a statistically significant decrease in PD from the baseline in all the test and control sites. Percentages of reduction of PD from baseline to 1,2,3 months, there was a statistically a significant difference in mean probing depth in the three groups ($p < 0.001$). iPRF group showed a higher reduction followed by PRP group then the control group (Table. 1).

TABLE (1) Comparison between the different time periods in each group according to probing depth.

	Probing depth				F	P
	Baseline	1 month	2 month	3 month		
Platelet Rich in Plasma (n = 30)	3.77 ± 0.75	2.41 ± 0.57	2.09 ± 0.64	1.90 ± 0.62	85.958*	<0.001*
P₀		<0.001*	<0.001*	<0.001*		
Injectable Platelet Rich in Fibrin (n = 30)	4.21 ± 0.78	2.40 ± 0.70	1.99 ± 0.51	1.68 ± 0.44	209.507*	<0.001*
P₀		<0.001*	<0.001*	<0.001*		
Control (n = 10)	4.06 ± 0.89	3.25 ± 0.97	2.76 ± 0.89	2.28 ± 0.77	102.227*	<0.001*
P₀		<0.001*	<0.001*	<0.001*		

Data was expressed using Mean \pm SD.

F: F for ANOVA test

p: p value for comparing between the studied periods

p0: p value for comparing between Baseline and each other period in each group

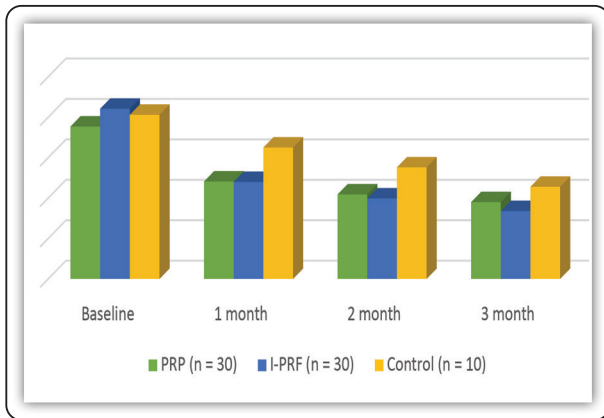


FIG (13) Comparison between the different time periods in each group according to probing depth(PD)

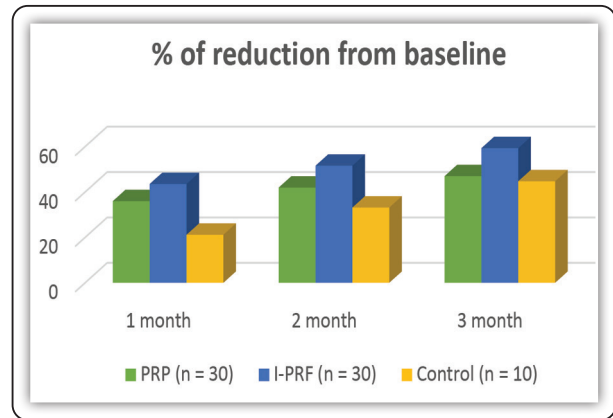


FIG (14) Comparison between the three studied groups according to % of reduction of PD from baseline.

There was statistically non-significant difference in clinical attachment level (CAL) between PRP group, iPRF group and control group at baseline. PRP showed a statistically a significant decrease ($p < 0.001$) in mean CAL at 1, 2 and 3 months ($p = 0.003$, $p < 0.001$ and $p < 0.001$ respectively). iPRF showed a statistically a significant decrease ($p < 0.001$) in mean of CAL at 1, 2 and 3 months ($p < 0.001$, $p < 0.001$ and $p < 0.001$ respectively). The Control showed a statistically a significant decrease ($p < 0.001$) in mean of CAL at 1, 2 and 3 months ($p = 0.083$, 0.001 and < 0.001 respectively) (Table 2).

Percentages of reduction from baseline to 1 month, there was a statistically a significant difference in mean clinical attachment level in the

three groups. iPRF group showed a higher reduction from baseline by 56.21 ± 14.71 , while PRP group was 40.18 ± 16.09 and control group was 36.73 ± 14.17 . Percentages of reduction from baseline to 2 month, there was a statistically a significant difference in mean clinical attachment loss in the three groups. iPRF group showed a higher reduction from baseline by 76.76 ± 20.03 , while PRP group was 79.16 ± 13.90 and control group was 60.39 ± 10.87 . Percentages of reduction from baseline to 3 month, there was a statistically a significant difference in mean clinical attachment loss in the three groups. iPRF group showed a higher reduction from baseline by 84.80 ± 17.10 , While PRP group was 82.84 ± 11.63 and control group was 74.07 ± 6.84 (Table 3).

TABLE (2) Comparison between the different time periods in each group according to clinical attachment level

	Clinical attachment level				Fr	p
	Baseline	1 month	2 month	3 month		
PRP (n = 30)	2.29 ± 0.55	1.35 ± 0.37	0.47 ± 0.28	0.38 ± 0.23	89.709*	<0.001*
P₀		0.003*	<0.001*	<0.001*		
iPRF (n = 30)	1.98 ± 0.79	0.89 ± 0.48	0.44 ± 0.34	0.28 ± 0.30	79.219*	<0.001*
P₀		<0.001*	<0.001*	<0.001*		
Control (n = 10)	2.22 ± 0.90	1.46 ± 0.81	0.93 ± 0.57	0.61 ± 0.36	30.000*	<0.001*
P₀		0.083	0.001*	<0.001*		

p₀: p value for comparing between Baseline and each other period in each group

TABLE (3) Comparison between the three studied groups according to clinical attachment loss

Clinical attachment level	PRP (n = 30)	iPRF (n = 30)	Control (n = 10)
Baseline	2.29 ± 0.55	1.98 ± 0.79	2.22 ± 0.90
Sig. bet. grps.	p ₁ =0.043*, p ₂ =0.724, p ₃ =0.008*		
1 month	1.35 ± 0.37	0.89 ± 0.48	1.46 ± 0.81
Sig. bet. grps.	p ₁ <0.001*, p ₂ =0.914, p ₃ =0.569		
2 month	0.47 ± 0.28	0.44 ± 0.34	0.93 ± 0.57
Sig. bet. grps.	p ₁ =0.459, p ₂ =0.008*, p ₃ <0.001*		
3 month	0.38 ± 0.23	0.28 ± 0.30	0.61 ± 0.36
Sig. bet. grps.	p ₁ =0.020*, p ₂ =0.077, p ₃ =0.003*		
% of reduction from baseline to			
1 month	40.18 ± 16.09	56.21 ± 14.71	36.73 ± 14.17
Sig. bet. grps.	p ₁ <0.001*, p ₂ =0.414, p ₃ =0.001*		
2 month	75.16 ± 13.90	76.76 ± 20.03	60.39 ± 10.87
Sig. bet. grps.	p ₁ =0.975, p ₂ =0.036*, p ₃ =0.008*		
3 month	82.84 ± 11.63	84.80 ± 17.10	74.07 ± 6.84
Sig. bet. grps.	p ₁ =0.237, p ₂ =0.012*, p ₃ =0.014*		

Data was expressed using Mean ± SD.

p1: p value for Wilcoxon signed ranks test for comparing between PRP and I-PRF

p2: p value for Mann Whitney test for comparing between PRP and Control

p3: p value for Mann Whitney test for comparing between I-PRF and Control

*: Statistically significant at p ≤ 0.05

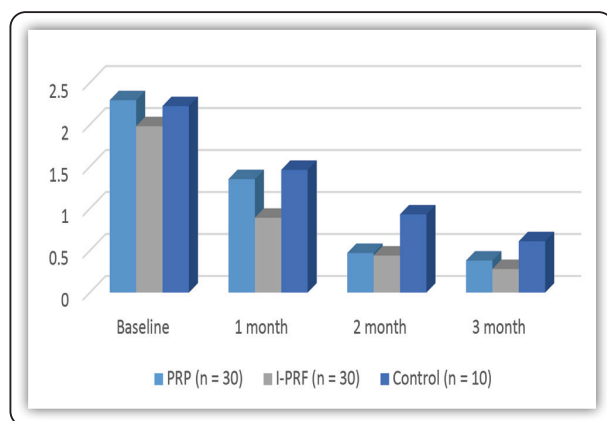


FIG (15) Comparison between the three studied groups according to clinical attachment loss

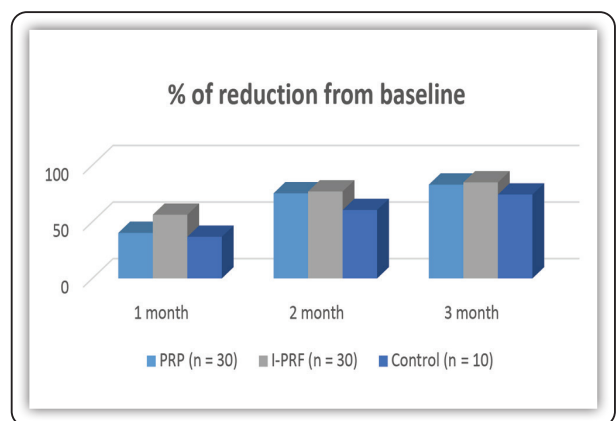


FIG (16) Comparison between the three studied groups according to % of reduction from baseline of clinical attachment level.

DISCUSSION

The non-surgical management of periodontal pockets is the phase one of all periodontal diseases. The need of surgical phase based on the concept of critical probing depths⁽¹²⁾. In this study, patients were selected with moderate pockets to treat them non-surgically, which otherwise may require surgical intervention. Non-surgical periodontal therapy causes resolution of inflammation and reduction in pocket depth. Hand instrumentation is considered as a gold standard for subgingival debridement, but its healing outcome is limited and depends on lowering the numbers of periodontal pathogens⁽¹³⁾. In the past, attempts were made by using systemic antibiotics, host modulation, local drug delivery, photodynamic therapy and subgingival irrigation as an adjunct to subgingival debridement to improve its value. However, the conclusions of these studies failed to give a clear result and need further investigation⁽¹⁴⁾. Gingival curettage and besides root planing complete root debridement exposure of the microvasculature to healthy cemental surfaces initiates the healing process. Healing of periodontal wounds results in the production of fibrin, aggregation of platelets, and release of platelet growth factors into the tissues. These growth factors attract and interact gingival fibroblasts, periodontal ligament cells, osteoblasts and epithelial cells. Furthermore, fibronectin, fibrin, and vitronectin secreted from platelets act as a scaffold for the connective tissue and adhesion molecules for enhance the migration of cells⁽²⁸⁾. Consequently, at this stage, it was intended to place the different platelet preparation in the periodontal pocket, for enhancement of healing and to compare that effect between them.

According to our study, iPRF has a higher concentration of GFs than PRP. It boosts fibroblast migration and transforming growth factor-1, platelet-derived growth factor, and vascular endothelial growth factor expression⁽¹⁵⁾. iPRF has a larger concentration of fibroblast growth factor, insulin-like growth factor-1, epidermal growth factor, and platelet-derived epidermal growth factor in addition to these factors, it provides a better environment

for defect regeneration and repair. iPRF is now frequently used in the surgical treatment of periodontal intrabony defects, furcation defects, sinus lift operations, and tissue engineering procedures⁽¹⁶⁾. Because the normal PRF isn't quite ready for injection, a novel injectable PRF formulation (dubbed iPRF) makes it possible to employ the platelet concentrate in a liquid state. It maintains its liquid viscosity for around 15 minutes after being created during centrifugation^(17,18). By altering spin centrifugation pressures, an injectable platelet-rich fibrin (iPRF) was produced in 2014⁽¹⁹⁾. The blood centrifuged at lower rates in non-glass centrifugation tubes yielded iPRF, which is a flowable platelet rich fibrin. The i-human PRF's liquid fibrinogen is progressively transformed into fibrin, which can serve as an autologous fibrin binder (AFB). Clinicians have lately adopted this approach to increase biomaterial coating in order to improve wound healing⁽²⁰⁾.

At 1, 2, and 3 months, mean probing depth and clinical attachment level assessments demonstrated a statistically significant decrease ($p < 0.001$) in PRP, iPRF, and Control. The findings showed that three months after starting therapy, therapeutic modalities could result in statistically significant improvements in all clinical indicators studied. The excellent clinical outcomes of the group after three months coincide with der Weijden and Timmerman's prior findings on the clinical efficacy of SRP in the treatment of CP. This suggests that SRP was effective in lowering PPD and enhancing CAL in CP patients⁽²¹⁾.

The iPRF group had the greatest reduction of probing depth from baseline to two months, followed by the PRP group and the control group had the least reduction of pocket depth. Clinical attachment level was reduced by 56.21-14.71 percent in the iPRF group from baseline to one month, compared to 40.18- 16.09 percent in the PRP group and 36.73 -14.17 percent in the control group. The iPRF group had a greater drop from baseline to two months, with a score of 76.76- 20.03, compared to 79.16 -13.90 for the PRP group and 60.39 -10.87 for the control group. The reduction in the iPRF group was 84.80

-17.10 from baseline to three months, whereas the PRP group was 82.84 -11.63 and the control group was 74.07- 6.84. Dsa et al.⁽²²⁾, compared the efficacy of injectable platelet-rich fibrin (iPRF) to platelet-rich fibrin (PRF) in the treatment of periodontal defects, which agreed with our findings. Clinical and radiological measures showed a considerable improvement from baseline. iPRF and PRF Group, on the other hand, outperformed the control group in every metric. The mean PI (1.65 0.18) and GI (1.19 0.06) in the I-PRF group improved throughout time from baseline to 9 months. Similarly, the PPD was lower after 9 months (5.80- 1.54) than at baseline (5.80- 1.54). Defect depth decrease (7.39 -1.46 from baseline to 9 months) was similarly improved; however, all of the measures in the iPRF group exhibited a statistically significant difference. In the treatment of intrabony defects in chronic periodontitis, iPRF and PRF have showed better clinical and radiographic outcomes than control.

In comparison to OFD, Yajamanya et al.⁽²³⁾ compared PRF and iPRF (sticky bone) in intrabony defects. All three groups and their subgroups had a statistically significant difference. However, Group II (iPRF) had much better results in terms of clinical parameters and defect depth reduction, although having a little greater bone level. After 9 months, the percentage of defect depth reduction for OFD, iPRF, and PRF was 41.59 percent, 72.75 percent, and 62.11 percent, respectively.

The larger clinical utility of CAL gain may be due to the fact that iPRF promotes faster wound healing, decreased short-term gingival inflammation, and long-term periopathogenic bacteria reduction⁽¹⁷⁾. Dohan et al. conducted a study⁽²⁴⁾. iPRF includes more GFs than PRF, which has six to seven times the amount of GFs as PRP. Furthermore, those GFs are released slowly over the course of 21 days. The method is enabled by the fact that iPRF is synthesised into a matrix scaffold after a short length of time, about 15 minutes⁽⁹⁾.

The scaffold was shown to have a direct effect on the ability of human gingival fibroblasts to

migrate, proliferate, release more GFs, and develop periodontal ligament cells, as well as increasing osteoblast differentiation⁽²⁵⁾. A new attachment on root surfaces can be generated by preventing junctional epithelium from growing down to the root surfaces and reducing its interaction with the root and soft tissue.

iPRF is built on the same principle as PRF, except it comes in an injectable version. Because iPRF is available in a liquid form, it is ideal for use in periodontal pockets. This injectable PRF has the benefit of being easily combined with other biomaterials or used alone. Because of the slower and shorter centrifugation spin, it is thought to have a higher number of regeneration cells and a higher concentration of growth factors⁽²⁶⁾. Furthermore, because of its fibrin components, iPRF generates a tiny clot that behaves like a dynamic gel-containing cells and releases extra growth factors even after 10 days⁽²⁷⁾.

CONCLUSION

iPRF is suitable for periodontal pocket application due to its advantage of being in a liquid form. In the current study, an effect of iPRF was detected during the first 3 months and these can be attributed to the repeated injection of iPRF that showing iPRF expresses a stronger and more durable effect. The repeated injection of iPRF showing a stronger and more durable effect, since it has number of growth factors which are responsible for tissue regeneration capable of inducing fibroblast behaviour.

REFERENCES

1. Papapanou PN, Sanz M, Buduneli N, Dietrich T, Feres M, Fine DH, et al. Periodontitis: Consensus report of workgroup 2 of the 2017 World Workshop on the Classification of Periodontal and Peri-Implant Diseases and Conditions. *J Periodontol* 2018; 89(Suppl 1):S173-s82.
2. Noguchi S, Ukai T, Kuramoto A, Yoshinaga Y, Nakamura H, Takamori Y, Yamashita Y, Hara Y. The histopathological comparison on the destruction of the periodontal tissue between normal junctional epithelium and long junctional epithelium. *Journal of Periodontal Research*. 2017 Feb;52(1):74-82.2.

3. Wikesjö UM, Selvig KA. Periodontal wound healing and regeneration. *Periodontology* 2000. 1999 Feb;19(1):21-39.
4. Agrawal AA. Evolution, current status and advances in application of platelet concentrate in periodontics and implantology. *World J Clin Cases* 2017; 5(5):159-71.
5. Vučković M, Nikolić N, Milašin J, Đorđević V, Milinković I, Asotić J, et al. The effect of injectable platelet-rich fibrin use in the initial treatment of chronic periodontitis. *Srp Arh Celok Lek* 2020; 148(5-6):280-5.
6. Weibrich G, Hansen T, Kleis W, Buch R, Hitzler WE. Effect of platelet concentration in platelet-rich plasma on peri-implant bone regeneration. *Bone* 2004; 34(4):665-71.
7. Zechner W, Tangl S, Tepper G, Fürst G, Bernhart T, Haas R, et al. Influence of platelet-rich plasma on osseous healing of dental implants: a histologic and histomorphometric study in minipigs. *Int J Oral Maxillofac Implants* 2003; 18(1):15-22.
8. Egelberg J. Regeneration and repair of periodontal tissues. *J Periodontol Res.* 1987;22:233-242.
9. Karimi K, Rockwell H. The Benefits of Platelet-Rich Fibrin. *Facial Plast Surg Clin North Am* 2019; 27(3):331-40.
10. Choukroun J. Advanced PRF, & i-PRF: platelet concentrates or blood concentrates. *J Periodontal Med Clin Pract* 2014; 1(1):3.
11. Mila Vučković, Nađa Nikolić, Jelena Milašin et al. The effect of injectable platelet-rich fibrin use in the initial treatment of chronic periodontitis. *Srp Arh Celok Lek.* 2020;148(5-6):280-285.
12. Heitz-Mayfield LJ, Lang NP. Surgical and nonsurgical periodontal therapy. Learned and unlearned concepts. *Periodontology* 2000. 2013; 62(1):218-231
13. Cugini M, Haffajee A, Smith C, Kent R Jr, Socransky S. The effect of scaling and root planing on the clinical and microbiological parameters of periodontal diseases: 12-month results. *J Clin Periodontol.* 2000;27(1):30-36
14. Yusri S, Elfana A, Elbattawy W, Fawzy El-Sayed KM. Effect of locally delivered adjunctive antibiotics during surgical periodontal therapy: a systematic review and meta-analysis. *Clinical oral investigations.* 2021 Sep; 25(9):5127-38.
15. Miron RJ, Fujioka-Kobayashi M, Hernandez M, Kandam U, Zhang Y, Ghanaati S, et al. Injectable platelet rich fibrin (i-PRF): opportunities in regenerative dentistry? *Clin Oral Investig* 2017; 21(8):2619-27.
16. Chen FM, Gao LN, Tian BM, Zhang XY, Zhang YJ, Dong GY, et al. Treatment of periodontal intrabony defects using autologous periodontal ligament stem cells: a randomized clinical trial. *Stem Cell Res Ther* 2016; 7:33.
17. Choukroun J, Ghanaati S. Reduction of relative centrifugation force within injectable platelet-rich-fibrin (PRF) concentrates advances patients' own inflammatory cells, platelets and growth factors: the first introduction to the low speed centrifugation concept. *Eur J Trauma Emerg Surg* 2018; 44(1):87-95.
18. El Bagdadi K, Kubesch A, Yu X, Al-Maawi S, Orłowska A, Dias A, et al. Reduction of relative centrifugal forces increases growth factor release within solid platelet-rich-fibrin (PRF)-based matrices: a proof of concept of LSCC (low speed centrifugation concept). *Eur J Trauma Emerg Surg* 2019; 45(3):467-79.
19. Wang X, Zhang Y, Choukroun J, Ghanaati S, Miron RJ. Effects of an injectable platelet-rich fibrin on osteoblast behavior and bone tissue formation in comparison to platelet-rich plasma. *Platelets* 2018; 29(1):48-55.
20. Mourão CF, Valiense H, Melo ER, Mourão NB, Maia MD. Obtention of injectable platelets rich-fibrin (i-PRF) and its polymerization with bone graft: technical note. *Rev Col Bras Cir* 2015; 42(6):421-3.
21. Van der Weijden GA, Timmerman MF. A systematic review on the clinical efficacy of subgingival debridement in the treatment of chronic periodontitis. *J Clin Periodontol* 2002; 29 Suppl 3:55-71.
22. Dsa E, Chatterjee A, Shetty DN, Pradeep AR. Clinical evaluation and comparison of platelet-rich fibrin and injectable platelet-rich fibrin (sticky bone) in the treatment of intrabony defects. *Nigerian J Experiment Clin Biosc* 2020; 8(2):78.
23. Yajamanya SR, Chatterjee A, Hussain A, Coutinho A, Das S, Subbaiah S. Bioactive glass versus autologous platelet-rich fibrin for treating periodontal intrabony defects: A comparative clinical study. *J Indian Soc Periodontol* 2017; 21(1):32-6.
24. Dastoor SF, Travan S, Neiva RF, Rayburn LA, Giannobile WV, Wang HL. Effect of adjunctive systemic azithromycin with periodontal surgery in the treatment of chronic periodontitis in smokers: a pilot study. *J Periodontol* 2007; 78(10):1887-96.
25. Dohan Ehrenfest DM, de Peppo GM, Doglioli P, Sammartino G. Slow release of growth factors and thrombospondin-1 in Choukroun's platelet-rich fibrin (PRF): a gold standard to achieve for all surgical platelet concentrates technologies. *Growth Factors* 2009; 27(1):63-9.
26. Kour P, Pudukalkatti PS, Vas AM, Das S, Padmanabhan S. Comparative Evaluation of Antimicrobial Efficacy of Platelet-rich Plasma, Platelet-rich Fibrin, and Injectable Platelet-rich Fibrin on the Standard Strains of *Porphyromonas gingivalis* and *Aggregatibacter actinomycetemcomitans*. *Contemp Clin Dent* 2018; 9(Suppl 2):S325-s30.
27. Ghanaati S, Booms P, Orłowska A, Kubesch A, Lorenz J, Rutkowski J, et al. Advanced platelet-rich fibrin: a new concept for cell-based tissue engineering by means of inflammatory cells. *J Oral Implantol* 2014; 40(6):679-89.
28. Bennett NT, Schultz GS. Growth factors and wound healing: part II. Role in normal and chronic wound healing. *Am J Surg.* 1993;166(1):74-81