



CLINICAL AND RADIOGRAPHIC EVALUATION OF SIMVASTATIN VERSUS FORMOCRESOL IN TREATMENT PULPOTOMIZED PRIMARY TEETH

Abd El-Aaty Gamal Abd El-Aaty^{1*}, Ibrahim Farouk Barakat², Alaa Nabil Abbas³

ABSTRACT

Objectives: This study was directed to evaluate the effect of simvastatin as pulpotomy medicament in the primary molar teeth, to determine its clinical and radiographic success rate and to compare it with formocresol (FC). **Subjects and Methods:** Children aged between 3-7 years which had a total of 80 decayed primary molar teeth indicated for pulpotomy treatment were included in this study. The involved teeth were grouped into two groups according to the received medicament; Group A; Pulpotomized teeth received simvastatin; Group B; Pulpotomized teeth received formocresol. The clinical and radiographic evaluation were made after 1-week, 3-months, and 6-months follow specific criteria. **Results:** Pulpotomized teeth which received formocresol showed slightly higher success rate, but both of simvastatin and formocresol treated teeth showed comparable clinical and radiographic clinical success rates with no statistically significant difference. **Conclusion:** Simvastatin can be used as effective alternative medicament for formocresol in the treatment of pulpotomized primary molar teeth.

KEYWORDS: Formocresol, Primary Teeth, Pulpotomy, Simvastatin

INTRODUCTION

The primary goal of pulp therapy in children is the preservation of their deciduous teeth until the normal time of exfoliation⁽¹⁾. Pulpotomy is one of the most frequently used treatments for retaining curiously involved primary molars that would otherwise be extracted⁽²⁾. It can be considered as the standard treatment for vital primary teeth with carious pulp exposures⁽³⁾.

Formocresol (FC) is one of the frequently used pulp medicaments for decades either in primary or permanent teeth⁽⁴⁾. It is the mostly used medicament

in the pulpotomized primary teeth to preserve the pulp involved teeth from early extraction^(4,5). However, the use of formocresol as a pulpotomy medicaments faced recently huge challenges because of its formaldehyde content which reported considerable carcinogenic potentials, cytotoxicity and systemic distribution, as well as it stimulates inflammatory response of the pulp tissues⁽⁶⁾.

Because of these considerable side-effects, researches directed toward looking for other applicable and viable alternatives to formocresol⁽⁷⁾. These alternatives include biologic materials such

1. Masters candidate.
2. Associate Professor, Pedodontics and Oral Health Department, Faculty of Dental Medicine, Boys, Cairo, Al-Azhar University.
3. Lecturer of Pedodontics, Faculty of Dental Medicine, Boys, Cairo, Al Azhar University.

• **Corresponding author:** dentistboody2012@gmail.com

as mineral trioxide aggerate (MTA), calcium hydroxide (Ca-HO), or antiseptic materials as glutaraldehyde (GAh), or hemostatic materials like ferric sulfate (FS), or physical-substitutes as electro-surgery, and laser ^(7,8).

Simvastatin is a statins-based drug, was classified as a safe drug worldwide after its use for long-time which has structural analogs of HMG-CoA (3-hydroxy-3-mthylglutaryl-coenzyme-A)⁽⁹⁾. Simvastatin the first-line of treatment for hyperlipidemia which used systemically to control the higher cholesterol levels in blood ⁽¹⁰⁾. Moreover, it was found that when simvastatin systemically administrated in patients with chronic periodontitis, it reduces risk of tooth loss⁽¹¹⁾. Also, it has a potent antimicrobial effect ⁽¹²⁾. Additionally, when simvastatin is applied topically around the tooth decreases the inflammatory response⁽¹³⁾. However, it was reported that the application of simvastatin at higher concentration to the exposed pulp of the primary teeth resulted higher inflammatory response, but when applied in low concentration it forms dentine-like bridge ⁽¹⁴⁾.

Therefore, this study was conducted to evaluate clinically and radiographically the efficacy of simvastatin as pulpotomy agent in primary teeth, and compare it with formocresol as the standard pulpotomy agent.

SUBJECT AND METHODS

This study was designed as interventional randomized controlled clinical study. The ethical approval was obtained from Ethical Committee, Faculty of Dental Medicine, Al-Azhar University (Boys, Cairo) before starting this study. The enrolled children from both genders were aged between 3-7 years and selected from outpatients of the Pedodontics and Oral Health Department, Faculty of Dental Medicine, Al-Azhar University (Cairo, Boys).

The current study involved 80 carious primary teeth indicated for pulpotomy treatment. The involved teeth were randomly divided into two equal groups (n=40) according to the received

pulpotomy treatment; group A; Pulpotomized teeth received simvastatin; Group B; Pulpotomized teeth received FC (control group).

Subject selection:

All selected children parents were informed about the all required information about this clinical study including; treatment procedures and follow-up periods before starting and then each parent signed a detailed informed consent. Children enrolled in this study should have at least on decayed primary molar with vital pulp involvement without any clinical or radiographic sign of preapical inflammation or pathosis. However, presence of any mobility, sensitivity to percussion, pathologic root resorption, preapical pathosis or furcation involvement were considered as exclusion criteria ^(15,16).

Operative procedures:

Pulpotomy procedures:

The pulpotomy procedures was performed as follows: administration of local anesthesia, followed by isolation of the operative side with rubber dam. Then, all caries was removed with a high-speed handpiece and carbide bur. After that, access cavity preparation by a sterile fissure bur. The coronal pulp was amputated entirely with sharp spoon excavator. Then, the pulp chamber was rinsed with water and the hemorrhage was stopped with cotton pellets moistened with normal saline ⁽¹⁷⁾ as showing in figure (1).

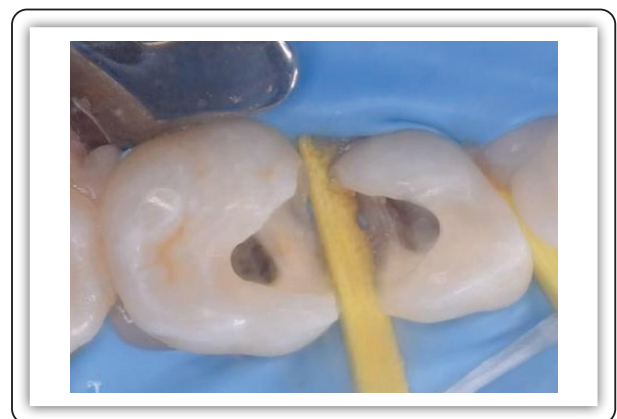

FIG (1) Gaining access and cavity preparation.

Restoration procedures:

After ending the pulpotomy protocols, a capping material of simvastatin (Prepared in Pharmacology Department, Faculty of Pharmacy, Al-Azhar University); or FC (Formol 50%, tricresols 35%, excipients qs 100%. Presentation 10 ml dropper bottle. Pharma Dent) was placed directly on the radicular pulp along with its related group as showing in Figure (2). Then, this capping was covered with glass ionomer cement (Light-curing glass ionomer VOCO, GmbH, Germany) till the cavity was filled. Finally, the pulpotomized teeth were restored with stainless-steel crowns (3M ESPE, USA) (18).

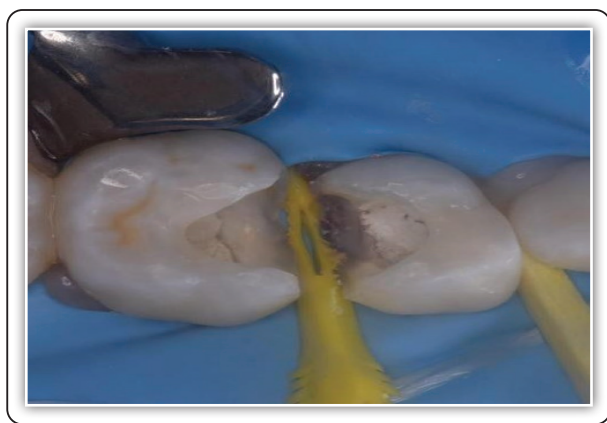


FIG (2) Placement of simvastatin paste.

Clinical and radiographic evaluation:

The postoperative clinical and periapical radiographic follow-up evaluation were performed after 1-week, 3-months, and 6-months. The restored teeth with any clinical signs of mobility, pain, swelling, or sensitivity to percussion was considered clinically failure. However, teeth with presence of any preapical sign of pathosis or radiolucency due to infection was considered a radiographic failure(16).

Statistical analysis

The collected numerical data were tabulated and analyzed statistically using Chi-square test to compare between groups at different follow-up time. The results considered significant statistically at p-value less than 0.05.

RESULTS

The results of this study showed non-statistically significant difference regard to age and gender between the both studied groups (Table 1). However, the results of the clinical and radiographic follow-up of this study also showed non-statistically significant difference between the both studied group regarding to the success and failure rates at the all follow-up periods.

TABLE (1) Comparison between the two studied groups according to demographic data.

Variables	Scores				p-value	
	Group A		Group B			
	N	%	N	%		
Age	< 5years	11	27.5%	7	17.5%	0.287ns
	> 5 years	29	72.5%	33	82.5%	
Gender	Female	21	52.5%	28	70%	0.110ns
	Male	19	47.5%	12	30%	

*; significant at $p < 0.05$.

; non-significant (ns) at $p > 0.05$.

TABLE (2): Comparison between the two studied groups according to Success in each period.

Variables	Success and Failure				p-value	
	Group A		Group B			
	N	%	N	%		
1- Week	Failure	0	0%	0	0%	1ns
	Success	40	100%	40	100%	
3- Months	Failure	4	10%	3	7.5%	0.694ns
	Success	36	90%	37	92.5%	
6- Months	Failure	5	12.5%	3	7.5%	0.459ns
	Success	35	87.5%	37	92.5%	

*; significant at $p < 0.05$.

; non-significant (ns) at $p > 0.05$.

DISCUSSION

Ideally, the material used for pulp dressing during pulpotomy treatment of the carious primary teeth must have specific criteria including; bactericidal effect, promoting radicular pulp healing, and did not have adverse effect on pulp or surrounding dental structures, as well as it did not interfere with the physiological process of root resorption⁽¹⁹⁾. Therefore, this study was aimed to investigate the effect of simvastatin and formocresol on the success rate of pulpotomized primary teeth.

Formocresol was selected as control group in this study since is still considered the gold standard pulp dressing medicament during pulpotomy of the primary teeth. However, a viable alternative should be investigated to replace it due to its hazardous systematic effects particularly on kidney and liver as well as its carcinogenic and cytotoxic effect⁽²⁰⁾. In addition to its harmful effect on the enamel of the permanent successors⁽²¹⁾. Therefore, simvastatin was chosen as a tested material because of its safe long-term action in addition to their antimicrobial activity^(9,12).

In this study children were selected with age ranging between 3 -7 years to ensure patient cooperation. Also, this because, this age range is the most preferable age range in which the root of teeth was with considerable length where, and no root resorption started yet or minimal range of root resorption could only exist⁽²²⁾.

The results of this study found that the success rate of simvastatin as a pulpotomy dressing (87.5%). This because the theory that of controlling hemorrhage might minimize the chances for inflammation and internal resorption believed by some investigators to be associated with physiologic clot formation. However, investigators have not explained how clotting itself could curtail these activities⁽²³⁾.

Also, Aminabadi et al.,⁽²⁴⁾ in their study reported mild to moderate pulp inflammation in responding to pulp capping with simvastatin which increase with

time and this might be attributed to the immediate inflammatory reaction of the periradicular tissues. This in accordance with the results of this study where the failure rate increases with time.

However, formocresol as a pulpotomy dressing in this study exhibited a higher success rate of (92.5%). This may be because the higher antibacterial effect of FC which able to control the infection and hence prevent the further pulp inflammation and root resorption⁽²⁵⁾. Also, FC had the ability to penetrated the pulp tissue apically for a few millimeters, resulting in a partial pulp tissue fixation and formation of barrier that prevent the passage of harmful bacterial ingredient to the radicular pulp⁽²⁶⁾.

CONCLUSION

Simvastatin has a comparable clinical and radiographic success rate with the standard pulp dressing material; Simvastatin and can be used as effective alternative pulp medicament for FC in the treatment of pulpotomized primary teeth.

REFERENCE

1. Huth KC, Paschos E, Hajek-Al-Khatat N, Hollweck R, Crispin A, Hickel R, Folwaczny M. Effectiveness of 4 pulpotomy techniques-randomized controlled trial. *J Dent Res.* 2005; 84:1144-8.
2. Martin FE. Carious pulpitis: microbiological and histopathological considerations. *Aust Endod J.* 2003; 29:134-7.
3. Murray PE, About I, Franquin JC, Remusat M, Smith AJ. Restorative pulpal and repair responses. *J Am Dent Assoc.* 2001; 132:482-91.
4. Bhayat A, Ahmad M, Hifnawy T, Mahrous M, Al-Shorman H. Correlating dental caries with oral bacteria and the buffering capacity of saliva in children in Madinah, Saudi Arabia. *J IntSocPrev Community Dent.* 2013; 3:38-43.
5. Yang F, Zhang Y, Yuan X, Yu J, Chen S. Caries experience and its association with weight status among 8-year-old children in Qingdao, China. *J IntSocPrev Community Dent.* 2015; 5: 52-8.
6. Witherspoon D. Vital pulp therapy with new materials: new directions and treatment perspectives-permanent teeth. *J Endo.* 2008; 34: S25-8.

7. Avram D, Pulver F. Pulpotomy medicaments for vital primary teeth: surveys to determine use and attitudes in pediatric dental practice and in dental schools throughout the world. *ASDC J Dent Child*. 1989; 56: 426–34.
8. Fuks A, Eidelman E, Cleaton-Jones P, Michaeli Y. Pulp response to ferric sulfate, diluted formocresol and IRM in pulpotomized primary baboon teeth. *ASDC J Dent Child*. 1997; 64: 254–9.
9. Okamoto Y, Sonoyama W, Ono M, Akiyama K, Fujisawa T. Simvastatin induces the odontogenic differentiation of human dental pulp stem cells in vitro and in vivo. *J Endod* 2009; 35:367–72.
10. Mundy G, Garrett R, Harris S, Chan J, Chen D, Rossini G, et al. Stimulation of bone formation in vitro and in rodents by statins. *Science*. 1999, 286, 1946–1949.
11. Cunha-Cruz J, Saver B, Maupome G, Hujoel P. Statin use and tooth loss in chronic periodontitis patients. *J Periodont*. 2006;77: 1061-1066.
12. Emani S, Gunjiganur G, Mehta D. Determination of the antibacterial activity of simvastatin against periodontal pathogens, *Porphyromonas gingivalis* and *Aggregatibacter actinomycetemcomitans*: An in vitro study. *Contemp Clinic Denti*. 2014; 5:377-81.
13. Pradeep A, Thorat M. Clinical effect of subgingivally delivered simvastatin in the treatment of patients with chronic periodontitis: a randomized clinical trial. *J Periodont*. 2010; 81:214-22.
14. Aminabadi N, Maljaei E, Erfanparast L, et al. Simvastatin versus calcium hydroxide direct pulp capping of human primary molars: a randomized clinical trial. *J Dent Res Dent Clin Dent Prosp*. 2013; 7:8–14.
15. John A, Webb T, Imamura G, Goodell G. Fluid flow evaluation of Fuji Triage and gray and white ProRoot mineral trioxide aggregate intraorifice barriers. *J Endod*. 2008; 34:830-2.
16. Ferracane J, Cooper P, Smith A. Can interaction of materials with the dentin-pulp complex contribute to dentin regeneration. *Odontology* 2010; 98:2-14.
17. Dammaschke T, Gerth H, Züchner H & Schäfer E. Chemical and physical surface and bulk material characterization of white ProRoot MTA and two Portland cements. *Dent Mater*. 2005; 21: 731–8.
18. Seto H, Ohba H, Tokunaga K, Hama H, Horibe M, Nagata T. Topical application of simvastatin recovers alveolar bone loss in rats. *J Periodontal Res* 2008; 43:261–7.
19. Pruhs R J, Olen G A. and Sharma P. S.; Relationship between formocresol pulpotomies on primary teeth and enamel defects on their permanent successors. *JADA*., 1977; 94: 698-700.
20. Ranly D M and Horn D; Assessment of the systemic distribution and toxicity of formaldehyde following pulpotomy treatment. *J. Dent Child*; 1987; 54:40-6.
21. Messer L B, Cline J T, Korf N W. Long term effects of primary molar pulpotomies on succedaneous bicuspid. *J Dent Res*. 1980; 59: 116-23.
22. Neamatollahi H, Tajik A. Comparison of clinical and radiographic success rates of pulpotomy in primary molars using Formocresol, Ferric Sulfate and Mineral Trioxide Aggregate (MTA). *J of Dent* 2006; 3: 6-14.
23. Esfahani N. E, Sadeghian S, Razavi M, Minaiyan M, Afshari E. The Effects of Simvastatin on Bone Remodeling, Tooth Movement and Root Resorption in Orthodontic Treatments. *Biomed Pharmacol J*. 2013; 6:271-8.
24. Asl Aminabadi N, Maljaei E, Erfanparast L, Ala Aghbali A, Hamishehkar H, Najafpour E. Simvastatin versus calcium hydroxide direct pulp capping of human primary molars: A randomized clinical trial. *J Dent Res Dent Clin Dent Prospects*. 2013; 7:8-14.
25. American Academy of Pediatric Dentistry. Pulp therapy for primary and immature permanent teeth. *The Reference Manual of Pediatric Dentistry*. Chicago, Ill.: American Academy of Pediatric Dentistry; 2020:384-92.
26. Namour M, Theys S. Pulp revascularization of immature permanent teeth: a review of the literature and a proposal of a new clinical protocol. *Sci World J*. 2014; 2014:737503.