

## Thyroid Autotransplantation after Total Thyroidectomy in Benign Thyroid Diseases

Mohamed Bakr Mohamed Kotb, Ahmed Mohamed Gamal Hemdan\*, Mahmoud Thabet Ayoub

Department of General Surgery, Faculty of Medicine, Assuit University

Corresponding authors: Ahmed Mohamed Gamal Hemdan, E-mail: [kottb73@gmail.com](mailto:kottb73@gmail.com),

Mobile number:01012127297

### ABSTRACT

**Background:** After achievement of parathyroid autotransplantation, thyroid autotransplantation was presented with goal of preventing or lessening severity of post-thyroidectomy hypothyroidism in noncompliant patients.

**Goal and objectives:** In this research, we intended to evaluate efficacy of autotransplantation of thyroid tissue after total thyroidectomy (TT) in benign thyroid disorders to keep the patient euthyroid with no need for life long hormone replacement therapy.

**Studied cases and methods:** The study included thirty patients with benign thyroid disorders for whom total thyroidectomy was done. Autotransplantation was done by excising an apparently healthy portion weighing about 2-5 gm from the resected thyroid gland after total thyroidectomy and slicing this portion into about 10 small fragments then inserting these fragments into pocket made in the sternomastoid muscle. Follow up process contained measurement of serum levels of T3, T4 and TSH and thyroid scanning by <sup>99m</sup>Tc-MIBI scintigraphy. **Results:** Serum calcium level following total thyroidectomy: 28 patients had normal serum calcium level (8.5mg/dl- 10.5mg/dl) and only 2 patients developed hypocalcaemia. These 2 patients were advised to take oral calcium to correct hypocalcaemia with regular follow up. **Conclusion:** Thyroid autotransplantation after total thyroidectomy is effective way to avoid postoperative hypothyroidism in benign thyroid disorders.

**Keywords:** Thyroid; Auto-transplantation; Total thyroidectomy; Benign; Auto-implanted

### INTRODUCTION

Whole thyroidectomy is standard of care for patients with bilateral benign thyroid complaints <sup>(1)</sup>. Several authors stated that TT can be done safely and with little problem rates using meticulous surgical method <sup>(2,3,4)</sup>. Even though surgery is good option for avoiding habitual medication consumption, patients still necessitate life-long levothyroxine replacement treatment, that was linked to coronary heart disease and lipid metabolism dysfunction <sup>(5,6)</sup>.

Postoperative control of hypothyroidism after TT by L-T4 replacement treatment appears simple, however for patients, daily dose of L-T4 and regular follow-up visits to hospital may become somewhat burdensome, and can interfere with achieving euthyroid status using replacement treatment because of patients noncompliance <sup>(7,8)</sup>. Another issue that may impede achieving euthyroid status with replacement treatment is medication mal-absorption caused by any gastrointestinal disorder <sup>(9)</sup>.

Heterotopic thyroid auto-transplantation was suggested to prevent reoperation at location of previous neck surgery <sup>(10)</sup>.

At this study, we aimed at evaluating efficacy of auto-transplantation of thyroid tissue after TT in benign thyroid disorders to keep the patient euthyroid with no need for life long hormone replacement therapy.

### STUDIED CASES AND METHODS

This study was carried out at Assiut University Hospital. The hospital is a main education hospital for Assiut University Faculty of Medicine. Adult patients with goiters were seen in the general surgery outpatient

clinic. The outpatient clinic was run by general surgery professor who was assisted by assistant lecturer, senior residents, intern doctors, and nursing officers.

The study included thirty studied cases presented in the outpatient clinic with benign thyroid disorders for whom total thyroidectomy was performed.

### Ethical Approval:

This research was approved by Assiut University Ethics Board, and each participant signed informed written consent form. Research's goal and therapy techniques were carefully explained to each studied case individually. They were free to ask questions to confirm that they understood. This work was done in accordance with World Medical Association's Code of Ethics for human researches.

**Inclusion Criteria:** Adult men or women with benign thyroid disease, suitable for anaesthesia, providing written informed consent, and agreeing to provide short term result data and contact information.

**Exclusion Criteria:** Children, patients deemed unfit for anaesthesia (ASA score greater than two), and suffering from malignant or recurring goiter.

**Sampling Procedure:** studied cases with benign thyroid disorders seen in outpatient clinic were interviewed and clinically assessed by principal investigator.

History taking, physical test, requesting and reviewing laboratory examinations, and imaging researches were all part of screening process for surgical suitability.

Goal was to document key research variables and major co-morbidities. Those who did not meet inclusion criteria and had other medical issues were given same routine care as all other studied cases.

**Interventions:**

**Preparation:**

The following procedures were performed: All studied cases received full valuation in procedure of full history and physical test, as well as routine preoperative laboratory surveys such as full blood count, liver function examinations, kidney function examinations, thyroid function exams, serum calcium, ECG and chest X-ray, neck ultrasound, and fine needle aspiration cytology. Studied cases also received preoperative laryngoscopic test to evaluate both vocal cord mobility.

**Operative technique:** All studied cases received general endotracheal anaesthesia, and all underwent total thyroidectomy. Most healthy-looking part of gland was selected after complete excision. Thyroid tissue to be transplanted weighed between two and five grammes. This section was finely split into ten-fifteen fragments with scalpel. Small pocket was created in sternomastoid muscle, into which these minor fragments were implanted, and this pocket was closed with absorbable sutures to prevent displacement of implanted fragments and was marked with metallic staples, as well as good hemostasis of thyroid bed and skin was closed with subcuticular sutures using absorbable three-zero Vicryl sutures.

**Follow-up:**

After one month, serum levels of T3, T4, and TSH were measured, and every three months, to assess functional ability of implanted thyroid tissue, as well as serum calcium levels. Tc-99m pertechnetate scintigraphy with SPECT-CT was performed from six to nine months after surgery to assess functional ability of transplanted thyroid tissue. Tc-99m pertechnetate scintigraphy was performed with gamma camera (Siemens, symbiat SPECT-CT, Germany) prepared with parallel-hole low energy all purpose collimator. 20 minutes after intravenous injection of 185 MBq of Tc-99m pertechnetate, anterior and left/right anterior oblique thyroid images were acquired. SPECT images of neck were acquired immediately following planar scintigraphy. We created transverse, sagittal, and coronal slices. Then, without use of contrast medium, CT scans were obtained.

**Statistical methods**

The collected data will be coded, processed and analyzed using SPSS program (Version 25) for windows. Descriptive statistics will be calculating to

include means, standard deviations, medians, ranges, and percentages. For continuous variables, independent t-tests will be performing to compare the means of normally distributed data, while Mann–Whitney U tests will be used to compare the median differences of the data that were not normally distributed, and chi-square test for categorical data. The t test and Wilcoxon test will be used in dependent groups. A p value below 0.05 considered statistically significant.

**RESULTS**

This research involved thirty studied cases. The personal and clinical data are shown in table 1.

**Table (1): Personal and clinical data**

	No. (n= 30)	%
<b>Age: (years)</b>		
<b>20- 30</b>	<b>9</b>	<b>30.0</b>
<b>30 - &lt; 40</b>	<b>10</b>	<b>33.3</b>
<b>40-55</b>	<b>11</b>	<b>36.7</b>
<b>Mean ± SD (Range)</b>	<b>36.23 ± 9.72 (20.0 – 55.0)</b>	
<b>Gender:</b>		
<b>Men</b>	<b>Seven</b>	<b>23.3</b>
<b>Women</b>	<b>Twenty three</b>	<b>76.7</b>
<b>Diagnosis:</b>		
<b>secondary toxic goiter</b>	<b>5</b>	<b>16.7</b>
<b>Graves disease</b>	<b>7</b>	<b>23.3</b>
<b>Simple nodular goiter</b>	<b>18</b>	<b>60.0</b>

The most common postoperative histopathological diagnosis was colloid nodular goitre (Table 2).

**Table (2): Postoperative histopathology**

Postoperative histopathology	No. (n= 30)	%
<b>Colloid nodular goiter</b>	<b>16</b>	<b>53.3</b>
<b>Diffuse toxic goiter</b>	<b>4</b>	<b>13.3</b>
<b>Hashimoto thyroiditis</b>	<b>2</b>	<b>6.7</b>
<b>Toxic nodular goiter</b>	<b>8</b>	<b>26.7</b>

Postoperative thyroid function follow-up at one, three, six, nine, and twelve months discovered statistically significant progressive rise in serum T3 and T4 levels returning to normal levels after six months of total thyroidectomy without hormone replacement treatment. There was important gradual decrease in serum TSH levels that returns to normal after twelve months (Table 3).

**Table (3): Postoperative follow-up of thyroid function test (n= 30)**

	Pre-operative	After one months	After three months	After six months	After nine months	After twelve months
<b>T3 (µg/dL):</b>						
Mean ± SD	3.32 ± 0.74	0.34 ± 0.05	0.71 ± 0.01	1.30 ± 0.36	2.01 ± 0.32	2.83 ± 0.28
<b>P-value</b>		<0.001*	<0.001*	<0.001*	<0.001*	<0.001*
<b>T4 (µg/dL):</b>						
Mean ± SD	1.57 ± 0.20	0.12 ± 0.02	0.36 ± 0.06	0.75 ± 0.12	1.16 ± 0.26	1.65 ± 0.16
<b>P-value</b>		<0.001*	<0.001*	<0.001*	<0.001*	0.107
<b>TSH (mU/L):</b>						
Mean ± SD	2.16 ± 0.27	72.33 ± 7.16	65.97 ± 15.6	42.40 ± 6.66	21.39 ± 3.89	4.25 ± 1.79
<b>P-value</b>		<0.001*	<0.001*	<0.001*	0.001*	0.011*

T-test

P-Value > 0.05: Non-significant

P-Value < 0.05: Significant

P-Value < 0.001: High significant

Thirteen of fifteen studied cases had functioning thyroid implant (86.7 percent success rate). Ten of them had functioning thyroid implant at sternomastoid muscle with no residual thyroid tissue (Table 4).

**Table (4): Ninety nine mTC scan with complementary SPECT/CT**

	No. (n= fifteen)	%
<b>Functioning thyroid implant:</b>	<b>13</b>	<b>86.7</b>
Functioning thyroid implant at left side of lower neck	8	53.3
Functioning thyroid implant at right side of lower neck	2	13.3
Intense uptake at site of implant with faint tracer uptake at both thyroid bed regions.	3	20
<b>Non-functioning thyroid implant</b>	<b>2</b>	<b>13.3</b>

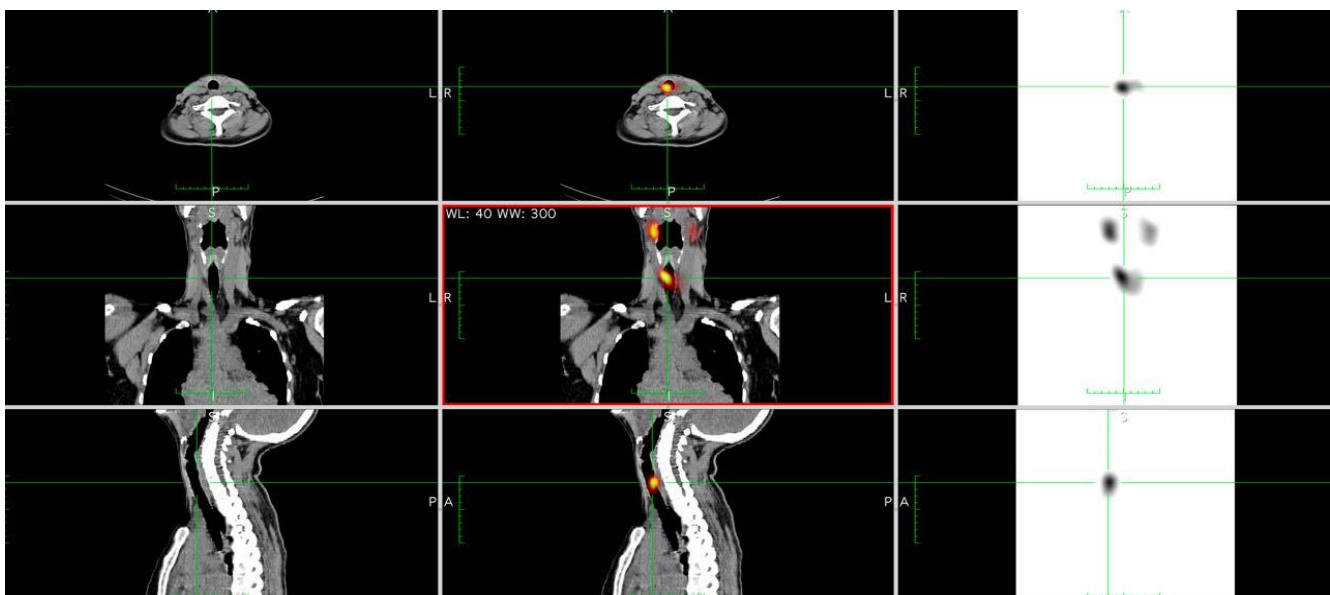

Fig.(1): Following total thyroidectomy, thyroid scan with SPECT/CT images demonstrating radioactive isotope uptake at location of thyroid implant

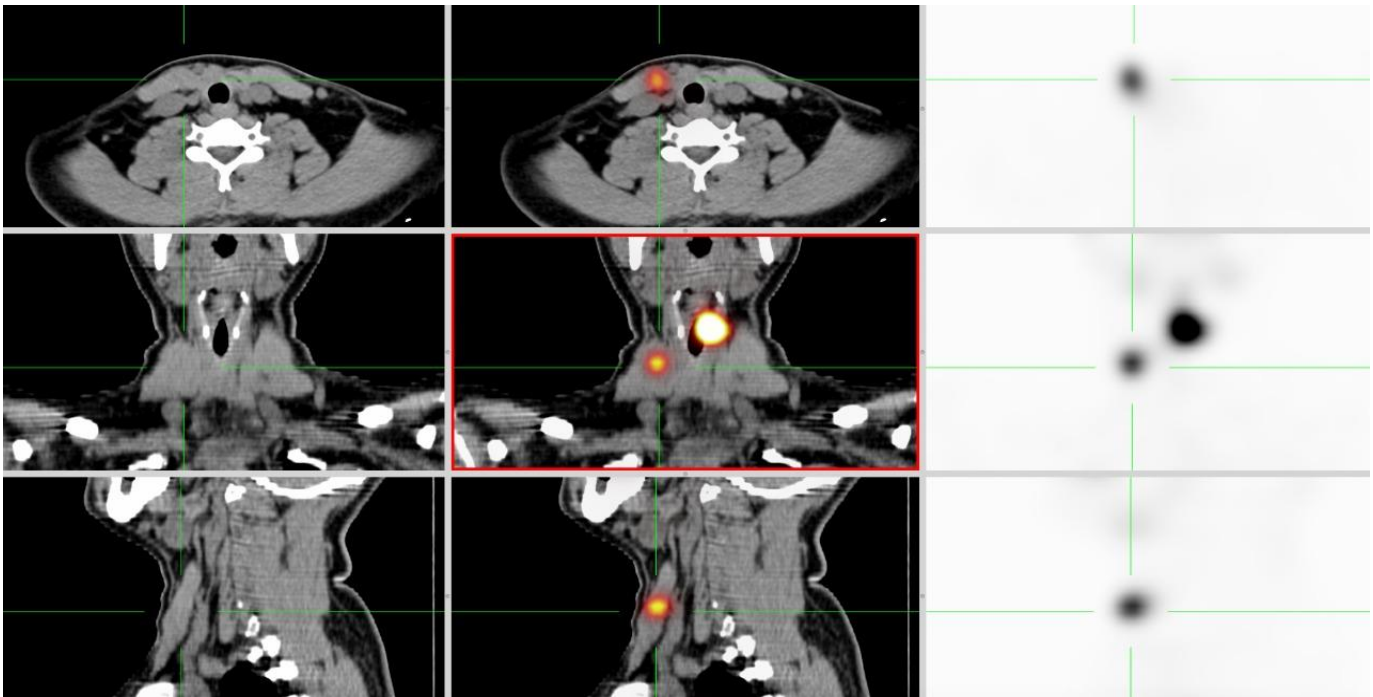


Fig. (2): Thyroid scan with SPECT/CT images demonstrating intense radioactive isotope uptake at implant location with residual functioning thyroid tissue

Table 5 shows that 28 patients had normal serum calcium level (8.5 mg/dl- 10.5 mg/dl) and only 2 patients developed hypocalcaemia. These 2 patients were advised to take oral calcium to correct hypocalcaemia with regular follow up.

**Table (5): Postoperative follow-up of serum calcium**

	After 2 days	After one months	After three months	After six months
<b>Serum calcium</b>				
Mean ±	8.49 ±	8.56 ±	9.03 ±	9.15 ±
SD	0.55	0.33	0.40	0.45
Range	7.0–9.2	7.8–8.8	8.3–9.6	8.4–10.0
<b>P-value</b>		0.465	<0.001*	<0.001*

T-test

P-Value > 0.05: Non-significant

P-Value < 0.05: Significant

P-Value < 0.001: High significant

## DISCUSSION

Goal of auto-transplantation of thyroid tissue after total thyroidectomy is to preserve postoperative thyroid function and avoid lifetime replacement treatment with oral thyroid hormone intake. Another benefit of this technique might be protection of internal auto-regulatory mechanism of thyroid hormone making in accordance with human body requirements. There are few reports in literature on clinical application of thyroid autotransplantation, with only few studied cases in each research. Despite fact that all animal and human researches demonstrated survival and function of thyroid tissue implanted in muscle, method

suffered from heterogeneity in tissue preparation, implant timing, and implant weight variation.

To avoid postoperative hypothyroidism, in 1990, **Okamoto**,<sup>(11)</sup> performed trial of autotransplantation of thyroid tissue at five studied cases with Graves disease whose remnant thyroid had been unintentionally formed minor during subtotal thyroidectomy. Thyroid tissue was cut into minor pieces and transplanted into sternocleidomastoid and strap muscles in amounts ranging from 0.5 to two gm. Even though postoperative serum TSH levels were normal and raised, serum triiodothyronine concentrations have been in normal variety in five studied cases at two-seven years after surgery. In four of five studied cases, thyroid scanning with one-123 and ninety nine mTc-pertechnetate indicated radioisotope uptake at transplantation places. These results confirm that implanted thyroid tissues were alive and functioning, and that autotransplantation could be used to avoid postoperative complications hypothyroidism.

**ROY**<sup>(12)</sup>, carried out another study in 2002 to find if human thyroid tissue auto grafts may survive and function in lack of their native blood supply in muscle. 15 studied cases with benign thyroid disorders, 7 of them had Graves' disease and 8 multinodular goiter (MNG), underwent changed subtotal thyroidectomy and autotransplantation of thyroid tissue in sternocleidomastoid muscle. Small amount of thyroid tissue (three-five gm) was removed and implanted into sternocleidomastoid muscle. To evaluate purpose of remnant and transplanted thyroid tissue, postoperative clinical assessments, thyroid function exams, and technetium scans of neck were performed. transplanted tissue was functional in 6 of 8

studied cases with MNG and 4 of 7 with Graves' disease, according to findings. Within six months of surgery, studied cases with MNG and functional transplant were euthyroid. Even though transplanted tissue was functional in 4 studied cases with Graves' disease, only 1 became euthyroid, whereas 3 received main supplemental hormone treatment for postoperative hypothyroidism. Outcomes showed capacity of autotransplanted thyroid tissue to survive, function, and grow in muscle.

Another study was carried out in 2015 by **Mohsen** <sup>(13)</sup>, to determine outcomes in greater number of studied cases, to discover practical technique for implantation, to examine impact of modifying weight of implant and impact of time on its function. For simple multinodular goitres, forty studied cases underwent total thyroidectomy in this research. Finely minced piece of excised gland was mixed with saline like emulsion and injected into thigh muscles. 12 studied cases received five-gm implants, whereas twenty eight received ten-gm implants. At two, six, and twelve months, four parameters were examined: technetium isotope uptake by implant, thyroid stimulating hormone, free T3, and free T4. Autotransplanted thyroid tissue survived and functioned, according to the findings. The isotope uptake of ten gm implants was significantly greater than that of five gm implants. TSH, FT3, and FT4 levels increased markedly over year.

Purpose of this current research was to investigate survival and function of thyroid tissues implanted at sternomastoid muscle after total thyroidectomy in benign goitres. The research included thirty studied cases with benign goitre. Research group's age was  $36.2 \pm 9.7$ , with range of twenty-five to fifty five years. Women to men ratio was three to one. Between included studied cases, eighteen were diagnosed with simple nodular goitre, seven with primary toxic goitre, and five with secondary toxic goitre. Total thyroidectomy was done for all of them with immediate autotransplantation of healthiest looking part of gland weighing about 2-5 gm at sternomastoid muscle. Follow up was done over a period of 12 months for serum levels of T3, T4 and TSH, thyroid scan by <sup>99m</sup>Tc-MIBI scintigraphy and serum calcium level.

We compared preoperative and postoperative thyroid hormone levels and TSH at one, three, six, nine, and twelve months postoperatively in this research. We discovered significant decrease in T3 and T4 serum levels, as well as significant increase in TSH levels, one month after surgery, followed by gradual advancement in thyroid function after three months. Thyroid function began to get back to normal six months after surgery if no hormone substitute was used. This was discovered in twenty studied cases, indicating that implanted thyroid tissue was viable and functioning from third month postoperatively, attaining full functional ability after

six months. After nine months, seven studied cases return to normal thyroid function. Three studied cases were discovered to be hypothyroid after thyroid implantation, indicating that thyroid implant was not functioning properly. Histopathology of post-thyroidectomy specimens proved that two of these three studied cases had Hashimoto thyroiditis, and third had primary toxic goitre. These findings are consistent with previous research on thyroid auto-transplantation and effectiveness of thyroid implants in accomplishing euthyroid status after thyroidectomy without necessity for lifelong hormone replacement treatment (6-8). More research is needed to determine effectiveness of thyroid implant in preserving this euthyroid state.

In this study, TC-99m pertechnetate scintigraphy with SPECT-CT was performed six-nine months after surgery to assess functional ability of thyroid implant. This was first time that SPECT/CT has been used to assess capability of thyroid transplant. SPECT/CT was previously limited to thyroid cancer assessment in identification of residual thyroid malignancy and follow-up for loco-regional recurrence or distant metastasis. In this research, we used this imaging method to evaluate uptake of radioactive isotope TC-99m by implanted thyroid tissue in precise and quantitative manner.

This thyroid scan was performed on fifteen different studied cases. We discovered that thirteen of fifteen studied cases had functioning thyroid implants, which were distributed as follows: Ten studied cases had working thyroid implant in sternomastoid muscle with no residual thyroid tissue at thyroid bed. Three studied cases had working thyroid implant at sternomastoid muscle and some residual thyroid tissue at thyroid bed. Two studied cases had nonfunctional thyroid implant. In these 2 studied cases, histopathological test of thyroid specimens revealed Hashimoto's thyroiditis.

## CONCLUSION

Thyroid autotransplantation after total thyroidectomy is effective technique of preventing postoperative hypothyroidism in benign thyroid disorders.

## Declarations:

**Consent for Publication:** I verify that all authors have agreed to submit manuscript.

**Availability of data and material:** Available

**Funding:** No fund

**Conflicts of Interest:** authors confirm that they have no conflicts of interest with regard to publication of this paper.

## REFERENCES

1. **Cirocchi R (2015):** Total or near-total thyroidectomy versus subtotal thyroidectomy for multi-nodular non-toxic goitre in adults. *Cochrane Database Syst Rev*, 7(8): CD010370. doi:10.1002/14651858.CD010370.pub2
2. **Bron L, O'Brien C (2004):** Total thyroidectomy for clinically benign disease of the thyroid gland. *Br J Surg*, 91(5): 569-74.
3. **Kim D, Sim N, Kim D et al. (2022):** Robot-Assisted Total Thyroidectomy with or without Robot-Assisted Neck Dissection in Pediatric Patients with Differentiated Thyroid Cancer. *Journal of Clinical Medicine*, 11(12): 3320.
4. **Musbah N, Saad H, Mohamed S (2019):** Safety and Effectiveness of Total Thyroidectomy for Benign Multinodular Goitre. *Al-Mukhtar Journal of Sciences*, 34(4): 243-247.
5. **Rabari M, Malaviya P, Patel S (2020):** Study Of Early Postoperative Complications After Thyroidectomy. [www.nhlmmc.edu.in/wp-content/uploads/2022/04/20-SURGERY-Publ...](http://www.nhlmmc.edu.in/wp-content/uploads/2022/04/20-SURGERY-Publ...)
6. **Lira R, De Cicco R, Rangel L et al. (2021):** Transoral endoscopic thyroidectomy vestibular approach: Experience from a multicenter national group with 412 patients. *Head & Neck*, 43(11): 3468-3475.
7. **Arem R, Patsch W (1990):** Lipoprotein and apolipoprotein levels in subclinical hypothyroidism: effect of levothyroxine therapy. *Arch Intern Med.*, 150(10): 2097-100.
8. **Sethi M, Parr M, Bhatia V (2008):** Management strategies for hypothyroidism in non-compliant patients: a case report and review of literature. *S D Med.*, 61(10): 368-9.
9. **Lips D (2004):** Diagnosis and treatment of levothyroxine pseudomalabsorption. *Neth J Med.*, 62(4): 114-8.
10. **Sakr M (2020):** Thyroid Auto-Transplantation. In *Thyroid Disease*, 663-699. Springer, Cham.
11. **Okamoto T (1990):** Trial of thyroid auto-transplantation in patients with Graves' disease whose remnant thyroid has unintentionally been made too small at subtotal thyroidectomy. *Endocrinol Jpn.*, 37(1): 95-101.
12. **Roy P (2003):** Fate of human thyroid tissue auto-transplants. *Surg Today*, 33(8): 571-6.
13. **Mohsen A (2017):** Technique and outcome of auto-transplanting thyroid tissue after total thyroidectomy for simple multi-nodular goiters. *Asian J Surg.*, 40(1): 17-22.