

Totally endoscopic versus conventional septoplasty assisted by endoscope

Mohamed Rabie Ahmed Ghonaim,¹ MSc, Mohamed Ali Ahmed,¹ MD, Mohamed Kamel El –Awady,¹ MD.

*** Corresponding Author:**

Mohamed Rabie Ahmed Ghonaim
mohammadghonaim7@gmail.com

Received for publication May 1, 2022; Accepted October 16, 2022; Published online October 16, 2022.

doi: 10.21608/aimj.2022.136729.1931.

Citation: Mohamed R., Mohamed A. and Mohamed K. Totally endoscopic versus conventional septoplasty assisted by endoscope. AIMJ. 2022; Vol.3-Issue7 .15-19.

¹Otorhinolaryngology Department, Faculty of Medicine, Al-Azhar University, Cairo, Egypt.

ABSTRACT

Background: Traditional septoplasty is being phased out in favor of endoscopic septoplasty. It ensures minimal tissue dissection and fewer surgical problems.

Aim of the study: Evaluation the effectiveness of the endoscopic septoplasty for correction of different types of septal deformity (deviation_ spur) compared to endoscopic assisted conventional septoplasty.

Patients and Methods: This prospective study was conducted on 60 patients of both sex, who attached to the out-patient E.N.T clinic at Bab El Sharaya (Sayed Galal) Hospital from April of 2021 to March of 2022 distributed as 2 same groups: Group A included thirty patients submit to totally endoscopic septoplasty and group B involved thirty patients underwent conventional septoplasty assisted by endoscope . All the patients suffering from nasal obstruction due to a significant septal deviation.

Results: Both groups had no significant differences in age or gender. While there was a substantial difference in the duration of operation and intraoperative blood loss between the two groups. The length ranged from 20 to 50 minutes in group A and 35 to 65 minutes in group B, while the blood loss ranged from 25 to 65 ml in group A and 45 to 90 ml in group B. In this study, the difference between the endoscopic and conventional groups was statistically insignificant in terms of early post-operative complications like nasal synechia, septal hematoma, septal perforation, or CSF leakage, as well as the intraoperative flap and late post-operative complications after 3 months in both groups.

Conclusion: Both techniques are effective in reducing nasal obstruction and related symptoms with fewer overall complications in the endoscopic approach.

Keywords: Anteroposterior; Kirschner Wire..

Disclosure: The author has no financial interest to declare in relation to the content of this article. The Article Processing Charge was paid for by the author.

Authorship: The author has a substantial contribution to the article.

Copyright The Author published by Al-Azhar University, Faculty of Medicine, Cairo, Egypt. Users have the right to read, download, copy, distribute, print, search, or link to the full texts of articles under the following conditions: Creative Commons Attribution-Share Alike 4.0 International Public License (CC BY-SA 4.0).

INTRODUCTION

Nasal septum is considered a major structure for the nasal stability and functions.¹ Septal deviations are the most common cause of nasal obstruction.² Nasal septoplasty is a common surgical intervention, directed to improve nasal breathing Karlsson TR et al.³ and sleep disturbances.⁴ Approaches for correcting nasal septal abnormalities have experienced various changes since their inception, ranging from extreme septal resection to the retention of the septal structure and nasal mucosa. Septal abnormalities are frequently linked to lateral wall disorders or are the cause of them. Epistaxis, sinusitis, obstructive sleep apnea, and migraines have all been linked to a severely deviated nasal septum due to contact with lateral nasal wall components.⁵ As a result, rectification of septal abnormalities is

inextricably linked to the therapy of lateral wall problems. Endoscopic septoplasty can thus be used to

address symptomatic abnormalities as well as to improve intraoperative surgical access to lateral nasal wall procedures (e.g., dacryocystorhinostomy, functional endoscopic sinus surgery).⁶ Endoscopic septoplasty is a minimally invasive treatment for correcting DNS that was created as an alternative to standard submucosal excision. By confining the excision to the area of deviation in the affected area, the exceptional visualization of this method is thought to reduce morbidity and postoperative edema.⁷

the aim of this work is to evaluate the effectiveness of the endoscopic septoplasty for correction of different types of septal deformity(deviation_ spur)

compared to endoscopic assisted conventional septoplasty.

PATIENTS AND METHODS

This prospective study was conducted on 60 patients of both sexes, who attended to the outpatient E.N.T clinic at Bab El Sharaya (Sayed Galal) Hospital from April of 2021 to March of 2022. All the patients suffering from nasal obstruction due to a significant septal deviation. All the study groups signed informed consents before surgery.

Inclusion criteria:

Age of patients range from 20 to 50 years old. Patients having different type of nasal septal deformity (deviation e.g. (c shaped – s shaped) - spur). patients presented with or without turbinate hypertrophy.

Exclusion criteria:

Inflammatory :- chronic or fungal rhinosinusitis
Allergic nasal polyposis – antrochoanal polyp.

Neoplastic:- Inverted papilloma – squamous cell carcinoma.

Certain types of septal deviation e.g. dislocation, impaction.

Patients with associated co-morbidity (diabetes mellitus, hepatitis, renal disorders, hypertension, cardiac diseases, bleeding disorder, anemia (Hb less than 10 gm %), malnutrition).

All patients were subjected to: Careful history taking; Personal history : name ,age, sex ,occupation and residence.

Complaint and history of present illness regarding the nasal obstruction which was the main complaint of all patients with emphasis on onset, course, and duration of the nasal obstruction, the side of the obstruction, postnasal discharge, epistaxis and hyposmia.

Past history of using nasal decongestant drops or any other medical treatment and its effect.

Examination: Meticulous preoperative examination was done by anterior rhinoscopy. Nasal patency examination and diagnostic nasal endoscopy for all patients was conducted to meticulously assess the type and severity of the septal deviation. CT scans of the paranasal sinuses was done only when chronic sinusitis was suspected.

Investigations: Pre-operative routine investigations as complete blood count, bleeding time, coagulation time, prothrombin time, partial prothrombin time, random blood sugar, liver enzyme, serum creatinine, ECG, and chest X-ray were done.

The patients were randomly distributed into two groups: Group A 30 patients underwent totally endoscopic septoplasty and Group B 30 patients underwent conventional septoplasty assisted by endoscope.

Both procedures were carried out under general anaesthetic with a cuffed endotracheal tube in order to avoid blood aspiration or swallowing. At the start of the procedure, a five-minute pack soaked in adrenaline in saline solution (1: 200,000) was introduced into the nostril. The patients were positioned supine on the surgical table, with the head end lifted. both nasal cavities were packed using merocel packs at the end of operation in both techniques.

Technique of totally endoscopic septoplasty using the endoscope, submucosal infiltration of the nasal septum was done. An incision was performed directly on deviated part then a mucoperichondrial flap was dissected at the proper cleavage plane to minimize bleeding, using a Cottle elevator in the right hand and endoscope in the left hand. The septal cartilage was then incised posterior to the mucosal incision. The dissection of the contralateral mucoperichondrial flap was then performed. In cases of spur only, the incision was done directly over the spur using a sickle knife under endoscopic vision especially for posterior spurs.

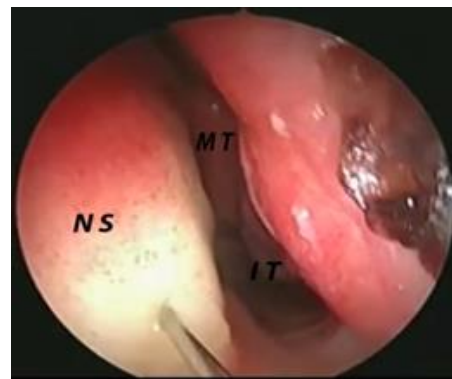


Fig.1: Infiltration of the nasal septum using 1:200,000 adrenaline in saline solution. (NS= Nasal septum. MT= Middle turbinate. IT= Inferior turbinate).

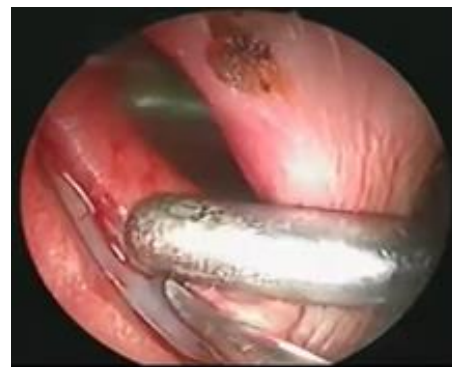

Fig.2: Flap elevation on the left side.

Technique of conventional septoplasty assisted by endoscope:

The conventional approach involves headlight illumination and visualization with nasal speculum. After injection, a Killian incision was made using a No. 15 blade. The incision was performed on the side of the deviation. Then the submucosal flaps were elevated, and the deviated segment was removed. In the end of operation we used 0 degree 4 mm endoscope to observe and remove any remnants of deviated nasal septum.

Postoperative care: Patients were kept under observation in the hospital for 24 for any sign of nasal bleeding. Antibiotics and oral anti-inflammatory were prescribed for all cases. After removal of nasal packs, patients were discharged and were kept on a regimen of alkaline nasal douche for one month. The nasal splint, if used, was removed after one week.

Postoperative evaluation: All patients were evaluated, once weekly for the first month then every 2 weeks for 3 months, then monthly till 6 months, regarding the nasal obstruction whether improved or not, and the degree of the improvement (no, mild, moderate, severe), also, the accompanying symptoms as a headache, snoring, postnasal discharge, epistaxis and hyposmia, whether disappeared or still persistent. Patients were checked out for any complications such as epistaxis, or any new symptoms that were not present preoperatively. They were also examined using nasal endoscope for any residual deformity of nasal septum or spurs, septal perforation, septal hematoma, nasal adhesion. In cases complicated with adhesions they were managed by cutting the adhesions and insertion of a corticosteroid pack for few days. Both groups were

compared objectively using the nasal endoscope regarding the healing process and the incidence of complications.

Statistical analysis

Prior to statistical analysis, the data were checked for normality using the Kolmogorov-Smirnov test. Continuous variables were defined by range, mean, and standard deviation, while categorical variables were described by number and percent (N, percent) (SD). The chi-square test and Fisher exact test were used to compare categorical variables, while the t-test was used to analyze continuous variables. Statistical significance was defined as a two-tailed p 0.05. The IBM SPSS 20.0 program was used to conduct all of the analyses.

RESULTS

There was no statistically significant difference in age and sex of both groups. (P-value was 0.379 & 0.196 respectively). Mean age of group A was 29.77 ± 6.58 years with range among 20 and 44 years and Mean age of Group B was 31.27 ± 6.51 years with range among 20 and 50 years. 30 patients (group A) who underwent endoscopic septoplasty, 17 (56.7%) were males and 13 (43.3%) were female patients. Likewise, among 30 patients (group B) who underwent conventional septoplasty, 12 (40.0%) were males and 18 (60.0%) were female patients.

Types of the septal deformity showed no statistically significant difference between both groups, (P-value 0.651). In group A: 9 (30%) patients had c shaped septal deviation, whereas 12 (40%) patients had an isolated spur deviation, and 9 (30%) patients had s shaped septal deviation. In group B: 12 (40%) patients had c shaped deviated septum, whereas 9 (30%) patients had an isolated spur deviation, and 9 (30%) patients had s shaped deviated septum..

Operative details		Group A	Group B	t- test	P-value
Duration	Range	20-50 minutes	35-65 minutes	5.663	<0.001 *
	Mean±SD	39.80±7.70	52.30±9.32		
Blood loss	Range	25-65 ml	45-90 ml	8.940	<0.001 *
	Mean±SD	41.63±9.07	70.80±15.39		
Nasal packing	yes	30 (100.0%)	30(100.0%)	-	-
Intraoperative flap tear	yes	5 (16.7%)	10 (33.3%)	2.222	0.136
Septal splinting	yes	30 (100.0%)	30 (100.0%)	-	-

Table 1: operative findings of both groups.

Regarding duration of surgery and intra operative blood loss there is statistically significant between both groups (p value > 0.001).

N.B.(Intraoperative blood loss was calculated by subtracting the volume of total irrigation used during the surgery from the total amount of fluid in the suction canister at the end of surgery).

Pre	Group A		Group B		Chi-Square	
	N	%	N	%	X2	P-value
Nasal obstruction	30	100.00	30	100.00	-	-
Headache	12	40.00	9	30.00	0.659	0.417
Post Nasal discharge	20	66.7	15	50.00	2.222	0.136
Epistaxis	4	13.33	5	16.67	0.131	0.718
Smell disorders	6	20.00	6	20.00	0.000	1.000
Ear complain	4	13.33	6	20.00	0.480	0.488

Table 2: Pre-operative Assessment of nasal manifestations in both groups.

There is no statistically significant in pre-operative assessment of nasal manifestations in both groups.

Post	Group A		Group B		Chi-Square	
	N	%	N	%	X2	P-value
Nasal obstruction	2	6.7	4	13.3	0.741	0.389
Headach	0	0.00	1	3.33	1.017	0.313
Post Nasal discharge	15	50.00	10	33.3	0.351	0.554
Epistaxis	0	0.00	0	0.00	-	-
Smell disorder	0	0.00	2	6.7	2.069	0.389
Ear complain	1	3.33	2	6.67	0.351	0.554

Table 3: Post-operative improvement of nasal manifestations after 3 months.

There is no statistically significant between both groups in Post-operative improvement of nasal manifestations after 3 months.

Complications	Group A		Group B		Chi-squar	p-value
	N	%	N	%		
Epistaxis	3	10	7	23.3	1.920	0.166
Synechia	2	6.7	5	16.7	1.456	0.228
Crustations	2	6.7	5	16.7	1.456	0.228
Septal hematoma	0	0	1	3.3	1.017	0.313
perforation	0	0	2	6.7	2.069	0.150
Posterior deviation	2	6.7	4	13.3	0.741	0.389

Table 4: Post-operative complications in both groups.

Regarding post-operative complications in both groups there is not statistically significant between both groups.

DISCUSSION

In this study, there were no significant differences detected among both groups regarding demographic data such as age and sex. Also, both groups showed insignificant differences regarding types of septal deformities. The most common affected group was of the younger age groups. This was in concordance with the study of Rao JJ.⁸

Regarding the duration of conventional and endoscopic septoplasty. Using the endoscope, the incision was made on the spur itself which markedly reduced the extent of subperichondrial dissection. This resulted in an apparent reduction in the duration of the procedure compared to the conventional septoplasty with a statistically significant difference (p 0.001). Supporting this study results, Aiyer et al.⁹ reported that, regarding cases of isolated spur or limited deviation in the nasal septum, the duration of endoscopic septoplasty was relatively shorter than traditional septoplasty. On the other side, Richtsmeier et al.¹⁰ reported that the average time of limited endoscopic septoplasty was 12min. Comparatively, the time required for a traditional septoplasty was nearly threefold (35min). We found an insignificant difference between both groups in the intraoperative flap tear (p 0.136). Similar to these results were the results of Kaushik et al.¹¹ who reported an intraoperative flap tear in 3 cases (10%) in the conventional group and 2 cases (6.67%) in the endoscopic group with an insignificant difference between both groups. On the contrary, Suligavi et al.¹² reported flap tear in 18 out of 50 cases (36%) in the conventional group and 10 out of 50 cases (20%) in the endoscopic group with a significant difference between both groups. To avoid

synechia formation following the intraoperative flap tears, septal splints were used in this study in all cases. Jung et al.¹³ support this study regarding that splint should be a routine step in septal surgery. On the contrary, according to Tang et al.¹⁴ placement of splints is unnecessary and should not be considered as a rule.

The difference of the endoscopic group as compared to the conventional group was statistically insignificant regarding early post-operative findings (p 0.166). Similar results were Obtained by Kaushik et al.¹¹ who reported more epistaxis cases in the conventional group than the endoscopic group with a statistically insignificant variance. On the other hand, Suligavi et al.¹² reported a statistically significant difference between the conventional group [13 cases (26%)] and the endoscopic group [7 cases (14%)]. In this study, the differences were statistically insignificant in nasal synechia, nasal crustations, septal hematoma or septal perforation (p-value 0.228, 0.228, 0.313, & 0.150 respectively). Results of this study agree with Bothra et al.¹⁵ who did not detect statistically significant differences in the reported immediate post-operative complications. Regarding this study, after 3 months postoperative, 2 patients (6.7%) of group A had a persistent posterior deviation, but neither persistent anterior nor spur deviations were present. On the contrary, 4 patients (13.3%) of group B suffered a persistent posterior deviation, but no patients had a persistent anterior deviation or spur deviations. (P-value 0.389 & 0.150 respectively). No nasal synechia, nasal crustations nor septal hematoma was recorded in both groups. While, 2 patients (6.7%) of group B had anterior septal perforation (fig.3), but no patient had a septal perforation in group A. Difference between both

group was statistically insignificant. The results of this study agree with the results of Kaushik et al.¹¹ regarding persistent posterior and spur deviations who reported statistically insignificant differences between both groups. In our study, the postoperative improvement of nasal manifestations after 3 months such as Nasal obstruction, Headache, post nasal discharge, epistaxis, smell disorders and ear complaint shows no statistically differences between both groups. The results of this study agree with the results of Gupta et al.¹⁶ However The chief complaint of the patients in our study was nasal obstruction reported by all patients in both groups. In our study only 2 (6.7%) patients had nasal obstruction in group A and 4 (13.3%) patients in group B. There is no statistically difference between both groups (p value 0.389). In a similar study done by Sathyaki et al.² conducted on 50 patients with nasal obstruction, 46 of the 50 patients were relieved of nasal obstruction of which 22 of the 25 patients belonged to conventional and 24 of the 25 patients belonged to endoscopic septoplasty group. Use of an endoscope during the performance of the conventional septoplasty to assess the result of the procedure and correction of the defect not visualized by the naked eye is advantageous especially in relief of symptoms of nasal obstruction and headache.¹⁷

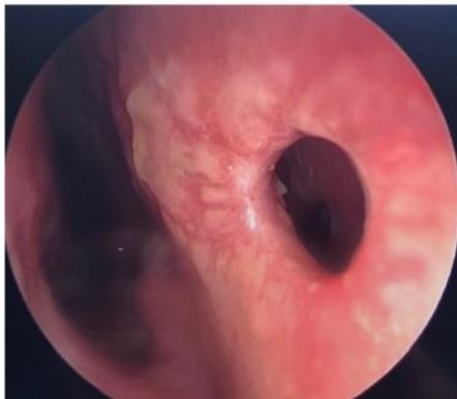

Fig.3: septal perforation.

CONCLUSION

In cases with isolated septal spur or posterior deviations the totally endoscopic septoplasty is preferred because the incision was done directly over the spur and therefore it requires shorter time than conventional methods with less blood loss and better visualization. While in cases with anterior deviation conventional septoplasty assisted by endoscope is preferred because we can use both hands and allow binocular vision.

Conflict of interest : none

REFERENCES

1. Uz U and Eskiizmir G. A comparison of quality of life and outcomes of endoscopic and conventional septoplasty. *KBB-Forum*. 2018; 17(4): 138-43.

2. Sathyaki DC, Geetha C, Munishwara GB, et al. Comparative Study Of Endoscopic Septoplasty Versus Conventional Septoplasty. *Int J Otorhinolaryngol Head Neck Surg*. 2014;66(2):155-61.
3. Karlsson TR, Shakeel M, Supriya M, et al. Septoplasty with concomitant inferior turbinate reduction reduces the need for revision procedure. *Rhinology*. 2015;53(1):59-65.
4. Ertugay CK, Toros SZ and Karaca CT. Is septoplasty effective on habitual snoring in patients with nasal obstruction? *Eur Arch Otorhinolaryngol*. 2015; ;272,7):1687-91.
5. Pannu KK, Chadha and Kaur IP. Evaluation of benefits of nasal septal surgery on nasal symptoms and general health. *Indian J Otolaryngol Head*. 2009;61:59-65.
6. Chang M, Lee H and Park M. Long-term outcomes of endoscopic endonasal conjunctivodacryocystorhinostomy with Jones tube placement: a thirteen-year experience. *J Cranio-maxillofac Surg*. 2015 ;43:7-10.
7. Kulkarni SV, Kulkarni VP and Burse K. Endoscopic septoplasty: a retrospective analysis of 415 cases. *Indian J Otolaryngol Head Neck Surg*. 2015;67(3):248-54.
8. Rao JJ, Kumar ECV, Babu KR, et al. Classification of nasal septal deviation relation to sinonasal pathology. *Indian J Otolaryngol Head Neck Surg*. 2005;57:199-201.
9. Aiyer R.G and Raval J. Endoscopic septoplasty: A novel technique-A case series of 19 cases. *Clinical Rhinology*. 2009; 2 (3): 11-3.
10. Richtsmeier WJ, Cantrell H. and Richtsmeier-ER WJ. Limited septoplasty for endoscopic sinus surgery. *Otolaryng. Head Neck*. 1998; 116 (2): 274-7.
11. Kaushik S, Vashistha S and Jain N. Endoscopic vs conventional septoplasty: A comparative study. *Clin Rhinol Int J*. 2013;6:84-87.
12. Suligavi S, Darde M and Guttigoli B. *Endoscopic Septoplasty: Advantages and Disadvantages*. *Clinical Rhinology. Int J*. 2010;3(1):27-30.
13. Jung YG, Hong JW, Eun Y-G, et al. Objective usefulness of thin silastic septal splints after septal surgery. *American journal of rhinology & allergy*. 2011;25(3):182-5.
14. Tang S and Kacker A. Should intranasal splints be used after nasal septal surgery? *The Laryngoscope*. 2012;122(8):1647-1648.
15. Bothra R and Mathur N. Comparative evaluation of conventional versus endoscopic septoplasty for limited septal deviation and spur. *The Journal of Laryngology & Otology*. 2009;123(7):737-41.
16. Gupta M and Motwani G. Comparative study of endoscopic aided septoplasty and traditional septoplasty in posterior nasal septal deviations. *Indian Journal of Otolaryngology and Head & Neck Surgery*. 2005;57(4):309-11.
17. Hwang PH, McLaughlin RB, Lanza DC. Et al. Endoscopic septoplasty: indications, technique, and results. *Otolaryngology--Head and Neck Surgery*. 1999; 120(5): 678-82.