

CLINICAL AND RADIOGRAPHIC (CBCT) ASSESSMENT OF ATM EXTRACTOR IN CONSERVATIVE EXTRACTION. A PILOT CLINICAL TRIAL

Tadros Ramses Morcos* , Ahmed Mohamed Abd Alsamad ** 
and Ahmed Tarek Elsharkawy *** 

ABSTRACT

Introduction: Traditional dental extraction can cause excessive swelling, pain and many complications. Atraumatic or conservative extraction techniques try to minimize these complications. ATM is considered one of the recently invented conservative extraction techniques, it implies the use of modified periostomes followed by insertion of modified post in the root canal, followed by vertical extraction of the straight remaining root using special nuts and wrench.

Methodology: Five patients requiring extraction of multiple remaining roots were enrolled in this study. Roots required for extraction were divided into 2 groups; in the study group extraction was made by the new technique (ATM), while in the control group, extraction was made using traditional elevators and forceps. Pre and postoperative ultra-low dose cone beam computed tomography (CBCT) examinations were made for each patient to assess bone remodeling and compare the two techniques.

Results: The new technique showed better results regarding time of surgery, postoperative pain, and bone resorption. However; these results were not statistically significant.

Conclusion: The use of ATM as a conservative extraction technique of single straight remaining roots is considered a successful promising technique. However; larger sample size and a multicenter study is required for better assessment and development of the technique.

KEYWORDS: ATM, conservative extraction, vertical extraction, remaining roots

* BDS, Ain Shams University, Matrya Health Center, Ministry of Health

** Associate Professor of Oral and Maxillofacial Radiology, Faculty of Dentistry, Cairo University

*** Associate Professor of Oral and Maxillofacial Surgery, Faculty of Dentistry, Cairo University

INTRODUCTION

In spite of the major advances in dentistry, tooth extraction is still inevitable in many occasions; as advanced caries lesions, periodontal diseases, failed endodontics, trauma, pericoronitis and orthodontics¹. Basic exodontia is defined as simple luxation techniques, bone expansion, and forceps delivery, while complex exodontia implies techniques used to remove teeth other than by simple luxation and forceps delivery².

Traditional extraction can be done using elevators and forceps or even improvised tools such as screw drivers and pliers³. In many occasions dental extractions may need surgical intervention especially for remaining roots and third molars, it may include flap opening and bone removal using rotary tools or piezoelectric instruments⁴. This excessive trauma cause excessive swelling and pain and many complications such as bone fracture, excessive bleeding, wound infection and dry socket⁵ which is destructive for the surrounding hard and soft tissues. However, Atraumatic extraction (as known as conservative extraction) is the removal of root or tooth, and in the same time conserve the surrounding soft and hard tissues⁶.

A lot of interventions for conservative extraction were lately introduced to the market trying to decrease this complications such as periotomes⁷, powertome⁸, piezotome⁹, sonosurgery¹⁰, using endo H file¹¹, physics forceps^{12,13}, Benex I¹⁴, Benex II extraction systems¹⁵, Sapien extraction kit¹⁶, the use of implant drills¹⁷ and the use of electromagnetic device (Osseotouch)¹⁸.

Despite these new techniques, most of them are having their problems, for example the periotome needs more forces to cut the apical periodontal ligament leading to instrument bending or even breakage and yet it does not help to take the root out of the socket⁷. Piezo-surgery is very expensive, time consuming and also can't take the root out of the socket⁹. H files¹¹ are not helpful with fixed roots and it may break. 'Easy X-TRAC' is not recommended

for curved remaining roots, rests on neighboring teeth which is not applied if they are periodontally affected and can't reach last molars¹⁹.

Vertical extraction systems may be helpful for severely destroyed teeth, decreasing the need for flap and bone removal²⁰. In a previous study this group tested "the key", a new extraction technique for curved roots, and it showed that a different technique is needed for extraction of straight roots²¹, so a new technique "ATM" was introduced, and needed testing.

ATM is considered one of the recently invented conservative extraction techniques. This technique starts with the use of modified periotomes followed by insertion of modified post in the root canal, followed by vertical extraction of the straight remaining root using special nuts and wrench.

The aim of this study was to compare clinically and radiographically socket healing (Bone and Gingiva) following extraction using ATM (the new extraction device) and traditional extraction technique (forceps and elevators).

Methodology

Ethical Approval

Approval from Ethical committee, Faculty of Dentistry, Cairo University, Egypt was obtained on 19/2/2019 and its number is (19-2-31).

Participant's recruitment

Five patients with thirteen single rooted teeth were enrolled in this study; they were selected randomly from the outpatient clinic of Oral and Maxillofacial Surgery Department, Faculty of Dentistry, Cairo University. Inclusion criteria included the presence of more than one straight root to be extracted in the same patient and confirmed using a digital periapical radiograph.

Medical and dental histories were taken from the patients. Patients with any systematic condition or disease that affect bone healing after extraction, or even affect soft tissue were excluded from the study.

Surgical Procedures

Teeth to be extracted in the same patient were divided randomly into two groups: In the study group, patients received local anesthesia in regular fashion, then periodontal ligaments around the roots were cut using modified periostomes (Fig. 1a). Root canals were prepared with special drills (Fig. 1b) so that certain modified ready-made post (Fig. 1c) is inserted stably in the canal to extract the root. A putty rubber base cushion was applied on the adjacent teeth followed by seating a metal tray with a hole corresponding the post (Fig. 1d). After the rubber base sets, the nut (Fig. 1e) was applied on the post using special wrench driver (Fig. 1f) till the root comes out (Fig.2).

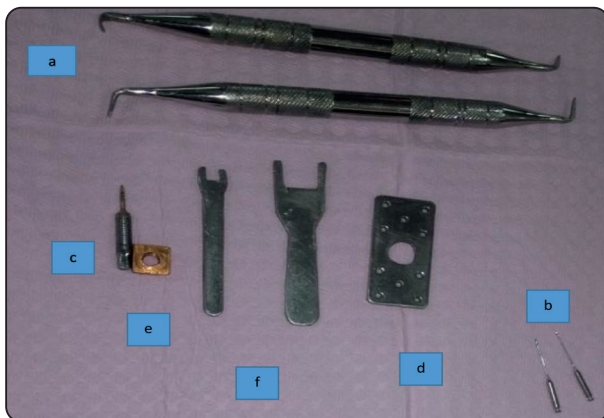

Fig. (1): Photograph showing components of the ATM extractor system: a: Modified periostomes, b: Special Drills, c: Modified ready-made post, d: Metal tray with a hole corresponding the post, e: The Nut, f: Special Wrench driver.

In the control group, local anesthesia was given normally and extraction was made using conventional forceps and elevators. The duration of procedure was calculated from the onset of local anesthesia till the completion of tooth extraction in both groups and was recorded.

Regular post extraction instructions and medications were given to the patients. The patients were instructed to record the number of times s/he needed extra analgesic. Patients follow up was made after 3 days to check the healing of soft tissue, and any postoperative complications.

Pre- and Post- operative Patient Imaging

The patients were referred to the outpatient clinic of Oral and Maxillofacial Radiology Department – Faculty of Dentistry – Cairo University. Each patient was imaged twice using ultra-low dose CBCT (preoperative CBCT scan and another scan CBCT after 2 months).

CBCT examination was performed by Planmeca ProMax® 3D Mid CBCT machine (Planmeca-Helsinki-Finland). The patients were positioned on the CBCT machine guided with the positioning laser beam of the machine so that the mid-sagittal plane and the occlusal plane were perpendicular and horizontal to the floor respectively. The examination was done using the following parameters: 90 kV, 5 mA, 6 seconds scan time, 0.2 mm voxel size and 8x5 cm field of view (FOV).

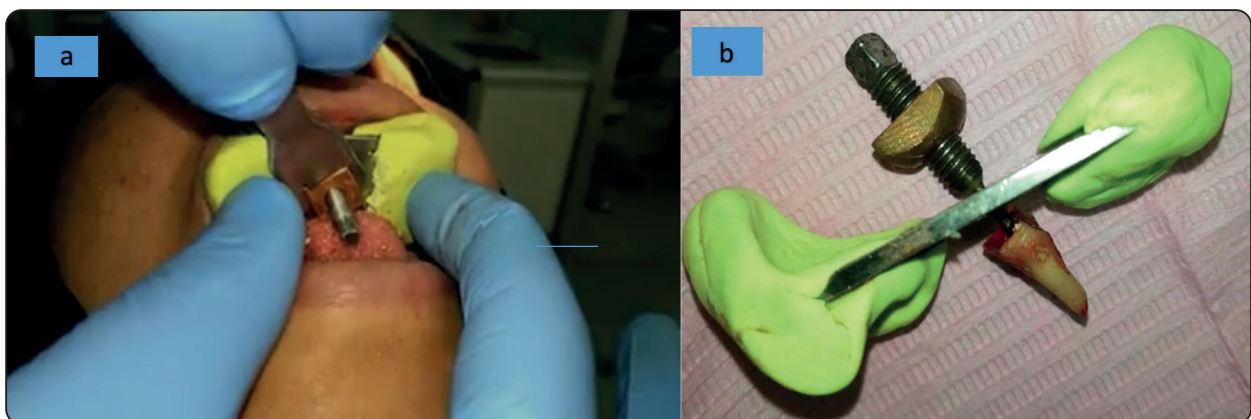


Fig. (2): a: A photograph showing the placement of ATM extractor inside patient mouth. b: The root after extraction with the ATM

Image Analysis:

Image analysis was performed by Planmeca Romexis software 4.6.2 (Planmeca- Helsinki-Finland). Both CBCT scans (Before & After extraction) were superimposed using “superimposition module” of Planmeca Romexis software which allowed semi-automatic superimposition by defining three common points between the 2 volumes. This allowed standardization of assessment of bone changes and confirmed that the measurements were performed on the same cut in both pre- and post-operative CBCT scans (Figure 3).

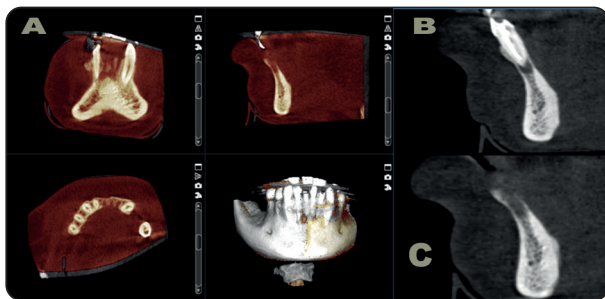


Fig. (3): A: Superimposed pre- and post-operative CBCT scans. Same cut is displayed in both pre- (B) and post-operative (C) CBCT scans.

The slice thickness for the three orthogonal planes (axial, sagittal and coronal) was adjusted to be 1 mm with no gap between cuts. The brightness, contrast and sharpness were adjusted according to observer preference to reach best image quality.

Using the “superimposition module”, the post extraction CBCT was hidden and only the pre-extraction CBCT was displayed. On the displayed pre-extraction CBCT, the level of the axial plane was adjusted to be in middle third of root to be extracted. On the axial image, the axis of the coronal plane was rotated to be aligned perpendicular on the buccal surface of the root to be extracted (coronal axis divides the root equally into mesial and distal halves). On the coronal and sagittal images, the axis of orthogonal planes were oriented along the long axis of the root to be extracted.

On the coronal image in center of root to be extracted, the distance between crest of buccal bone, crest of lingual bone and most apical part of potential socket to a fixed anatomical landmark as inferior border in mandible and floor of the nasal cavity in the maxilla were measured as well as the width of the ridge in buccolingual direction (For anterior teeth, the sagittal image was used). Then the pre-extraction CBCT was hidden and only the post-extraction CBCT was displayed and the same image with the same orientation used for measurement in pre-extraction CBCT was displayed on post-extraction CBCT. These measurements were repeated on the post-extraction CBCT and the difference in the height of bone crest of buccal bone and lingual bone as well as changes in socket depth and ridge width were calculated.

Image assessment was done by an Oral and Maxillofacial Radiologist. The observer was blind to the grouping of the teeth of patients.

Statistical Analysis

Numerical data were explored for normality by checking the distribution of data and using tests of normality (Kolmogorov-Smirnov and Shapiro-Wilk tests). All data showed non-normal (non-parametric) distribution. Data were presented as mean, standard deviation (SD), median and range values. Wilcoxon signed-rank test was used to compare between the two groups as well as to study the changes within each group. Qualitative data were presented as frequencies and percentages. McNemar’s test was used to compare between the two groups. The significance level was set at $P \leq 0.05$. Statistical analysis was performed with IBM SPSS Statistics for Windows, Version 23.0. Armonk, NY: IBM Corp.

RESULTS

Base line characteristics

The present study was conducted on five subjects; three males (60%) and two females (40%). The mean and standard deviation values for age

were 46.6 (13.8) years old with a minimum of 34 and a maximum of 70 years old. Six roots were extracted atraumatically while seven roots had traumatic extraction.

Extraction time (minutes)

There was no statistically significant difference between extraction time in the two groups although mean time needed with atraumatic extraction was less than mean time needed with traumatic extraction (P -value = 0.916, Effect size = 0.043) (Table 1).

TABLE (1): Descriptive statistics and results of Wilcoxon signed-rank test for comparison between extraction time (minutes) in the two groups

Traumatic extraction (n = 7)		Atraumatic extraction (n = 6)		P-value	Effect size (d)
Mean (SD)	Median (Range)	Mean (SD)	Median (Range)		
8.7 (9.6)	3 (2-27)	8.2 (3.5)	7.5 (5-12)	0.916	0.043

*: Significant at $P \leq 0.05$

Pain

There was no statistically significant difference between prevalence of pain in the two groups

(P -value = 1). Only one patient reported post-operative pain in the first three days following extraction in traumatic extraction group and absence of post-operative pain needing extra analgesic in atraumatic extraction group (Table 2).

Ridge width (mm)

In traumatic extraction group; there was a decrease in ridge width post-extraction by 1.27 (± 1.31) mm while in atraumatic extraction group, there was a decrease in ridge width post-extraction by 0.8 (± 0.78) mm. Although atraumatic extraction showed decreased bone loss in ridge width than traumatic extraction, there was no statistically significant difference between changes in ridge width in the two groups (P -value = 0.500, Effect size = 0.275) (Table 3).

TABLE (2): Descriptive statistics and results of McNemar’s test for comparison between prevalence of pain in the two groups

Traumatic extraction (n = 7)		Atraumatic extraction (n = 6)		P-value
n	%	n	%	
1	16.7	0	0	1

*: Significant at $P \leq 0.05$

TABLE (3): Descriptive statistics and results of Wilcoxon signed-rank test for comparison between ridge width (mm) in the two groups as well as the changes within each group

Time	Traumatic extraction (n = 7)		Atraumatic extraction (n = 6)		P-value	Effect size (d)
	Mean (SD)	Median (Range)	Mean (SD)	Median (Range)		
Pre-extraction	7.94 (1.46)	7.7 (6.45-10)	7.5 (2.86)	6.8 (4.6-11.6)	0.917	0.043
Post-extraction	6.66 (1.12)	6.6 (5-8.2)	6.8 (3.06)	6.2 (3.6-11.2)	0.500	0.275
Change	-1.27 (1.31)	-0.8 (-3.6-0)	-0.8 (0.78)	-0.4 (-1.9-0)	0.500	0.275
P-value	0.028*		0.068			
Effect size (d)	0.899		0.696			

*: Significant at $P \leq 0.05$

Change in height of buccal plate of bone (mm):

In traumatic extraction group; there was a decrease in height of buccal bone post-extraction by 1.02 (± 0.87) mm while in atraumatic extraction group, there was a decrease in height of crest of buccal bone post-extraction by 2.95 (± 4.79) mm. While for median (range) of bone changes, traumatic extraction group; there was a decrease in height of buccal bone post-extraction by 1.1 (-2.1-0) mm while in atraumatic extraction group, there was a decrease in height of crest of buccal bone post-extraction by 1.05 (-12.6-0) mm.

There was no statistically significant difference between changes in height of buccal bone in the two groups (P -value = 0.500, Effect size = 0.275) (Table 4).

Change in height of lingual plate of bone (mm)

In traumatic extraction group; there was a decrease in height of lingual bone post-extraction by

2.92 (± 1.67) mm while in atraumatic extraction group, there was a decrease in height of lingual bone post-extraction by 0.92 (± 1.01) mm.

Although atraumatic extraction showed decreased bone loss in height of lingual bone than traumatic extraction, there was no statistically significant difference between changes in height of lingual bone in the two groups (P -value = 0.075, Effect size = 0.727) (Table 5).

Bone formation in depth of extraction socket (mm)

In traumatic extraction group; there was a decrease in depth of extraction socket by 0.46 (± 0.39) mm while in atraumatic extraction group, there was almost no change in depth of extraction socket -0.1 (± 1.01) mm. There was no statistically significant difference between depth of extraction socket in the two groups (P -value = 0.249, Effect size = 0.471) (Table 6).

TABLE (4): Descriptive statistics and results of Wilcoxon signed-rank test for comparison between buccal ridge height (mm) in the two groups as well as the changes within each group

Time	Traumatic extraction (n = 7)		Atraumatic extraction (n = 6)		P -value	Effect size (d)
	Mean (SD)	Median (Range)	Mean (SD)	Median (Range)		
Pre-extraction	21.57 (10.34)	21 (7-34)	24.47 (7.4)	23.25 (14.8-34.5)	0.917	0.043
Post-extraction	20.55 (10.87)	19 (5.6-34)	21.52 (9.76)	22.95 (7.6-33.6)	0.917	0.043
Change	-1.02 (0.87)	-1.1 (-2.1-0)	-2.95 (4.79)	-1.05 (-12.6-0)	0.500	0.275
P -value	0.043*		0.043*			
Effect size (d)	0.765		0.765			

*: Significant at $P \leq 0.05$

TABLE (5) Descriptive statistics and results of Wilcoxon signed-rank test for comparison between lingual ridge height (mm) in the two groups as well as the changes within each group

Time	Traumatic extraction (n = 7)		Atraumatic extraction (n = 6)		P-value	Effect size (d)
	Mean (SD)	Median (Range)	Mean (SD)	Median (Range)		
Pre-extraction	21.46 (11.28)	20.14 (6.4-34.2)	24.78 (7.86)	24.75 (14.2-34.5)	0.753	0.128
Post-extraction	18.54 (10.27)	15.7 (5.2-29.57)	23.87 (7.6)	24.6 (13.2-33.6)	0.249	0.471
Change	-2.92 (1.67)	-2.4 (-4.9- -1.2)	-0.92 (1.01)	-0.8 (-2.8-0)	0.075	0.727
P-value		0.018*		0.043*		
Effect size (d)		0.896		0.765		

*: Significant at $P \leq 0.05$

TABLE (6) Descriptive statistics and results of Wilcoxon signed-rank test for comparison between distance to floor of the socket (mm) in the two groups as well as the changes within each group

Time	Traumatic extraction (n = 7)		Atraumatic extraction (n = 6)		P-value	Effect size (d)
	Mean (SD)	Median (Range)	Mean (SD)	Median (Range)		
Pre-extraction	11.59 (9.35)	9 (0.4-22)	15.27 (9.27)	17 (3.5-24.3)	0.600	0.214
Post-extraction	12.05 (9.57)	9 (0.6-22.7)	15.17 (8.85)	16.5 (3.6-24.3)	0.893	0.055
Change	0.46 (0.39)	0.55 (0-0.95)	-0.1 (1.01)	0 (-2-1)	0.249	0.471
P-value		0.043*		1		
Effect size (d)		0.765		0		

*: Significant at $P \leq 0.05$

DISCUSSION

Conservative extraction techniques are continuously developed through history in order to find a simple, fast, painless, universal and economic technique, however; the flawless technique that met all these criteria is not invented yet. ATM is considered one of the conservative extraction techniques, it was originally invented by Dr. Tadros Morcos, and later tested and developed by Dr. Ahmed Elsharkawy and Dr. Mohamed Elanwar; hence the name (ATM) which is short for (Ahmed- Tadros -Mohamed).

Considering the time needed for extraction, our study showed no statistically significant difference between extraction time in the two groups although mean time needed with atraumatic extraction was less than mean time needed with traumatic extraction. This results went with the results of the regular time of extraction using traditional forceps and even physics forceps tested by Hariharan et al 2014¹². On the contrary, Sharma et al 2014⁷ showed that the duration of extraction in conventional extraction forceps group was significantly greater than atraumatic extraction group. This may be due to their higher sample size than our study and different atraumatic

technique as the use of periosteal elevator before ATM is mandatory and time consuming.

While for postoperative pain, there was no statistically significant difference between pain intensity in the two groups although only one patient reported post-operative pain needing extra dose of analgesic in traumatic extraction group and absence of post-operative pain in atraumatic extraction group. This result is in line with the results of Hariharan et al 2014¹² which reported absence of any post-operative pain in traumatic and atraumatic extraction after 3 days of follow up in atraumatic (physics forceps) and traumatic groups. Again Sharma et al 2014⁷ showed that pain reduction in atraumatic extraction group was significantly greater than conventional extraction forceps. This may be due to the fact that none of our patients required open flap surgery and bone removal or timely procedure, which are the main reasons for postoperative pain regardless of the technique.

Low dose protocol of CBCT examination allows reduction in dose delivered to the patient with acceptable image quality fulfilling the diagnostic purpose of examination²². The amount of radiation (Dose Area Product- DAP) delivered to the patient using ultra-low dose CBCT was less than half the amount of radiation Dose Area Product- DAP (DAP) of the same CBCT machine of the same field of view FOV with conventional exposure parameters. DAP of ultra-low dose protocol of CBCT used in our study was comparable to DAP of conventional radiography mentioned in the study of Harris et al 2012²². Dose Area Product is used as a measure of patient dose as it is relatively easy to be measured in a clinical situation^{23,24}. For that, Ultra-low dose CBCT protocol was used in our study to decrease the amount of radiation delivered to the patient to the minimum with the benefit of 3D assessment.

For accurate radiographic assessment, standardization is essential in order to get identical CBCT images for reliable measurements²⁵. For that in our study, superimposition between pre- and post-oper-

ative CBCT was done to achieve identical cuts and highest accuracy in measuring difference as Meloni et al 2015²⁶. Method of measuring the changes in ridge width and level of buccal and lingual bone was similar to the method used by Jung et al 2013²⁷ except for using fixed anatomical landmark as inferior border in mandible and floor of the nasal cavity in the maxilla in our study instead of horizontal reference line at the most apical point of the extraction socket to avoid any changes in the level of reference line under the effect of healing and bone formation.

Considering bone changes assessment using ultra-low dose CBCT, there was no statistically significant difference between changes in the two groups. Although atraumatic extraction showed decreased bone loss in ridge width and height of lingual plate of bone than traumatic extraction, perhaps due to the fact that it's a vertical extraction technique which requires no load on the bone plates, and hence no bone resorption later on. These results are in line with the results of Menchini-Fabris et al 2022¹⁸, as they found no significant differences in height of bone buccally and lingually in atraumatic and traumatic extraction groups although they used 3-dimensional intra-oral scanner instead of CBCT and followed up the patients for 4 months. Considering changes in height of buccal plate of bone, there was a controversy between results of mean of change in bone height and median of the change, this is related to presence of one case of severe bone loss in atraumatic group (Loss of 12.6mm).

Points of strength of this study included the 1st time assessment of the new tool (ATM) which is improvised tool that may represent a cost effective tool for vertical conservative extraction. Also the clinical selection of patients included only those having multiple extractions to make a split mouth study, so each patient was his own control; eliminating the host immunity and healing power factor from the equation. The radiographic assessment added to the strength by making the results more objective and reliable.

Points of weakness in the study included the limited number of patients; since it was a pilot study, lack of objective assessment of gingival healing, and the fact that the inventor of the device was the surgeon, so next study is recommended to be a multicenter one with large number of patients.

CONCLUSION

The use of ATM as a conservative extraction technique of single straight remaining roots is considered a successful promising technique. However; larger sample size and a multicenter study is required for better assessment and development of the technique.

REFERENCES

1. Chestnutt IG, Binnie VI, Taylor MM. Reasons for tooth extraction in Scotland. *J Dent.* 2000;28(4):295-297. doi:10.1016/S0300-5712(99)00069-X
2. Dym H, Weiss A. Exodontia: Tips and Techniques for Better Outcomes. *Dent Clin North Am.* 2012;56(1):245-266. doi:10.1016/j.cden.2011.07.002
3. Iserson K V. Dental extractions using improvised equipment. *Wilderness Environ Med.* 2013;24(4):384-389. doi:10.1016/j.wem.2013.07.001
4. Tsai SJ, Chen YL, Chang HH, Shyu YC, Lin CP. Effect of piezoelectric instruments on healing propensity of alveolar sockets following mandibular third molar extraction. *J Dent Sci.* 2012;7(3):296-300. doi:10.1016/j.jds.2012.07.001
5. Jaafar N, Nor GM. The prevalence of post-extraction complications in an outpatient dental clinic in Kuala Lumpur Malaysia--a retrospective survey. *Singapore Dent J.* 2000;23(1):24-28. <http://www.ncbi.nlm.nih.gov/pubmed/11602946>.
6. Jain S, Oswal RH, Purohit B, et al. Advances in Methods of Atraumatic Tooth Removal: An Update. Kumar A, ed. *Int J Prev Clin Dent Res.* 2017;4(4):295-299. doi:10.5005/jp-journals-10052-0129
7. Sharma SD, Vidya B, Alexander M, Deshmukh S. Periosteal as an Aid to Atraumatic Extraction: A Comparative Double Blind Randomized Controlled Trial. *J Maxillofac Oral Surg.* 2015;14(3):611-615. doi:10.1007/s12663-014-0723-8
8. White J, Holtzclaw D, Toscano N. Powertome® Assisted Atraumatic Tooth Extraction. *J Implant Adv Clin Dent.* 2009;1(6):35-44.
9. Blus C, Szmukler-Moncler S. Atraumatic tooth extraction and immediate implant placement with Piezosurgery: evaluation of 40 sites after at least 1 year of loading. *Int J Periodontics Restorative Dent.* 2010;30(4):355-363. <http://www.ncbi.nlm.nih.gov/pubmed/20664837>.
10. Papadimitriou DEV, Geminiani A, Zahavi T, Ercoli C. Sonosurgery for atraumatic tooth extraction: A clinical report. *J Prosthet Dent.* 2012;108(6):339-343. doi:10.1016/S0022-3913(12)00169-2
11. Sadesh Kannan V, Sathya Narayanan GR, Saneem Ahamed A, Velavan K, Elavarasi E, Danavel C. A new atraumatic method of removing fractured palatal root using endodontic H-files luted with resin modified glass ionomer cement: A pilot study. *J Pharm Bioallied Sci.* 2014;6(SUPPL. 1). doi:10.4103/0975-7406.137431
12. Hariharan S, Narayanan V, Soh CL. Split-mouth comparison of Physics forceps and extraction forceps in orthodontic extraction of upper premolars. *Br J Oral Maxillofac Surg.* 2014;52(10):e137-e140. doi:10.1016/j.bjoms.2014.06.013
13. Kapila S, Kaur T, Bhullar RS, Sandhu A, Dhawan A, Kaur A. Use of Physics Forceps in Atraumatic Orthodontic Extractions of Bilateral Premolars: A Randomized Control Clinical Study. *J Maxillofac Oral Surg.* 2020;19(3):347-354. doi:10.1007/s12663-020-01347-6
14. Muska E, Walter C, Knight A, et al. Atraumatic vertical tooth extraction: a proof of principle clinical study of a novel system. *Oral Surg Oral Med Oral Pathol Oral Radiol.* 2013;116(5):e303-e310. doi:10.1016/j.oooo.2011.11.037
15. Makki AZ, Nassar AA, Alharbi WM, et al. Evaluation of post-extraction healing after atraumatic axial tooth extraction using Benex system II versus conventional extraction: Randomized control trial. *Saudi Dent J.* 2021;33(8):923-928. doi:10.1016/j.sdentj.2021.09.002
16. Jain A, Sridevi U. An innovative approach for atraumatic tooth extraction for immediate implant placement by using Sopian extraction kit: A case report. *Dent Oral Craniofacial Res.* 2016;2(2):234-237. doi:10.15761/DOCR.1000153
17. Yalcin S, Aktas I, Emes Y, Kaya G, Aybar B, Atalay B. A technique for atraumatic extraction of teeth before immediate implant placement using implant drills. *Implant Dent.* 2009;18(6):464-472. doi:10.1097/ID.0b013e3181bcc6d9

18. Menchini-Fabris GB, Toti P, Crespi R, Crespi G, Cosola S, Covani U. A Retrospective Digital Analysis of Contour Changing after Tooth Extraction with or without Using Less Traumatic Surgical Procedures. *J Clin Med.* 2022;11(4):922. doi:10.3390/jcm11040922
19. Babbush CA. A new atraumatic system for tooth removal and immediate implant restoration. *Implant Dent.* 2007;16(2):139-145. doi:10.1097/ID.0b013e3180581656
20. Hong B, Bulsara Y, Gorecki P, Dietrich T. Minimally invasive vertical versus conventional tooth extraction: An interrupted time series study. *J Am Dent Assoc.* 2018;149(8):688-695. doi:10.1016/j.adaj.2018.03.022
21. Kaiser T, Elsharkawy A. The Key: A Pilot Study of A Novel Technique For Conservative Extraction of Remaining Roots. *Egypt Dent J.* 2017;63(1):383-388. doi:10.21608/edj.2017.74755
22. Harris D, Horner K, Gröndahl K, et al. E.A.O. guidelines for the use of diagnostic imaging in implant dentistry 2011. A consensus workshop organized by the European Association for Osseointegration at the Medical University of Warsaw. *Clin Oral Implants Res.* 2012;23(11):1243-1253. doi:10.1111/j.1600-0501.2012.02441.x
23. Hidalgo Rivas JA, Horner K, Thiruvengkatchari B, Davies J, Theodorakou C. Development of a low-dose protocol for cone beam CT examinations of the anterior maxilla in children. *Br J Radiol.* 2015;88(1054):20150559. doi:10.1259/bjr.20150559
24. Okano T, Sur J. Radiation dose and protection in dentistry. *Jpn Dent Sci Rev.* 2010;46(2):112-121. doi:10.1016/j.jdsr.2009.11.004
25. Xia Y, Xie L, Zhou Y, Song T, Zhang F, Gu N. A new method to standardize CBCT for quantitative evaluation of alveolar ridge preservation in the mandible: a case report and review of the literature. *Regen Biomater.* 2015;2(4):251-260. doi:10.1093/rb/rbv017
26. Meloni SM, Tallarico M, Lolli FM, Deledda A, Pisano M, Jovanovic SA. Postextraction socket preservation using epithelial connective tissue graft vs porcine collagen matrix. 1-year results of a randomised controlled trial. *Eur J Oral Implantol.* 2015; 8(1): 39-48. <http://www.ncbi.nlm.nih.gov/pubmed/25738178>.
27. Jung RE, Philipp A, Annen BM, et al. Radiographic evaluation of different techniques for ridge preservation after tooth extraction: A randomized controlled clinical trial. *J Clin Periodontol.* 2013;40(1):90-98. doi:10.1111/jcpe.12027