

CLINICAL AND RADIOGRAPHIC ASSESSMENT OF THE EFFECTIVENESS OF DECOMPRESSION AS TREATMENT OF PEDIATRIC MANDIBULAR RADICULAR CYST

Waleed F. Esmael*^{ID}, Lobna Aly**^{ID} and Ahmed K. Abozekry*^{ID}

ABSTRACT

Background: Radicular cysts are the most common inflammatory odontogenic cyst which can be treated with decompression especially in children with large cyst and has vital structures and or vital tooth.

Purpose: to evaluate clinical and radiographic effectiveness of decompression as a conservative treatment in decreasing the size of a pediatric radicular cysts and reveal the effect of different variables such as impacted tooth angulation, cusp tip depth and cyst size on related impacted tooth eruption.

Methodology: A healthy 10 children with average age of 9years old with unilateral radicular mandibular cysts. decompression was done incorporating a multipurpose space maintainer. Clinical and radiographic follow up was done.

Results: Ten patients were treated by decompression and the volume reduction rate was 79.1%. The monthly reduction rate was better in lesions greater than 275 mm² with -28.00 ± 20.05 and -17.52 ± 7.05 in lesions lower than 275mm² with statistical significant difference ($p < 0.05$).

Conclusion: Decompression is effective for the treatment of radicular cystic lesions in pediatrics as it enables eruption of the impacted teeth within the cyst and decrease morbidity and protects neighboring vital structures.

KEYWORDS: pediatric cyst, decompression, conservative treatment.

* Lecturer of Oral & Maxillofacial Surgery, Faculty of Oral & Dental Medicine. Future University in Egypt.

** Professor of Oral and Maxillofacial Surgery, Faculty of Oral and Dental Medicine, Future University in Egypt

INTRODUCTION

Odontogenic cysts are a group of common pathological lesions of the jaw. Typically, they're discovered by X-rays as round radiolucent lesions. The radicular cyst is the most common odontogenic cystic lesions originating from epithelial remnants from periodontal ligament. Cyst starts as a consequence of pulp necrosis which extends to the apex of the affected tooth^[1,2].

Certain things should be taken in consideration during treatment of cyst in growing patients, such as permanent tooth buds, patient cooperation, jaw growth and the healing process. There are common techniques for treating the odontogenic cyst, i.e. enucleation, marsupialization or a combination of these techniques.⁽³⁾ Enucleation of a large cyst can result in complications like hemorrhage, pain, swelling, ecchymosis, formation of an oro nasal communication, or damage of adjacent nerve.⁽⁴⁾ Conservative approach as marsupialization can be preferred instead of excessive bone removal in cases of the large radicular cysts.^[5]

Furthermore, clinical and radiographic assessment of the effectiveness of decompression as a conservative treatment in decreasing the size of a pediatric radicular mandibular cysts and the correlation between cyst decompression and several variables such as impacted tooth angulation, cusp tip depth and cyst size on related impacted tooth eruption.

Methodology

Ten children (seven girls and three boys) whose age ranged 8-11 years with no systemic disease, with a mean of 9 years, reported to the Department of Oral and Maxillofacial Surgery, Future university in Egypt with the chief complaint of asymptomatic swelling and difficulty in mastication on the premolar molar area of mandibular region. Lesions suspected of cysts were detected in routine panoramic radiographs.

In clinical examination, mandibular lesions showed buccal expansion but no sign of infection was found in any patient. The preoperative radiographic examination showed, a well-defined unilocular radiolucent area with the crown of an unerupted permanent teeth and diffuse corticated border, fourteen impacted permanent teeth were detected in 10 cystic cavities.

Inclusion criteria were as all pediatric patients with mandibular cystic lesion. The exclusion criteria were any pathological lesion rather than inflammatory cyst as well as any existing systemic disease which could impair the healing potential.

Cone-beam computerized tomography (CBCT) small window imaging (to reduce radiation exposure to children) was performed during the initial diagnosis for the evaluation of lesion borders and anatomic structures (tooth roots, inferior alveolar nerve, etc.) [Fig. 1], and during the follow-up period to assess the volume and diameter of cystic lesions.

Decompression of the cystic cavity with preservation of all the involved permanent teeth was planned as regard age of the patient and size of the cyst. Written consent was signed by all patients included in this study. Participation was done according to the guidelines outlined in the Declaration of Helsinki for human experimentation. The study was approved by the research ethics committee board- Future university in Egypt.

Surgical Procedure

Site preparation was done intraorally by using 0.12% chlorhexidine gluconate oral rinse Hexitol (ADCO, Cairo, Egypt) 5 minutes preoperatively. The procedure was done under local anesthesia using standard inferior alveolar nerve block and buccal infiltration with 4% Articaine hydrochloride with 1:100,000 epinephrine. All patients were treated by extraction of the mandibular primary molars and decompression of the cystic cavity. One centimeter rounded incision was done and the full thickness flap was reflected. Drilling was performed

using straight surgical handpiece and a fissure bur (Carbide Bur 2.35mm HP 559, Wave Dental, China) to gain access to the lesion. Excision of the cystic lining through the created bony window is done and taken as an incisional biopsy with the removed bone cortex. The cyst was deflated by evacuation of the cystic fluid and then the cavity was irrigated with normal saline which was free of any mass. marsupialization is done by suturing the cystic lining to the oral mucosa with 4-0 polyglycolic acid (PGA, Assut, Switzerland). Cavity was packed using sterile Gauze soaked in Fusidic (Fucidin cream 2 %, Minapharm pharmaceutical & chemical industries, Egypt under license of LEO Pharmaceutical Products, Ballerup, Denmark). A plastic tube was inserted in the cystic cavity on the top of the alveolar crest and sutured to the mucosa for creating a window with a drain to irrigate the cystic cavity. Biopsy specimens were taken from all patients and sent for histopathologic examination.

Follow-up

Prescription containing antibiotics such as (amoxicillin, 20-40 mg/kg per day in 3 doses) were used for five days to prevent and contain postoperative infection. parents were instructed to irrigate the cystic cavity using normal saline using a 10 ml syringe with needle to prevent food accumulation after meals.

During the subsequent two weeks, the patients were requested to return in every three days to change the gauze pack to a smaller one. After two weeks an acrylic space maintainer was fabricated with a posterior stainless steel clasp on the first mandibular molar and anterior one. This was frequently checked every week and the splint was adjusted to make room for the 1st premolar tooth and the remaining part contained space for the second premolar. It had been remained within the mouth until the premolar eruption, which became visible through subsequent radiological evaluation

Postoperative follow-up consisted of clinical and radiographic examinations 1 month, 3 and 9 months after decompression as follows (fig. 2,3):

- (A) Cusp depth; the distance of the central cusp tip of the cyst-associated tooth from the line that passes the cementenamel junction of the adjacent teeth;
- (B) Angulation of the impacted tooth to axis of adjacent teeth;
- (C) Measurement of cyst size: The width (mm), depth (mm), and height (mm) were measured for every position adjustment with 3D shape analysis software (PlanmecaRomexis®, Planmeca OY, Helsinki, Finland) For every patient, the change in diameter before and after marsupialization was measured. The three different investigators independently collected the info and analyzed it with the average values. The authors evaluated the effect of decompression of the lesions in terms of volume change as well as MD and BL widths. The 3D data were went to measure the volume (mm³) with **PlanmecaRomexis®** and to determine the change in volume before and after decompression, similar to the observation on diameter.
- (D) Reduction rate of cyst size: The reduction rate of the cyst size was calculated as follows: initial area minus the final area expressed in square millimeters (mm²) divided by the time expressed in months observation
- (E) Inferior alveolar or mental nerve affection: After the extra oral and intra oral examination, the superficial sensations were evaluated supported Zuniga and Essick ^[6] protocol. The patient's eyes were closed and therefor the sharp and blunt part of a pin was touched to the skin on both sides of the face in symmetrical areas after which the patient was asked whether he felt it. In this manner, the outline was drawn of the area that represented the altered sensation as subjectively by the patient . After mapping the subsequent tests were carried out in the same order. After this procedure, it had been determined that there was a loss of touch and sensory sensation in the lower lip and mental region of the patient.

Statistical analysis

Data were represented as mean and standard deviation. Repeated measures analysis of variance (ANOVA) test was used to compare numeric variables within the studied group of patients. Post Hoc test was done if ANOVA or Friedman tests were positive. Using SPSS version in all tests, result was considered statistically significant if the p-value was less than 0.05.

TABLE (1): Variables affecting teeth eruption after cyst decompression

Comparison	Spontaneous eruption	Lack of spontaneous eruption
Number of teeth/number of observations (n)	12/14	2/14
Eruption period (days)	90±93.1	70±150.5
Mean age (years)	9.5±1.9	11±1.2
Sex (n)	6F, 2M	1F, 1M
Cusp depth (mm)	4.5±4.3	9.3±6.31
Angulation (°)	21.6±19.9	62.8±46.3

TABLE (2). Descriptive data of the sample, as well as values of monthly reduction rate of the cyst.

Average age (years)	9-11	
Gender and monthly reduction rate (mm ² /months)	Male n=3 (30%) -19.55 ± 17.04	Female n= 7 (70%) -24.06 ± 14.88
Initial cystic size and monthly reduction rate (mm ² /months)	> 275 mm ² n=2(20%) -17.52 ± 7.05*	≤ 275 mm ² n=8 (80%) -28.00 ± 20.05*
Initial size (mm ²)	335.40 ± 209.14	
Final size (mm ²)	224.84 ± 116.65	
Time in months	7.86 ± 1.44	
Monthly reduction rate (mm ² /months)	-20.05 ± 14.96	

* = p < 0.05 between these pairs of values.

RESULTS

Ten patients with histologically proven radicular cyst of the mandible were treated by decompression from 2020 to 2022. Of the ten patients, seven were female (70.0%) and three were male (30.0%). The mean age was 9 years. The lesions were located within the posterior premolar to molar region .

After cystic cavity contraction and fully tooth eruption the shortened drain were completely removed during the 2 months follow-up visits of the patients, two cases needed orthodontic alignment after eruption of impacted teeth. (Fig. 4). At 9 months follow up , the cystic lesions had disappeared completely and the premolars were able to erupt (Fig. 5). Along the follow up period, there haven't any recurrence of the cysts in all patients.

The average of maximum diameter of cyst was 46.3± 38.8 mm before decompression. The average maximum diameter was of 21.5 ±38.2 mm after decompression. The average decreasing rate was 59 ± 21% and the average period of the decompression was 9.8 months. The average of volume of cyst in CBCT was 1.95cm³ before decompression and 0.408cm³ after decompression. The volume reduction rate was 79.1%. The monthly reduction rate was better in lesions greater than 275 mm² with -28.00 ± 20.05 and -17.52 ± 7.05 in lesions less than 275mm² with statistical significant difference (p<0.05). (Fig. 6)

The tomography showed that the cortical layer was preserved in the buccal and lingual walls and there was no resorption in the buccolingual direction. Three patients stated that the numbness gradually decreased and it almost completely disappeared at the end of 3 months. The involved inferior alveolar nerve were no longer involved, and adjacent new bone formation was observed between the anatomical structure and the cyst.

Histopathology report of our cases showed a predominant presence of acute inflammatory cells, stratified squamous epithelium with underlying connective tissue and confirmed the diagnostic of radicular cysts.

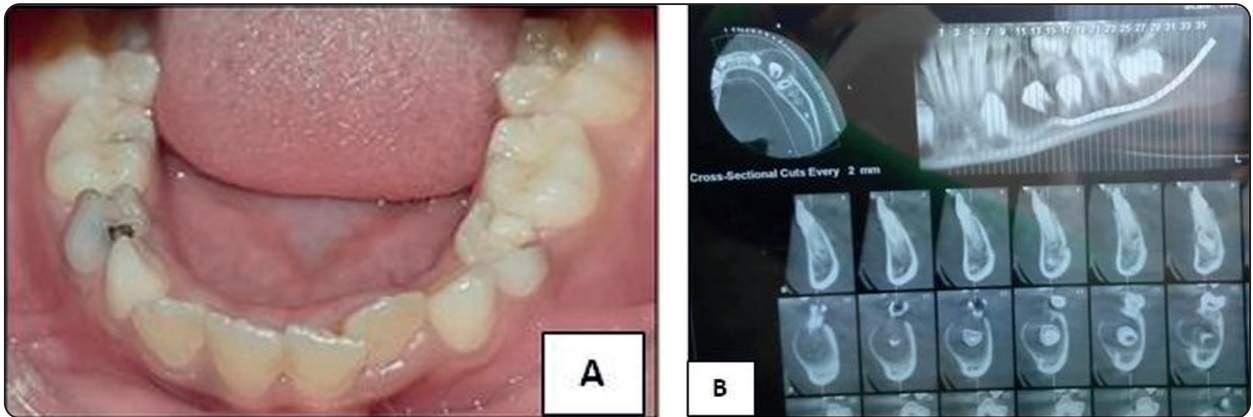


Fig. (1) Figure 1. a. clinical presentation of a case of asymptomatic swelling on the mandibular premolar molar area b. CBCT showing a radiolucent lesion at the mandibular right side (first premolar region).

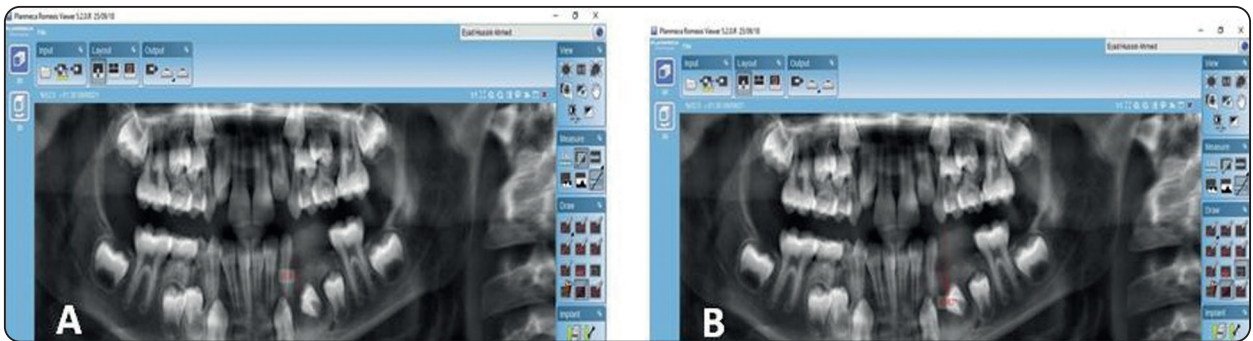


Fig. (2): a. Cusp depth b. Angulation of the impacted tooth to axis of adjacent teeth.

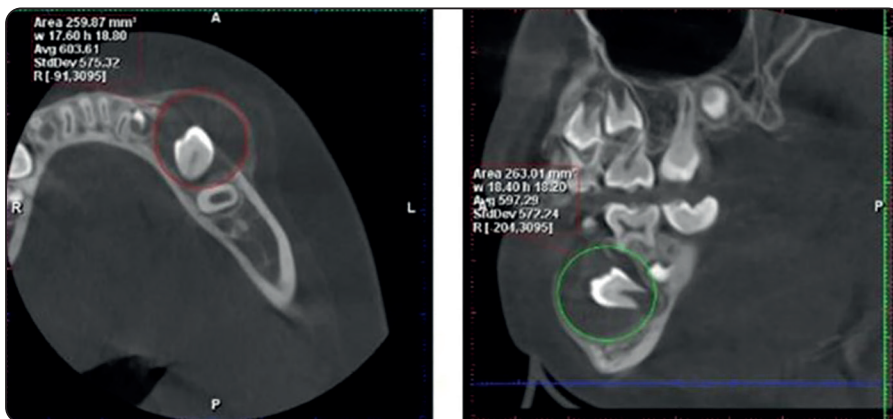


Fig. (3) preoperative measurements of cyst size (mm²)

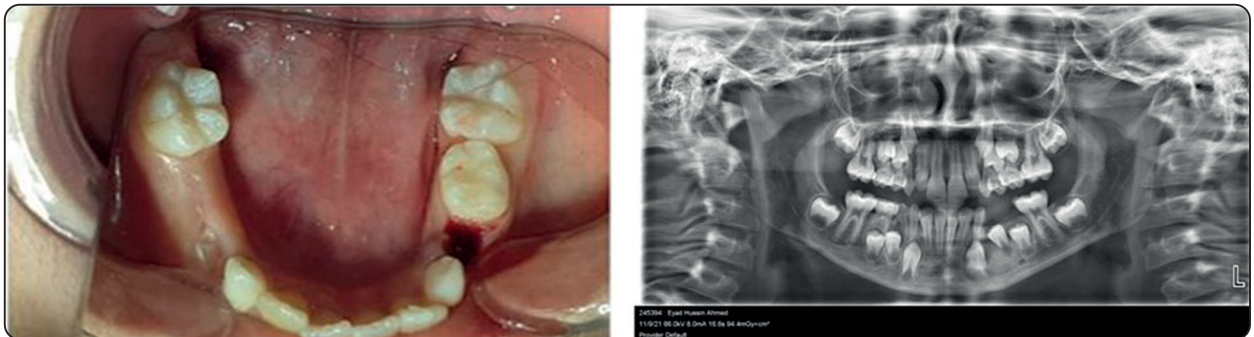


Fig. (4) Radiographic decrease of lesion diameter and eruption of the involved premolars within first 2 months follow-up visits of the patients

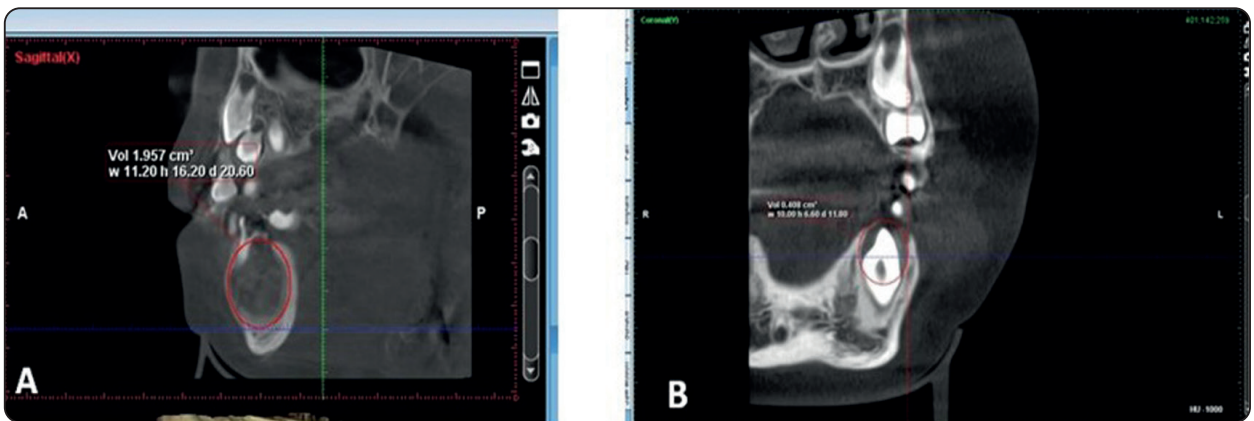


Fig. (5) Cbct measurements of cyst volume (cm³) A.before decompression. B. After decompression

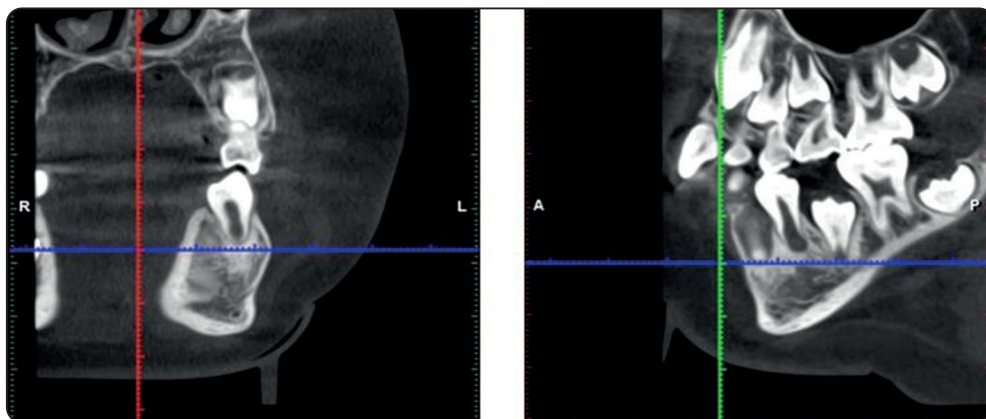


Fig. (6) 9 month Cbct follow up

DISCUSSION

Cystic decompression is a conservative surgical technique and have been widely performed for the treatment of jaw cysts.^[7] Advantages of decompression are: it reduces the cyst size; decrease the risk of anatomical structures damage such as inferior alveolar nerve and maxillary sinus; minimizes bone tissue damage; stimulates osteogenesis; and promotes the eruption of the involved teeth.^[8,9] On the contrary, the disadvantages are: patient discomfort which is prominent at the early stages of decompression; it requires cooperation of patients for long treatment period, longer follow-up period is required to control involved tooth eruption and pathological tissue remains in situ.^[10,11]

Decompression mainly forms an opening and a communication between the cyst and the oral cavity, leading to drainage of the cystic fluid, so the cyst cavity gradually decreases in size by new bone regeneration⁽¹²⁾. However, the placement of the plug is preferred after decompression to avoid wound deformity and food accumulation⁽¹³⁾.

Complete resolution of the cystic lesions were achieved in all of ten cases, twelve of fourteen impacted teeth within the cystic lesions erupted spontaneously, two of them erupted orthodontically. In the present study, the spontaneous erupted teeth had lower angulation degrees than the teeth needed orthodontic treatment, as these results was in agreement with Fuji et al. who found that as angulation and cusp depth increase, the success rate decreases.^[10] However, the depth of the tooth in the alveolar bone did not affect eruption.

Hyomoto et al.^[14] reported that 81% of mandibular premolars erupted 3 months after decompression without the need of orthodontic traction, Also Yahara et al.^[15] presented the successful eruption without orthodontic traction after decompression. As regard our follow up findings, the radiographic decrease of the lesion diameter and the eruption of the involved premolars was predicted in the first 2

months postoperative in all patients except for 2 teeth that erupt orthodontically which can be concluded that cystic decompression stimulate faster eruption by inducing osteogenesis and pressure reduction in the alveolar bone^[16,17]

If early deciduous teeth are lost, the entire mesiodistal width of the deciduous teeth must be maintained in order to avoid inadequate arch length.^[18] Therefore, acrylic space maintainers were fabricated for all of the study cases to temporarily occupy this space to avoid wasting space and permitted tooth eruption and enabled cystic cavity shrinkage.^[19,20]

CONCLUSION

Early diagnosis of odontogenic cysts followed by rapid treatment in children is of a huge importance, as it reduces damage in such cases where the successor tooth is included within the lesion. such as those cases included in the study. According to size of the lesion, patient's age, proximity to vital structures and the importance of the included permanent tooth, cyst decompression as conservative treatment is a favorable treatment modality for preservation and eruption of the affected teeth.

Financial support and sponsorship

Nil.

Conflicts of interests:

There are no conflicts of interests

REFERENCES

1. Slootweg P. Lesions of the jaws. *Histopathol.* 2009; 54:401-18.
2. Delbem ACB, Cunha RF, Vieira AEM, Pugliesi DMC. Conservative treatment of a radicular cyst in a 5-year-old child: a case report. *International Journal of Paediatric Dentistry.* 2003;13(6):447-450.
3. Domingos R. Surgical approaches of extensive Periapical cyst. Considerations about Surgical technique. 2004; 23: 317-28.

4. George V, Thomas G, Kuttappa M, Govind G. Management of a large periapical cyst (apical matrix & surgical complications) - A case report. *Endodontol.* 2009; 10:84-9.
5. Torres-Lagares D, Segura-Egea JJ, Rodriguez-Caballero A, Llamas-Carreras JM, Gutierrez-Perez JL, Treatment of a large maxillary cyst with marsupialization, decompression, surgical endodontic therapy and enucleation. *J Can Dent Assoc* 2011;77:b87
6. Zuniga JR, Essick GK. A contemporary approach to the clinical evaluation of trigeminal nerve injuries. *Oral Maxillofac Clin North Am.* 1992;4(2):353-367.
7. Torres-Lagares D, Segura-Egea JJ, Rodriguez-Caballero A, Llamas-Carreras JM, Gutierrez-Perez JL, Treatment of a large maxillary cyst with marsupialization, decompression, surgical endodontic therapy and enucleation. *J Can Dent Assoc* 2011;77:b87.
8. L, Su K, Seong M, Ji O, Jae Y, and Jae K. The effect of decompression as treatment of the cysts in the jaws: retrospective analysis. *J Korean Assoc Oral Maxillofac Surg.* 2017; 43: 83-7.
9. YJ, Liang HeWJ, Zheng PB, Liao GQ: Inferior alveolar nerve function recovers after decompression of large mandibular cystic lesions. *Oral Dis* .2015; 21:674-8.
10. Fujii R, Kawakami M, Hyomoto M, Ishida J, Kirita T. Panoramic findings for predicting eruption of mandibular premolars associated with dentigerous cyst after marsupialization. *J Oral Maxillofac Surg* 2008;66:272-6.
11. Zhao YF, Wei JX, Wang SP. Treatment of odontogenic keratocysts: A follow-up of 255 Chinese patients. *Oral Surg Oral Med Oral Pathol Oral Radiol Endod* 2002;94:151-6
12. Gao L, Wang X, Li S, Liu C, Chen C, et al. Decompression as a treatment for odontogenic cystic lesions of the jaw. *J Oral Maxillofac Surg.* 2014 Feb;72(2):327-33.
13. Yakir Anavi I, Gavriel Gal, Hagai Miron, Shlomo Calderon, Dror M Allon. Decompression of odontogenic cystic lesions: clinical long-term study of 73. *Oral Surg Oral Med Oral Pathol Oral Radiol Endod.* 2011;112:164-9.
14. Hyomoto M, Kawakami M, Inoue M, Kirita T. Clinical conditions for eruption of maxillary canines and mandibular premolars associated with dentigerous cysts. *Am J orthod dentofac orthop.* 2003;124(5):515-20
15. Yahara Y1, Kubota Y, Yamashiro T, Shirasuna K. Eruption prediction of mandibular premolars associated with dentigerous cysts. *Oral Surgery, Oral Medicine, Oral Pathology, Oral Radiology, and Endodontics*, 2009, 108(1):28-31
16. Qian WT, Ma ZG, Xie QY, Cai XY, Zhang Y, Yang C. Marsupialization facilitates eruption of dentigerous cyst-associated mandibular premolars in preadolescent patients. *J Oral Maxillofac Surg.* 2013;71:1825-1832.
17. Gama TM, Dos Santos Brito E, Da Silva LV, et al. conservative treatment of extensive mandibular midline cystic lesion- case report. *Oral Surgery, Oral Medicine, Oral Pathology and Oral radiology*, 2020;129,109
18. Bijoor E, Kohli K. Contemporary space maintenance for the pediatric patient. *N Y state Dent J.* 2005;71:32-37.
19. Dibiasi AT, Leggat TG. Primary failure of eruption in the permanent dentition of siblings. *Int J Paediatr Dent* 2000; 10: 153-157. 8.
20. Y L, W M, Y N, et al. Application of 3D Printed Cyst Plug in Mandibular Cystic Lesions. *Journal of Oral Science Research* 2019;v.35:52-5.