

Reconstructive Option Selection for Lower Third Leg Defects

Ahmed Mohamed Soliman, Wael Mohamed Ayad, Ahmed Taha Sayed, Yasser Helmy Ismail

Plastic and Reconstructive Surgery Department, Al Azhar University

Abstract

Background: patients with the lower 3rd leg defects are increasing in number especially among victims of road accidents. Due to anatomical features of this area nearly most cases required flap coverage. **Aim of the work:** the aim of this study was to help in selection of the appropriate option for coverage among available local perforator flaps and free microvascular flaps. **Patients and methods:** 30 patients with lower 3rd leg defect were included in this study and they were categorized into 2 groups. 15 patients underwent reconstruction by using local flaps (A) and 15 patients underwent reconstruction using free micro-vascular flaps (B). **Results:** free flaps were more versatile than local flaps, but consumed more operative time and had higher morbidity. **Conclusion:** small and moderately-sized lower 3rd leg soft tissue defects can be covered easily and safely by using locally available perforator flaps. Local flaps do not scarify any of the main arteries, consume less operative time, there was a specific like to like soft tissue replacement leading to a better cosmetic and reconstructive outcome. Free flaps have proven its versatility and reliability in coverage of significantly large and complex defects.

Keywords: lower third leg, lower limb

Introduction

Lower limb traumas are common among victims of road accidents. The relatively unprotected antero medial portion of the tibia is at risk of bone exposure following trauma. Because of complexity of the defect, soft tissue coverage remains a challenge to plastic surgeons ⁽¹⁾. The goal of lower extremity reconstruction is the coverage of defects with good aesthetic and functional outcome and salvages the limb ⁽²⁾ leg defect may result from trauma, tumor resection and chronic diseases such as peripheral vascular disease or post contracture release ⁽³⁾. The reconstructive ladder offers a list of options in terms in surgical closure of the wound. However, the simplest option is not always the best option. A failed technique in lower limb reconstruction can have a devastating effect on the patient resulting in further tissue and bone loss, deterioration of comorbidities and functional deficit with an end point involving amputation. For this reason, the best reconstructive option is often not the easiest choice and should consider all options including free flap reconstruction ⁽⁴⁾. The local flap has the disadvantage of limited mobility. The cross-leg flap has disadvantages, too, not only in that it causes discomfort to patients because it restricts the movement of the legs, but also in that it requires a secondary operation to isolate the pedicle⁽⁵⁾. Perforator flaps, gained a high popularity due to their main advantages: decreasing donor-site morbidity and improving aesthetic outcome. The use as local perforator flaps in lower leg was possible due to a better understanding of the cutaneous circulation, leg

vascular anatomy, angiosome and perforasome concepts, as well as innovations in flaps design⁽⁶⁾. The propeller flap, a pedicle based perforator flap, is well documented as an option for the majority of coverage in the lower limb, particularly below the knee, with the peroneal and posterior tibial artery perforators being commonly used⁽⁷⁾. The reverse sural fasciocutaneous flap is also a viable option for the soft tissue coverage of distal third leg. It was, firstly described by **Masquelet et al.** as skin island flap supplied by arteries accompanying the superficial sensory nerve of leg. Hence, described as neurocutaneous Island flap ⁽⁸⁾. The advancement of microscopy, micro-instruments and sutures had allowed the development of free flap surgery. Microsurgery has allowed the direct transfer of large tissue units from distant donor sites, allowing wounds to be covered and reconstructed based on flap suitability rather than wound proximity ⁽⁹⁾. Microsurgical free flaps have featured early on reconstructive algorithms. As it offers versatile and sufficient coverage without the limitations of the pedicle, and elevation and anastomosis can occur well beyond the zone of injury, but unfortunately qualified micro surgeons not available in all centers and not all patient can withstands long operative time of the surgery ⁽⁹⁾.

Aim of the Work

The aim of this study was to help in selection of the appropriate option for coverage among available local perforator flaps and free microvascular flaps.

Patient and Methods

Reconstructive Option Selection for Lower Third Leg Defects

This work has been conducted at the plastic surgery department, Al Hussein and Sayed Galal hospitals faculty of medicine, Azhar University the period from march 2016 till march 2018. **The study was approved by the Ethics Board of Al-Azhar University.**

Thirty patients were included in this study of males and females (23male and 7 female). All patients were suffering from soft tissue defect of the lower third of the leg and were in need for flaps for reconstruction. The patients were categorized into two groups. **Group 1:** fifteen patients treated with local flaps anterior tibial perforator flap, posterior tibial perforator flap or revesed sural flap. **Group 2:** fifteen patients treated with free flaps free latissimus dorsi flap, free anterolateral thigh flap or free rectus femoris.

Inclusion criteria: all patients fulfilled the following criteria:

- Site lower 3rd leg defect, both sex male and female, age 15-60 y old.
- Nature of defect post traumatic, unstable scar and post contracture release defect.

-Exclusion criteria: patient with any of the following criteria was excluded from the study:

- Age below 15 and above 60 y old.
- Associated general co morbidities; hypertension, diabetes mellitus, chronic liver disease and ischemic heart disease.
- Associated local comorbidity; peripheral vascular disease, chronic lymphodema and deep venous thrombosis
- Other pathological defects; venous ulcers, ischemic ulcer, neuropathic ulcer and malignant ulcer

Preoperatively all patients underwent:

- **History:** personal history, history of present illness, past history.
- **Examination:** general examination of the patient, local examination of the defect and leg
- **Investigation:** routine preoperative investigation plus duplex ultrasonography study of lower limb, x-ray of leg, CT angiography if needed and intra-operative portable Doppler examination.

• **Photography.**

• **Consent:** written informed consents were obtained preoperative

Post Evaluation of techniques: Each group was evaluated for:

1. Flap versatility.
2. Flap complication.
3. Reoperation postoperative.
4. Donor and recipient site morbidity either functional or aesthetic morbidity.
5. Operative time and anesthesia complication.
6. Average duration of wound healing.
7. Average length of hospital stay.
8. Patient satisfaction

Results

Flap complication is defined as necessity for additional, unplanned operative procedure. It is divided into **major** and **minor** complication.

- Major complication (Failure) included total "complete re-exposure of the defect" or partial flap necrosis.
- Minor complication occurred when additional skin grafts were required to regraft lost ones or when it was necessary to evacuate a hematoma. In these cases defect remained covered.

Table 1: demographic characteristics of the studied patients

Variables	Local flap group (n=15)	Free flap group (n=15)	Test of Sig.	P
Age (years):				
Mean ± SD	35.6 ± 13.5	33.6 ± 12.1	t	0.6
Range				
Sex:			χ^2	
Males	14 (93.3%)	10 (66.7%)	Fisher	0.1
Females	1 (6.7%)	5 (33.3%)		
Etiology:			χ^2	
Trauma	13 (86.7%)	11 (73.3%)	Fisher	0.7
Scar	2 (13.3%)	3 (20.0%)	Fisher	0.9
Contracture	0 (0.0%)	1 (6.7%)	Fisher	0.9
Defect size:			χ^2 for trend	
Small up to 50cm	10 (66.7%)	0 (0.0%)	17.7	<0.001
Medium 50-100cm	4 (26.6%)	4 (26.6%)		HS
Large >100cm	1 (6.7%)	11 (73.3%)		
Reconstruction time (for trauma cases):			χ^2	
Late	12 (92.3%)	11 (100%)	Fisher	0.9
Early	1 (7.7%)	0 (0.0%)		

This table showed that there was a high statistical significant difference between the studied groups in defect size as 66.7% of local flap group had small defect size while, 73.3% of free flap group had large defect size.

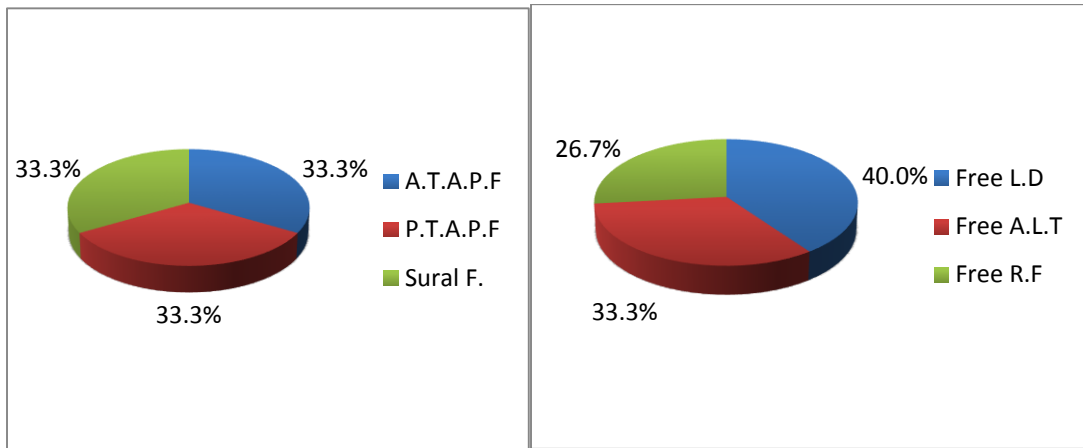


Fig. 1: types of flaps in local flap group. Fig. 2: types of flaps in free flap group

Table 2: flap complications in the studied patients

Flap complications	Local flap group (n=15)	Free flap group (n=15)	χ^2	P
No complications	9 (60.0%)	11 (73.3%)	0.6	0.4
Complications:	6 (40.0%)	4 (26.7%)		
Partial loss	1 (16.7%)	1 (25.0%)		
Total loss	0 (0.0%)	2 (50.0%)		
Graft loss	1 (16.7%)	0 (0.0%)		
Wound dehiscence	2 (33.3%)	0 (0.0%)		
Donor hematoma	0 (0.0%)	1 (25.0%)		
Congestion	1 (16.7%)	0 (0.0%)		
Infection	1 (16.7%)	0 (0.0%)		

This table showed that there was no statistical significant difference between study groups in flap complications. The most frequent complications in local flap group and free flap group were wound dehiscence and total loss respectively.

Table 3: reoperation post-operative in the studied patients

Reoperation postoperative	Local flap group (n=15)	Free flap group (n=15)	χ^2 for trend	P
No	13 (86.7%)	12 (80.0%)	0.9	0.3
Once	2 (13.3%)	1 (6.7%)		
Twice	0 (0.0%)	2 (13.3%)		

This table showed that there was no statistical significant difference between study groups in reoperation postoperative.

Table 4: operative time in the studied patients

Operative time (min.)	Local flap group (n=15)	Free flap group (n=15)	t	P
Mean \pm SD	148.7 \pm 31.4	303.7 \pm 21.3	15.8	< 0.001 HS
Range	110.0 – 200.0	270.0 – 330.0		

Reconstructive Option Selection for Lower Third Leg Defects

This table showed that there was a high statistical significant difference between study groups in operative time. Operative time was longer in free flap group. Mean operative time in local flap group and free flap group were 148.7 & 303.7 minutes respectively.

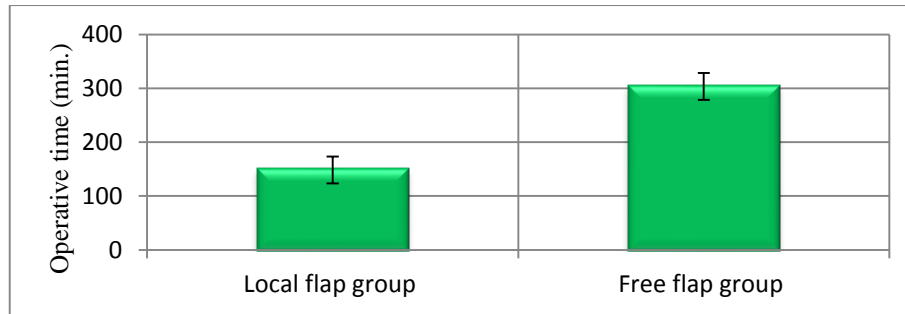


Figure 3: operative time in the studied patients

Table 5: duration of wound healing in the studied patients

Duration of wound healing (days)	Local flap group (n=15)	Free flap group (n=15)	T	P
Mean ± SD	23.6 ± 7.6	24.5 ± 9.8	0.3	0.7
Range	12.0 – 35.0	18.0 – 45.0		

This table showed that there was no statistical significant difference between study groups in duration of wound healing.

Table 6: length of stay in the studied patients

Length of stay (days)	Local flap group (n=15)	Free flap group (n=15)	MW	P
Median	8.0	14.0	53.0	0.01
IQ-Range	7.0 – 15.0	12.0 – 15.0		S

This table showed that there was a statistical significant difference between study groups in Length of stay. Length of stay was longer in free flap group. Median length of stay in local flap group and free flap group were 8.0 & 14.0 days respectively.

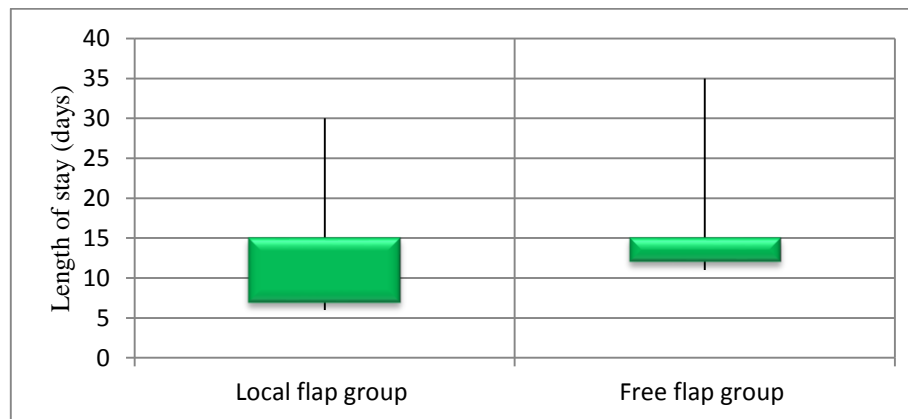


Figure 4: length of stay in the studied patients

Table 7: patient satisfaction in the studied groups

Patient satisfaction	Local flap group (n=15)	Free flap group (n=15)	χ^2 for trend	P
Accepted	1 (6.7%)	2 (13.3%)	0.6	0.4
Average	6 (40.0%)	7 (46.7%)		
Good	8 (53.3%)	6 (40.0%)		

This table showed that there was no statistical significant difference between study groups in Patient satisfaction.

Table 8: donor and recipient site morbidity in the studied groups

Morbidity	Local flap group (n=15)	Free flap group (n=15)	χ^2	P
Functional:				
* Positive	0 (0.0%)	10 (66.6%)	Fisher	< 0.001 HS
* Negative	15 (100%)	0 (33.4%)		
Aesthetic:				
* Positive	15 (100%)	15 (100%)	NA	NA
* Negative	0 (0.0%)	0 (0.0%)		

This table showed that there were statistical significant differences between the studied groups in donor and recipient site functional morbidity. Local flap group had less morbidities than free flap group, but regarding aesthetic outcomes they were the same

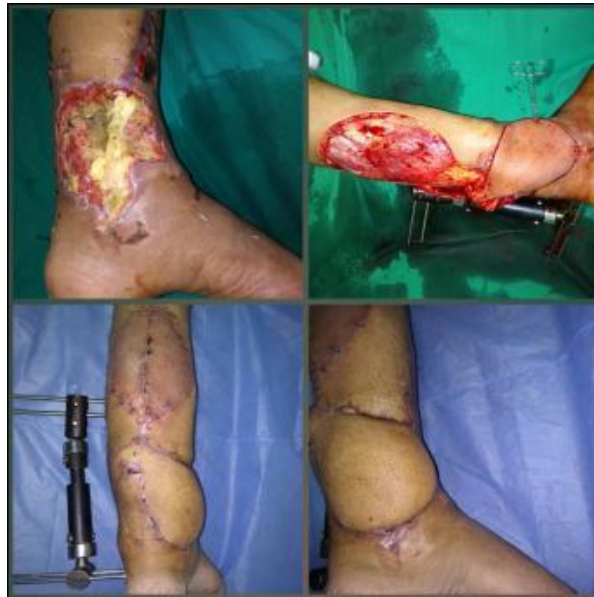

Fig. 5: showing pre op. defect, intra op. reversed sural flap elevation and flap inseting and 1 month post op.

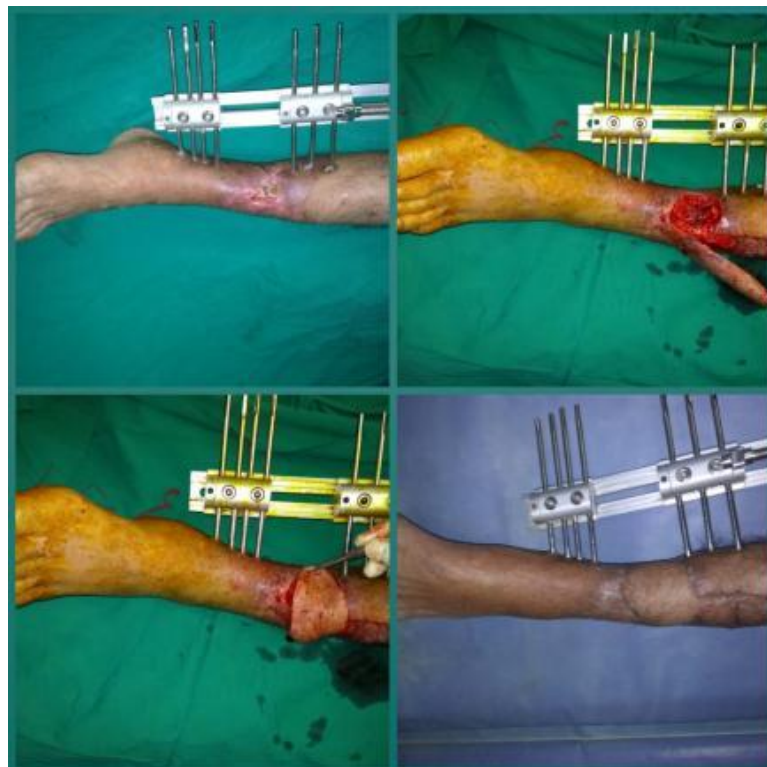

Fig. 6: pre op. defect, intra op. ant. Tibial flap elevation then flap inseting and 2 month post op.

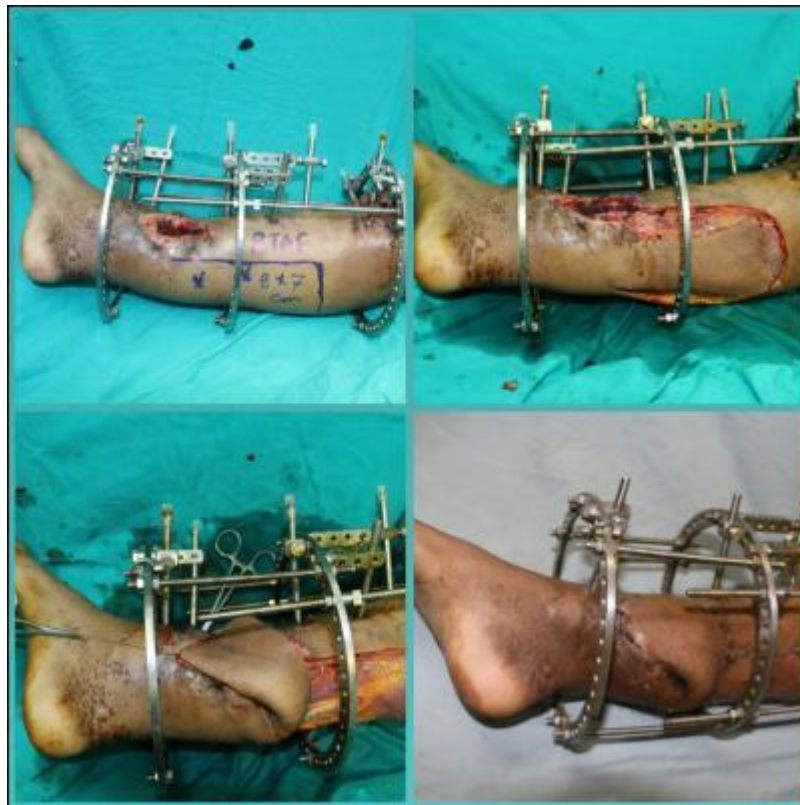


Fig. 7: pre op. defect and flap marking, intra op. post. Tibial flap elevation then flap inseting, and 1 month post op.

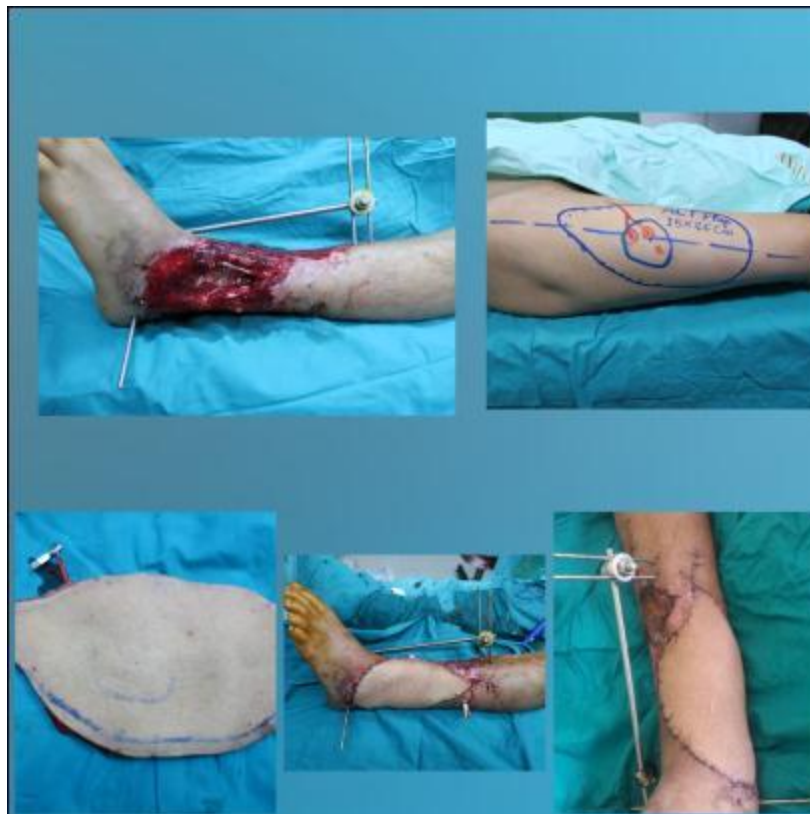

Fig. 8: pre op. defect and flap marking, intra op. flap elevation and flap inseting, and 1 month post op.

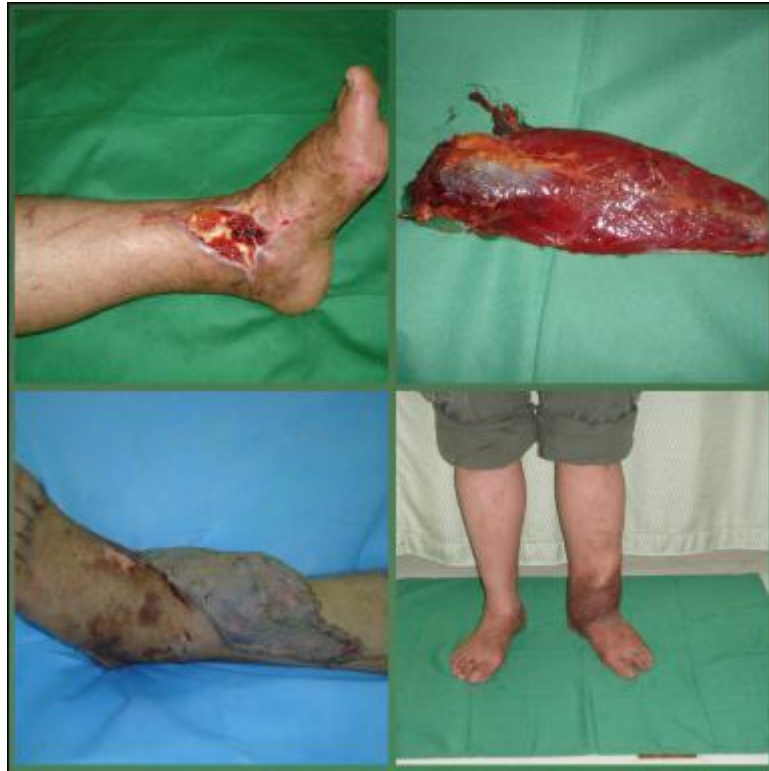

Fig. 9: pre op. defect intra op. free rectus femoris m. flap harvesting then flap inseting, 1st dressing 6 days post op. and 9 months post op.

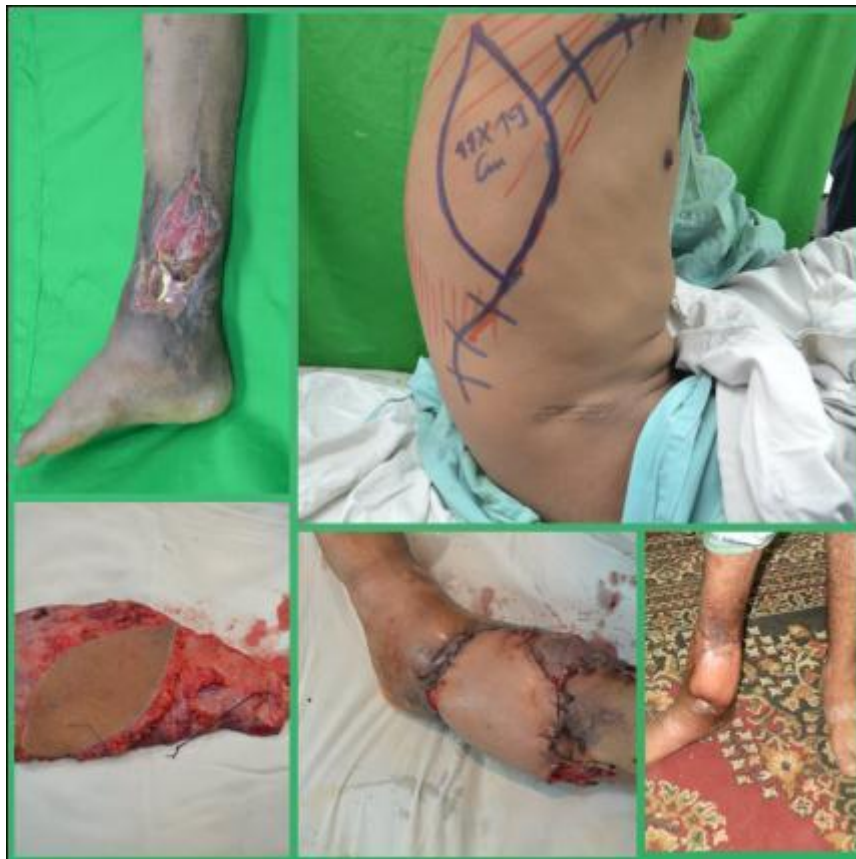

Fig. 10: pre op. defect and flap marking, then intra op. flap harvesting and, flap inseting then 2 months post op.

Discussion

Lower third leg defect coverage is a challenging problem because the tibia and fibula are vulnerable to injury, open fractures being more common due to the paucity of soft tissues around them. Moreover, as most muscles become tendons at this level, flap cover becomes mandatory in the event of trauma. Early ambulation with good aesthetic and functional outcomes with minimal morbidity as possible should be the aim of reconstruction of the lower extremity. This study included 30 patients, 15 patients "14 male and 1 female" were treated with local flaps and 15 patients "10 male and 5 female" were treated by free flaps. Trauma was the most common cause of distal leg defects. It was responsible for 86.7% of defects in patient treated with local flaps and 73.3% of defects in patients treated with free flaps. The same finding was reported by **Kumar et al.**⁽⁹⁾. They found that trauma "especially road traffic accident" was responsible for 94% of lower leg defects. Also, **Khouri and Shaw**⁽¹⁰⁾ reported that trauma cause 91% of lower leg defects. **Santanelli**⁽¹¹⁾ reported that road traffic accidents continue to be the major cause of soft tissue defect in a developing country like ours. While, **Kang et al.**⁽¹²⁾ in their retrospective study "52 cases" reported that trauma was the cause of lower limb defect in about 40% of cases. In this study, we found that free flaps were more versatile than local flap as it covered large defects ">100cm²" in 73.3% of cases while, local flap covered only 6.7%. **Kang et al.**⁽¹²⁾ reported the same. Regarding timing of reconstruction it was already proved in literature that early coverage had better outcomes as mentioned by **Godina**⁽¹³⁾ and **Byrd et al.**⁽¹⁴⁾ as it shortened the hospital stay significantly, few dressing changes, fewer operations, decreased infection rate and secondary necrosis of exposed tissues. Thus, early consultation for soft tissue reconstruction is advised, and all attempts should be done to perform immediate reconstruction. **Kumar et al.**⁽⁹⁾ treated 91% of cases in their series "64 from 73" in acute and subacute phases "within 6 weeks". But in this study 90% and 100% of post traumatic cases reconstructed by local and free flaps respectively were late this reflect availability rather than personal preference. The treatments of these cases were initiated in other hospitals or other departments of the same hospital then they were referred to the plastic surgery department later on.

We emphasized the importance of cooperation at the time of primary surgery between orthopedic and plastic surgeon to save time and preserve access to

potential flaps. The technique of bony fixation of the tibia may prevent the use of this flap, especially in the presence of external fixation pins, which may injure perforating vessels or tether the flap, restricting its range of transposition.

According to our study, major complication occurred in 20% and 6% of cases reconstructed with free and local flaps respectively. Total flap loss occurred in 2 cases of free flap and partial loss occurred in 2 cases 1 free and 1 local. In cases with total loss another flap was done. Fortunately in cases of partial flap loss there was no exposed bone after debridement so split thickness graft solved the problem.

Khurram et al.⁽¹⁵⁾ reported in their study that 10% and 4.5% major complication of cases reconstructed with free and local flaps respectively.

In this study, minor complication occurred in 6% and 33% of cases reconstructed with free and local flaps respectively. Thus over all complication was more in local flap but were less severe. Donor site hematoma occurred in case with free L.D evacuation was done. Wound dehiscence occurred in a case of PTAPF. And case of reversed sural flap conservative management and healing by 2ry intention occurred. Venous congestion occurred in case of reversed sural flap. Infection occurred in case of reversed sural flap and medical treatment was done with appropriate antibiotic after culture and sensitivity from wound discharge. Graft loss occurred in case of P.T.A.P.F. regrafting was done. **Bhatti et al.**⁽¹⁶⁾ in their series "50 cases" found that local flaps had lower complication rate 18% compared to free flaps 27%. **Bekara et al.**⁽¹⁷⁾ reported 14% major complication and 10% minor complication in local flaps. In the present study, 2 cases of local flap entered the theatre again to manage complication by skin grafting while 3 cases of free flaps needed reoperation. Also, the operative time range from 110-200 minute (mean 148) for local flaps and from 270-330 minute (mean 303) for free flaps. Also, **Bhatti et al.**⁽¹⁶⁾ reported nearby results 45-270 minute (mean 75) for local flaps and 105-480 minute (mean 270) for free flaps. In this study, the duration of wound healing ranged from 12-35 days (mean 23) in cases treated by local flaps, and from 18-45 days (mean 24) in cases treated with free flaps; the "median" of hospital stay in local flaps 8 days and in free flap was 14 days. **Kumar et al.**⁽⁹⁾ reported the same finding as most patients were discharged before 10th and 20th days in patients who underwent local and free flaps respectively. Also, **Mahesh et al.**⁽¹⁸⁾ founded that

average duration of hospital stay was least in local flaps (60% of patients were discharged within 10 days) and most in free flaps (2-3 weeks). **Bhatti *et al.*** ⁽¹⁶⁾ reported that 60% of cases with local flaps were discharged within 2 weeks and 75% of cases with free flaps were discharged after 2 weeks. We found that patients satisfaction in local flaps was good in 53% and average in 40% which was comparable to that in free flap good in 40% and average in 46%. **Kumar *et al.*** ⁽⁹⁾ reported higher results as satisfaction was good in 70% and average in 22% in local flaps, while it was good in 66% and average in 33% in free flaps.

Regarding aesthetic morbidity in our study it was found that free and local flaps are the same. Local flaps add scarring and donor site grafting also free flap are bulky. Regarding functional morbidity local flaps and free fasciocutaneous flaps have no functional morbidity but free muscle flaps have. **Daigeler *et al.*** ⁽¹⁹⁾ reported that donor-site morbidity of the rectus femoris muscle flap was evident but well compensated. But, **Gardetto *et al.*** ⁽²⁰⁾ concluded that there was no significant limitation in the strength of the donor leg after removal of the rectus femoris muscle and consequently no significant functional donor-site morbidity. They believed that for the realisation of such results that the intraoperative linking of the vastus lateralis muscle with the vastus medialis muscle, especially in their lower third and an extensive postoperative rehabilitation and training program are essential. **Smith *et al.*** ⁽²¹⁾ reported some shoulder strength weakness over time, and shoulder extension, adduction and internal rotation involvement after L.D. muscle transfer.

Conclusion

- This study proved that small to moderate-size soft tissue defects lower 3rd leg can be covered by local perforator flaps. Local flaps did not scarify any of the main arteries. There was a specific like to like soft tissue replacement leading to a better cosmetic and reconstructive outcome. The average operative time taken for perforator flaps was less than that for free flaps, thereby minimizing the cost and effort of surgery however, these flaps had a limited role in larger defects and the perforator can be within the zone of injury, which can threaten the viability of the flap. Free flaps proved its versatility and reliability in coverage of significantly large and complex defects of the lower third of the leg. Free flaps had the disadvantage of being sophisticated and

lengthy procedures that need expertise and advanced equipment.

References

1. **Ahmad I, Akhtar S, Rashidi E *et al.*** (2013): Hemisoleus muscle flap in the reconstruction of exposed bones in the lower limb. *J. Wound Care*, 22(11): 635-640.
2. **Lu TC, Lin CH, Lin YT *et al.*** (2011): Versatility of the pedicled peroneal artery perforator flaps for soft-tissue coverage of the lower leg and foot defects. *Journal of Plastic Reconstructive and Aesthetic Surgery*, 64(3):386-393.
3. **Parret BM and Pribaz JJ** (2010): Lower extremity reconstruction. *Rev. Med. Clin. Condes.*, 21(1):66 -75.
4. **Jordan DJ, Malahias M, Hindocha S *et al.*** (2014): Flap decisions and options in soft tissue coverage of the lower limb. *The Open Orthopaedics Journal*, 8(2) 423-432.
5. **Georgescu AV** (2012): Propeller perforator flaps in distal lower leg: evolution and clinical applications. *Archives of Plastic Surgery*, 39(2): 94-105.
6. **Gir P, Cheng A, Oni G *et al.*** (2012): Pedicled perforator (Propeller) flaps in lower extremity defects: a systematic review. *J. Reconstr. Microsurg.*, 28(9): 595-601.
7. **Masquelet AC, Romana MC and Wolt G** (1992): Skin island flaps supplied by the vascular axis of the sensitive superficial nerves: anatomic study and clinical experience in the leg. *Plast. Reconstr. Surg.*, 89: 1115-1121.
8. **Rogers AD** (2014): Propeller flaps for lower-limb trauma. *S. Afr. J. Surg.*, 52(4):105-107.
9. **Kumar PS, Srinivas ER and Anandan H** (2017): Reconstruction of lower one-third leg soft tissue defects. *International Journal of Scientific Study*, 5 (7):80-85.
10. **Khouri RK and Shaw WW** (1989): Reconstruction of lower extremity with microvascular free flaps a 10 year experience with 304 consecutive cases. *J. Trauma*, 29(8): 1086-1094.
11. **Santanelli F** (2005): Lower extremity reconstruction, tibia, e-medicine; 2005. <https://www.ijss->

sn.com/uploads/2/0/1/5/20153321/ijss_oct_oa18_-
_2017.pdf

12. Kang MJ, Chung CH, Chang YJ *et al.* (2013): Reconstruction of the lower extremity using free flaps. *APS.*, 40(5),575-583.

13. Godina M (1986): Early microsurgical reconstruction of complex trauma of the extremities. *Plast. Reconstr. Surg.*, 78(3):285–292.

14. Byrd HS, Spicer TE and Cierney G (1985): Management of open tibial fractures. *Plast. Reconstr. Surg.*, 76: 719-730.

15. Khurram MF, Ahmad I and Nanda M (2014): Soft tissue reconstruction of foot and ankle defects: free vs pedicled flaps with the use of 6 different flaps in 50 cases of road traffic accidents. *Austin. J. Surg.*, 1(7):14-18.

16. Bhatti A, Adeshola A, Ismael T *et al.* (2006): Lower leg flaps comparison between free versus local flaps. *Internet Journal of Plastic Surgery*, 3(2):1-8.

17. Bekara F, Herlin C, Mojallal A *et al.* (2016): A systematic review and meta-analysis of perforator-pedicled propeller flaps in lower extremity defects: identification of risk factors for complications. *Plast. Reconstr. Surg.*, 137(1): 314-331.

18. Mahesh SG, Ashwath NR, Balaji R *et al.* (2018): Reconstructive strategies for lower one-third leg soft tissue defects. *International Surgery Journal*, 5(12): 4016-4021.

19. Daigeler A, Dodic T, Awiszus F *et al.* (2005): Donor-site morbidity of the pedicled rectus femoris muscle flap. *Plast. Reconstr. Surg.*, 115(3):786-792.

20. Gardetto A, Raschner Ch, Schoeller T *et al.* (2005): Rectus femoris muscle flap donor-site morbidity. *Br. J. Plast. Surg.*, 58(2):175-82.

21. Smith SL (2014): Functional morbidity following latissimus dorsi flap breast reconstruction. *Journal of Advanced Practitioner*, 5(3):181-187.