

THE PROLIFERATIVE EFFECT OF CURCUMIN NANO PARTICLES ON RADIATED PAROTID GLANDS OF ALBINO RATS

Omyma Mohamed Meabed,^{*ID} Ali Shamaa^{**ID} and Saher Sayed Mohammed^{**ID}

ABSTRACT

Objectives: Xerostomia, which occurs early in the course of radiation, causes a decrease in salivary flow rate. The time it takes for a patient's salivary function to become diminished varies. The salivary glands go through a variety of histological alterations.

Aim: The goal of this study was to explore how curcumin nanoparticles affected cellular proliferation after radiotherapy. Curcumin nanoparticles are an anti-oxidant material that has been used to treat the histopathological alterations caused by radiation therapy in the parotid glands of albino rats.

Materials and methods: The researchers used 45 adult male Albino rats, 15 for the control group, 15 for the radiated group, and 15 for the curcumin nanoparticle group. The parotid glands were dissected and histological and immunohistochemical examinations were performed.

Result: Curcumin nanoparticles have a proliferative action that restores atrophied radiated parotid glands, according to histological and immunohistochemistry data.

Conclusion: Curcumin nanoparticles have been shown to be a proliferative and anti-oxidant substrate in the treatment of histological abnormalities in albino rats radiated parotid glands.

KEYWORDS: radiotherapy; curcumin; nanoparticles; PCNA; Parotid Glands.

INTRODUCTION

Radiotherapy for cancer treatment is used in a variety of ways around the world. According to some estimates, nearly half of all cancer patients fall into this category should take radiation therapy (Delaney, Jacob, Featherstone, & Barton, 2005).

Many negative effects, such as decreased salivary flow rate and mouth dryness, appear early in the irradiation treatment (Vissink, Jansma, Spijkervet, Burlage, & Coppes, 2003).

Inhibited oral function, a burning feeling, chapped lips, and increased susceptibility to oral

* Oral Biology Department Faculty of Dentistry Benisuef University Benisuef Egypt

** Oral Biology Department, Faculty of Dentistry, Minia University Minia, Egypt

infections and dental caries are all symptoms of salivary gland dysfunction. Radiation therapy alters the composition of saliva by increasing viscosity, reducing buffering capacity, changing electrolyte concentrations and affecting the nonimmune and immune antibacterial systems (Tolentino et al., 2011).

One-week post-irradiation, gamma-irradiated parotid glands expressed many destructive changes including a massive loss of acinar architecture, a widen inter-acinar space, sever acinar atrophy, vacuolization and degeneration. The acini exhibited nuclear pleomorphism and hyperchromatism from a cellular standpoint. The ducts' harmful effects included cellular architecture loss, cell vacuolization, and perinuclear hallow. The destructive manifestations of the ducts included loss of cellular architecture, cell vacuolization and perinuclear hallow. The parotid glands of the quercetin (flavonoid anti-oxidant substance) + radiation group revealed almost a normal outline and architecture of the acini. Moderate acinar atrophy and degenerative alterations were limited to discrete areas in the gland. The cells of acini showed normal size and nucleal stain while, the ducts were normal with slight architectural distortion (Hani, Abd Elmawla, Ahmed, & Emran, 2019).

Anti-oxidants are generally reducing substances, such as thiols, ascorbic acid, or polyphenols, since they block the oxidation of other molecules by oxidizing themselves (Began, Sudharshan, Sankar, & Rao, 2000). Curcumin (diferuloylmethane), derived from the turmeric plant *Curcuma longa*, and its derivatives, known as curcuminoids, has been studied as an anti-inflammatory drug for cancer and other disorders (Dende et al., 2017). Curcumin nano-range formulations, often known as "nanocurcumin," have been developed, they have given a strong evidence to reap all the biological benefits from this phyto-drug (Flora, Gupta, & Tiwari, 2013). Curcumin suggested to protect

normal cells against the harmful effects of radiation. Its ability to reduce oxidative stress and inhibit transcription of genes related to oxidative stress and inflammatory responses may be the main reason for its radioprotective effect (GC, 2007).

PCNA (proliferating cell nuclear antigen) is a DNA polymerase delta helper factor involved in both DNA replication and repairing. PCNA is required in the resynthesis step of nucleotide excision repair (NER) and base excision repair (BER) in vitro investigations (BER). Immunohistochemistry of PCNA in the cytoplasm and nuclei of salivary glands (El-Sakhawy, Abusaida, Issa, & Al-Sabaa, 2020).

The degree of PCNA immunoreaction depends on the dose of radiation (Kujan et al., 2015); As radiation cause dimension of epithelial stem cells, which are required for mucosal proliferation and renewal (J. Zhang et al., 2021). PCNA expression was improved by curcumin (CUR)-loaded PLGA in colon carcinogenesis induced mice (Elbassiouni, El-Kholy, Elhabibi, Albogami, & Fayad, 2022). The levels of PCNA protein were increased when chitosan and 0.5% gingival fibroblasts were combined.

When cells were treated with Cur NPs, the expression of the inflammatory cytokines IL6, NFkB, COX₂, COX₁ and mRNA was drastically reduced. Cur NPs could be a viable anti-inflammatory drug, according to these studies. (Khamis, Elkeiy, El-Magd, & El-Gamal, 2019).

MATERIALS AND METHODS

Experimental procedure

Animal Model:

The Atomic Energy Authority got 45 adult male Albino rats with an average weight of 200-250 g from the animal home. The animals were kept in a controlled environment (25°C and 12 hour dark/

light cycles) and fed a regular pellet diet and ad libitum tap water. They were housed in separate cages. All studies were carried out at the animal house at the National Center for Radiation Research and Technology in Egypt, in accordance with the recommendations of the Faculty of Oral and Dental Medicine's ethics committee on animal experimentation (ethical approval number 399/2020).

Animal classification; the animals were split into four classes (3 main groups). The control group (group I) consisted of 15 healthy rats who were kept away from the radiation building. There were 15 rats in Group II (radiated group). Rats were placed in a lead cylinder to shield their bodies from radiation while their heads were exposed. Radiation was carried out with a cobalt 60 radioisotope source (energy 1.25 MV). Indian gamma cell dosage rate is 0.971 K.Gy/h (0.2697Gy/sec). The rats' heads were irradiated with a single pulse of 15 Gy (56 seconds) at an SSD (source surface distance) of 80 cm (Yang et al., 2018). Each of the 15 rats in Group III (Nano-Curcumin treated group) received a daily dose of nanocurcumin diluted with filtered water (1:8) (Modasiya & Patel, 2012), was given by oral gavage 48 hours before radiation, then 24 hours afterwards, and then every day for a week (100 mg/kg body weight each day) (Sankar et al., 2014).

Irradiation

30 minutes before the irradiation, the animals were weighed and anaesthetized with an intramuscular dosage of thiopental 70 mg/kg and atropine 40 mg/kg (Abdelrahman, El-Kashef, & Hassan, 2020). Only the head and neck parts of the animals were exposed since they were placed on the cylinder lead to protect the body. The dosage rate is approximately 26.97 cGy/sec. The rats' heads were irradiated with a dose of 15 Gy (56 seconds) delivered in a single shot at a distance of 80 cm from the SSD source surface. This radiation source is predicted to deliver 100% of its dose at a distance of 0.5 cm from the skin. (Yang et al., 2018).

Materials

Now food company procured curcumin, Turmeric curcumin powder Pure Nature 100 percent Pure Curcumin Extract (Standardized to 95 percent Curcuminoids).

Synthesis of Curcumin nanoparticles

curcumin was dissolved in distilled water (100 ml). All the solution was mixed with 2 ml of isopropanol in every solution to avoid the formation of freer radicals and all solutions were gamma-irradiated at 15 kGy. The color changes were due to the surface plasmon resonance (SPR) and confirmed the formation of curcumin nanoparticle (Cur NPs).

Tissue samples

The animals were sacrificed with an intra-peritoneal injection of ketamine at 100 mg/kg once the experiment period was completed, and the parotid glands were dissected. The tissues were washed in saline solution and fixed for 24 hours in 4 percent buffered formalin, then dehydrated in ethyl alcohol in successive stages, cleaned in xylene, and embedded in paraffin. microscope slides, 4-5 m thick sections were obtained and collected on microscope slides.

Haematoxylin and Eosin (H&E) staining

For histological evaluation of morphological changes, a set of sections from each of the four groups were stained with haematoxylin and eosin solutions, dried, mounted, and inspected in a Leica light microscope outfitted with a digital camera and image processing software.

Immunohistochemistry

The method utilized was avidin-biotin in conjunction with alkaline phosphatase. Washing and rehydrating. For 60 minutes, the slides were treated with diluted primary antiserum (1: 100), anti-mouse IgG biotin compound (Sigma Chemie GmbH, Deisenhofen, Germany, code No. B-0529),

and avidin-alkaline phosphatase complex (Sigma Chemie GmbH, code No. E-2636). For 20 minutes, the substrate solution (fast red chromogen, Dako Diagnostics GmbH, code No. K 699) was incubated; after each incubation phase, three washes (5 minutes each) in buffer were performed (0.05 M Tris, 0.15 M NaCl, pH 7.6). Immuno-gold-silver staining (IGSS) was used as an alternative (Schlatt & Weinbauer, 1994).

Histomorphometry Analyses

The image analyzing computing system is composed of a digital camera coupled to a light microscope, as well as a computer system running the Leica Quin 5000 software (Leica Microsystems Inc., Switzerland) capable of performing high speed digital image processing. H&E-stained sections were used to count the number of nuclei per field and the number of acini per field using magnification (400x). In the Immunolabelled sections for PCNA the area and area percentage of PVNA immunoreaction in 15 fields from each group using magnification (400x) were measured.

Statistical Analysis

The arithmetic mean (\bar{X}), standard deviation (SD), and analysis of variance were used in the statistical study (ANOVA). All statistical analyses were performed on an IBM PC running SPSS 17 (Statistical Package for Scientific Studies) for Windows. When the probability (P-) value was less than 0.05, the results were considered significant, highly significant when the P-value was less than 0.01 and extremely highly significant when the P-value was less than 0.001.

Histological Examination Results

Group I (control group)

Parotid gland of control group was found to be composed of secretory end pieces and collecting ducts. The secretory end pieces were arranged in

spherical fashion and each one was composed of pyramidal shaped serous cells with basally located rounded deeply basophilic nuclei. The intercalated ducts were lined by cuboidal cells and had a narrow and compressed lumens, the striated ducts appeared to be lined by low columnar cells with centrally placed nuclei (**fig. 1.A**).

Group II (radiated group)

Histological examination and evaluation of hematoxylin and eosin-stained sections of radiated parotid gland in rats revealed increase in the inter acinar and interlobular spaces. The gland appeared to be composed of parenchyma and connective tissue stroma, CT septa thickness was increased in this group. Serous acini were found to lose their architecture and arrangement with ill-defined boundaries. The nuclei of serous acinar cells showed hyperchromatism, pleomorphism, abnormal mitotic figures, karyomegaly and perinuclear haloing. Intercalated ducts appeared to be dilated and stagnated. The lining cells of intercalated ducts appeared with abnormal nuclear morphology. Striated ducts appeared with stagnant secretion, cell proliferation and abnormal nuclear morphology (**fig.1.B**).

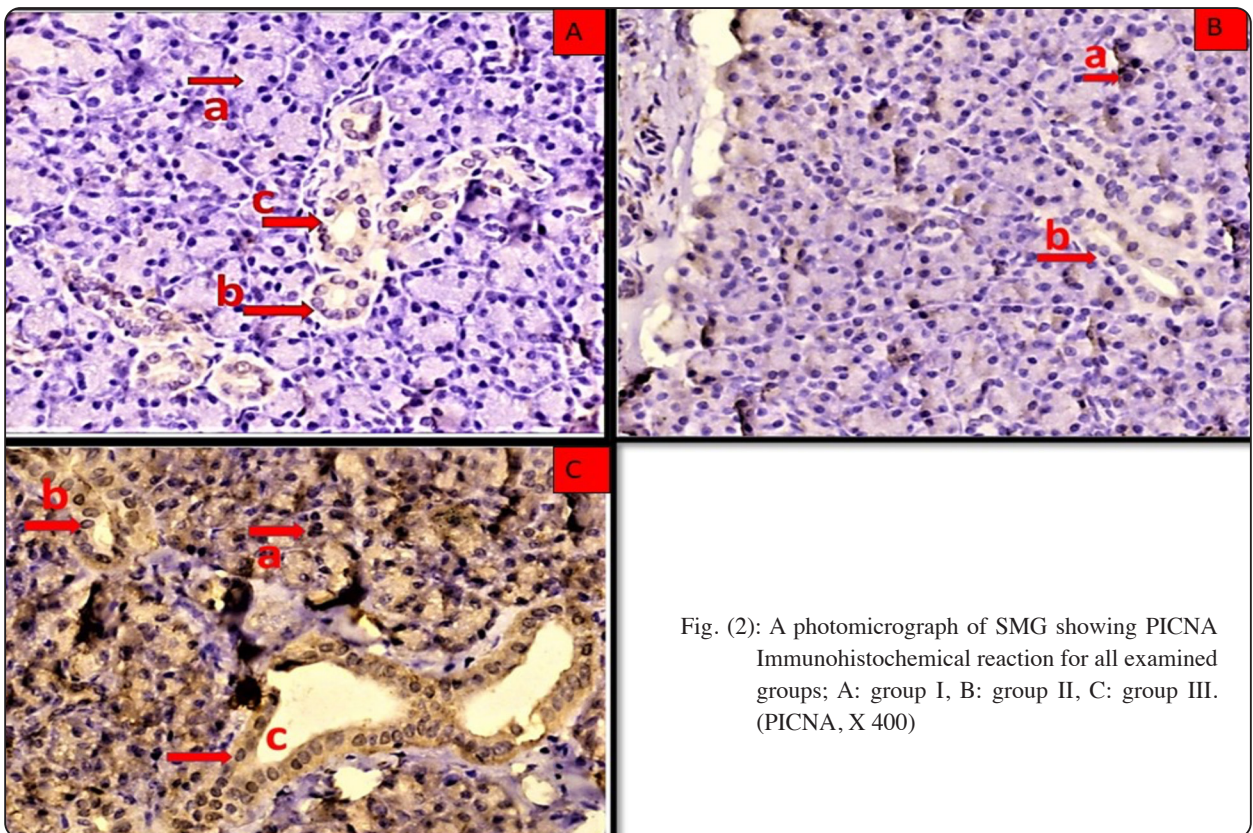
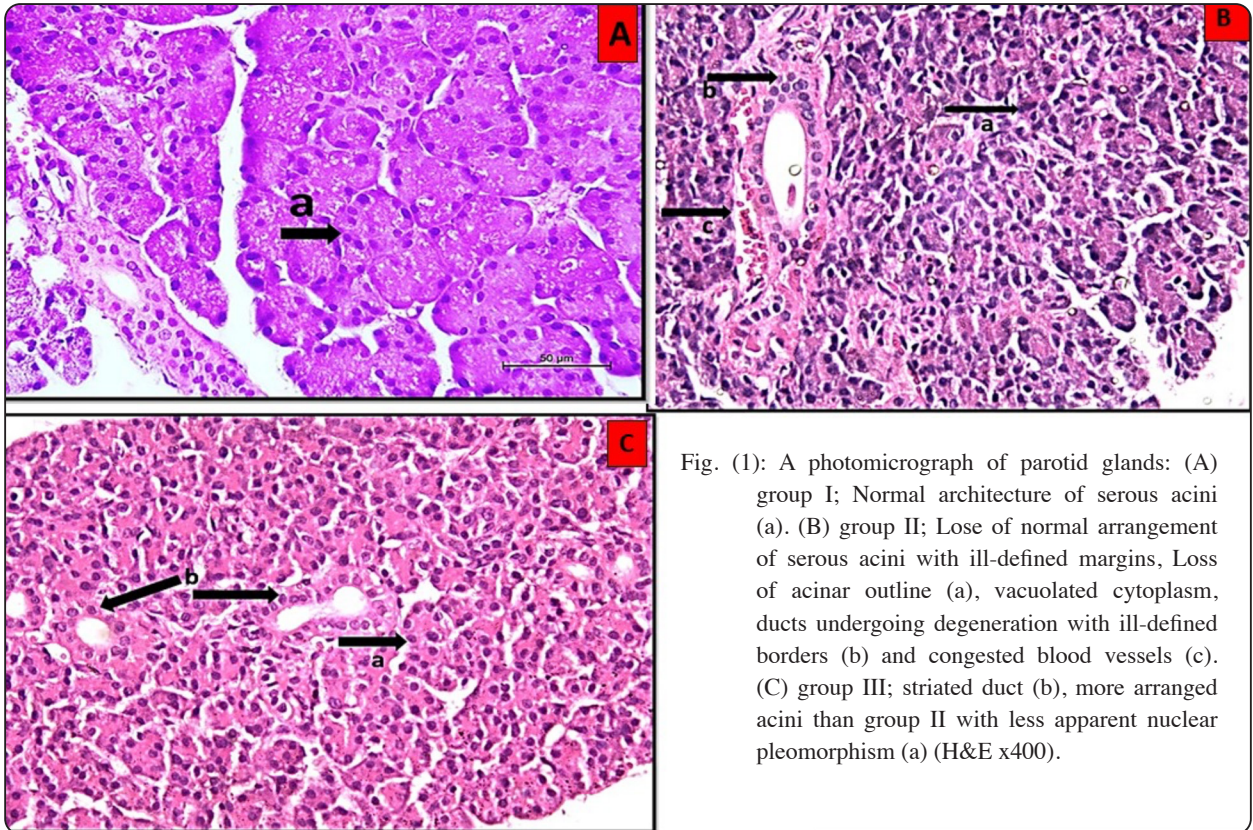
Group III (Curcumin nanoparticles treated group)

Radiated parotid gland treated with curcumin nanoparticles showed histological features of normal parotid glands. The acini started to restore its normal architecture. The nuclear changes appeared less than in group II (radiated group). The duct system with less histological deformity (**fig.1.C**).

Immunohistochemical Results of PCNA

Group I (control group)

Control rats' parotid gland immunoreaction patterns revealed that secretory cells of serous acini and epithelial lining cells in the duct system had negative nuclear and cytoplasmic immunological reaction for PCNA (Fig.2.A).



Group II (radiated group)

This group's immune-stained parotid gland sections indicated that the cytoplasm and nucleus of serous acinar cells and duct cells were negative for PCNA. On the other hand, the nuclei of some acinar and ductal cells reacted positively to PCNA (Fig.2.B).

Group III (Cur NPs treated group)

Anti PCNA antibody was used to stain slices of the parotid gland from group C, which demonstrated strong positivity throughout the gland. The cytoplasmic and nuclear immunoreactivity for PICNA was seen in the serous acinar sections, intercalated duct, striated duct, and excretory duct. (Fig.2.c).

Histomprphometric, color density area percentage statistical analysis Statistical analysis revealed a high significant difference between the control group and radiated groups as regarding the number of nuclei/slide and the number of acini/field. The difference between radiated group and the CurNP group was significant regarding acini/field while highly significant regarding nuclei/field and PCNA color density area percentage.

TABLE (1): P-values of comparison between every two groups as regarding all parameters

Group 1	Group 2	Acini/ slide P value	Nuclei/ slide P value	Area percentage for PCNA P value
Control	Radiated	0.001**	0.001**	0.131
	Nanocurcumin	0.045*	0.789	0.001**
Radiated	Nanocurcumin	0.027*	0.001**	0.001**

*P value: Probability value *; P-value 0.05 Significant
**; P-value 0.01 High Significant NS: Non-significant
P-value > 0.05*

DISSCUSION

In 2008, it was estimated that 28.800,000 persons above 5 years had tumors worldwide. Oral cancer is highly common cancer in India, while Kaposi sarcoma is a cancer with the greatest five-year incidence in African countries (**Bray et al., 2013**).

Large chemotherapy and radiation doses have improved the long-term survival rates of young cancer patients, even at the cost of considerable side effects (**Meirow & Nugent, 2001**).

Radiation therapy for head and neck cancer has considerable secondary side effects in normal salivary glands, resulting in a lower quality of life for those who get it. Radiation is extremely sensitive to salivary glands, which show acute and chronic reactions to irradiation (**Grundmann, Mitchell, & Limesand, 2009**).

Ionizing radiation generates ROS, such as hydroxyl radicals, superoxide radicals and other oxidants like hydrogen peroxide, to develop in the tissue environment. As a result of several chemical interactions, more harmful radicals are formed (**Borek, 2004**).

There is a need for a medication or prescription that is naturally available, has no known side effects, and is inexpensive to alleviate the negative consequences of radiotherapeutic treatment. The anti-radiotherapeutic effects of curcumin nanoparticles on the level of histological and structural changes in the parotid glands of albino rats were investigated.

The serous acini in this study's radiated group had an irregular shape and seemed to be distant from one another (increase in inter-acinar spaces). It was discovered that the foundation membrane of certain acini had ruptured. Variable levels of atrophy, perinuclear haloing, aberrant mitotic figures, hyperchromatism, karyomegaly, and cytoplasmic vacuolization were present in the acinar cells. The nuclei were either binucleated or elongated and pressed up against the cell membrane. Red blood

cells (RBCs) that had extravasated were seen between the acini. Thinning and atrophies were visible in the ductal epithelial lining. All types of ducts showed perinuclear haloing and cytoplasmic vacuolization. Excretory channels were found between the lobules, and they were encircled by C.T. stroma, which showed hyalinization. Blood vessels that were intensely conjugated with RBCs dilated and thickened in the C.T. stroma.

All of the earlier findings supported the findings of **Stramandinoli-Zanicotti et al., 2013**, who demonstrated that the majority of cells had prominent, bigger, and hyperchromatic nuclei. Comparatively to the non-irradiated glands, fibrosis and parenchyma loss were seen. Ductal dilatation was the most frequent of the several ductal changes, and it was occasionally accompanied by cellular debris. According to **Shubin, Demidyuk, Komissarov, Rafieva, & Kostrov, 2016**, who pointed them to the decrease in the water content in the cytoplasm of apoptotic cells, the perinuclear haloing and cytoplasmic vacuolization seen in the serous acinar cells as well as in the duct cells in the current study might be explained. The cells respond by swelling and vacuolizing as a result. Additionally, they discovered that vigorous vacuolization, which might be lipid-filled or autophagic vacuoles, resulted in lytic or apoptotic cell death. This could be justified to the increase in the acinar atrophy in IR group in the current work.

Another explanation for the perinuclear vacuolization and haloing has been proposed by **Short, 2014** who pointed them toward the mechanical strain placed on the widely spaced nuclear membranes. In the current study, the strain may have resulted from an increase in the cytoplasmic lipid concentration.

In the ongoing study acinar atrophy was observed in radiated group. This atrophy explained by **Jasmer, Gilman, Forti, Weisman, & Limesand, 2020** who reported that, programmed cell death of acinar cells of rats salivary glands occurs from eight to seventy

two hours after radiotherapy, the peak occurs after one day from parotid glands radiation. To describe this acute mechanistic state, apoptosis has been studied in a variety of approaches, including elevated apoptosis regulator mRNA expression as well as caspase-3 protein breakdown.

McKinnell & Rudnicki, 2004 reported that atrophy is the loss of a cell's substance, which causes it to diminish in size. Atrophic cells may have lost function, but they are not dead, according to the researchers. According to the authors, atrophy can be caused by a lack of blood flow and poor nourishment. Atrophic cells' underlying cellular alterations were discovered to depict the cell's retreat to a smaller size where survival is still viable. A novel equilibrium between cell size and reduced blood supply or nourishment has been discovered.

Xerostomia after radiation has been resulted from serous acinar cells atrophy. In normal tissue, they make up roughly eighty percent of the volume of parotid gland and are in charge of producing water and protein (**Grundmann, Mitchell, & Limesand, 2009b**).

Radiated group parotid gland ducts demonstrated cell lining atrophy, duct dilatation, retained secretion in this investigation. these results supported by **Cheng, Wu, Kwong, & Ying, 2011** who identified parenchymal atrophy, acinar degeneration and interstitial fibrosis in both irradiated parotid and submandibular glands, as well as dilated intercalated and striated duct.

In the tissue, radiation induces three key changes: hypo-vascularity, hypo-cellularity and hypoxia. Decreasing in oxygen level induced adverse actions, duct blockage and a range of mechanisms that affect salivary secretion. Hypo-oxygenation, that may be brought on by vascular abnormalities, affects oxidative aerobic cellular activity and leads to cell death. Cells can adapt, incur harm, or even perish depending on the degree of the hypoxic state. Radiation-induced fibrosis is a theory that claims that stimulation and instability of mesenchymal activity

causes tissue shrinkage in earlier irradiated regions. Cell damage is caused by inflammatory reaction, oxidative stress, continual fibroblast stimulation, and growth regulators (**Stramandinoli-Zanicotti et al., 2013**).

In the present study the area percentage of PCNA marker in cur NP treated group showed intense positive immunoreactivity than radiated group; this agrees with (**Kujan et al., 2015**) who proved that the degree of reaction depends on the degree of radiation; this explained by **Yasser & Shon, 2020** who proved that in an attempt to avoid the damage caused by oxidative stressors, diabetic SMG had higher levels of PCNA expression in the seromucous acini than controls.

Curcumin positive immunoreaction illustrated by **Ghufran et al., 2020** who said that curcumin human combined with adipose derived stem cells (Cur-hASCs) co-injected with platelet rich plasma resulted in improved wound healing and proliferation of fibroblasts is increased, increased vascular supply and a significant decrease in inflammatory cells. Furthermore, Cur-hASCs + PRP treatment increased the expression of critical wound healing markers such as cell migration (bFgf) and cell proliferation (PCNA).

Our results supported by **Lee et al., 2006** study who found that compared to laryngeal tumors before radiotherapy, PCNA expression increased in recurrent laryngeal tumors after radiotherapy. Following treatment, recurrent laryngeal tumors were physiologically aggressive.

Z Kelman, 1997 proved that despite the fact that the cells were not in S-phase, the nucleus reacted positively with anti-PCNA antibodies after UV irradiation caused DNA damage. This finding suggested that the protein is involved in DNA repair processes. PCNA has been shown to be involved in DNA excision and mismatch repair mechanisms in in vitro repair tests.

The highest percentage of PCNA-positive immune-reactivity was found in radiated parotid

salivary glands in Groups A (high dose of radiation) and group D (low dose of radiation). The degree of reaction depends on the dose of radiation (**Kujan et al., 2015**); as radiation cause damage to epithelial stem cells, which are important for proliferation and renewal of the mucosal cells (**J. Zhang et al., 2021**).

In the ongoing study PCNA expression elevation after radiotherapy can be explained by **Xu & Morris, 1999** who making a study on fibroblast cell line of a mice embryo (CREF cells) exposed to γ radiation which increased PCNA expression. They found that PCNA mRNA expression elevated transiently in serum-depleted cells exposed to ionising radiation, implying that the radiation-induced increase in PCNA expression could be separated from cell cycle progression. Irradiation of CREF cells activated p53 binding regions in the PCNA promoter via a mechanism that was prevented by a dominant negative mutant p53.

The PCNA gene is upregulated by p53, and the PCNA protein interacts with p53-regulated proteins to determine cell fate. Apoptosis happens when PCNA is rendered non-functional or is absent or present in low numbers in the cell; on the other hand, DNA repair occurs when PCNA protein levels are high in the cell in the presence of p53 (**Paunesku et al., 2001**).

Shan, Xu, Zhuo, Morris, & Morris, 2003 confirmed these findings through a human fibroblast cell line. After exposure to ionizing radiation, a human fibroblast cell line with conditional p53 expression showed a p53-dependent rise in both the protein and mRNA levels of proliferating cell nuclear antigen (PCNA) (IR). A p53-responsive element was used in conjunction with p53 induction and irradiation to activate a transiently produced human PCNA promoter-reporter gene.

In the present study curcumin nanoparticles treated group is showing a high proliferative results through PCNA positive immunoreaction. This finding agreed with **Elbassiouni, El-Kholy, Elhabibi, Albogami, & Fayad, 2022** who found

that PCNA expression was improved by curcumin (CUR)-loaded PLGA in colon carcinogenesis induced mice.

In acute renal damage rats given curcumin, the expression of proliferating cell nuclear antigen (PCNA) increased considerably. PCNA is a DNA polymerase auxiliary protein that plays a critical function in the start of cell proliferation. The degree of PCNA expression correlates closely with the rates of cellular proliferation and DNA replication, making it a good indicator of renal regeneration. As a result of the findings, curcumin appears to be able to increase cell proliferation and renal tissue repair (Wu et al., 2017).

On the other hand M. Zhang, Bian, Wen, & Hao, 2007 suggested that curcumin could significantly inhibit the proliferation of human pterygium fibroblasts (HPF), make HPF arrest in G0/G1 phase and induce the apoptosis of HPF in a dose-and time-dependent manner. More studies needed to end this debate.

CONCLUSION

Curcumin nanoparticles have the ability to alleviate the albino rat's parotid glands histological deformity resulted from radiation, through its proliferative effect.

REFERENCES

- Abdelrahman, I., El-Kashef, H., & Hassan, N. (2020). Anti-Tumor Effect of Green Tea Extract, Simvastatin and Gamma Radiation on Solid Tumor in Mice. *Arab Journal of Nuclear Sciences and Applications*, 0(0), 1–14. <https://doi.org/10.21608/ajnsa.2020.22827.1322>
- Began, G., Sudharshan, E., Sankar, K. U., & Rao, A. G. A. (2000). Interaction of Curcumin with Phosphatidylcholine: A Spectrofluorometric Study. *Journal of Agricultural and Food Chemistry*, 48(2), 576–576. <https://doi.org/10.1021/jf991308g>
- Borek, C. (2004). Antioxidants and radiation therapy. *Journal of Nutrition*, 134(11), 3207S–3209S. <https://doi.org/10.1093/jn/134.11.3207s>
- Cheng, S. C. H., Wu, V. W. C., Kwong, D. L. W., & Ying, M. T. C. (2011). Assessment of post-radiotherapy salivary glands. *The British Journal of Radiology*, 84(1001), 393. <https://doi.org/10.1259/BJR/66754762>
- Dende, C., Meena, J., Nagarajan, P., Nagaraj, V. A., Panda, A. K., & Padmanaban, G. (2017). Nanocurcumin is superior to native curcumin in preventing degenerative changes in Experimental Cerebral Malaria. *Scientific Reports*, 7(1). <https://doi.org/10.1038/s41598-017-10672-9>
- El-Sakhawy, M., Abusaida, H., Issa, Y., & Al-Sabaa, A. (2020). Immunohistochemical expression of proliferating cell nuclear antigen (PCNA) in the parotid salivary glands of male albino rats after long administration of . Retrieved from <http://www.aljameai.org.ly/index.php/aljameai/article/download/350/303>
- Elbassiouni, F. E., El-Kholy, W. M., Elhabibi, E. S. M., Albogami, S., & Fayad, E. (2022). Comparative Study between Curcumin and Nanocurcumin Loaded PLGA on Colon Carcinogenesis Induced Mice. *Nanomaterials*, 12(3). <https://doi.org/10.3390/nano12030324>
- Flora, G., Gupta, D., & Tiwari, A. (2013). Nanocurcumin: a promising therapeutic advancement over native curcumin. *Critical Reviews in Therapeutic Drug Carrier Systems*, 30(4), 331–368. <https://doi.org/10.1615/critrevtherdrugcarriersyst.2013007236>
- GC, J. (2007). Radioprotection and radiosensitization by curcumin. *Advances in Experimental Medicine and Biology*, 595, 301–320. https://doi.org/10.1007/978-0-387-46401-5_13
- Ghufuran, H., Mehmood, A., Azam, M., Butt, H., Ramzan, A., Yousaf, M. A., Riazuddin, S. (2020). Curcumin preconditioned human adipose derived stem cells co-transplanted with platelet rich plasma improve wound healing in diabetic rats. *Life Sciences*, 257, 118091. <https://doi.org/10.1016/J.LFS.2020.118091>
- Grundmann, O., Mitchell, G. C., & Limesand, K. H. (2009a). Sensitivity of salivary glands to radiation: from animal models to therapies. *Journal of Dental Research*, 88(10), 894–903. <https://doi.org/10.1177/0022034509343143>
- Grundmann, O., Mitchell, G. C., & Limesand, K. H. (2009b). Sensitivity of Salivary Glands to Radiation: from Animal Models to Therapies. *Journal of Dental Research*, 88(10), 894. <https://doi.org/10.1177/0022034509343143>
- Hani, S., Abd Elmawla, A. E., Ahmed, S., & Emran, A. (2019). Histological and immunohistochemical evaluation for the effect of pilocarpine and quercetin on gamma-irradiated parotid salivary glands. *Egyptian Journal of Radiation Sciences and Applications*, 0(0), 0–0. <https://doi.org/10.1016/j.ejras.2019.01.001>

- org/10.21608/ejrja.2018.4820.1048
- Jasmer, K. J., Gilman, K. E., Forti, K. M., Weisman, G. A., & Limesand, K. H. (2020). Radiation-Induced Salivary Gland Dysfunction: Mechanisms, Therapeutics and Future Directions. *Journal of Clinical Medicine*, 9(12), 1–37. <https://doi.org/10.3390/JCM9124095>
 - Khamis, A. A., Elkeiy, M. M., El-Magd, M. A., & El-Gamal, M. M. (2019). Arabian Journal of Medical Sciences Chitosan nanoparticles from *Artemia salina* attenuate LPS-induced inflammation in MCF7 cells. *AJMS*. <https://doi.org/10.5455/ajms.23>
 - Kujan, O., Othman, R., Alshehri, M., Iqbal, F., Kochaji, N., & Proliferative, K. N. (2015). Radiotherapy impact on salivary myoepithelial cells activity ... Kujan O et al Conflicts of Interest: None Source of Support: Nil Proliferative Activity of Myoepithelial Cells in Irradiated Rabbit Parotid and Submandibular Salivary Glands. In *Journal of International Oral Health* (Vol. 7).
 - Lee, B. J., Wang, S. G., Roh, H. J., Goh, E. K., Chon, K. M., & Park, D. Y. (2006). Changes in expression of p53, proliferating cell nuclear antigen and bcl-2 in recurrent laryngeal cancer after radiotherapy. *The Journal of Laryngology and Otology*, 120(7), 579–582. <https://doi.org/10.1017/S0022215106001150>
 - McKinnell, I. W., & Rudnicki, M. A. (2004). Molecular Mechanisms of Muscle Atrophy. *Cell*, 119(7), 907–910. <https://doi.org/10.1016/J.CELL.2004.12.007>
 - Modasiya, M. K., & Patel, V. M. (2012). INTERNATIONAL JOURNAL OF PHARMACY & LIFE SCIENCES Studies on solubility of curcumin. *Int. J. of Pharm. & Life Sci. (IJPLS)*, 3, 1490–1497.
 - Paunesku, T., Mittal, S., Protić, M., Oryhon, J., Korolev, S. V., Joachimiak, A., & Woloschak, G. E. (2001). Proliferating cell nuclear antigen (PCNA): ringmaster of the genome. *International Journal of Radiation Biology*, 77(10), 1007–1021. <https://doi.org/10.1080/09553000110069335>
 - Sankar, P., Telang, A. G., Ramya, K., Vijayakaran, K., Kesavan, M., & Sarkar, S. N. (2014). Protective action of curcumin and nano-curcumin against arsenic-induced genotoxicity in rats in vivo. *Molecular Biology Reports*, 41(11), 7413–7422. <https://doi.org/10.1007/s11033-014-3629-0>
 - Schlatt, S., & Weinbauer, G. E. (1994). Immunohistochemical localization of proliferating cell nuclear antigen as a tool to study cell proliferation in rodent and primate testes.
 - Shan, B., Xu, J., Zhuo, Y., Morris, C. A., & Morris, G. F. (2003). Induction of p53-dependent Activation of the Human Proliferating Cell Nuclear Antigen Gene in Chromatin by Ionizing Radiation. *Journal of Biological Chemistry*, 278(45), 44009–44017. <https://doi.org/10.1074/JBC.M302671200>
 - Stramandinoli-Zanicotti, R. T., Sassi, L. M., Schussel, J. L., Torres, M. F., Funchal, M., Smaniotto, G. H., ... Carvalho, A. L. (2013). Effect of fractionated radiotherapy on the parotid gland: an experimental study in Brazilian minipigs. *International Archives of Otorhinolaryngology*, 17(2), 163–167. <https://doi.org/10.7162/S1809-97772013000200008>
 - Tolentino, E. de S., Centurion, B. S., Ferreira, L. H. C., de Souza, A. P., Damante, J. H., & Rubira-Bullen, I. R. F. (2011). Oral adverse effects of head and neck radiotherapy: Literature review and suggestion of a clinical oral care guideline for irradiated patients. *Journal of Applied Oral Science*, 19(5), 448–454. <https://doi.org/10.1590/S1678-77572011000500003>
 - Vissink, A., Jansma, J., Spijkervet, F. K. L., Burlage, F. R., & Coppes, R. P. (2003). Oral sequelae of head and neck radiotherapy. *Critical Reviews in Oral Biology and Medicine*, Vol. 14, pp. 199–212. <https://doi.org/10.1177/154411130301400305>
 - Wu, J., Pan, X., Fu, H., Zheng, Y., Dai, Y., Yin, Y., ... Hou, D. (2017). Effect of curcumin on glycerol-induced acute kidney injury in rats OPEN. *Nature*. <https://doi.org/10.1038/s41598-017-10693-4>
 - Xu, J., & Morris, G. F. (1999). p53-Mediated Regulation of Proliferating Cell Nuclear Antigen Expression in Cells Exposed to Ionizing Radiation. *Molecular and Cellular Biology*, 19(1), 12–20. <https://doi.org/10.1128/mcb.19.1.12>
 - Yang, G., Wang, Y., Cui, Z., Due, B., Yin, G., Yu, Y., & Zhang, W. (2018). Expression and Analysis of EPOR after Radiation Injury of Salivary Glands in Rats. 2(1), 2–5.
 - Z Kelman. (1997). PCNA: structure, functions and interactions. *Nature.Com*. Retrieved from <https://www.nature.com/articles/1200886>
 - Zhang, J., Hong, Y., Liuyang, Z., Li, H., Jiang, Z., Tao, J., ... Wang, G. (2021). Quercetin Prevents Radiation-Induced Oral Mucositis by Upregulating BMI-1. *Oxidative Medicine and Cellular Longevity*, 2021. <https://doi.org/10.1155/2021/2231680>
 - Zhang, M., Bian, F., Wen, C., & Hao, N. (2007). Inhibitory effect of curcumin on proliferation of human pterygium fibroblasts. *Journal of Huazhong University of Science and Technology. Medical Sciences = Hua Zhong Ke Ji Da Xue Xue Bao. Yi Xue Ying De Wen Ban = Huazhong Keji Daxue Xuebao. Yixue Yingdewen Ban*, 27(3), 339–342. <https://doi.org/10.1007/S11596-007-0332-6>