

## CLINICAL AND HISTOPATHOLOGIC EVALUATION OF THE EFFECT OF LASER PHOTOBIMODULATION AND EPICATECHIN IN THE TREATMENT OF RADIATION INDUCED ORAL MUCOSITIS IN RAT MODEL

Gasser M. Elewa\*, Hani Z. Abu El-Ezz\*\* and Mahmoud M. Aboufotouh\*\*\*

### ABSTRACT

**Aim:** This study aimed to determine the early-stage anticytotoxic effects of Ga–Al–As diode laser photobiomodulation (LPBM) and Epicatechin (green tea extract) (GT), either alone or combined, when used to treat induced oral mucositis (OM) in rats.

**Subjects & Methods:** Thirty Wistar rats were included; two of them were sacrificed in the beginning (normal mucosa control). Radiotherapy OM was induced by a fractionated course of oral radiotherapy at a rate of 2 Gy/min bilaterally twice weekly for two weeks. On day 6, four animals were sacrificed to confirm OM induction. The remaining animals (24 rats) were equally assigned into four groups: Control group (CG), Laser group (LG), green tea extract group (GG) and combined group (L+G). They continued for 5 successive days in the 3-test groups. Animal sacrifice has then occurred on day 11. The mucositis degree (MD) was clinically evaluated, the histopathological assessment of tissue changes was applied using (H&E) and Monoclonal cytochrome-c antibody.

**Results:** All treated animals showed a statistically significant difference ( $P$ -value  $\leq 0.05$ ) than those in CG. The lased animals had a better clinical outcome with a faster healing than GT. The best clinical outcome and healing pattern were shown in (L+G).

**Conclusion:** Ga–Al–As diode laser and Epicatechin produced protection against radiotherapy induced OM through their antioxidant and anti-apoptotic activity effects. Better outcomes were noted in favor of LPBM over GT.

**KEY WORDS:** Oral mucositis, Laser photobiomodulation (LPBM), Epicatechin, Apoptosis.

\* PhD in LASER applications in Dentistry, Oral Medicine, Diagnosis and Periodontology Department, Faculty of Oral and Dental Medicine, Delta University of Science and Technology, Gamasa, Egypt.

\*\* PhD Oral Medicine and Periodontology, Oral Medicine, Diagnosis and Periodontology Department, Faculty of Oral and Dental Medicine, Delta University of Science and Technology, Gamasa, Egypt.

\*\*\* PhD Oral Biology, Oral Biology Department, Faculty of Oral and Dental Medicine, Delta University of Science and Technology, Gamasa, Egypt.

## INTRODUCTION

Radiotherapy has become increasingly important for the treatment of head and neck squamous cell carcinoma<sup>(1, 2)</sup>. Radiation-induced oral mucositis (OM) develops because radiation therapy can interfere with the maturity and cellular growth of epithelial cells, causing changes to normal turnover and cell death. Irradiated epithelial, endothelial, and connective tissue cells in the buccal mucosa release free radicals, modified proteins, and pro-inflammatory cytokines, including interleukin-1B, prostaglandins, and tumor necrosis factor<sup>(2)</sup>. OM associated with both radiation and chemotherapy, is a very common, painful, and dose-limiting toxicity, with an incidence that can be as high as 90%<sup>(3)</sup>. Radiation-induced OM may be accompanied by altered taste, pain, dry mouth, decreased appetite, and decreased nutritional uptake<sup>(3-5)</sup>.

Moreover, this treatment leads to other complications such as; a breakdown in the saliva barrier, a disruption of epithelial cells with thinning of epithelium, and even ulceration. Delays in drug administration and increased medical costs are also considered, additionally, it may be a life-threatening condition due to septicemia<sup>(5)</sup>. It was found that damage occurs to the epithelium of the oropharyngeal cavity and gastrointestinal tract (GIT) as a result of radiation and/or chemotherapy. In most instances, epithelial cells of the mucous membranes have a more rapid turnover than those cancer being treated and are vulnerable to damage by cytotoxic agents and radiation<sup>(6)</sup>.

Unfortunately, the standard therapy for OM is predominantly palliative with few interventions that may reduce its severity or duration. Many strategies have been used such as; basic oral care, oral rinses, analgesics, antibiotics, cryotherapy, local anesthetics, growth factors and cytokines, biologic mucosal protectants, and anti-inflammatory agents<sup>(5-8)</sup>, with no proven therapeutic approach to prevent OM occurrence or severity<sup>(7)</sup>. Some

studies have reported beneficial effects of low-intensity laser therapy (LILT) to promote tissue repair, reduce pain and inflammation<sup>(9-11)</sup>. It was reported as a well-tolerated, safe and effective modality to manage OM related complications<sup>(12)</sup> owing to its anti-inflammatory<sup>(13)</sup> and antioxidant capabilities<sup>(14)</sup>. Furthermore, it has the ability to accelerate healing process through activating mitochondrial-ATP production, the local release of growth factors<sup>(15, 16)</sup>, increased proliferation of fibroblasts<sup>(17, 18)</sup>, improving extracellular matrix production, macrophage stimulation or activation of collagen production<sup>(19)</sup>.

Tea, which is made from the leaves of the plant *Camellia sinensis*, is the most popular beverage worldwide besides water; it is rich in antioxidant polyphenolic flavonoids<sup>(20)</sup>. Epigallocatechin Gallate (Epicatechin), a green tea polyphenol, possesses potent antioxidant, anti-apoptotic, anti-inflammatory, and autoantigen-inhibitory properties<sup>(21)</sup>. Until now, OM represented a significant medical problem in oncology settings, with no universally accepted treatment protocols<sup>(22)</sup>. Therefore, this experiment aimed, to clinically and histopathologically evaluate the effects of combining LPBM and GT on treating the radiotherapy induced-OM in rat model, compared to the sole use of each therapeutic line.

## MATERIALS AND METHODS

### Animal model

Thirty, 12-week-old, with a mean weight 200 g, male Wistar Albino rats (W. rats) were maintained in the central animal laboratory (Delta University of Science and Technology, Gamasa, Egypt) for at least 1 week. The animals were housed in small groups of three animals per cage and allowed free access to water and food. The temperature was maintained at 21±1°C and lights were turned on from 8:00 AM to 8:00 PM.

This research was carried out in line with the Helsinki Declaration, the study was approved by the Committee for Ethics in Animal Experiments, Delta University of Science and Technology, Gamasa, Egypt.

### OM-induction protocol

The W. rats were sedated using an intraperitoneal (IP) injection of 3.125 mg/kg tiletamine, 3.125 mg/kg zolazepam, and 11.5 mg/kg xylazine hydrochloride. The rats were placed and restrained in the prone position on an acrylic plate. Radiation was restricted to the oral cavity to spare the rest of the body<sup>(23)</sup>. A 30 Gy dose was delivered twice weekly for two weeks (the total dose of radiation = 120 Gy/animal) at a rate of 2 Gy/min bilaterally with a distance of 100 cm from the source to the axis using the LINAC, 6MV (21EX; Varian). Tissue-equivalent material was placed on the irradiated regions to ensure a uniform distribution of the prescribed dose.

### Animal grouping

Two rats were sacrificed before the beginning of the experiment (normal mucosa control). On day 6, after the 2 weeks period of OM induction; 4 rats were sacrificed before the beginning of treatment to histopathologically evaluate any tissue changes. The remaining animals (n= 24) were randomly and equally (n=6 animals/group) assigned into the study groups as following:

- I- Control group (CG): Animals that were not given any treatment and were used as a spontaneous healing control model.
- II- Laser group (LG): Animals that underwent LPBM irradiation.
- III- Green tea extract group (GG): Animals assigned for GT application.
- IV- Combined group (L+G): Animals that had both LPBM irradiation then GT application.

### Laser set up

Animals in Groups II and IV were subjected to LPBM daily for five successive days. Extra-oral irradiation was applied using Ga–Al–As diode, semiconductor laser (Soft Laser SL–202, 870 nm PETROLASER, RUSSIA), in continuous wave mode (CW) with special probe of spot size = 0.55 cm<sup>2</sup> and power (P) = 25 mW (Figure 1), in direct contact to the skin of the cheeks for 60 seconds. The surface area of the probe was enough to cover approximately half the cheek area of the rat, so two applications for each side were enough to cover the target area with total energy density (ED) = 5.4 J/cm<sup>2</sup>.<sup>(24)</sup>



Fig. (1): Laser device showing the used parameters.

### Green tea application

A solution of GT-extract (20 mg/kg) was administered orally two times daily (total 40 mg/kg/day) by intra-oral intubation<sup>(25)</sup>. For all groups and before any procedure, animals were anaesthetized then; each line of treatment was applied from day 6 up to day 10. All the animals were sacrificed on day 11 then, excisional mucosal biopsies were carefully collected to include the adjacent healthy mucosa and the healed tissue in depth, for further histopathological and immunohistochemical examination. During the clinical investigation, the mucosal changes were evaluated and scored, as well as the animal weighting.

### Clinical assessment of OM in rats

The clinical aspect of the oral mucosa was observed by two blind-independent calibrated observers and the degree of mucositis (DM) was evaluated through OM assessment scale (OMAS)<sup>(26)</sup> as follows: 0—no ulceration and no erythema; 1—ulceration < 4mm<sup>2</sup> and slight erythema; 2—ulceration of 4–9 mm<sup>2</sup> and moderate erythema; 3—ulceration > 9 mm<sup>2</sup> and severe erythema; 4—appearance of pseudomembrane. OM scores were recorded daily starting from day 1 to provide an overview of the mucositis development.

### Histopathology

Histological analysis was performed on specimens from the buccal mucosa to verify the influence of treatment options on the course of mucositis, for the assessment of healing events. Buccal mucosae were harvested, and then cut into horizontal sections perpendicular to the long axis of the cheek pouch and fixed in 10% neutralized buffered formalin. Tissue Samples embedded in paraffin blocks and cut into 4 µm thick sections. Serial sections were stained with hematoxylin and eosin (H&E).

### Immunohistochemical analysis

Sections of 4 µm thickness were mounted on electrically positive charged slides and deparaffinized by overnight incubation with xylene then rehydrated in a gradual descending concentration of ethanol followed by PBS wash. Blocking the endogenous peroxidase activity was performed by 3% hydrogen peroxide (H<sub>2</sub>O<sub>2</sub>) for 5 minutes at room temperature. For antigen retrieval, tissue sections were put in glass jars containing 0.01M sodium citrate buffer (pH 6.0) and boiled in a microwave oven twice for 5 minutes each to enhance immunoreactivity (reserve the loss of antigenicity that occurred with some epitopes of formalin-fixed paraffin-embedded tissues). The slides were allowed to cool and rinsed with phosphate-buffered saline (PBS), pH 7.2. The immunohistochemical staining

for monoclonal cytochrome-c antibody was done according to the manufacturer's instructions using the primary antibody Cytochrome (Thermo scientific Clone 7H8.2C12 cat# MS-1192-R7).

Detection was carried out using the universal kit (DAKO, Denmark) by washing slides in PBS for 5 minutes and incubated with secondary antibody that was biotinylated goat serum conjugated rabbit and mouse sera for 30 minutes. Sections were then washed for 5 minutes in PBS followed by development of antigen-antibody visualization by diaminobenzidine [DAB] in PBS containing 40% hydrogen peroxide. Sections were washed under running tap water for 10 minutes, then counterstained with Mayer's haematoxylin and mounted.

### Histomorphometric analysis

Monoclonal cytochrome-c antibody was used in staining cytochrome-c protein inside apoptotic cells as it provides an effective and specific means for detecting cytochrome-c translocation from mitochondria into cytosol during apoptosis. The kit provides unique formulations of reagents to isolate a highly enriched mitochondria fraction from cytosol. The procedure is so simple and easy to perform, no ultra-centrifugation is required and no toxic chemicals are involved.

The stain appeared punctuate and faint in normal cells according to its mitochondrial distribution but appeared brownish diffuse cytoplasmic color in the cells going in apoptotic pathway, and quantitative imaging-based score<sup>(27)</sup> was performed as following; negative staining: less than 5%+ve cells / 10 HPF, mild staining: from 5-15 % +ve cells / 10 HPF, moderate staining: from 16-30 % +ve cell / 10 HPF, strong staining: more than 30% +ve cell / 10 HPF. The area percent of cytochrome-c immunopositive cells was assessed using image-j software.

### Statistical Analysis

Statistical analysis was performed with SPSS 16.0® (Statistical Package for Scientific Studies)

for Windows. Data were presented as means and standard deviation (SD) values. Kruskal-Wallis test was used to compare between the groups. MannWhitney U test was used in the procedure of pairwise comparisons between the groups. Friedman's test was used to study the changes by time in each group. Wilcoxon signed-rank test was used in the procedure of pair-wise comparisons.

The significance level was set at  $P \leq 0.05$ .

## RESULTS

### 1. Mucositis degree (MD)

There was no statistically significant difference in the mean of MD among the four groups from day 1 up to day 7 (score 2.5). Whereas, on days 8, 9, 10 and 11, CG showed the statistically significant highest mean score, with no statistically significant difference among the three test groups. It is noteworthy that L+G group showed the lowest mean score (Figure 2).

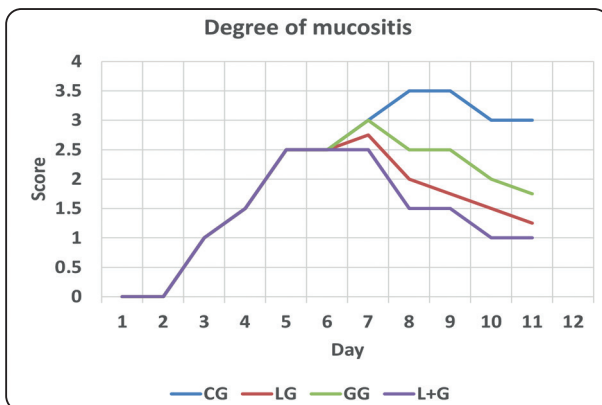


Fig. (2): The degree of OM among the four groups.

### 2. Hematoxylin / eosin (H&E)

The mucosa before treatment was shown in Figure 3-A. The epithelium was markedly thinner with hydropic degeneration of basal cell layer and detachment of surface keratinized layer. In addition, patches of fibrin exudation over the epithelium was observed and the sub-epithelial tissue showed dilated

congested blood vessels, infiltration of lymphocytes, PNLs and macrophages with fragmentation of sub-epithelial collagen fibers.

In CG, the specimens showed evidence of severe mucositis in the form of considerable epithelial destruction and the connective tissue showed extensive collagen degeneration, dilated engorged capillaries and extensive inflammatory infiltrate (Figure 3-B1). Moreover, some views revealed evidence of healing in the form of more cellular connective tissue, moderate angiogenesis and moderate mixed inflammatory infiltrate (Figure 3-B2).

Figure 3-C represented the mucosa of GG in which; the epithelium showed prominent basal cell layer with focal regeneration of the epithelium up to keratinized layer. Sub-epithelial tissue showed cellular granulation tissue formation in the form of numerous thin walled blood vessels, fibroblasts and haphazardly arranged collagen fibers admixed with mild to moderate mixed inflammatory cell infiltrate. (Figure 3-D) displayed histopathological analysis of LG mucosa with regeneration of the full epithelial thickness, the sub-epithelial tissue showed organization of granulation tissue with mild mixed inflammatory cell infiltrate and excessive angiogenesis. The mucosal changes of the combined group were represented in Figure 3-E. A complete reconstruction of the epithelium up to surface keratinized layer was shown, with more organization and maturation of sub-epithelial granulation tissue in the form of obliteration of most blood vessels, parallelism of collagen fibers and depletion of fibroblasts with scanty mixed inflammatory infiltrate.

### 3. Immunohistochemical results

In Figure 4-A sections, cytochrome-c antibody was shown before treatment, with a strong expression in the destroyed and sloughed epithelium (Figure 4-A1) and mild expression in the sub-epithelial

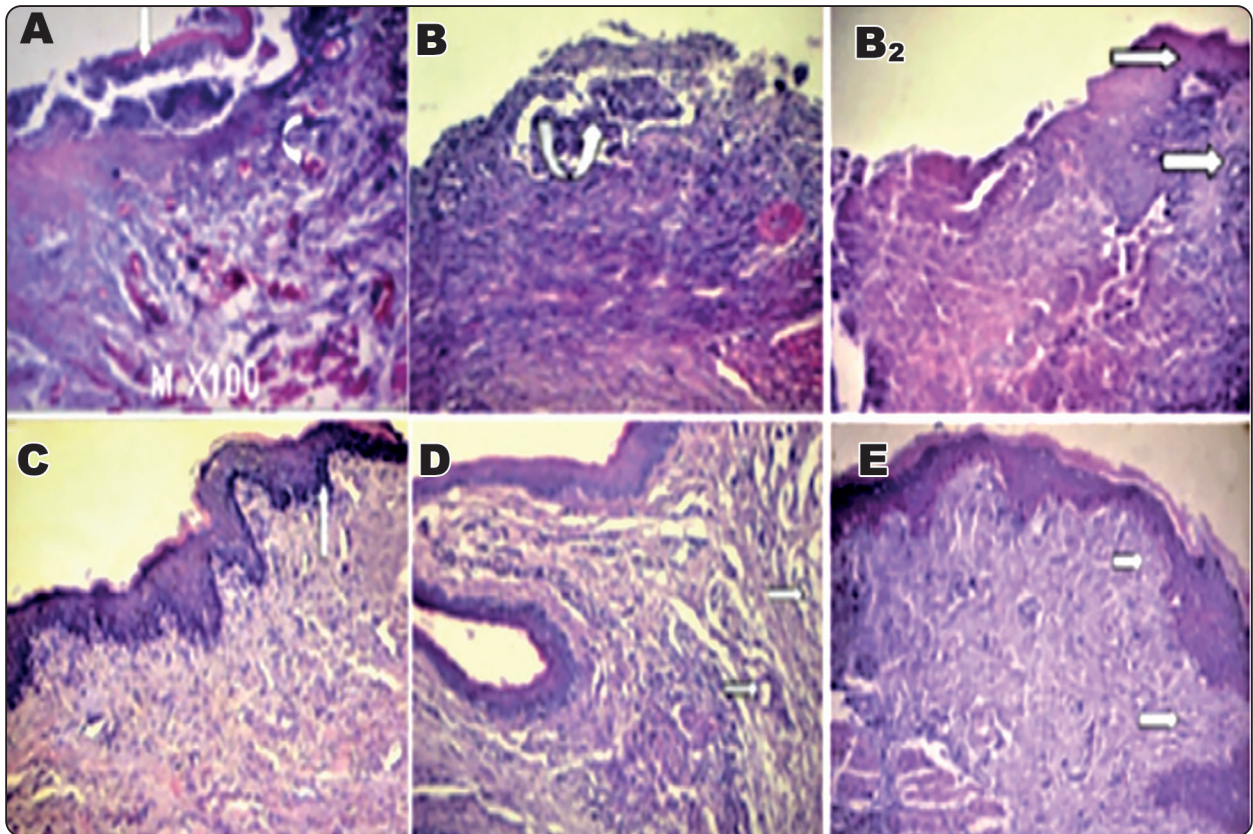


Fig. (3): Photomicrograph of W. rat buccal pouch mucosa. (A) Mucosa before treatment with detachment of surface keratinized layer, patches of fibrin exudation over the epithelium (arrow) and the sub-epithelial tissue showed dilated congested blood vessels (arrow), infiltration of lymphocytes, PNLs and macrophages with fragmentation of sub-epithelial collagen fibers (M x100 H&E). (B) CG showing areas of intense inflammatory infiltrate and considerable epithelial destruction (arrow). (B2) showing focal epithelial regeneration and sub-epithelial cellular immature granulation tissue (arrow) (M X 40 H&E). (C) GG mucosa showing prominent basal cell layer (arrow) and cellular granulation tissue (M x100 H&E). (D) LG mucosa showing granulation tissue with marked angiogenesis (arrow) (M x100 H&E). (E) (L+G) mucosa showing parallelism of collagen fibers (arrow) with scanty mixed inflammatory infiltrate (M x100 H&E).

inflammatory tissue (Figure 4-A2). Furthermore, the immunostained mucosal sections of CG showed strong expression in the sub-epithelial inflammatory collections (Figure 4-B1), while other sections showed moderate cytochrome-c staining in the endothelium and developing granulation tissue, in addition to remnants of inflammatory cells (Figure 4-B2).

The immunostained mucosa of GG was shown in Figure 4-C. The cytochrome-c expression was moderate in epithelial cells and mild in sub-epithelial granulation tissue. Whereas, Figure 4-D display the immunostained mucosal sections

of LG with cytochrome-c expression in the sub-epithelial fibroblasts (Figure 5-D1) and capillary endothelium (Figure 4-D2). The immunostained mucosa of (L+G) group was revealed in Figure 4-E showing mild cytochrome-c expression in epithelial and negative to mild in sub-epithelial mature granulation tissue.

#### 4. Histomorphometric results

Figure 5 revealed the mean value and SD of apoptotic cells in the five studied groups. There was no statistically significant difference between the samples before treatment and CG; both showed

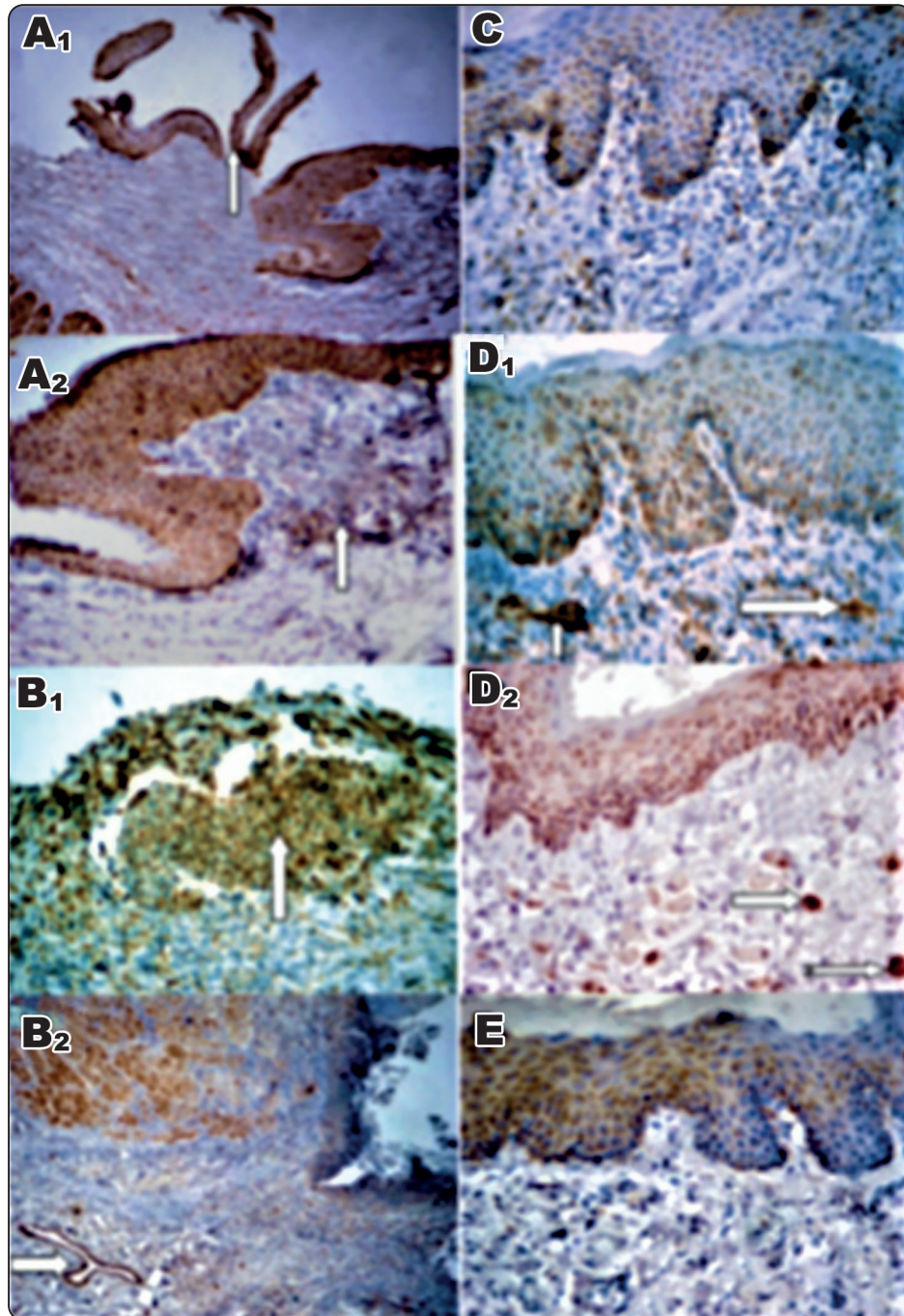


Fig. (4): Photomicrograph of W. rat buccal pouch mucosa immunostained by cytochrome-c antibody. (A1) mucosa before treatment with strong expression in detached surface keratinized layer (arrow) (A2) showing mild expression in the sub-epithelial inflammatory tissue (arrow) (M x 40). (B1) CG showing strong expression in the sub-epithelial inflammatory collections (arrow), (B2) showing moderate cytochrome -c staining in the endothelium and fibroblast of granulation tissue (arrow) (M X 40). (C) GG immunostained mucosa showing moderate staining in epithelial cells and mild in sub-epithelial granulation tissue (M x 200). (D) LG immunostained section showing cytochrome-c expression mainly in the sub-epithelial fibroblasts (D1), (arrow) and capillary endothelium of granulation tissue (D2), (arrow) (M x100). (E) (L+G) immunostained section showing mild cytochrome-c expression in epithelial and negative to mild in sub-epithelial mature granulation tissue (M x200).

the statistically significant highest mean values. In LG, a statistically significant lower mean value was recorded compared to GG, while the statistically significant lowest mean value was found with (L+G) group.

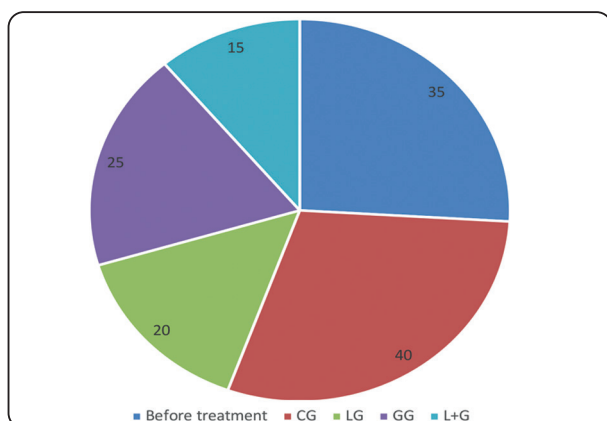


Fig. (5): Image analysis of mucosal samples before treatment, CG, LG, GG, and (L+G).

## DISCUSSION

OM is one of the major side effects of ionizing radiation toxicities and normal tissue injuries that result from radiotherapy<sup>(5)</sup>. This ensuing tissue injury additionally acts as a challenge for radiation oncologists since it leads to cancer therapy interruption and poor tumor control, as well. OM can therefore impair the quality of life of cancer patients.

The pathophysiology of radiation induced OM is not fully understood. Many studies proposed that the pathogenesis of this problem is composed of four stages: an initial inflammatory/vascular stage, an epithelial tissue stage, an ulcerative/bacteriological stage, and the last stage of healing<sup>(29)</sup>.

In this study, the W. rat buccal-pouch model of induced OM was used to determine either LPBM or GT treatment, or their combined use; can affect the clinical or pathological hallmarks of the disease. In this regard, W.rats are commonly used because they present some advantages in relation to other animals,

e.g. the low cost, easy manipulation, maintenance in controlled environmental and sanitary conditions including special diets. Besides, the similarity between the oral mucosa of W.rats and humans.<sup>(29)</sup>

Thirty animals were included in this trial; this sample size was suitable for displaying valid results as reported by similar studies.<sup>(30, 31)</sup> Male animals were selected to avoid the systemic impact of the female sex hormones on the final results.<sup>(32)</sup> Each animal received radiation with a total dose of 120 Gy. This dose of radiation was recommended by Nakajima et al<sup>(33)</sup> due to the high radiation tolerance at the rat oral mucosa. They reported that; in human, oral mucositis is usually created at a total amount of 40 Gy radiation, however, rats need about 2 to 3 times of this radiation dose for creating oral mucositis. In addition, Jordan et al<sup>(34)</sup> concluded that the induced radiation oral mucositis is a dose dependent process, as the severity of the oral mucositis is directly proportional to the total amount of radiation.

Green tea extract was also chosen owing to its well proven antioxidant, anti-apoptotic, and anti-inflammatory properties.<sup>(20)</sup> Near infrared (Ga-Al-As) diode laser (870 nm) was used in this study at extra-oral points for its greater power of penetration which is more effective in treatment of OM injuries, compared to the red spectrum.<sup>(35)</sup> The target area was covered with total ED of 5.4 J/cm<sup>2</sup> that was used based on the recommendations of similar trials using energy densities ranging from 2 to 8 J/cm<sup>2</sup><sup>(35, 36)</sup>

Results of the current study revealed clinically that there was no statistically significant difference among the four groups up to day 7, that revealed the highest MD score, which was in agreement with similar studies.<sup>(37)</sup> The mean MD score did not exceed 3 in the three therapeutic groups, in contrast to CG with the mean MD score reaching 3.5 on days 8 and 9, reflecting the positive role of the therapeutic agents in managing the condition. Although there



was a trend toward less MD score in LG and (L+G) groups, as compared to GG from day 8 up to day 11, but the difference was non-significant.

In the present study, Epicatechin treatment significantly improved the clinical features and histologic findings caused by irradiation. The clinical improvement in GG was supported by similar studies which concluded that GT possesses potent antioxidant property and can protect the mucosa against oxidative stress and prevent damage to cells.<sup>(24)</sup> Research suggests that GT may help to diminish risks associated with conventional therapeutics such as; high-dose chemotherapy and radiation by supporting mucosal integrity, immune competence through its anti-angiogenic properties; thus, reducing the availability of chemotherapeutic agents to the oral mucosa.<sup>(38)</sup> Moreover, our results indicated that treatment with soft laser irradiation was effective in reducing the severity of OM which was in agreement with similar studies.<sup>(39)</sup>

More favorable clinical points were reflected in favor of LPBM, which may be related to the fact that; epithelial cells become more motile with LPBM and are able to migrate across wound sites with accelerated closure of defects. Leucocytic infiltration, and neovascularization are also seen in LPBM irradiated wounds. Because of the overall impact of these influences, the time required for complete healing is reduced, which is of great importance in compromised patients, like diabetics, and patients undergoing treatment for malignancies.<sup>(40)</sup>

Fortunately, our results showed that the best clinical outcome was revealed with the adjunctive use of LPBM and GT. To date, there is no single treatment capable of preventing or treating mucositis in an efficient way.<sup>(38)</sup>

Histopathologically, it was found that OM become evident in the pre-treatment group by appearance of inflammatory criteria, vascular and epithelial phases as well as ulcerative phase with pseudomembrane

formation. While in CG, criteria of mucositis were shown in addition to healing stage by formation of sub-epithelial immature granulation tissue with regeneration of some epithelial layers. While, in both GG and LG, there were regeneration of the full epithelial thickness, reduction of inflammatory infiltrate, granulation tissue formation with excess angiogenesis especially in LG, in agreement with similar studies.<sup>(41, 42)</sup>

LPBM seems to be a simple and non-traumatic technique for prevention and treatment of OM from different etiologies; having the ability to delay its onset, decrease its duration and peak of severity.<sup>(43)</sup> On their combined use, a scanty inflammatory reaction with more mature and less cellular collagenous granulation tissue were shown. Furthermore, better improvements of the inflammatory process with a more pronounced healing in shorter duration were revealed. These results may be attributed to the great role of LPBM in the induction of cytokines and growth factors known to be involved in many phases of wound healing.<sup>(44)</sup> Green tea possesses an antioxidant action and anti-angiogenic properties in addition to its beneficial contents including; carotenoids, tocopherols, vitamin C, vitamin E, minerals such as Cr, Mn, Zn, and certain phytochemical compounds, which can decrease the severity of OM.<sup>(45)</sup>

In this current study, the role of apoptosis was investigated in the different stages of chemotherapy induced OM including; inflammatory, ulcerative and healing stages. In all the study groups, immunohistochemical analysis of cytochrome-c immunostained sections was used as an indicator of apoptotic cells, to detect effects of the therapeutic agents on apoptosis. Cytochrome-c is a monoclonal antibody protein located in the space between inner and outer mitochondrial membranes. It has been studied extensively, not only for its role in electron transport, but also in apoptosis. Cytochrome-c is released from the mitochondria in response to

specific apoptotic stimuli via Bcl-2 family-regulated mechanisms.<sup>(46)</sup> In pre-treatment group, the staining of cytochrome-c antibody was more evident in destructed surface keratinocytes, as its cytoplasmic expression was strong in the epithelium and mild in the sub-epithelial inflammatory cells. This is explained by early pro-apoptotic and cytotoxic effect of chemotherapeutic agent leading to epithelial injury and destruction with removal of destructed epithelial cells by apoptotic pathway. Our data were in agreement with Kane et al.<sup>(47)</sup>, who proved the role of apoptosis during inflammation at the leading edge of the epithelium by exploring the role of apoptosis-related markers. Whereas, in CG immunostained mucosal sections, the cytochrome-c expression was more evident in the sub-epithelial inflammatory collection. While, in other views, staining became more evident in fibroblasts and capillary endothelium of early cellular granulation tissue.

This is explained by the role of apoptosis in elimination of inflammatory cells to start healing process and also in elimination of fibroblasts and unwanted capillary with progression of healing. This was supported by findings of Brown et al., who observed that apoptosis was detected early in the inflammatory cells.<sup>(48)</sup> Moreover, the samples of GG revealed that cytochrome-c expression was moderate in epithelial cells and mild in sub-epithelial granulation tissue, which may be attributed to effect of GT in inducing epithelial cells protection. It reduces apoptosis in intestinal and oral mucosa, as well. It is an important precursor for antioxidants which by itself has antiapoptotic properties under conditions of oxidative stress.<sup>(37, 45)</sup>

The advantage of green tea application as a radiation mitigator for OM is its chemo-preventive properties and its well-proven safety. Meanwhile, Epicatechin has different target molecules which might explain the site-specific differences of anti-cancer effects found in human studies.<sup>(49)</sup> For

clinical application of any agent as a radiation mitigator, absolute certainty about the protection factors for tumor and normal tissues is compulsory to avoid unpredictable disease progression or complications. Epicatechin is a dietary component of green tea which has been ingested by humans for a long time, the ingredients should be therefore safe and non-toxic. The molecular mechanisms related to the chemo-preventive properties of green tea component are known to be appreciated to the modulating cell signaling pathways such as NF- $\kappa$ B, or MAPK kinases.<sup>(50)</sup> By regulating signaling pathways, polyphenols could promote cell death and induce apoptosis in premalignant or malignant cells, consequently leading to the inhibition of cancer development or progression.

The least cytochrome-c expression was observed in LG and (L+G) groups. In LG, the staining was moderate in the sub-epithelial fibroblasts and capillary endothelium while in (L+G) group, mild staining was shown in epithelial and negative to mild in sub-epithelial mature granulation tissues. This finding may be due to the presence of more mature granulation tissue which reach remodeling stage with less inflammatory reaction and complete epithelial reconstruction. These findings may be attributed to the anti-inflammatory effect of LPBM in addition to, its role in accelerating the proliferation and maturation (remodeling) stages of healing and inducing the apoptotic pathway to eliminate unwanted capillaries and fibroblasts.<sup>(51)</sup> This leads to stopping proliferation and beginning of final remodeling stage, in which mature acellular avascular granulation tissue is formed with decreased apoptosis as mentioned. This note was parallel to the findings of Desmouliere et al.,<sup>(52)</sup> who investigated the direct role of apoptosis in the gradual evolution of granulation tissue to scar tissue, in a consecutive fashion, after wound closure.

## CONCLUSION

Within the limits of this study, it was found that; either LPBM or Epicatechin significantly reduced both the duration and severity of radiation-induced OM. LPBM showed a more favorable clinical and healing outcomes when compared to Epicatechin.

Nevertheless, the remarkable clinical and biological improvement were demonstrated up on their combined use in terms of; the reduction of OM scores, the organized and mature quality of tissue samples which reflected the minimal apoptotic changes.

## REFERENCES

- Sankaranarayanan R, Masuyer E, Swaminathan R, Ferlay J, Whelan S. Head and neck cancer: a global perspective on epidemiology and prognosis. *Anticancer Res* 1998; 18: P. 4779–4786.
- Sousa O, Lopes N, Alves M, Caran E. Effects of Glycine on Collagen, PDGF, and EGF Expression in Model of Oral Mucositis. *Nutrients* 2018; 10: p 1-11.
- Epstein JB, Gorsky M, Guglietta A, Le N, Sonis ST. The correlation between epidermal growth factor levels in saliva and the severity of oral mucositis during oropharyngeal radiation therapy. *Cancer Res* 2000; 89: P. 2258–2265.
- Westgaard K, Hynne H, Amdal C, Young A, Singh P, Chen X, et al. Oral and ocular late effects in head and neck cancer patients treated with radiotherapy. *Sci Rep* 2021; 11: P 1-11.
- Muanza TM, Cotrim AP, McAuliffe M, Sowers AL, Baum BJ, Cook JA, et al. Evaluation of radiation-induced oral mucositis by optical coherence tomography. *Clin Cancer Res* 2005; 11(14):5121–7.
- Van den Wyngaert T. Topical honey application to reduce radiation-induced oral mucositis: a therapy too sweet to ignore? *J Evid Based Dent Pract* 2012; 12(4):203–5.
- Rubenstein EB, Peterson DE, Schubert M. Clinical practice guidelines for the prevention and treatment of cancer therapy-I induced oral and gastrointestinal mucositis. *Am. Cancer Soc* 2004;100:2026–2046.
- Pereira DA, Mendes PGJ, de Souza Santos S, de Rezende Barbosa GL, Pessoa RSE, de Oliveira GJPL. Effect of the association of infra-red and red wavelength photobiomodulation therapy on the healing of post-extraction sockets of third lower molars: a split-mouth randomized clinical trial. *Lasers Med Sci* 2022; doi: 10.1007/s10103-022-03511-5. Online ahead of print.
- Bardellini E, Veneri F, Amadori F, Conti G, Majorana A. Photobiomodulation therapy for the management of recurrent aphthous stomatitis in children: clinical effectiveness and parental satisfaction. *Med Oral Patol Oral y Cir Bucal* 2020; 25:e549–e553.
- Nunes EC, Herkrath FJ, Suzuki EH, Gualberto Junior EC, Marques AAF, Sponchiado Junior EC. Comparison of the effect of photobiomodulation therapy and Ibuprofen on postoperative pain after endodontic treatment: randomized, controlled, clinical study. *Lasers Med Sci* 2020; 35(4), 971-978.
- Redman MG, Harris K, Phillips BS. Low-level laser therapy for oral mucositis in children with cancer. *Arch Dis Child* 2022;107(2):128-133.
- Pereira ESBM, Basting RT, Abdalla HB, Garcez AS, Napimoga MH, Clemente-Napimoga JT. Photobiomodulation inhibits inflammation in the temporomandibular joint of rats. *J Photochem Photobiol B: Biol* 2021; 222(128):112281.
- Lu Y, Wang R, Dong Y, Tucker D, Zhao N, Ahmed ME, et al. Low-level laser therapy for beta amyloid toxicity in rat hippocampus. *Neurobiol Aging* 2017; 49, 165–182.
- Klausner G, Troussier I, Canova CH, Bensadoun RJ. Clinical use of photobiomodulation as a supportive care during radiation therapy. *Support Care Cancer* 2022; 30, 13–19.
- Serrage HJ, Cooper PR, Palin WM, Horstman P, Hadis M, Milward MR. Photobiomodulation of oral fibroblasts stimulated with periodontal pathogens. *Lasers Med Sci* 2021;36(9):1957-1969.
- Sterczala B, Grzech-Leśniak K, Michel O, Trzeciakowski W, Dominiak M, Jurczynszyn K. Assessment of Human Gingival Fibroblast Proliferation after Laser Stimulation In Vitro Using Different Laser Types and Wavelengths (1064, 980, 635, 450, and 405 nm)-Preliminary Report. *J Pers Med* 2021; 4:11(2):98.
- Carroll JD. Summary of Photobiomodulation Literature. *Photobiomodulation Photomed Laser Surg* 2021; 39(8): 499-501.

18. Keshri GK, Kumar G, Sharma M, Bora K, Kumar B, Gupta A. Photobiomodulation effects of pulsed-NIR laser (810 nm) and LED (808 ± 3 nm) with identical treatment regimen on burn wound healing: A quantitative label-free global proteomic approach. *J Photochem Photobiol* 2021; 6.
19. Astuti, S.D., Sulisty, A., Setiawati, E.M. et al. An in-vivo study of photobiomodulation using 403 nm and 649 nm diode lasers for molar tooth extraction wound healing in wistar rats. *Odontology* 2021. <https://doi.org/10.1007/s10266-021-00653-w>
20. Braicu C, Lodomery MR, Chedea VS, Irimie A, Berindan-Neagoe I. The relationship between the structure and biological actions of green tea catechins. *Food Chem* 2013; 141: 3282-3289.
21. Menegazzi M, Campagnari R, Bertoldi M, Crupi R, Paola R, Cuzzocrea S. Protective Effect of Epigallocatechin-3-Gallate (EGCG) in Diseases with Uncontrolled Immune Activation: Could Such a Scenario Be Helpful to Counteract COVID-19? *Int J Mol Sci* 2020; 21: P 1-19.
22. Vera-Llonch M, Oster G, Ford CM. Oral mucositis and outcomes of allogeneic hematopoietic stem-cell transplantation in patients with hematologic malignancies. *Support Care Cancer* 2007; 15 (5): 491–496.
23. Shin YS, Shin HA, Kang SU, Kim JH, Oh YT, Park KH, Kim CH Effect of Epicatechin against Radiation-Induced Oral Mucositis: In Vitro and In Vivo Study. *Research Article, DOI* 2013 10: P. 1371
24. Thieme S, Ribeiro JT, Dos Santos BG, de Almeida Zieger R, Severo MLB, Martins MAT, et al. Comparison of photobiomodulation using either an intraoral or an extraoral laser on oral mucositis induced by chemotherapy in rats. *Support Care Cancer* 2020;28(2):867-876.
25. Sultan AA, Ali AH, Kmal KA. Immunohistochemical study of the effect of green tea extract on methotrexate-induced oral mucositis in albino rats. *J Cytol Histol* 2014; 5: P. 3.
26. Wilder-Smith P, Hammer-Wilson MJ, Zhang J. In vivo imaging of oral mucositis in an animal model using optical coherence tomography and optical Doppler tomography. *Clin Cancer Res* 2007; 13: P. 2449–2454.
27. Rasband WS, ImageJ US (2009): National Institutes of Health, Bethesda, Maryland, USA.
28. Naidu MU, Ramana GV, Rani PU, Mohan IK, Suman A, Roy P. Chemotherapy-induced and/or radiation therapy-induced oral mucositis— complicating the treatment of cancer. *Neoplasia* 2004; 6(5):423–31.
29. Priprem A, Damrongrungruang T, Limsitthichaikoon S, Khampaenjiraroach B, Nukulkit C, Thappasaphong S, et al. Topical Niosome Gel Containing an Anthocyanin Complex: a Potential Oral Wound Healing in Rats. *AAPS PharmSciTech* 2018; 19: P 1681-1692.
30. Patel, A., Rajesh, S., Chandrashekhar, V. M., Rathnam, S., Shah, K., Mallikarjuna Rao, C., & Nandakumar, K. A rat model against chemotherapy plus radiation-induced oral mucositis. *Saudi pharmaceutical journal : SPJ : the official publication of the Saudi Pharmaceutical Society*, 2013; 21(4), 399–403. <https://doi.org/10.1016/j.jsps.2012.11.003>
31. Da Cruz Campos, M.I., Campos, C.N., Corrêa, J.A., Aarestrup, F.M., & Aarestrup, B.J. Induced oral mucositis in Wistar rats treated with different drugs: Preventive potential in cytokine production. *Molecular and Clinical Oncology*, 2021; 14, 127. <https://doi.org/10.3892/mco.2021.2289>
32. Saraswathy GR, Maheswari E, Santhrani T. Effect of vitamin C supplementation on phenytoin induced behavioral abnormalities and regional lipid peroxidation in rats. *International Journal of pharmacy and technology* 2011; 3(2): P. 2248-2269.
33. Nakajima, Masami & Inagi, Katsuhide & Hasumi, Keiko. Radiation-Induced Mucositis: An Animal Model. *Otolaryngology-head and Neck Surgery - OTOLARYNGOL HEAD NECK SURG.* 2004; 131. 10.1016/j.otohns.2004.06.371.
34. Jordan, Carolyn & Bradford, Emily & Cheek, Dennis & Kudrimoti, Mahesh & Miller, Craig & Smith, Molly & Hilt, J. & Dziubla, Thomas. Radiation-induced oral mucositis hamster model using a linear accelerator enhances clinical relevance of preclinical studies for treatment strategy investigation. *Animal Models and Experimental Medicine.* 2021; 4. 10.1002/ame2.12148.
35. Ather A, Anna AN, James CD, Wayne S, Amy JF, Wendy LB, et al. The Path to an Evidence-Based Treatment Protocol for Extraoral Photobiomodulation Therapy for the Prevention of Oral Mucositis. *Front Oral Health* 2021; 2: 689386
36. Al-Rudayni AHM, Gopinath D, Maharajan MK, Veettil SK, Menon RK. Efficacy of Photobiomodulation in the Treatment of Cancer Chemotherapy-Induced Oral

- Mucositis: A Meta-Analysis with Trial Sequential Analysis. *Int J Environ Res Public Health* 2021; 18: 7418.
37. Zadik Y, Arany PR, Fregnani ER, Bossi P, Antunes HS, Bensadoun RJ, et al. Systematic review of photobiomodulation for the management of oral mucositis in cancer patients and clinical practice guidelines. *Sup Care Cancer* 2019; 27:3969–83.
  38. Lopes NNF, Plapler H, Chavantes MC. Cyclooxygenase-2 and vascular endothelial growth factor expression in 5-fluorouracil-induced oral mucositis in hamster: Evaluation of two low intensity laser protocols. *Support Care Cancer* 2009; 17: P. 1409-1415.
  39. Thakur VS, Gupta K, Gupta S. The chemopreventive and chemotherapeutic potentials of tea polyphenols. *Curr Pharm Biotechnol* 2012; 13:P. 191-199.
  40. Legouté F, Bensadoun RJ, Seegers V, Pointreau Y, Caron D, Lang P, et al. Low-level laser therapy in treatment of chemoradiotherapy-induced mucositis in head and neck cancer: results of a randomised, triple blind, multicentre phase III trial. *Radiat Oncol* 2019; 22;14(1):83.
  41. Vinesh, E. and Jeyapriya, S. and Kumar, M. and Arunachalam, M., Photobiomodulation and oral wound healing. *Indian Journal of Multidisciplinary Dentistry*. 2017; 7(2):129-134.
  42. Thieme S, Ribeiro JT, Dos Santos BG, de Almeida Zieger R, Severo MLB, Martins MAT, Matté C, Martins MD. Comparison of photobiomodulation using either an intraoral or an extraoral laser on oral mucositis induced by chemotherapy in rats. *Support Care Cancer*. 2020 Feb;28(2):867-876.
  43. Hanna, R.; Dalvi, S.; Benedicenti, S.; Amaroli, A.; Sălăgean, T.; Pop, I.D.; Todea, D.; Bordea, I.R. Photobiomodulation Therapy in Oral Mucositis and Potentially Malignant Oral Lesions: A Therapy Towards the Future. *Cancers* 2020, 12, 1949.
  44. Ramos-Pinto MB, de Lima Gusmao TP, Schmidt-Filho J, Jaguar GC, Martins MD, et al. Intraoral versus extraoral photobiomodulation therapy in the prevention of oral mucositis in HSCT patients: a randomized, single-blind, controlled clinical trial. *Sup Care Cancer* 2021; 29(11):6495-6503.
  45. Cardoso LM, Pansani TN, Hebling J, de Souza Costa CA, Basso FG. Photobiomodulation of inflammatory-cytokine-related effects in a 3-D culture model with gingival fibroblasts. *Lasers Med Sci* 2020; 35(5):1205-1212.
  46. Yapar K, CavuÅŸoÅŸlu K, OruÅŸ E, YalÅŸin E . Protective effect of royal jelly and green tea extracts effect against cisplatin-induced nephrotoxicity in mice: a comparative study. *J Med Food* 2009; 12:P. 1136-1142.
  47. Lim MLR, Lum M-G, Hansen TM. On the release of cytochrome-c from mitochondria during cell death signaling. *J Biomed Sci* 2002; 9:P. 488–506.
  48. Kane CD, Greenhalgh DG. Expression and localization of p53 and bcl-2 in healing wounds in diabetic and nondiabetic mice. *Wound Rep Reg* 2000; 8:P. 45–58.
  49. Brown DL, Kao WW, Greenhalgh DG. Apoptosis down-regulates inflammation under the advancing epithelial wound edge: Delayed patterns in diabetes and improvement with topical growth factors. *Surgery* 1997; 121:P.372–380.
  50. Hayakawa S, Ohishi T, Miyoshi N, Oishi Y, Nakamura Y, Isemura M. Anti-Cancer Effects of Green Tea Epigallocatechin-3-Gallate and Coffee Chlorogenic Acid. *Molecules* 2020 5; 25(19): P. 4553.
  51. De Mejia EG, Ramirez-Mares MV, Puangraphant S. Bioactive components of tea: cancer, inflammation and behavior. *Brain Behav Immun* 2009; 23: P.721–731.
  52. Rocha AM, Vieira BJ, Ferreira de Andrade LC. Low-Level Laser Therapy Increases Transforming Growth Factor-2 Expression and Induces Apoptosis of Epithelial Cells During the Tissue Repair Process. *Photomed and Laser Surg* 2009; 27: P. 2.
  53. Desmouliere A, Redard M, Darby I. Apoptosis mediates the decrease in cellularity during the transition between granulation tissue and scar. *Am J Pathol* 1995; 146:P. 56–66.