

EVALUATION OF LINGUAL CONCAVITIES IN THE POSTERIOR MANDIBULAR AREA USING CONE BEAM COMPUTED TOMOGRAPHY SCANS IN AN EGYPTIAN POPULATION- A CROSS-SECTIONAL STUDY

Alaa Adel Nawwar* 

ABSTRACT

Objective: The objective of this study was to evaluate the prevalence and measure the depth of the mandibular lingual concavities, using Cone-Beam Computed Tomography (CBCT) scans. This was done in an attempt to avoid perforation of the lingual cortex during dental implant insertion.

Methodology: CBCT scans of 174 patients requiring dental implants were used in this study. The scans included 86 females and 88 males, with an age range of 20-60 years. On each scan, the depth of the mandibular lingual concavity was measured at the first and second molar areas. These measurements were then tabulated and statistically analyzed to compare the prevalence and depth of the lingual concavity at the first and second molar areas, on the right and left sides, in males and females, and in dentate and edentulous cases.

Results: There was a statistically significant difference between the mean depth of the mandibular lingual concavity in males and females, as it was higher in males (4.85mm) than females (4.09mm). The mean depth of the concavity was greater at the second molar than at the first molar in both males and females. The concavities were also found to be deeper on the left side of the mandible in both genders. Meanwhile, there was no statistically significant difference in concavity depth in dentulous and edentulous cases at the same areas, but the depths in the dentulous cases were greater.

Conclusion: In the examined Egyptian population, the concavity depth was greater in males than in females, and greater at the second molar area, on the left side of the mandible. Therefore, CBCT imaging is advised to provide accurate preoperative examination in dental implant cases to avoid complications as lingual perforations.

KEYWORDS: Cone beam computed tomography – mandibular concavity – dental implant – lingual perforation

* Lecturer Oral and Maxillofacial Radiology Department, Faculty of Dentistry, Cairo University, Cairo, Egypt

INTRODUCTION

For the past decade, endosseous dental implants have been an integral part of the treatment and replacement of missing teeth.⁽¹⁾ Implant placement is generally considered a minimally invasive procedure, given the thorough and comprehensive planning done beforehand.⁽²⁾ This is to avoid any complications that may occur during or after the procedure.⁽³⁾ Possible complications include damage of neighboring teeth, implant displacement, nerve damage and hemorrhage.^(4,5) In the mandible, hemorrhage occurs more often at the inter-foraminal region and in the posterior area because of the presence of lingual concavities in the bone.⁽⁶⁾ The compressive force caused by the submandibular salivary gland, as it grows, is the main cause of the posterior lingual concavity in the mandible.⁽⁷⁾ When those concavities are deep, the risk of lingual perforation is increased during implant insertion. This is because the implant may extrude outside the lingual bone and cause complications such as infection and inflammation.⁽³⁾

Radiographs are essential during implant planning, to assess the quality and quantity of bone at the implant site and the proximity to vital structures.⁽⁸⁾ Panoramic and periapical radiographs can be used but the information provided by them is not enough since they are two-dimensional techniques.⁽⁹⁾ These two-dimensional images do not help in the assessment of the mandibular lingual concavities of the mandible.⁽¹⁰⁾ Computed tomography (CT) provides 3-dimensional images and cross-sectional analysis of the maxillofacial facial structures.⁽¹¹⁾ CT scans are expensive and expose the patients to a very high radiation dose.⁽¹²⁾ This is not recommended, especially for younger patients because of the risk of cancer development and tissue damage.⁽¹³⁾ Cone beam computed tomography (CBCT), on the other hand, is the most cross-sectional modality used in the dental field.⁽¹⁴⁾ It provides images of the maxillofacial area with greater accuracy and reduced patient radiation exposure, when compared to conventional computed tomography.⁽¹⁵⁾ Cone beam computed to-

mography (CBCT) produces three-dimensional images which are multiplanar (sagittal, coronal, axial, and cross-sectional) reconstructions. These images provide accurate measurements in any plane.⁽¹⁶⁾ The American Academy of Oral and Maxillofacial Radiology encourage the use of CBCT for the preoperative implant planning.⁽¹⁷⁾ CBCT images provide accurate information about the bone morphology and surrounding structures and allow for interactive treatment planning.⁽¹⁸⁾ CBCT guided virtual implant planning enables the clinician to plan and visualize the final outcome before starting treatment.⁽¹⁹⁾

CBCT images help in the accurate visualization of the degree of the mandibular lingual concavities, which is crucial to avoid lingual perforation during implant placement.⁽²⁰⁾ This is achieved by the cross-sectional analysis provided by the CBCT software, which assesses the lingual undercuts in terms of linear and angular measurements.⁽²¹⁾

The aim of the current study was to evaluate lingual concavities in the posterior area of the mandible, in an Egyptian population, to avoid perforation of the lingual cortex during dental implant insertion. CBCT scans were used to assess the prevalence, and measure the depth, of those concavities in males and females, at the sites of the first and second molars, on the right and left sides of the mandible and in different dentate statuses.

MATERIALS AND METHODS

This is a retrospective study that included a total of 174 CBCT scans of Egyptian patients requiring dental implants. The scans were taken from the database at the Oral and Maxillofacial Radiology department at the Faculty of Dentistry, Cairo university. These CBCT scans included 88 males and 86 females, with an age range of 20-60 years (an average age of 40 years). The exclusion criteria were CBCT scans with any of the following; artifacts or low resolution, pathologic lesions, fractures or alveolar grafts in the posterior mandible. All the scans were taken using the CBCT scanner Planmeca

Promax® 3D Mid (Planmeca, Helsinki - Finland), and the exposure parameters were set to 90 kVp and 8 mA, with an exposure time of 13.5s and an isotropic voxel size of 0.4mm³.

The areas examined on each CBCT scan were the sites of the first and second molars, on the right and left sides of the mandible. For each CBCT scan, the following steps were carried out on the CBCT software to measure the lingual concavity.

- On the sagittal view, the lines of orientation were adjusted so that their intersection lies at the furcation area of the molar (in the dentulous cases) (figure 1) or just below the alveolar ridge in the center of the edentulous span of the missing molar (in the edentulous cases) (figure 2).
- On the axial view, the sagittal line of orientation was adjusted in the center of and parallel to the body of the mandible at the area of interest (figures 3 & 4).
- The previous two steps ensured that the resulting coronal view would be a true cross-sectional view of the area of interest.

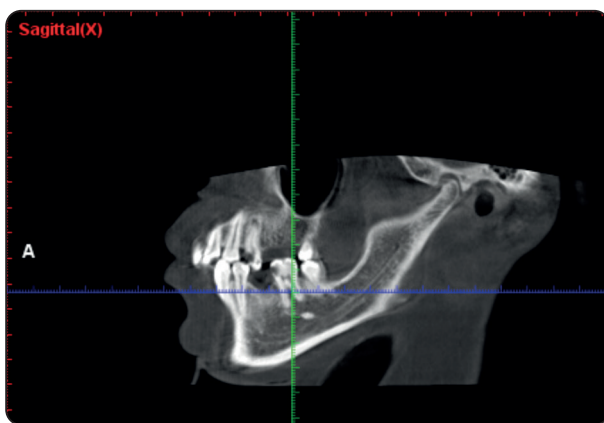


Fig. (1): The sagittal view of the CBCT scan, the lines of orientation oriented so that their intersection lies at the furcation area of the molar at the area of interest. This was done in all the dentulous cases.

- On the coronal view, the lines of orientation were used to aid in the lingual concavity depth measurement. The vertical line was oriented just adjacent to the most prominent lingual bony part, above the inferior alveolar canal. The horizontal line was oriented above the superior boundary of the inferior alveolar canal.
- The distance measured was along the horizontal line, between the vertical line and the outer surface of the mandibular lingual cortex. This was the measurement of the lingual mandibular concavity at that area (figures 5 & 6).

The above-mentioned steps were carried out to measure the mandibular lingual concavity at the areas of the first and second mandibular molars, on the right and left sides of the mandible for each CBCT scan, in the dentulous and edentulous cases. These measurements were taken by one Oral and Maxillofacial radiologist with 17 years of experience in the oral and maxillofacial radiology field. To assess intra-observer agreement, the measurements were taken twice with an interval of two weeks in-between.

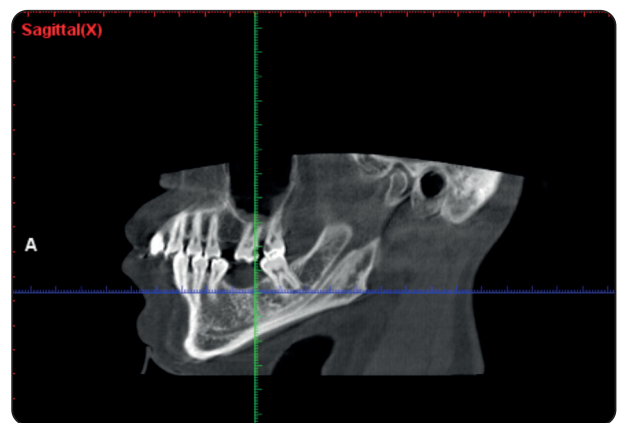


Fig. (2): The sagittal view of the CBCT scan, the lines of orientation oriented so that their intersection lies just below the alveolar ridge in the center of the edentulous span of the missing molar. This was done in all the edentulous cases.

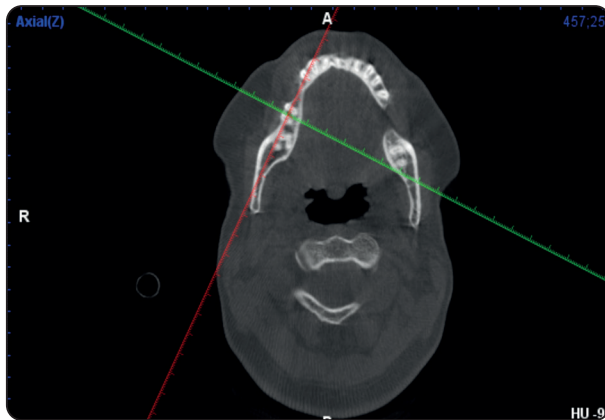


Fig. (3): The axial view, where the red sagittal plane is adjusted to be in the center of and parallel to the body of the mandible at the area of interest, in a dentulous case.

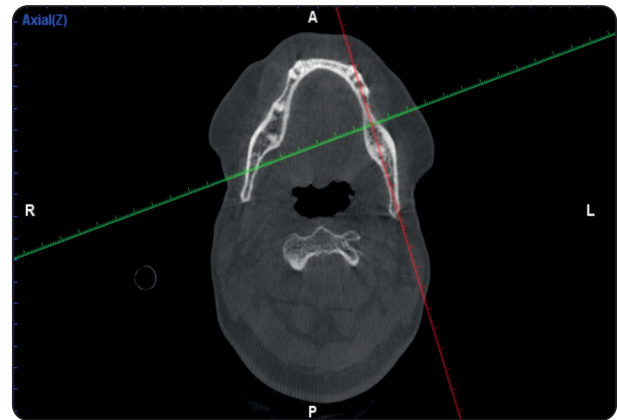


Fig. (4): The axial view, where the red sagittal plane is adjusted to be in the center of and parallel to the body of the mandible at the area of interest, in an edentulous case.

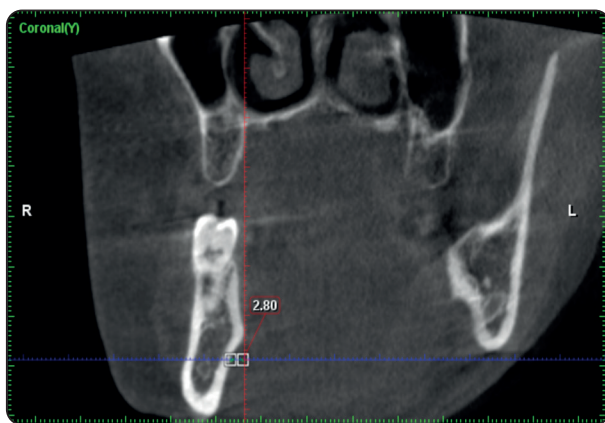

Fig. (5): The coronal view, where the depth of the concavity was measured along the horizontal line, between the vertical line and the outer surface of the mandibular lingual cortex, in a dentulous case.

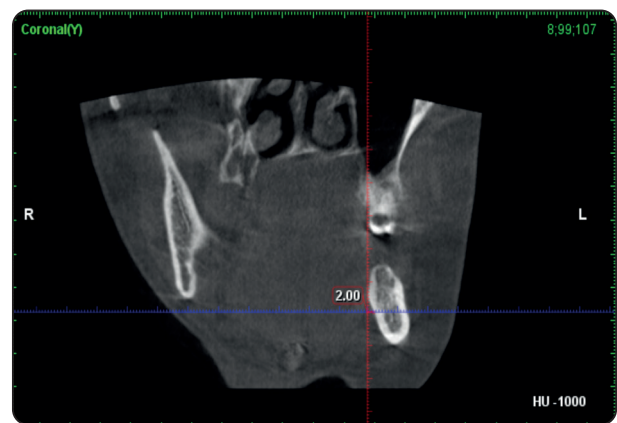


Fig. (6): The coronal view, where the depth of the concavity was measured along the horizontal line, between the vertical line and the outer surface of the mandibular lingual cortex, in an edentulous case.

Statistical analysis

The measured depths of the mandibular lingual concavities at the areas of the first and second mandibular molars, on the right and left sides of the mandible, for females and males, and dentulous and edentulous cases were tabulated and statistically analyzed. The mean and standard deviation values were calculated for each group in each test. Data were explored for normality using Kolmogorov-Smirnov and Shapiro-Wilk tests, data showed parametric (normal) distribution

Independent sample t-test was used to compare between two groups in non-related samples for

quantitative data. Paired sample t-test was used to compare between two groups in related samples for quantitative data. The significance level was set at $P \leq 0.05$. Statistical analysis was performed with IBM® SPSS® Statistics Version 20 for Windows.

RESULTS

The current study included 174 CBCT scans of patients, 88 were males (50.6%) and 86 were females (49.4%). The mandibular molars areas evaluated were 336 (50 %) first molars and 336 (50 %) second molars, yielding a total of 672 examined cross-sectional CBCT cuts. The molar

sites were as follows: 536 (79.8 %) dentulous and 136 (20.2 %) edentulous. 346 (51.5 %) of the molars were on the right side of the mandible and 326 (48.5 %) were on the left.

There was a statistically significant difference between the mean depth of the mandibular lingual concavity in males and females, in the area of the first and second molars, as it was higher in males (4.85mm) than females (4.09mm). (Table 1 & Figure 7)

TABLE (1) The mean, standard deviation (SD) values of depth of concavity of different groups: males and females.

Variables	Depth of concavity	
	Mean	SD
Males	4.85	2.25
Females	4.09	1.68
<i>p-value</i>	0.001*	

*; significant ($p < 0.05$)

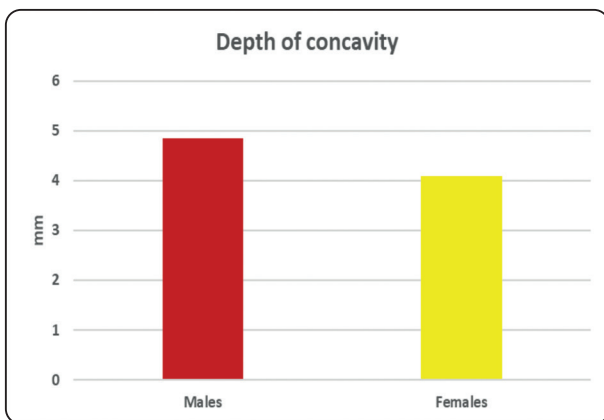


Fig. (7): Bar charts representing depth of concavity in males and females.

The mean depth of the concavity was greater at the second molar than at the first molar in both males and females. (Table 2 & Figure 8)

TABLE (2) The mean, standard deviation (SD) values of depth of concavity of different groups: first and second molars in males and females.

Variables	Depth of concavity				<i>p-value</i>
	Male		Females		
	Mean	SD	Mean	SD	
First molar	3.79	1.72	3.13	1.24	0.015*
Second molar	5.72	2.27	4.82	1.62	0.004*
<i>p-value</i>	<0.001*		<0.001*		

*; significant ($p < 0.05$)

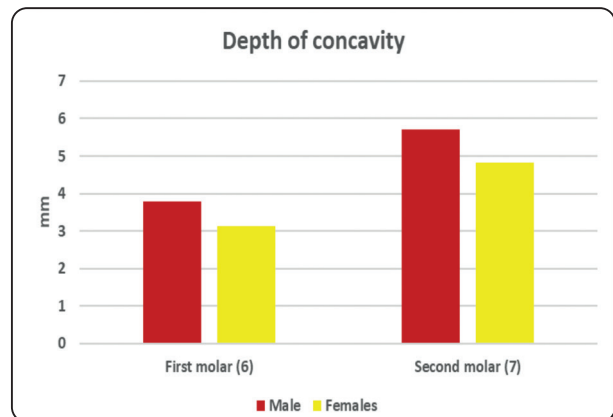


Fig. (8): Bar charts representing depth of concavity in the first and second molar areas, in males and females.

The concavities were also found to be deeper on the left side of the mandible, when compared to the right side, in both genders. (Table 3 & Figure 9)

Meanwhile, there was no statistically significant difference in concavity depth in dentulous and edentulous cases at the same areas, but the depths in the dentulous cases were greater. (Table 4 & Figure 10) Also, there was an excellent intra-observer agreement regarding the measurements of the mandibular concavity depths.

TABLE (3) The mean, standard deviation (SD) values of depth of concavity of different groups: right and left sides in males and females.

Variables	Depth of concavity				p-value
	Male		Females		
	Mean	SD	Mean	SD	
Right	4.42	2.27	3.87	1.47	0.045*
Left	5.52	2.26	4.45	1.82	0.003*
p-value	0.006*		0.033*		

*; significant (p<0.05)

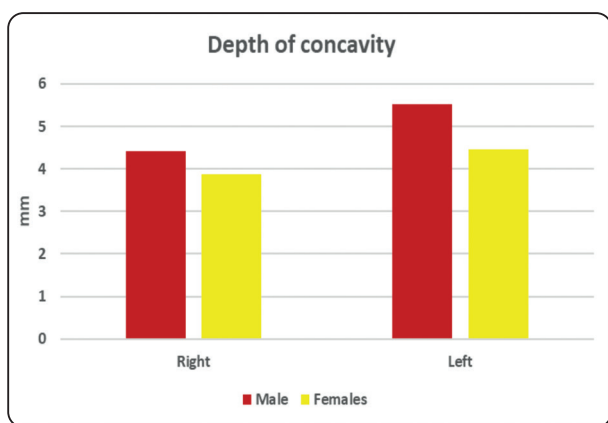


Fig. (9): Bar charts representing depth of concavity on the right and left sides in males and females.

TABLE (4): The mean, standard deviation (SD) values of depth of concavity of different groups: dentulous and edentulous cases

Variables	Depth of concavity	
	Mean	SD
Dentulous	4.57	2.07
Edentulous	4.09	1.82
p-value	0.107ns	

ns; non-significant (p>0.05)

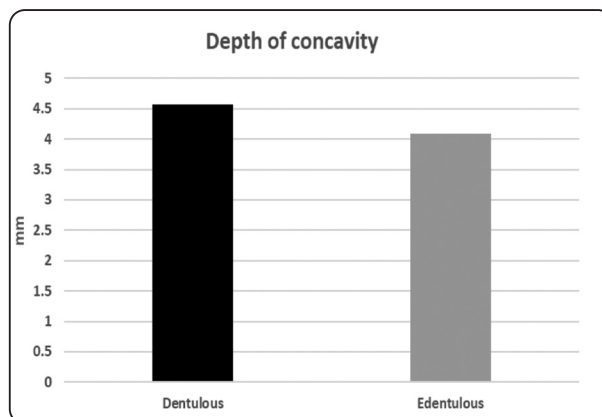


Fig. (10): Bar charts representing depth of concavity in dentulous and edentulous cases

DISCUSSION

Over the past decade, conventional radiographic imaging has shifted towards 3D imaging using CBCT.⁽²²⁾ CBCT is preferred in the dental field, over conventional computed tomography (CT), because of many advantages including the lower radiation dose to the patient, lower cost and superior resolution.^(11,15) CBCT is now recognized, by maxillofacial societies worldwide, as an important part of the preoperative examinations for dental implants.⁽²²⁾ Implant guided surgery helps in virtual planning preoperatively to avoid complications during implant insertion in areas with deep undercuts in the mandibular molar area.^(23, 24)

Improper implant placement may cause neurological complications, which are very common in the posterior mandibular area.^(25, 26) It has been reported that mandibular lingual concavities are great risk factors for lingual perforation.⁽¹⁹⁾ These posterior concavities result from the forces caused by the adjacent submandibular salivary gland, lying in the submandibular gland fossa.⁽⁷⁾

Accordingly, accurate evaluation of these concavities is crucial before implant placement.⁽¹⁹⁾ The presence of deep lingual concavities (more than 2mm), in different populations, supports the necessity of thorough examination of the potential implant site in the posterior mandibular area.⁽²⁷⁾

For that reason, this study has been carried out to evaluate lingual concavities in the posterior mandibular area, in an Egyptian population. This was done in an attempt to help dentists anticipate those concavities in different areas in the mandible, different genders and different dentate states, before dental implant placement.

174 patient CBCT scans were included in this study, 88 males and 86 females. The areas studied included 336 mandibular first molars and 336 mandibular second molars, yielding a total of 672 examined cross-sectional CBCT cuts. Some of the areas were dentulous areas (536) and the others were edentulous (536). The molar sites were 346 on the right side of the mandible and 326 were on the left. The depth of the mandibular lingual concavities was measured by means of the digital software on the CBCT scanner Planmeca Promax® 3D Mid. Cross-sectional cuts on the CBCT scans were used to measure the depth of those concavities in each specific site. This method of concavity depth measurement was in accordance to the method used by Salemi et al and Chan et al. ^(1,27)

The current study revealed that the mean depth of the mandibular lingual concavity in males was 4.85mm and 4.09mm in females. These findings were similar to those in a study by Nickenig et al., where the mean depth of the lingual concavities was 3.7 mm. ⁽²⁸⁾ This was also in agreement with studies carried out by Salemi et al, Quirynen et al, Parnia et al and Chan et al who reported a mean lingual concavity depth of over 2 mm. ^(1, 8, 11, 27)

In this study, there was a statistically significant difference between the mean depth of the mandibular lingual concavity in males and females, where it was greater in males. This was in contrast to studies carried out by Yoon et al. and Parnia et al, who concluded that there was no significant difference in the depth between both genders. ^(11, 29) On the other hand, the results of the current study were in agreement with the studies carried out by Tan et al and Rajput et al, who also reported deeper lingual concavities in males than in females. ^(30, 31)

Furthermore, the results of the present study revealed that the mean depth of the concavity was greater at the second molar than at the first molar in both males and females. These results were not in line with those obtained by Kamburoglu et al, which included that the highest prevalence of the mandibular concavity was at the first molar. ⁽³²⁾ However, this study's results were comparable to those reported by Rajput et al and Froum et al, who stated that the depth of the submandibular gland fossa was greater at the site of the second molar, than at the first molar ^(30, 33) These results were also confirmed by Tan et al, Lin et al and Nickenig et al. ^(28, 31, 34) Additionally, Huang et al, stated in their study that there was a significantly higher frequency of mandibular lingual concavity in the second molar area (62.7%) than at the first molar area (56.2%). This consequently puts the area of the second molar at a greater risk of lingual perforation during implant placement. ⁽¹⁹⁾ Moreover, Yu et al reported that in their study, the concavity was greater at the second molar in more than 90% of the cases. ⁽³⁵⁾ Didem Tözüm et al stated that, due to the greater concavity at the site of the second molar, replacing that tooth by a dental implant is more complicated when compared to the first molar and that bone grafting would probably be essential before implant placement. ⁽³⁶⁾

In the present study, the concavities were found to be deeper on the left side of the mandible, when compared to the right side, in both males and females. Tan et al suggested that this difference may be related to the different sizes of the submandibular glands on both sides of the mandible. ⁽³¹⁾

From the obtained results of the current study, there was no statistically significant difference in mandibular lingual concavity depth in dentulous and edentulous cases at the first and second molar areas, but the depths in the dentulous cases were greater. This was contrary to studies by Didem Tözüm et al and Nilsun et al who reported that the concavity depth was greater in edentulous second molar areas. ^(36, 37)

The different ethnicity of populations, the different points of reference in measurements, the dentate status and the pattern of bone are possible factors contributing to the differences in mean depths of the mandibular concavities in different studies.^(8,28)

LIMITATIONS

This is a retrospective study where the CBCT scans used were retrieved from a database. Consequently, there was some missing information that may have affected the conclusions and correlations of this study. This includes information like the time that had passed since extraction/loss of a tooth and factors affecting bone quality like metabolic disorders.

CONCLUSION

Accurate evaluation of the mandibular lingual concavity using cone beam computed tomography, prior to implant placement, is essential to avoid lingual cortex perforation at the sites of the mandibular first and second molars. In the examined Egyptian population, the concavity depth was greater in males than in females, and greater at the second molar area, on the left side of the mandible.

REFERENCES

- Chan HL, Brooks SL, Fu JH, Yeh CY, Rudek I, Wang HL. Cross-sectional analysis of the mandibular lingual concavity using cone beam computed tomography. *Clin Oral Implants Res.* 2011 Feb;22(2):201–6.
- Kalpidis CDR, Setayesh RM. Hemorrhaging Associated With Endosseous Implant Placement in the Anterior Mandible: A Review of the Literature. *J Periodontol.* 2004 May;75(5):631–45.
- Leong DJM, Chan HL, Yeh CY, Takarakis N, Fu JH, Wang HL. Risk of Lingual Plate Perforation During Implant Placement in the Posterior Mandible: A Human Cadaver Study. *Implant Dent.* 2011 Oct;20(5):360–3.
- Dubois L, de Lange J, Baas E, van Ingen J. Excessive bleeding in the floor of the mouth after endosseous implant placement: a report of two cases. *Int J Oral Maxillofac Surg.* 2010 Apr;39(4):412–5.
- Palma-Carrió C, Balaguer-Martínez J, Peñarrocha-Oltra D, Peñarrocha-Diago M. Irritative and sensory disturbances in oral implantology. Literature review. *Med Oral Patol Oral Cir Bucal.* 2011 Nov 1;16(7):e1043–6.
- Lamas Pelayo J, Peñarrocha Diago M, Martí Bowen E, Peñarrocha Diago M. Intraoperative complications during oral implantology. *Med Oral Patol Oral Cir Bucal.* 2008 Apr 1;13(4):E239–43.
- Philipsen HP, Takata T, Reichart PA, Sato S, Suei Y. Lingual and buccal mandibular bone depressions: a review based on 583 cases from a world-wide literature survey, including 69 new cases from Japan. *Dentomaxillofacial Radiology.* 2002 Sep;31(5):281–90.
- Quirynen M, Mraiwa N, van Steenberghe D, Jacobs R. Morphology and dimensions of the mandibular jaw bone in the interforaminal region in patients requiring implants in the distal areas. *Clin Oral Implants Res.* 2003 May;14(3):280–5.
- Chen LC, Lundgren T, Hallström H, Cherel F. Comparison of different methods of assessing alveolar ridge dimensions prior to dental implant placement. *J Periodontol.* 2008 Mar;79(3):401–5.
- Bodart L, Hanken H, Smeets R, Gosau M, Li C, Kluwe L, et al. Assessing the frequency of deep lingual concavities in 826 posterior mandible sockets. *Journal of Cranio-Maxillofacial Surgery.* 2020 Nov 1;48(11):1045–51.
- Parnia F, Fard EM, Mahboub F, Hafezeqoran A, Gavvani FE. Tomographic volume evaluation of submandibular fossa in patients requiring dental implants. *Oral Surgery, Oral Medicine, Oral Pathology, Oral Radiology and Endodontology.* 2010 Jan 1;109(1).
- Brenner DJ, Hall EJ. Computed tomography--an increasing source of radiation exposure. *N Engl J Med.* 2007 Nov 29;357(22):2277–84.
- Harris D, Horner K, Gröndahl K, Jacobs R, Helmrot E, Benic GI, et al. E.A.O. Guidelines for the use of diagnostic imaging in implant dentistry 2011. A consensus workshop organized by the European Association for Osseointegration at the Medical University of Warsaw. *Clin Oral Implants Res.* 2012 Nov;23(11):1243–53.
- Gupta J, Ali SP. Cone beam computed tomography in oral implants. *Natl J Maxillofac Surg.* 2013 Jan;4(1):2–6.

15. Suomalainen A, Vehmas T, Kortensniemi M, Robinson S, Peltola J. Accuracy of linear measurements using dental cone beam and conventional multislice computed tomography. *Dentomaxillofacial Radiology*. 2008 Jan; 37(1):10–7.
16. Scarfe WC, Farman AG, Sukovic P. Clinical applications of cone-beam computed tomography in dental practice. *J Can Dent Assoc*. 2006 Feb;72(1):75–80.
17. Tyndall DA, Price JB, Tetradis S, Ganz SD, Hildebolt C, Scarfe WC. Position statement of the American Academy of Oral and Maxillofacial Radiology on selection criteria for the use of radiology in dental implantology with emphasis on cone beam computed tomography. *Oral Surg Oral Med Oral Pathol Oral Radiol*. 2012 Jun;113(6): 817–26.
18. Horner K, O'Malley L, Taylor K, Glenny AM. Guidelines for clinical use of CBCT: a review. *Dentomaxillofacial Radiology*. 2015 Jan;44(1):20140225.
19. Huang RY, Cochran DL, Cheng WC, Lin MH, Fan WH, Sung CE, et al. Risk of lingual plate perforation for virtual immediate implant placement in the posterior mandible: A computer simulation study. *Journal of the American Dental Association*. 2015 Oct 1;146(10):735–42.
20. van Assche N, van Steenberghe D, Guerrero ME, Hirsch E, Schutyser F, Quirynen M, et al. Accuracy of implant placement based on pre-surgical planning of three-dimensional cone-beam images: a pilot study. *J Clin Periodontol*. 2007 Sep;34(9):816–21.
21. Kaeppeler G, Mast M. Indications for cone-beam computed tomography in the area of oral and maxillofacial surgery. *Int J Comput Dent*. 2012;15(4):271–86.
22. Jacobs R, Salmon B, Codari M, Hassan B, Bornstein MM. Cone beam computed tomography in implant dentistry: recommendations for clinical use. Available from: <https://doi.org/10.1186/s12903-018-0523-5>
23. Nickenig HJ, Eitner S. Reliability of implant placement after virtual planning of implant positions using cone beam CT data and surgical (guide) templates. *Journal of Cranio-Maxillofacial Surgery*. 2007 Jun;35(4–5):207–11.
24. Vinci R, Manacorda M, Abundo R, Lucchina AG, Scarano A, Crocetta C, et al. Clinical Medicine Accuracy of Edentulous Computer-Aided Implant Surgery as Compared to Virtual Planning: A Retrospective Multicenter Study. *J Clin Med [Internet]*. 2020;774. Available from: www.mdpi.com/journal/jcm
25. Abarca M, van Steenberghe D, Malevez C, de Ridder J, Jacobs R. Neurosensory disturbances after immediate loading of implants in the anterior mandible: an initial questionnaire approach followed by a psychophysical assessment.
26. Walton JN. Altered sensation associated with implants in the anterior mandible: A prospective study. *J Prosthet Dent*. 2000 Apr;83(4):443–9.
27. Salemi F, Shokri A, Forouzandeh M, Karami M, Khalili Z. Mandibular lingual concavity: A cross-sectional analysis using cone beam computed tomography. *Journal of Clinical and Diagnostic Research*. 2018 Oct 1;12(10):ZC37–41.
28. Nickenig HJ, Wichmann M, Eitner S, Zöller JE, Kreppel M. Lingual concavities in the mandible: A morphological study using cross-sectional analysis determined by CBCT. *Journal of Cranio-Maxillofacial Surgery*. 2015 Mar 1;43(2):254–9.
29. Yoon TYH, Patel M, Michaud RA, Manibo AM. Cone Beam Computerized Tomography Analysis of the Posterior and Anterior Mandibular Lingual Concavity for Dental Implant Patients. Available from: <http://meridian.allenpress.com/joi/article-pdf/43/1/12/2058189/aaidd-joi-d-16-00084.pdf>
30. Rajput BS, Mehta S, Parihar AS, Vyas T, Kaur P, Chansoria S. Assessment of lingual concavities in submandibular fossa region in patients requiring dental implants- A cone beam computed tomography study. *Journal of Contemporary Dental Practice*. 2018 Nov 1;19(11):1329–33.
31. Tan WY, Zhi J, Ng L, Ajit Bapat R, Chaubal TV, Kannepedy SK. Evaluation of anatomic variations of mandibular lingual concavities from cone beam computed tomography scans in a Malaysian population.
32. Kamburoğlu K, Acar B, Yüksel S, Paksoy CS. CBCT quantitative evaluation of mandibular lingual concavities in dental implant patients. *Surgical and Radiologic Anatomy*. 2015 Dec 1;37(10):1209–15.
33. Froum S, Casanova L, Byrne S, Cho SC. Risk Assessment Before Extraction for Immediate Implant Placement in the Posterior Mandible: A Computerized Tomographic Scan Study. *J Periodontol*. 2011 Mar; 82(3):395–402.
34. Lin MH, Mau LP, Cochran DL, Shieh YS, Huang PH, Huang RY. Risk assessment of inferior alveolar nerve injury for immediate implant placement in the posterior mandible: A virtual implant placement study. *J Dent*. 2014 Mar;42(3):263–70.

35. Yu DC, Friedland BD, Karimbux NY, Guze KA. Supramandibular Canal Portion Superior to the Fossa of the Submaxillary Gland: A Tomographic Evaluation of the Cross-Sectional Dimension in the Molar Region. *id_429 750..758*. 2012.
36. Didem Tözüm M, Tugba Ataman-Duruel E, Duruel O, Nares S, Tözüm TF. Association between ridge morphology and complexity of implant placement planning in the posterior mandible.
37. Nilsun B, Canan B, Evren H, Kaan O. Cone-Beam Computed Tomography Evaluation of the Submandibular Fossa in a Group of Dental Implant Patients. *Implant Dent*. 2019 Aug; 28(4):329–39.