

Therapeutic Effects of Strontium Ranelate and Risedronate on a Glucocorticoid-Induced Osteoporosis Rat Model: A Comparative Histological and Morphometric Study

Einas M. Yousef^{1,4}, Samar. M. Abd El-moneam², Basma S. A. Mansour² and Noha R. Noufal^{3,4}

Original
Article

¹Department of Histology and Cell Biology, Faculty of Medicine, Menoufia University, Egypt

²Department of Human Anatomy and Embryology, ³Department of Pathology, Faculty of Medicine, Suez Canal University, Egypt

⁴Department of Basic Medical Sciences, College of Medicine, Dar Al Uloom University

ABSTRACT

Introduction: Osteoporosis is the most prevalent bone disease in humans, affecting people of all ages but more common in postmenopausal women. Risedronate (RIS) and strontium ranelate (SR) are two clinically accessible anti-osteoporotic medicines.

Objectives: To assess and compare the anti-osteoporotic effects of RIS and SR on the histologic, histomorphometric, and ultrastructural features of compact bones in a rat model of glucocorticoid-induced osteoporosis.

Materials and Methods: 42 mature healthy male albino rats were randomly allocated into 6 main groups (7 rats /group) and received daily oral treatments for 12 weeks as following: negative control, RIS +ve control (2.5 mg/kg/day), SR +ve control (625 mg/kg/day), prednisolone (pred)-treated (1.5 mg/kg/day), pred + RIS (treated concurrently with prednisolone and RIS), and pred + SR (treated concurrently with prednisolone and SR). At the end of the experiment, all animals were anesthetized, sacrificed, and the femurs and tibias were excised for x-ray, histological, histomorphometric, and electron microscopic studies.

Results: Oral prednisolone provoked significant osteoporotic changes as evidenced by generalized osteopenia and bone bending detected in the X-ray. Histological examination demonstrated decreased cortical bone thickness, multiple irregular perforations, reduced lamellar bone formation, and an increase in the osteoid tissue. Ultrastructural changes were observed in the form of distorted osteoblasts and osteocytes together with lysis of collagen fibrils in the bone matrix. Oral administration of RIS and SR was associated with moderate and marked improvement of prednisolone induced perturbations of the bone architecture respectively.

Conclusion: Our data suggest that SR outperforms RIS in alleviating glucocorticoid-induced osteoporotic changes in cortical bone tissues.

Received: 02 October 2022, **Accepted:** 23 October 2022

Key Words: Glucocorticoid, osteoporosis, risedronate, strontium ranelate, ultrastructure.

Corresponding Author: Einas M. Yousef, PhD, Department of Histology and Cell Biology, Faculty of Medicine, Menoufia University, Egypt, **Tel.:** +20 12 2396 0645, **E-mail:** enasesawy@gmail.com

ISSN: 1110-0559, Vol. 46, No. 4

INTRODUCTION

Osteoporosis is a chronic illness that is caused by an imbalance between bone formation and resorption, resulting in a loss of bone integrity and an elevated risk of fracture^[1]. It affects anyone at any age, but it is more common in older people, particularly postmenopausal women. Recently, it has been estimated that more than 200 million individuals suffer from osteoporosis^[2]. Secondary osteoporosis, which accounts for 30%-60% of all instances of osteoporosis, can affect younger people as a result of underlying medical disorders or the use of particular medications^[3]. Glucocorticoid (GC)-induced osteoporosis is considered the most prevalent iatrogenic cause of secondary osteoporosis that is associated with significant therapeutic implications^[4].

Long-term GC therapy has a number of negative consequences on the body's metabolism, cardiovascular, dermatologic, and musculoskeletal systems^[5]. The most prevalent significant adverse effects linked with chronic GC therapy are fragility fractures, such as vertebral and hip fractures, induced by substantial loss of bone mineral density^[6]. It was reported that the annual incidence rate of vertebral fractures was 3.2% among patients treated with GC for prolonged time and 5.1% in subjects initiating GC therapy^[7]. GCs induce localized alterations in architecture of bone, resulting in micro-lesions that reduce bone strength. Because GCs not only limit bone formation but also accelerate bone resorption, the loss of bone density is highest during the first few months of treatment^[6,8]. Many clinical studies found that the prevalence of fractures

dropped about three months after GC treatment was stopped^[8].

Rapid advancements in our understanding of bone metabolism have prompted the development of a variety of anti-osteoporotic medications. Pharmacologic treatments of osteoporosis generally classified into anabolic and catabolic, which both work to substantially increase bone mass and decrease fractures^[9]. On the one hand, the anabolic group such as parathyroid hormones and monoclonal sclerostin antibodies acts by activating bone-synthesizing osteoblasts^[10]. On the other hand, the catabolic treatments such as bisphosphonates and selective estrogen receptor modulators (SERM) act mainly by inhibiting excessive bone resorption by osteoclasts^[11].

Risedronate (RIS), a nitrogen containing bisphosphonates, is known with its potent antiresorptive effect through suppressing the osteoclastic bone resorption. It has been shown to be an effective therapy for Paget disease of bone, postmenopausal and GC-induced osteoporosis^[12,13]. Many clinical and experimental studies have demonstrated that RIS increase bone mineral density, conserve of trabecular geometry, and structural strength in osteoporotic bones^[12,14-16]. There is still controversy concerning the benefits of bisphosphonates versus their long-term reported adverse effects, such as atypical femoral fractures and osteonecrosis. SR is another antiosteoporotic drug with dual mode of action on both bone formation and resorption^[17]. The antiresorptive and bone pro-forming actions of SR are achieved through increasing osteoblast differentiation, decreasing osteoclast formation, apoptosis of mature osteoclasts, and increasing synthesis of collagen and non-collagen proteins of the bone^[18]. Furthermore, SR likely influence bone volume and material composition^[19].

Recently, there has been a growing body of evidence indicating the beneficial anti-osteoporotic effects of RIS and SR. In the current study, our main objective was to assess and compare the anti-osteoporotic effects of RIS and SR on the histologic, histomorphometric, and ultrastructural features of compact bones in a rat model of GC-induced osteoporosis.

MATERIAL AND METHODS

Chemicals

The prednisolone tablets 5 mg (predilone, Alqahira Pharm. Company, Egypt), RIS tablets 5 mg (Actonel, Sanofi Aventis Pharm, Egypt), and SR sachets 2 g (protelos, Servier Egypt) were purchased before the beginning of the experiment. Both crushed tablets and the powder from sachets were dissolved in normal saline to form fresh suspensions that were administered orally by oral gavage.

Experimental animals

A total of forty two (42) male Albino Wistar rats weighing between (180-210 g), approximately three-month-old were used in the current experiment. They were obtained from the animal house of the Faculty of Veterinary

Medicine, Suez Canal University, Ismailia, Egypt. All rats were housed in a standardized cages in group of 3-4 per cage at room temperature. They were fed a standard laboratory pelleted food and water ad libitum. The animal house is well-ventilated with a 12 h light/dark cycle, throughout the experimental period. Animals were left to acclimatize to laboratory conditions for two weeks prior to the experiment. All animal procedures were carried out in accordance with the guidelines of the Ethics Committee of Faculty of Medicine, Suez Canal University, Egypt (IRB No. 4894).

Experimental design

After 7 days of habituation, the rats were randomly divided into six groups (No. = 7 rats/group) as following:

- Negative control group: rats received normal saline (the vehicle) via oral gavage.
- RIS +ve control: rats were treated with RIS (2.5 mg/kg/day, P.O. by oral gavage) for 12 weeks^[20].
- SR +ve control: rats were treated with SR (625 mg/kg/day, P.O. by oral gavage) for 12 weeks^[21].
- Prednisolone (Pred-treated) group: rats were treated with prednisolone (1.5 mg/kg/day, orally (P.O.) by oral gavage, daily) for 12 weeks to induce osteoporosis^[22].
- Pred + RIS group: rats were treated concurrently with prednisolone and RIS for 12 weeks.
- Pred + SR group: rats were treated concurrently with prednisolone and SR for 12 weeks.

All animals were weighed before the beginning of the experiment (day 0) and once weekly thereafter until the end of the 12 weeks. One day after receiving the final administrations of all medications, all animals were anesthetized by intraperitoneal injection of 60 mg/kg ketamine and 5 mg/kg xylazine and sacrificed by cervical dislocation.

Ethical Considerations

Our experiment was conducted after taking the permission of the Ethics Committee of Faculty of Medicine, Suez Canal University, Ismailia, Egypt. All experiments were carried out in accordance with the Good Laboratory Practice Regulations for the laboratory animal care. These regulations were as following: animals were maintained in a manner that assured their physical comfort, were handled gently and solely by the investigator, and were kept in a setting that was suitable to their physical and nutritional needs. Moreover, there was no interference except after complete anesthesia of the animal. In case any animal was observed to be experiencing severe, unbearable pain or discomfort, it was anesthetized and immediately was killed, using a method providing initial rapid unconsciousness (decapitation).

Bone X-ray

Immediately after euthanasia, the right femurs were carefully disarticulated, and the surrounding soft tissues were removed. Bones from all the groups were X-rayed from a distance of 30 cm, to obtain both anteroposterior (A/P) and lateral views (Armonicus, Forex Medical Zrt.).

Histological analysis

Long bones (left femurs) from rats of different groups were immediately labelled and fixed in 10% neutral buffered formalin for 48 hours. After bone decalcification with ethylenediaminetetraacetic acid (EDTA), the tissues were processed for preparation of Formalin-fixed, paraffin-embedded (FFPE) blocks. All blocks were sectioned (5µm thickness, longitudinal and transverse sections) and stained with hematoxylin and eosin (H&E) for general histological examination. Sections from each group were stained with Masson's trichrome to differentiate between osteoid and mineralized bone. Histological slides were imaged at 100, 200, 400X using bright-field microscopy on an Olympus BX-46 microscope equipped with an Olympus SC30 digital camera.

Histomorphometric analyses

Histomorphometric analysis was conducted using a computerized 2D image analysis software (Olympus CellSense Entry, version 510). The following parameters were analyzed in H&E stained slides from different experimental groups: cortical bone thickness, size of osteocytes (area and perimeter), and number of osteocytes. For each assessed parameter in histomorphometry, measurements were obtained from ten non-overlapping randomly selected fields in the slides from each rat. For each section, 15 readings were obtained. Meanwhile, other parameters including vascularity of the sections, loss of matrix homogeneity, Haversian system arrangement, and irregularity of periosteum have been evaluated by two independent histopathologist using conventional light microscopy.

Histological scoring of bone affection

Grading of bone affection was conducted according to the scoring protocol of Khalifa *et al.*, 2020 which was modified from that of Pritzker *et al.*^[23,24]. Using this scoring system, we compared each group to the control concerning the following parameters: reduced cortex thickness, vascularity of the sections, size and number of osteocytes, loss of matrix homogeneity, Haversian system arrangement, and irregularity of periosteum. A score from 0-3 was given for each section, where 0 means like normal, 1 means mild change, 2 means moderate change, and 3 means sever change. The total score (0-21) was calculated by averaging the mean score of each parameter. Scores from 0-4 was considered normal, 5-10 was considered as mild osteoporosis, 11-16 as moderate osteoporosis, and 17-21 as sever osteoporosis^[24].

Transmission Electron microscopic (TEM) studies

For TEM examination, small decalcified bone specimens Rt tibia (1 mm³) were fixed with standard fixative 2.5 % buffered glutaraldehyde (pH 7.2 - 7.4) at 4 °C for 2 h, followed by post fixation in 2% osmium tetroxide at 4 °C for 30 minutes. Specimens were dehydrated in serial dilutions of ethanol then immersed in acetone for one hour. The fixed specimens were then embedded in epoxy resin (Epoxy Embedding Medium Kit; Sigma). The capsules were cut on ultra microtome into semithin and ultra-thin sections. Semithin sections were stained with toluidine blue to light microscopic examination while ultra-thin sections were cut at 70 nm and stained with uranyl acetate as a principal stain and lead citrate as a counter stain^[25]. Finally, all the sections were observed at 160 kv using a JEOL JEM-2100 at EM unit, Mansoura University, Egypt.

Statistical analysis

Statistical analysis was performed using SPSS package version 22.0 (SPSS Inc., Chicago, IL, USA). All data was summarized using mean and standard deviation (SD). The difference between the mean values of the study groups was assessed using the ANOVA with post hoc Bonferroni test. A *p* value < 0.01 was considered statistically significant.

RESULTS

During the 12-week of the experiment period, there were no signs of morbidity or mortality recorded between rats with generally good conditions.

Body weight results

Except for pred-treated group, all experimental groups demonstrated significant increase in the body weight at the end of the experiments when compared to their initial weight (*p* < 0.01). Interestingly, pred-treated group showed significant reduction of the final body weight when compared to both the initial body weight and the control group (*p* < 0.01). Although the final body weight in the Pred + RIS and Pred + SR-treated groups was significantly higher from the initial body weight, it was significantly lower than that of the negative control. Of note, all groups showed significant increase (*p* < 0.01) in their final body weight compared to pred-treated rats (Table 1, Figure 1A).

X-ray results

As depicted in Figure 1B, control, RIS +ve control, and SR +ve control groups demonstrated normal bone architecture, density, alignment, and corticomedullary ratio. Administration of prednisolone was associated with generalized decrease in bone density (osteopenia), decreased cortico-medullary ratio, and abnormal bone modeling (bending). Both Pred + RIS and Pred + SR-treated rats showed relatively increased bone density with relatively normal cortico-medullary ratio. However, abnormal bending of bone were detected in Pred + RIS group.

Histological results

Hematoxylin and eosin (H&E)

Light microscopic examination of bone sections from negative control, RIS +ve control, and SR +ve control groups revealed characteristic morphological features of normal compact bone with well-developed cortical and trabecular bones. These sections demonstrated regular periosteum and endosteum, closely packed haversian system, large number of osteocytes in their lacunae, and homogenous matrix (Figure 2A-2C). However, we detected marked thickening of the periosteum of both RIS +ve control and SR +ve control groups (Figure 2B,2C).

Sections obtained from pred-treated rats showed separation of the periosteum from the surface of the bone and increased surface resorptive pitting. As the bone shows multiple irregular perforations, the number of osteocytes was markedly reduced, many empty lacunae were detected together with unrecognized or distorted haversian system in majority of the sections (Figure 2D). Of note, some sections of rats treated with prednisolone show fat infiltration of the bone marrow. On the other hand, our findings revealed that Pred + RIS and Pred + SR administration were associated with moderate and marked improvement of prednisolone induced perturbations of the bone architecture respectively, however some osteoporotic cavities were still detected. Furthermore, Haversian system were almost regularly arranged with wide haversian canal and increased blood vessels. Of note, bone sections of Pred + RIS-treated group showed non homogeneity as demonstrated with many areas with dark and light bone matrix (Figure 2E,2F).

Masson trichrome

We next used Masson trichrome histochemical staining to assess the amount of lamellar and immature bone in the studied experimental groups. In general, two reactions could be detected: a blue reaction that was primarily localized to immature bone tissue (osteoid tissue and collagen fiber), and a red reaction that was mainly associated with lamellar bone formation. In negative control, RIS +ve control, and SR +ve control groups, we detected marked increase in the lamellar bone as evidenced by increased red reaction (Figure 3A-C). A marked decrease in lamellar bone formation and increase in osteoid tissue were detected in sections obtained from Pred-treated group (Figure 3D). In rats treated with Pred+ RIS, a significant increase in lamellar bone formation (red reaction) was detected, however, the osteoid tissue and thick organized collagen fibers (blue reaction) were still prominent (Figure 3E). These findings indicates that RIS may have alleviated bone loss caused by prednisolone administration. Regarding Pred+ SR treated group, we detected marked increase in the lamellar bone formation which is demonstrated by the red reaction detected all over the stained sections (Figure 3F). Importantly, the lamellar bone pattern detected in Pred+ SR treated group was comparable to that of the negative control group. Taken together, our results indicated that both RIS and SR were able to mitigate the osteoporotic

effects of prednisolone on compact bone, however, SR overperforms RIS in its action.

Transmission Electron microscopic (TEM) results

Electron microscopic examination of a compact bone section from the negative control group displayed normal osteocytes within their lacunae in the collagenous bone matrix. The osteocytes have more or less normal nuclei and cell processes in the canaliculi (Figure 4A). In addition, normal osteoblastic cells rested between bone matrix and bone marrow were detected (Figure 4B). For both RIS +ve control and SR +ve control groups, electron microscopic study demonstrated most probably normal osteocytes (normal nucleus, homogenous cytoplasm, normal cytoplasmic processes) embedded in collagenous bone matrix (Figure 4C,4D).

Sections from pred-treated rats revealed distorted osteocytes within the lacunae with irregular or ruptured nuclei, massive rarefication of cytoplasm, disrupted rough endoplasmic reticulum, and complete lysis of mitochondrial cristae. Damaged cytoplasmic processes were detected in the canaliculi. Around the osteocytes, we detected an aberrant appearance of granular and fibril bone matrix, eosinophilic infiltration in between collagen bone matrix, as well as lysis of collagen fibrils situated between osteoblasts and bone matrix (Figure 5A). In the same group, some osteoblasts have mild dilated rough endoplasmic reticulum together with partial lysis of cristae of mitochondria. Osteoclast with disrupted ruffled border was also detected (Figure 5B).

Electron microscopic examination of tissue from rats treated with pred+RIS displayed more or less normal osteocytes within their lacunae surrounded by the bone matrix. As depicted in (Figure 5C), the osteocyte of Pred + RIS treated rats has slightly irregular nucleus, focal area of rarified cytoplasm, some cytoplasmic vacuoles can be observed and numerous well-defined cytoplasmic processes. Moreover, a granular appearance of bone matrix around the processes was detected. As regards of the Pred + SR treated group, it reveals most probably normal osteocyte resting in lacuna and embedded in bone matrix. The osteocyte has normal nucleus with detectable dilated perinuclear membrane, mitochondria, cytoplasm, rough endoplasmic reticulum, and well developed cytoplasmic processes embedded through canaliculi in bone matrix (Figure 5D).

Histomorphometric results

In comparison to negative control, RIS +ve control, SR +ve control, Pred + RIS, and Pred + SR groups demonstrated no statistically significant difference in any histomorphometric parameters (cortical thickness, osteocyte size (area and perimeter), and osteocyte number) was detected. In contrast, pred-treated rats showed a significant decrease in cortical bone thickness, osteocyte size (area), and osteocyte number when compared to all other experimental groups ($p \leq 0.0001$). Although RIS and

SR were able to restore both the cortical bone thickness and osteocyte number following prednisolone administration, no significant difference could be identified between osteocyte size (area and perimeter) of Pred + RIS and Pred + SR-treated groups when compared to pred-treated rats (Table 2).

Regarding the histological scoring of bone affection, RIS +ve control and SR +ve control showed non-significant difference of the calculated histological scores

when compared to negative control. Sections obtained from pred-treated rats showed a typical histological profile of osteoporosis with histological score indicating severe osteoporosis (18.14 ± 3.24). Rats treated with Pred + RIS and Pred + SR showed improvement of prednisolone-induced osteoporosis as evidenced by lower histological score = 11.57 ± 1.62 which indicates moderate osteoporosis and 9.29 ± 1.11 which indicates mild osteoporosis in both groups; respectively (Table 2).

Figure 1

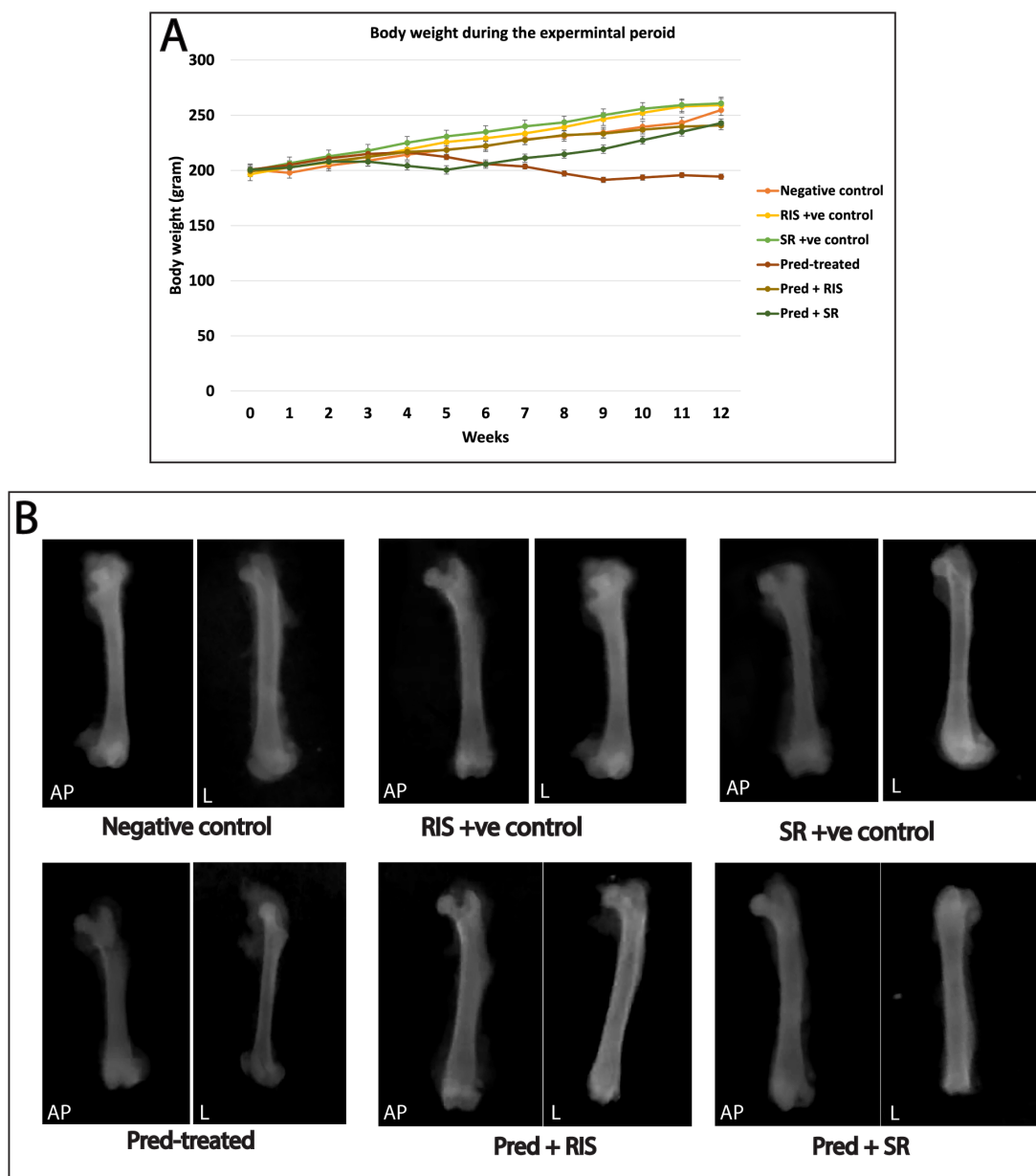


Fig. 1: A) Changes in the body weight of rats in different experimental groups. B) X-ray of right femur (antio-posterior and lateral views) from different experimental groups: negative control, RIS +ve control, and SR +ve control groups demonstrated normal bone architecture, density, alignment, and corticomedullary ratio. For pred-treated group, decreased bone density (osteopenia), fissure fracture together with bending, and decreased cortico-medullary ratio were detected. For both Pred + RIS and Pred + SR-treated groups, an increase in bone density with relatively normal cortico-medullary ratio was detected. AP: antio-posterior view, L: lateral view.

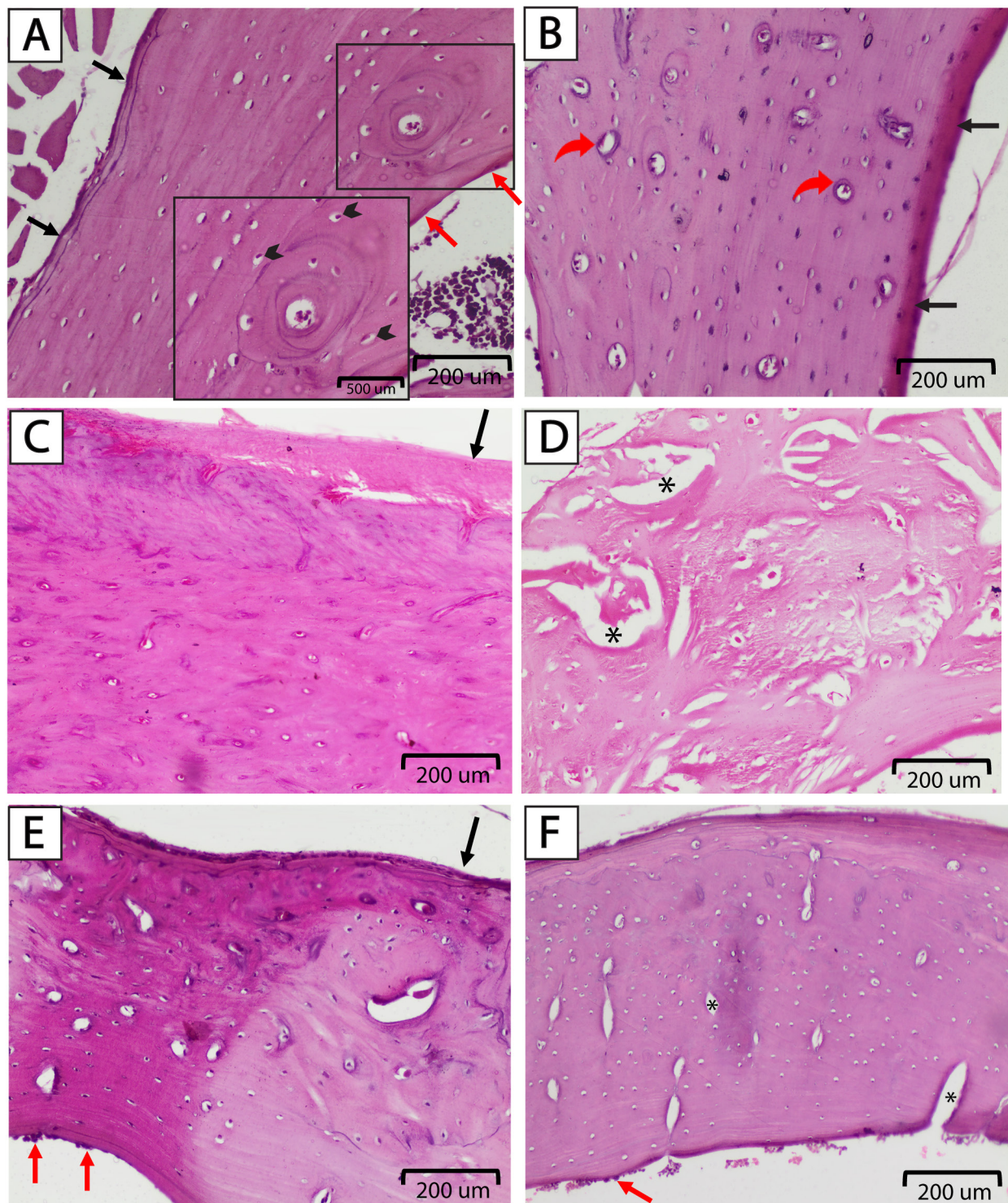


Fig. 2: Effect of RIS, and SR on prednisolone induced osteoporosis of the compact bone, stained with H&E (x200). (A) Negative control group: the bone density is normal, the periosteum (black arrow) and endosteum (red arrow) are regular, and average number of osteocytes (arrow heads). Inset in figure A showing osteon with central Haversian canal, concentric lamellae of bone matrix, and osteocytes in their lacunae (x400) (B) RIS +ve control group: the cortical bone showing average number of osteocytes inside their lacunae, the Haversian canal are well organized (red curved arrows), and the periosteum is regular and thickened (black arrows). (C) SR +ve control group: regular thickened periosteum (black arrows), normal bone density with average number of normally appearing osteocytes. (D) Pred-treated group: showed diminished cortical density, unrecognized or distorted Haversian system, many osteoporotic cavities are seen (black stars) with marked reduction of osteocytes. (E) Pred+RIS-treated group: section demonstrating heterogenous bone density, regular and intact periosteum (black arrow) and endosteum, osteoblasts (red arrows), average number of osteocytes and regular Haversian canals. (F) Pred + SR-treated group: diminished sized osteoporotic cavities (black stars), osteoblasts (red arrow), and regular and intact periosteum and endosteum.

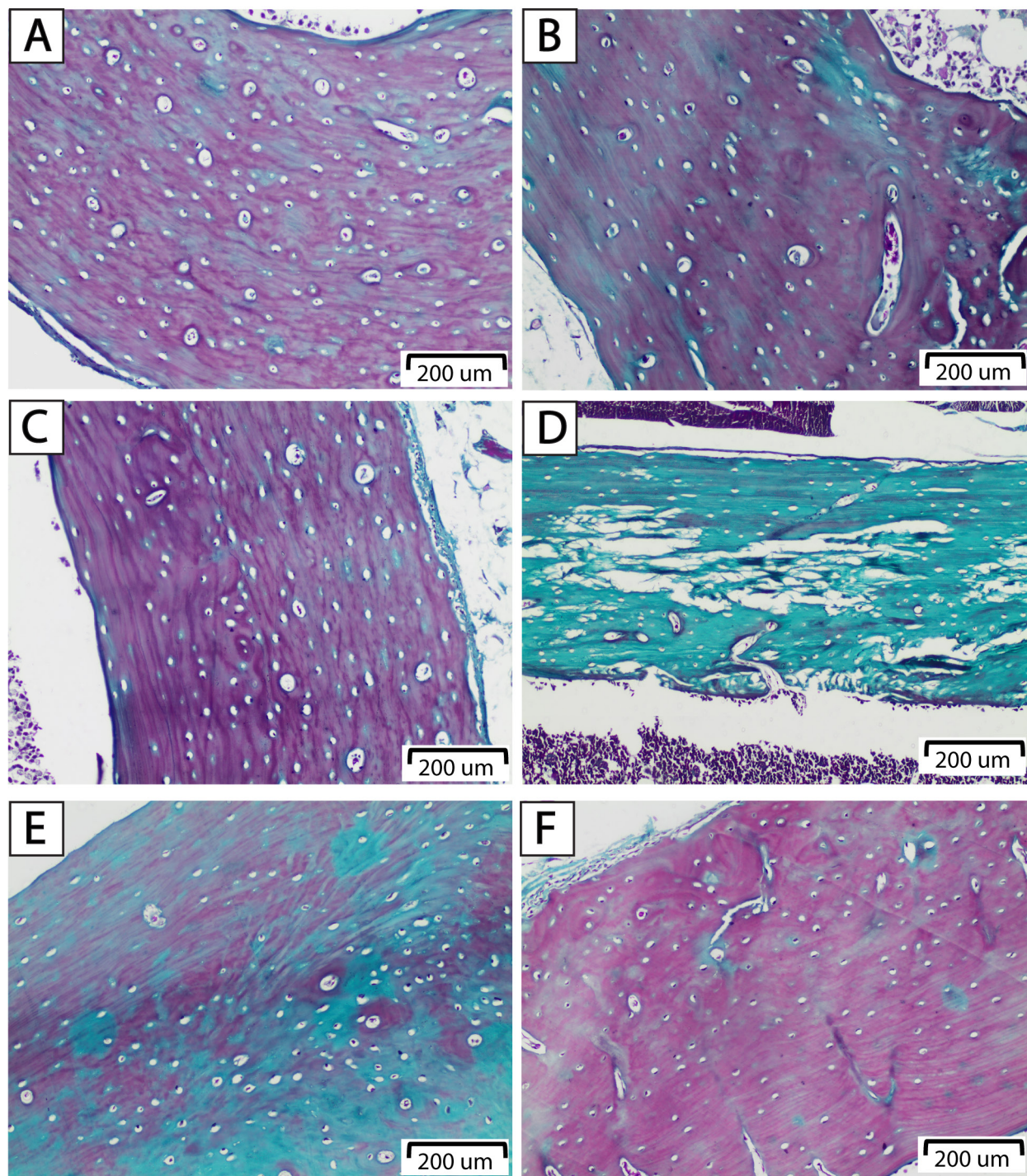


Fig. 3: Effect of risedronate, and strontium ranelate on prednisolone induced osteoporosis of the compact bone, stained with Masson Trichrome (x200). (A) Negative control group, (B) RIS +ve control, and (C) SR +ve control groups: showing normal accumulation of connective tissue (blue color), normally appearing osteocytes, and regularly arranged Haversian canal. (D) Pred-treated group: section is showing marked distribution of connective tissue (blue color) with absence of osteoid tissue (E) Pred + RIS-treated group: demonstrates moderate increase in lamellar bone formation together with moderate amount of connective tissue, (F) Pred + SR-treated group: section demonstrates bone remodeling with restoration of lamellar bone and diminished amount of C.T (blue color).

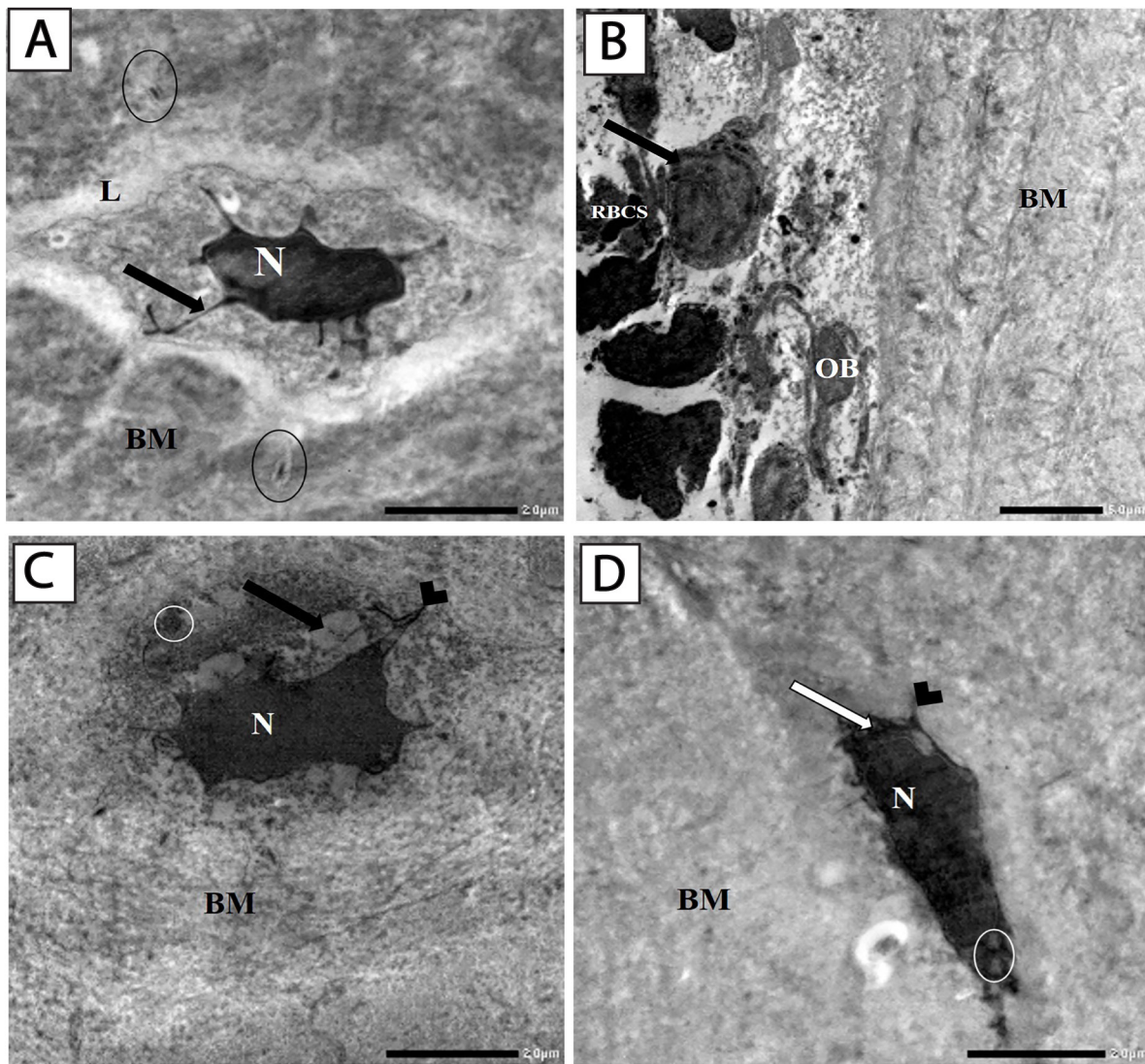


Fig. 4: An electron micrograph of a compact bone section of A) Negative control group showing normal osteocyte within a lacuna (L) in collagen bone matrix (BM). The cell has more or less normal nucleus (N) and cytoplasmic extensions (arrow). Notice cross section of cell processes and canaliculi can be seen (circle). B) Negative control group showing normal osteoblastic cell (OB) rested between bone matrix (BM) and bone marrow. The bone marrow showed several hematopoietic cell included RBCs and neutrophils (arrow). C) RIS +ve control group showing rarified cytoplasm of osteocyte (arrow), most probably normal nucleus (N) and normal mitochondria (circle), well developed cytoplasmic cell process embedded through canaliculi (arrow head) in bone matrix (BM). D) SR +ve control group showing most probably normal osteocyte has more or less regular nucleus (N), normal mitochondria (circle), homogenous cytoplasm (arrow) and normal cytoplasmic cell processes (arrowhead) embedded in bone matrix (BM). (Bar = 2 µm, x 6000).

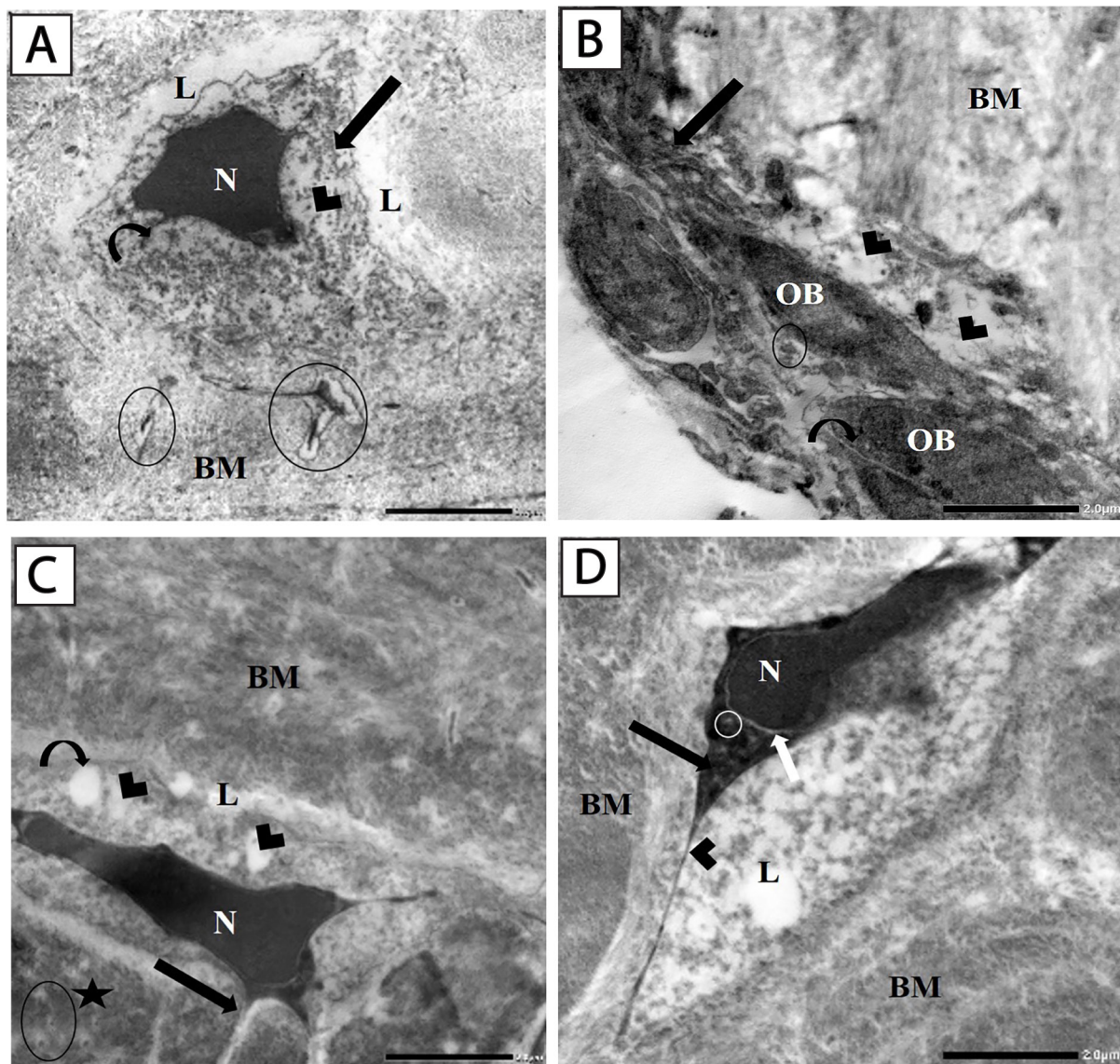


Fig. 5: An electron micrograph of a compact bone section of A) Pred-treated group showing abnormal osteocyte with irregular nucleus (N), massive rarefication of cytoplasm (arrowhead), disrupted rough endoplasmic reticulum (arrow) and complete lysis of cristae of mitochondria (curved arrow). Osteocyte imprisoned in a lacuna (L) surrounded by bone matrix (BM). No cell processes can be observed, damaged cytoplasmic cell process in canaliculi of other osteocyte can be seen (circle). (B) Pred-treated group showing osteoclast with disrupted ruffled border (arrow) and osteoblasts (OB) that have mild dilated rough endoplasmic reticulum (curved arrow) and partial lysis of mitochondrial cristae (circle). Lysis of collagen fibrils (arrow head) situated between osteoblasts and bone matrix (BM). (C) Pred + RIS-treated group showing an osteocyte within a lacuna (L) surrounded by bone matrix (BM). The cell has slightly irregular nucleus (N), focal area of rarefied cytoplasm (arrow head), just one cytoplasmic vacuole can be observed (curved arrow) and numerous well-defined cytoplasmic processes (arrow). Notice granular appearance of bone matrix around the processes (asteric) and cross section of cell processes and canaliculi can be seen (circle). (D) Pred + SR-treated group showing osteocyte resting in lacuna (L). The cell has most probably normal nucleus (N), normal mitochondria (circle), cytoplasm (arrow), rough endoplasmic reticulum and normal cytoplasmic cell processes (arrow head) embedded in bone matrix (BM). The dilated perinuclear membrane (white arrow) can be observed (Bar = 2 μ m, x 6000).

Table 1: Effect of Prednisolone, RIS, and SR administration on the body weight of rats in different experimental groups

	Initial body weight Mean \pm SD	Final body weight Mean \pm SD
Control	200.71 \pm 6.73	254.71 \pm 5.91 ^{b,c}
RIS +ve	196.43 \pm 8.52	259.14 \pm 6.84 ^{b,c}
SR +ve	200 \pm 8.16	260.71 \pm 6.73 ^{b,c}
Pred-treated	200.71 \pm 8.38	194.29 \pm 4.50 ^{a,c}
Pred + RIS	199.29 \pm 7.32	240.71 \pm 3.45 ^{a,b,c}
Pred + SR	200.71 \pm 6.07	242.86 \pm 3.95 ^{a,b,c}

SD: standard deviation, RIS: risedronate, SR: strontium ranelate, Pred: prednisolone

a Significantly different from control at $p < 0.01$

b Significantly different from steroid treated group at $p < 0.01$.

c Significant difference between initial and final body weight in each group at $p < 0.01$.

Table 2: The effect of prednisolone, RIS, and SR on different histomorphometric parameters of the studied groups

Groups	Cortical thickness (μm)	Osteocyte size (Area μm^2)	Osteocyte size (Perimeter μm)	osteocyte number	Scoring of osteoporosis
Negative control	2784.6 \pm 344 ^d	32029 \pm 2489 ^d	698.35 \pm 26.34 ^b	33 \pm 4.67 ^d	0 ^d
RIS +ve control	2699.03 \pm 363.75 ^d	36624 \pm 2989 ^d	798.27 \pm 75.15 ^{ad}	32 \pm 4.69 ^d	0.714 \pm 0.95 ^d
SR +ve control	2739.64 \pm 333.18 ^d	34308 \pm 1325 ^d	735.40 \pm 33.93 ^d	32.5 \pm 4.55 ^d	0.57 \pm 0.79 ^d
Pred-treated	1908.03 \pm 238.46 ^{abc}	21500 \pm 6764 ^{abc}	600.61 \pm 71.25 ^{bc}	14 \pm 3.62 ^{abc}	18.14 \pm 3.24 ^{abc}
Pred + RIS	2889.19 \pm 252.79 ^d	27097 \pm 2880 ^b	655.16 \pm 34.63 ^b	27.8 \pm 5.14 ^d	11.57 \pm 1.62 ^{abcd}
Pred + SR	2904.26 \pm 155.8 ^d	27523 \pm 2378 ^b	631.33 \pm 56.21 ^{bc}	32.3 \pm 8.31 ^d	9.29 \pm 1.11 ^{abcd}

Pred: Prednisolone, RIS: risedronate, SR: strontium ranelate

- a= Significantly different from negative control group at $p \leq 0.01$
- b= Significantly different from RIS +ve control group at $p \leq 0.01$
- c= Significantly different from SR +ve control group at $p \leq 0.01$
- d= Significantly different from Pred-treated group at $p \leq 0.01$

DISCUSSION

Osteoporosis is the most frequent bone disease in humans that remains silent until fracture occurs. It represents a serious public health problem that causes a significant economic burden and impact on the patients' quality of life^[26]. It is characterized by weak bone as a result of disruption of bone microarchitecture and reduced bone mineral density. Various anti-osteoporotic drugs, such as antiresorptive and anabolic agents, are currently available for use in clinics alone or in combination^[27]. In the present study, we assessed and compared the anti-osteoporotic effects of RIS and SR on the histologic, histomorphometric, and ultrastructural features of compact bones in a rat model of GC-induced osteoporosis.

In this study, we employed the GC-induced osteoporosis rat model as it is considered one of the most appropriate, cost-effective, easy handling, and convenient animal models of osteoporosis^[22,28]. Moreover, the used dose and duration of prednisolone administration were documented in previous studies to induce systemic osteoporosis^[22]. Long-term use of prednisolone, a glucocorticoid with anti-inflammatory and immunomodulatory effects, is reported to increase the risk of fracture due to the combined suppression of bone formation and increase bone resorption^[29]. In the present study, we demonstrated that oral prednisolone provoked significant osteoporotic changes as evidenced histologically by decreased cortical bone thickness, multiple osteoporotic cavities, and marked decrease of lamellar bone formation together with an increase in the osteoid tissue when compared to the control group. Our X-ray results demonstrated that administration of prednisolone was associated with generalized decreased in bone density (osteopenia), decrease cortico-medullary ratio, and abnormal bone modeling (bending). These results agreed with the previous observations that GC administration is associated with impairment of bone architecture, reduced bone mass, increased cortical porosity, and bone fragility^[13,30]. In agreement with the findings of previous studies^[22,29], our electron microscopic examination of pred-treated group detected markedly distorted osteocytes, mild changes in osteoblast, and aberrant appearance of the bone matrix with detected

lysis of collagen fibers. Taken together, our observations indicated that prednisolone acts by inhibiting new bone formation and inducing unbalanced bone resorption.

Earlier research findings suggested that GC-induced osteoporosis is caused by decreased bone formation in the presence of unchanged but continued bone resorption^[31]. There are many plausible mechanistic explanations for how GCs induced osteoporosis by affecting osteoblast, osteocyte, and osteoclast. One possible mechanism is that GCs act by inhibiting the Wnt protein expression in osteoblasts, which is crucial for osteoblast formation from the mesenchymal progenitor cells^[4,32]. Another possible mechanism is the direct proapoptotic effect of GC on osteoblast and osteocyte with subsequent reduction of bone formation^[33]. Furthermore, Huang *et al.* showed that long-term steroid treatment suppresses the hypothalamus–hypophysis–adrenal cortex (HPA) axis, hence lowering the release of growth hormone (GH) and insulin like growth factor (IGF-1)^[34]. The disturbance of GH/IGF-1 axis was reported to cause low bone turnover osteoporosis and inhibit the process of endochondral ossification^[35,36]. On the other side, GCs can stimulate osteoclastogenesis and prolong the osteoclast survival via stimulation of the receptor activator of nuclear factor kappa B ligand (RANKL), inhibition of osteoprotegerin (OPG) production from osteoblasts, and inhibition of caspase-3 dependent apoptosis^[33,37]. Importantly, our electron microscopic analysis revealed disrupted ruffled border of osteoclast after administration of prednisolone which signify the inhibition of bone resorption. This is consistent with Kim *et al.* who reported that GC suppress the bone-degrading capacity of osteoclast by disrupting its ruffled border^[38]. This can be elucidated by the failure of osteoclasts to organize their cytoskeleton due to inhibition of VAV3 guanine nucleotide exchange factor (vav3), small GTPases Radiant Heat Output A (RhoA) and Ras-related C3 botulinum toxin substrate 1 (rac) which are essential for osteoclast cytoskeletal organization^[38-40]. Further studies are needed to better understand the effect of GC on osteoclast and to solve this contradiction.

RIS belongs to the nitrogen-containing bisphosphonates class of medications which functions as

potent antiresorptive agent that is commonly indicated for treatment of osteoporosis^[41]. In the current study, our results demonstrated that RIS co-treatment with prednisolone was associated with moderate improvement of prednisolone induced perturbation of the bone architecture. Our results from histological and histomorphometric analyses revealed a significant increase in the cortical bone thickness together with thickened organized collagen fibers in rats treated with Pred+ RIS in comparison to those treated with prednisolone. Our findings are supported by the results of previous studies which also reported the ability of RIS to counteract the GC-induced osteoporosis by maintaining bone architecture and inhibiting bone turnover^[13,42]. Our results can be explained by the findings of Bellido & Plotkin who reported that bisphosphonates preserve osteoblast and osteocyte viability via suppressing their apoptosis^[43]. In addition, some researchers demonstrated that RIS can increase periosteal bone formation as a result to the anabolic effect of parathyroid hormone, however, the exact mechanism is still unclear^[44]. Previous studies demonstrated that nitrogen-containing bisphosphonate inhibits post-translational prenylation of small GTPase and disrupt osteoclast depolarization, which effectively inhibits bone resorption^[45,46]. This is also supported by Bergstrom *et al.* who reported that RIS inhibits osseous resorption by triggering osteoclast apoptosis^[47]. Furthermore, the short-term use of RIS has been linked to a decrease in enzymatic collagen cross-link turnover, which is associated with an increase in collagen fibers that contributes to an increase in bone strength^[48]. Interestingly, we detected a significant heterogeneity of bone matrix in sections obtained from rats treated with Pred + RIS. However, this was clearly at odds with the observations of previous studies that reported reduced cortical bone heterogeneity with administration of bisphosphonate^[48,49]. One potential explanation of this discrepancy is the difference in the duration of bisphosphonate administration as our findings based on short term treatment with RIS. A previous study reported that early in the course of treatment, bisphosphonates increased structural integrity; however, such improvements were lost with long-term therapy^[50].

Regarding Pred + SR-treated group, our findings indicated that SR were able to mitigate the osteoporotic effects of prednisolone on compact bone as evidenced by marked improvement of prednisolone induced perturbations of the bone architecture detected in histologic and histomorphometry analyses. In comparison to the pred-treated group, Pred + SR-treated rats exhibited marked increase in lamellar bone formation which is associated with a significant restoration in the cortical bone thickness. This is consistent with previous data suggested that SR administration increases trabecular bone volume and improves bone microarchitecture^[51,52]. Furthermore, our findings showed that the histomorphometric effects of prednisolone on compact bone were counteracted by the administration of SR. This is in line with the findings of Arlot *et al.* who reported a significant increase in bone formation parameters (osteoblastic surfaces and mineral

apposition rate) in both cancellous and cortical bone in a group of postmenopausal women with osteoporosis treated with SR^[52]. Previous studies have shown that SR has a double effect on bone by both boosting osteoblastogenesis and inhibiting osteoclastic activity^[53]. SR stimulates the proliferation and differentiation of osteoblasts by increasing the expression of osteogenic genes such as runt-related transcription factor (Runx), and SP7 genes^[54,55]. Another putative mechanism implicated in the effect of SR on osteoblasts differentiation is increased Cyclooxygenase-2 (COX2) activities that lead to an increase in prostaglandins E2 production (PGE2), which enhances bone formation^[56]. Proliferated osteoblasts result in formation of collagen and non-collagen proteins and increase the bone matrix density^[57]. SR, on the other hand, inhibits the osteoclastic activity by acting on the two components of bone remodeling through the RANK/RANKL/OPG pathway; it increases OPG secretion while suppressing RANKL expression in osteoblasts, resulting in increased bone formation and decreased osteoclastogenesis^[51]. One cautionary note should be highlighted, although SR is a recommended therapeutic option in patients with severe osteoporosis, it has been associated with an increased risk of venous thromboembolism and myocardial infarction. Taken together our results suggest that SR outperforms RIS in ameliorating the glucocorticoid-induced osteoporosis.

CONCLUSION

Our results provide further insights in understanding the histopathological and ultrastructural changes of GC-induced osteoporosis. Despite the fact that our findings indicate that both RIS and SR are effective treatments for glucocorticoid-induced osteoporosis, we confirmed that SR is superior than RIS. In future research, it will be noteworthy to assess the effect of combining cardioprotective agents with SR in management of osteoporosis.

CONFLICT OF INTERESTS

There are no conflicts of interest.

REFERENCE

1. Rajfer RA, Flores M, Abraham A, *et al.* Prevention of Osteoporosis in the Ovariectomized Rat by Oral Administration of a Nutraceutical Combination That Stimulates Nitric Oxide Production. *J Osteoporos.* 2019;2019:1592328. doi:10.1155/2019/1592328
2. Sozen T, Ozisik L, Basaran NC. An overview and management of osteoporosis. *Eur J Rheumatol.* Mar 2017;4(1):46-56. doi:10.5152/eurjrheum.2016.048
3. Mirza F, Canalis E. Management of endocrine disease: Secondary osteoporosis: pathophysiology and management. *Eur J Endocrinol.* Sep 2015;173(3):R131-51. doi:10.1530/EJE-15-0118
4. Seibel MJ, Cooper MS, Zhou H. Glucocorticoid-induced osteoporosis: mechanisms, management, and future perspectives. *Lancet Diabetes Endocrinol.* Sep 2013;1(1):59-70. doi:10.1016/S2213-8587(13)70045-7

5. Briot K, Roux C. Glucocorticoid-induced osteoporosis. *RMD Open*. 2015;1(1):e000014. doi:10.1136/rmdopen-2014-000014
6. Canalis E, Mazziotti G, Giustina A, Bilezikian JP. Glucocorticoid-induced osteoporosis: pathophysiology and therapy. *Osteoporos Int*. Oct 2007;18(10):1319-28. doi:10.1007/s00198-007-0394-0
7. Amiche MA, Albaum JM, Tadrous M, *et al*. Fracture risk in oral glucocorticoid users: a Bayesian meta-regression leveraging control arms of osteoporosis clinical trials. *Osteoporos Int*. May 2016;27(5):1709-18. doi:10.1007/s00198-015-3455-9
8. Van Staa TP, Leufkens HG, Abenhaim L, Zhang B, Cooper C. Use of oral corticosteroids and risk of fractures. June, 2000. *J Bone Miner Res*. Aug 2005;20(8):1487-94; discussion 1486. doi:10.1359/jbmr.2005.20.8.1486
9. Tonk CH, Shoushrah SH, Babczyk P, *et al*. Therapeutic Treatments for Osteoporosis-Which Combination of Pills Is the Best among the Bad? *Int J Mol Sci*. Jan 26 2022;23(3)doi:10.3390/ijms23031393
10. Russow G, Jahn D, Appelt J, Mardian S, Tsitsilonis S, Keller J. Anabolic Therapies in Osteoporosis and Bone Regeneration. *Int J Mol Sci*. Dec 26 2018;20(1) doi:10.3390/ijms20010083
11. Bi H, Chen X, Gao S, *et al*. Key Triggers of Osteoclast-Related Diseases and Available Strategies for Targeted Therapies: A Review. *Front Med (Lausanne)*. 2017;4:234. doi:10.3389/fmed.2017.00234
12. Harris ST, Watts NB, Genant HK, *et al*. Effects of risedronate treatment on vertebral and nonvertebral fractures in women with postmenopausal osteoporosis: a randomized controlled trial. Vertebral Efficacy With Risedronate Therapy (VERT) Study Group. *JAMA*. Oct 13 1999;282(14):1344-52. doi:10.1001/jama.282.14.1344
13. Dalle Carbonare L, Bertoldo F, Valenti MT, *et al*. Risedronate prevents the loss of microarchitecture in glucocorticoid-induced osteoporosis in rats. *J Endocrinol Invest*. Oct 2007;30(9):739-46. doi:10.1007/BF03350811
14. Ensrud KE. Bisphosphonates for Postmenopausal Osteoporosis. *JAMA*. Jan 5 2021;325(1):96. doi:10.1001/jama.2020.2923
15. Mortensen L, Charles P, Bekker PJ, Digennaro J, Johnston CC, Jr. Risedronate increases bone mass in an early postmenopausal population: two years of treatment plus one year of follow-up. *J Clin Endocrinol Metab*. Feb 1998;83(2):396-402. doi:10.1210/jcem.83.2.4586
16. Reginster J, Minne HW, Sorensen OH, *et al*. Randomized trial of the effects of risedronate on vertebral fractures in women with established postmenopausal osteoporosis. Vertebral Efficacy with Risedronate Therapy (VERT) Study Group. *Osteoporos Int*. 2000;11(1):83-91. doi:10.1007/s001980050010
17. Gupta A, March L. Treating osteoporosis. *Aust Prescr*. Apr 2016;39(2):40-6. doi:10.18773/austprescr.2016.028
18. Alexandru Nemtoi VD, Eliza Dragan, Sorin Pasca, Ana Nemtoi, Mihai Constantin, Anca Sava, Danisia Haba. The Effects of Insulin and Strontium Ranelate on Guided Bone Regeneration in Diabetic Rats. *Revista de Chimie*. 2017; 68(4):693-697. doi:10.37358/RC.17.4.5532
19. Wu Y, Adeeb SM, Duke MJ, Munoz-Paniagua D, Doschak MR. Compositional and material properties of rat bone after bisphosphonate and/or Strontium ranelate drug treatment. *J Pharm Pharm Sci*. 2013;16(1):52-64. doi:10.18433/j3c59h
20. Dambacher; MA, Schmitt; S, Schacht; E, *et al*. Bone Structures *in vitro* and *in vivo* in Animals and in Men – A view into the future. *Journal für Mineralstoffwechsel & Muskuloskelettale Erkrankungen*. 2004;11(3):13-19. doi:https://www.kup.at/kup/pdf/4677.pdf
21. Yu DG, Ding HF, Mao YQ, *et al*. Strontium ranelate reduces cartilage degeneration and subchondral bone remodeling in rat osteoarthritis model. *Acta Pharmacol Sin*. Mar 2013;34(3):393-402. doi:10.1038/aps.2012.167
22. Lin S, Huang J, Zheng L, *et al*. Glucocorticoid-induced osteoporosis in growing rats. *Calcif Tissue Int*. Oct 2014;95(4):362-73. doi:10.1007/s00223-014-9899-7
23. Pritzker KP, Gay S, Jimenez SA, *et al*. Osteoarthritis cartilage histopathology: grading and staging. *Osteoarthritis Cartilage*. Jan 2006;14(1):13-29. doi:10.1016/j.joca.2005.07.014
24. Amira K, Khalifa SAD, Ghada M. Hashem, Essam F. Alalkamy, Mira F. Yacoub. New promising avenue for the simvastatin combination with risedronate, strontium ranelate and raloxifene in experimentally-induced osteoporosis. *The Egyptian Rheumatologist*. 2020;42:63-69. doi:https://doi.org/10.1016/j.ejr.2019.07.005
25. Reynolds ES. The use of lead citrate at high pH as an electron-opaque stain in electron microscopy. *J Cell Biol*. Apr 1963;17:208-12. doi:10.1083/jcb.17.1.208
26. Yong EL, Logan S. Menopausal osteoporosis: screening, prevention and treatment. *Singapore Med J*. Apr 2021;62(4):159-166. doi:10.11622/smedj.2021036
27. Yano T, Ito T, Kanehira Y, *et al*. Effects of risedronate, alendronate, and minodronate alone or in combination with eldecalcitol on bone mineral density, quality, and strength in ovariectomized rats. *Bone Rep*. Jun 2021;14:101061. doi:10.1016/j.bonr.2021.101061

28. Komori T. Animal models for osteoporosis. *Eur J Pharmacol.* Jul 15 2015;759:287-94. doi:10.1016/j.ejphar.2015.03.028
29. Xing-Ming Shi NC, Mark W. Hamrick and Carlos M. Isaacs. Mechanism of Glucocorticoid-Induced Osteoporosis: An Update. In: Qian X, ed. *Glucocorticoids - New Recognition of Our Familiar Friend* doi: 101007/s12020-018-1588-2. 2012.
30. Dalle Carbonare L, Arlot ME, Chavassieux PM, Roux JP, Portero NR, Meunier PJ. Comparison of trabecular bone microarchitecture and remodeling in glucocorticoid-induced and postmenopausal osteoporosis. *J Bone Miner Res.* Jan 2001;16(1):97-103. doi:10.1359/jbmr.2001.16.1.97
31. Prummel MF, Wiersinga WM, Lips P, Sanders GT, Sauerwein HP. The course of biochemical parameters of bone turnover during treatment with corticosteroids. *J Clin Endocrinol Metab.* Feb 1991;72(2):382-6. doi:10.1210/jcem-72-2-382
32. Hildebrandt S, Baschant U, Thiele S, Tuckermann J, Hofbauer LC, Rauner M. Glucocorticoids suppress Wnt16 expression in osteoblasts *in vitro* and *in vivo*. *Sci Rep.* Jun 7 2018;8(1):8711. doi:10.1038/s41598-018-26300-z
33. O'Brien CA, Jia D, Plotkin LI, *et al.* Glucocorticoids act directly on osteoblasts and osteocytes to induce their apoptosis and reduce bone formation and strength. *Endocrinology.* Apr 2004;145(4):1835-41. doi:10.1210/en.2003-0990
34. Huang J, Li J, Zheng S, *et al.* Epimedium flavonoids counteract the side effects of glucocorticoids on hypothalamic-pituitary-adrenal axis. *Evid Based Complement Alternat Med.* 2013;2013:938425. doi:10.1155/2013/938425
35. Giustina A, Mazziotti G, Canalis E. Growth hormone, insulin-like growth factors, and the skeleton. *Endocr Rev.* Aug 2008;29(5):535-59. doi:10.1210/er.2007-0036
36. Lui JC, Baron J. Effects of glucocorticoids on the growth plate. *Endocr Dev.* 2011;20:187-193. doi:10.1159/000321244
37. Cherian KE, Kapoor N, Paul TV. Glucocorticoid-induced Osteoporosis. *Indian J Endocrinol Metab.* Sep-Oct 2017;21(5):652-654. doi:10.4103/ijem.IJEM_187_17
38. Kim HJ, Zhao H, Kitaura H, *et al.* Glucocorticoids suppress bone formation via the osteoclast. *J Clin Invest.* Aug 2006;116(8):2152-60. doi:10.1172/JCI28084
39. Faccio R, Teitelbaum SL, Fujikawa K, *et al.* Vav3 regulates osteoclast function and bone mass. *Nat Med.* Mar 2005;11(3):284-90. doi:10.1038/nm1194
40. Chellaiah MA, Soga N, Swanson S, *et al.* Rho-A is critical for osteoclast podosome organization, motility, and bone resorption. *J Biol Chem.* Apr 21 2000;275(16):11993-2002. doi:10.1074/jbc.275.16.11993
41. Tabatabaei-Malazy O, Salari P, Khashayar P, Larijani B. New horizons in treatment of osteoporosis. *Daru.* Feb 7 2017;25(1):2. doi:10.1186/s40199-017-0167-z
42. Iwamoto J, Seki A, Takeda T, *et al.* Preventive effects of risedronate and calcitriol on cancellous osteopenia in rats treated with high-dose glucocorticoid. *Exp Anim.* Jul 2006;55(4):349-55. doi:10.1538/expanim.55.349
43. Bellido T, Plotkin LI. Novel actions of bisphosphonates in bone: preservation of osteoblast and osteocyte viability. *Bone.* Jul 2011;49(1):50-5. doi:10.1016/j.bone.2010.08.008
44. Iwamoto J, Matsumoto H, Takeda T, Sato Y, Liu X, Yeh JK. Effects of vitamin K(2) and risedronate on bone formation and resorption, osteocyte lacunar system, and porosity in the cortical bone of glucocorticoid-treated rats. *Calcif Tissue Int.* Aug 2008;83(2):121-8. doi:10.1007/s00223-008-9146-1
45. Coxon FP, Thompson K, Roelofs AJ, Ebetino FH, Rogers MJ. Visualizing mineral binding and uptake of bisphosphonate by osteoclasts and non-resorbing cells. *Bone.* May 2008;42(5):848-60. doi:10.1016/j.bone.2007.12.225
46. Rogers MJ, Crockett JC, Coxon FP, Monkkonen J. Biochemical and molecular mechanisms of action of bisphosphonates. *Bone.* Jul 2011;49(1):34-41. doi:10.1016/j.bone.2010.11.008
47. Bergstrom JD, Bostedor RG, Masarachia PJ, Reszka AA, Rodan G. Alendronate is a specific, nanomolar inhibitor of farnesyl diphosphate synthase. *Arch Biochem Biophys.* Jan 1 2000;373(1):231-41. doi:10.1006/abbi.1999.1502
48. Leung JY, Ho AY, Ip TP, Lee G, Kung AW. The efficacy and tolerability of risedronate on bone mineral density and bone turnover markers in osteoporotic Chinese women: a randomized placebo-controlled study. *Bone.* Feb 2005;36(2):358-64. doi:10.1016/j.bone.2004.10.014
49. Donnelly E, Meredith DS, Nguyen JT, *et al.* Reduced cortical bone compositional heterogeneity with bisphosphonate treatment in postmenopausal women with intertrochanteric and subtrochanteric fractures. *J Bone Miner Res.* Mar 2012;27(3):672-8. doi:10.1002/jbmr.560
50. Somford MP, Draijer FW, Thomassen BJ, Chavassieux PM, Boivin G, Papapoulos SE. Bilateral fractures of the femur diaphysis in a patient with rheumatoid arthritis on long-term treatment with alendronate: clues to the mechanism of increased bone fragility. *J Bone Miner Res.* Oct 2009;24(10):1736-40. doi:10.1359/jbmr.090408

51. Hamdy NA. Strontium ranelate improves bone microarchitecture in osteoporosis. *Rheumatology (Oxford)*. Oct 2009;48 Suppl 4:iv9-13. doi:10.1093/rheumatology/kep274
52. Arlot ME, Jiang Y, Genant HK, *et al.* Histomorphometric and microCT analysis of bone biopsies from postmenopausal osteoporotic women treated with strontium ranelate. *J Bone Miner Res*. Feb 2008;23(2):215-22. doi:10.1359/jbmr.071012
53. Bonnellye E, Chabadel A, Saltel F, Jurdic P. Dual effect of strontium ranelate: stimulation of osteoblast differentiation and inhibition of osteoclast formation and resorption *in vitro*. *Bone*. Jan 2008;42(1):129-38. doi:10.1016/j.bone.2007.08.043
54. Malgorzata Witkowska-Zimny, Edyta Wrobel, Przybylski J. The Most Important Transcriptional Factors of Osteoblastogenesis. *Medical Journal of Cell Biology*. 2010;2(1)
55. Rashid H, Ma C, Chen H, *et al.* Sp7 and Runx2 molecular complex synergistically regulate expression of target genes. *Connect Tissue Res*. Aug 2014;55 Suppl 1:83-7. doi:10.3109/03008207.2014.923872
56. Choudhary S, Halbout P, Alander C, Raisz L, Pilbeam C. Strontium ranelate promotes osteoblastic differentiation and mineralization of murine bone marrow stromal cells: involvement of prostaglandins. *J Bone Miner Res*. Jul 2007;22(7):1002-10. doi:10.1359/jbmr.070321
57. Blair HC, Larrouture QC, Li Y, *et al.* Osteoblast Differentiation and Bone Matrix Formation *In Vivo* and *In Vitro*. *Tissue Eng Part B Rev*. Jun 2017;23(3):268-280. doi:10.1089/ten.TEB.2016.0454

الملخص العربي

التأثيرات العلاجية للسترونتيوم رانيلات وريزدرونات على نموذج هشاشة العظام للفئران المستحث بالجلوكوكورتيكويد: دراسة نسيجية ومورفومترية مقارنة

ايناس يوسف^١، سمر عبد المنعم^٢، بسمه منصور^٢، نهي نوفل^٣

^١قسم الأنسجة وبيولوجيا الخلية، كلية الطب، جامعة المنوفية مصر

^٢قسم التشريح البشري وعلم الأجنة، قسم علم الأمراض، كلية الطب، جامعة قناة السويس، مصر

^٣قسم العلوم الطبية الأساسية، كلية الطب، جامعة دار العلوم، الرياض، السعودية

المقدمة: هشاشة العظام هي أكثر أمراض العظام انتشارًا في البشر، حيث تصيب الأشخاص من جميع الأعمار ولكنها أكثر شيوعًا لدى النساء بعد سن اليأس. ريزدرونات والسترونتيوم رانيلات هما دواءان مضادان لهشاشة العظام تحت الاستخدام الكلينيكي

الاهداف: تقييم ومقارنة التأثيرات المحتملة لريزدرونات وسترونتيوم رانيلات على السمات النسيجية والمورفومترية والتركيب الدقيق للعظام المضغوطة في نموذج الفئران لهشاشة العظام الناجمة عن الجلوكوكورتيكويد

الطرق والمواد: تم تخصيص ٤٢ جردًا من الذكور الناضجة السليمة مقسمة بشكل عشوائي إلى ٦ مجموعات رئيسية (٧ فئران / مجموعة) وتلقوا علاجات يوميًا عن طريق الفم لمدة ١٢ أسبوعًا على النحو التالي المجموعة الحاكمة السليمة، المجموعة الحاكمة ريزدرونات (٢,٥ ملغ/كغ/يوم)، المجموعة الحاكمة رانيلات السترونتيوم (٦٢٥ ملغ/كغ/يوم)، مجموعة بريدنيسولون المعالجة (١,٥ ملغ/كغ/يوم)، مجموعة بريدنيسولون + ريزدرونات، ومجموعة بريدنيسولون + رانيلات السترونتيوم. في نهاية التجربة، تم تخدير جميع الحيوانات والتضحية بها، وتم استئصال عظم الفخذ وقصبه الساق من أجل الدراسات المجهرية النسيجية والنسجية الإلكترونية والأشعة السينية

النتائج: أثار بريدنيزولون الفموي تغيرات كبيرة في هشاشة العظام وانحناء العظام المكتشفة في الأشعة السينية. اكتشف التحليل النسيجي انخفاض سمك العظام القشرية، وثقوب متعددة غير منتظمة، وانخفاض تكوين العظام الصفائحية لوحظت تغيرات في البنية الدقيقة للعظام في شكل بانينات عظمية مشوهة وخلايا عظمية وتحلل الياف الكولاجين في مصفوفة العظام. ارتبط الإعطاء الفموي لريزدرونات وسترونتيوم رانيلات بتحسين معتدل وملحوظ في الاضطرابات الناجمة عن بريدنيزولون في بنية العظام على التوالي

الاستنتاج: تشير بياناتنا إلى أن ريزدرونات يتفوق في الأداء على رانيلات السترونتيوم في التخفيف من هشاشة العظام الناجمة عن الجلوكوكورتيكويد