

## Role of Tracheal Resection & Anastomosis in Treatment of Tracheal Stenosis after Prolonged Intubation

Moataz Helmy Ibrahim Younis,<sup>1\*</sup> MSc, Mohamed Mahmoud El Sway,<sup>1</sup> MD, Ahmed Mohamed El sheikh,<sup>1</sup> MD.

*\* Corresponding Author:*

Moataz Helmy Ibrahim Younis  
[moatazyounis111@gmail.com](mailto:moatazyounis111@gmail.com)

*Received for publication April 12, 2022; Accepted October 25, 2022; Published online October 25, 2022.*

*doi:* 10.21608/aimj.2022.132675.1910.

*Citation:* Moataz HIY., Mohamed ME and Ahmed ME. Role of Tracheal Resection & Anastomosis in Treatment of Tracheal Stenosis after Prolonged Intubation. AIMJ. 2022; Vol.3-Issue10 .149-157.

<sup>1</sup>Otorhinolaryngology Department, Faculty of Medicine, Al-Azhar University, Cairo, Egypt.

### ABSTRACT

**Background:** tracheal stenosis is a challenging condition for the otolaryngologist –head and neck surgeon. The prevalence of Tracheal stenosis after intubation has been found to range between 10% and 19%.

**Aim of the study:** To discuss and evaluate the Anastomosis and tracheal resection operation in the treatment of Post- intubation Tracheal Stenosis.

**Patients and Methods:** This statistical analysis was performed on 14 cases where Tracheal resection and anastomosis are used to treat Tracheal Stenosis after Prolonged Intubation in Department of Otorhinolaryngology, Al-Azhar University Hospitals.

**Results:** This study included 14 male patients ranging from 15 to 49 years of age, having a mean age of 24.14286, with only tracheal stenosis after prolonged intubation, 11 patients fourth grade, 2 patients third grade, one patient second grade (70%) according to Myer and Cotton grade, they underwent tracheal resection and anastomosis and suprahyoid release for treatment of tracheal stenosis after prolonged intubation. The stenotic segment's length ranged from 1.5 to 4 cm (mean=2.7 cm). We achieved an overall success rate of 100%.

**Conclusion:** Anastomosis and Tracheal resection is a dependable surgical procedure for management of second grade failed to be treated endoscopically, third grade and fourth grade tracheal stenosis after prolonged intubation. Male patients benefit the most from this approach when the stenosis is short segment, and not involving the cricoid cartilage. The surgical results are unaffected by the severity of stenosis or the history of prior endoscopic procedures.

**Keywords:** Tracheal Resection; Tracheal Stenosis; Prolonged Intubation.

**Disclosure:** The authors have no financial interest to declare in relation to the content of this article. The Article Processing Charge was paid for by the authors.

**Authorship:** All authors have a substantial contribution to the article.

**Copyright** The Authors published by Al-Azhar University, Faculty of Medicine, Cairo, Egypt. Users have the right to read, download, copy, distribute, print, search, or link to the full texts of articles under the following conditions: Creative Commons Attribution-Share Alike 4.0 International Public License (CC BY-SA 4.0).

### INTRODUCTION

Mechanical trauma from prolonged intubation or tracheotomy is the most prevalent reason for tracheal stenosis throughout the contemporary era. Tracheal stenosis can be produced by tracheostomy stomal injury, cuff-induced ischemia damage to the trachea or a combination of the both (Figure 1).<sup>1</sup>

Depending on the form and severity of the disease, a variety of therapies are available. Endoscopic laser treatments that include or exclude dilatation or stenting are available for Reconstruction of the laryngotracheum using anterior, posterior, or mixed costal cartilage grafts, the most severe grades of stenosis are treated with partial cricotracheal resection, and laryngotracheal stenosis is treated with extended partial cricotracheal resection.<sup>2</sup>

The effects of several treatment approaches for people with acquired subglottic stenosis were evaluated in a meta-analysis study. The success rate of tracheal resection and anastomosis was reported to be 95%, reconstruction of the laryngotracheum was 76 percent with or without grafting, and endoscopic treatments had rates of success range from 40% to 82 percent.<sup>3</sup>

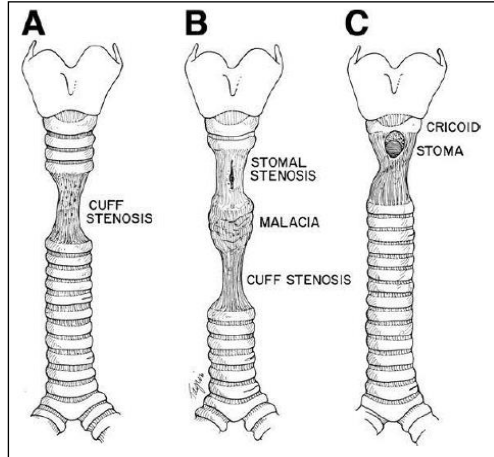
The gold standard for treating tracheal stenosis is tracheal resection and primary anastomosis.<sup>4</sup>

### PATIENTS AND METHODS

This analytic investigation was carried out on 14 patients using Tracheal resection and anastomosis for Tracheal Stenosis Following Prolonged Intubation in Department of Otorhinolaryngology, Al-Azhar

University Hospitals and other hospitals by Prof. Dr. Mohamed Mahmoud El Sawy and his surgical team.

All patients had a history of ICU admission, prolonged intubation, then they developed airway compromise such as dyspnea and stridor and the most needed tracheotomy later.

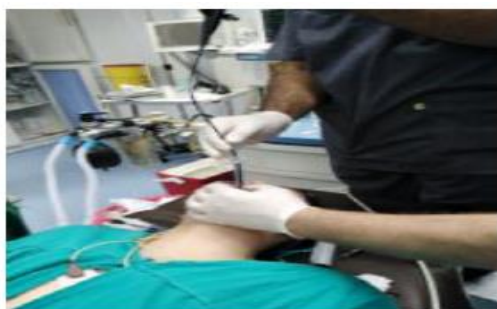

**Fig.1:** Iatrogenic laryngotracheal stenosis can be produced by cuff-induced ischemia damage to the trachea, tracheostomy stomal injury, or a combination of the two<sup>5</sup>.

A high-resolution spiral computed tomography scan was used to investigate all of the patients. Furthermore, by using virtual tracheobronchoscopy. To determine the grade and extent of the stenosis, all patients received a preoperative flexible fiberoptic endoscopic examination. All of these procedures were carried out to accurately determine the position and length of the stenotic segment. The severity of the stenosis was determined using the Myer and Cotton grading technique, as indicated below:

First Grade: a lesion that causes less than 50 percent blockage; Second Grade: a lesion that causes blockage between 51 and 70 percent; Third Grade : a lesion that causes 71–99 percent blockage; and Fourth Grade: complete stenosis.

11 patients were fourth grade and they had previous tracheostomy, 2 patients were third grade, and one patient was second grade (obstruction was 70%).



**Fig.2:** Preoperative direct laryngotracheobronchoscopy.

Under general anaesthesia, a direct laryngotracheoscopic examination was performed prior to surgery for all cases. The objectives were to determine the nature (soft or hard), location (relative to the vocal cords), degree (diameter of the airway), and length of the stenotic segment (Figure 2).

**Inclusion criteria:**

The following procedure was used to all patients with Post-intubation Tracheal Stenosis: Full history taking; head and neck examination; full laboratory investigation include (CBC, T3, T4, TSH, liver and kidney functions, PT, PC, INR, FBS); neck ultrasound; CT head and neck - virtual tracheobronchoscopy; preoperative flexible fiberoptic endoscopic examination and cine MRI of the airway.

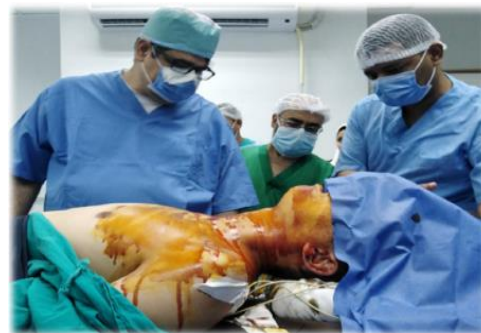**Exclusion criteria:**

Patients with Tracheal Stenosis caused by other causes except post intubation; there is glottic stenosis or cricoid cartilage involvement, when the lesion extends over half the length of the trachea; impaired pulmonary function considered a contraindication and scarring from previous neck surgery: limits mobility & places tension on anastomosis.

**Surgical technique**

**Pre-operative preparation**

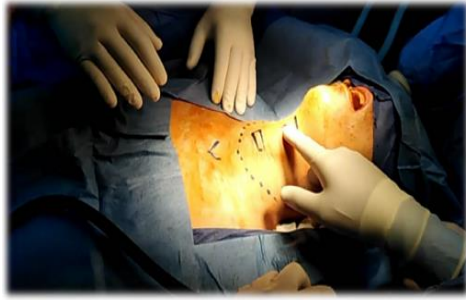Rigid bronchoscopy performed shortly prior to the surgery to confirm the exact kind and location of the stenosis. Ryle is inserted to help define the position of the oesophagus during posterior tracheal wall dissection, folly’s catheter and patient position.



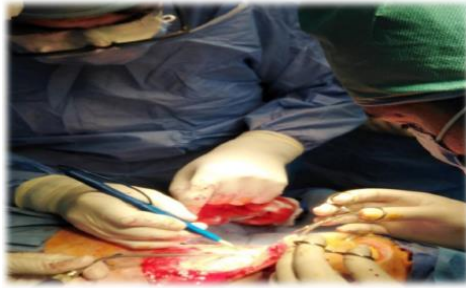
**Fig.3:** Anti-Trendelenburg position.

The patient is Supine with Shoulder roll (thyroid bag) to optimally extend the neck

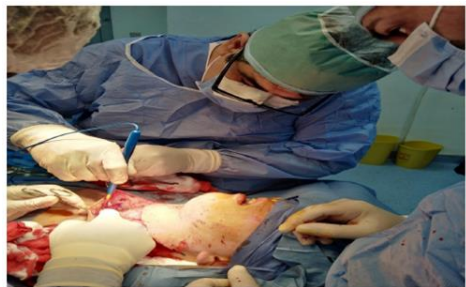Head ring, the patient must be in the midline. Back of the operating room table elevated to 10-15°: to position the cervical & sternal areas parallel to the floor when the head is extended fully.



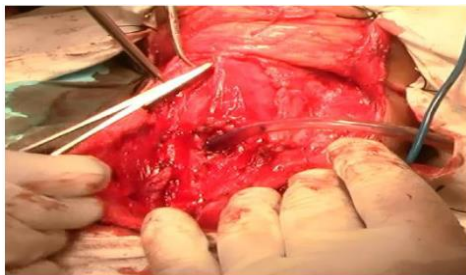
**Fig.4:** Anterior cervical U-shaped incision.



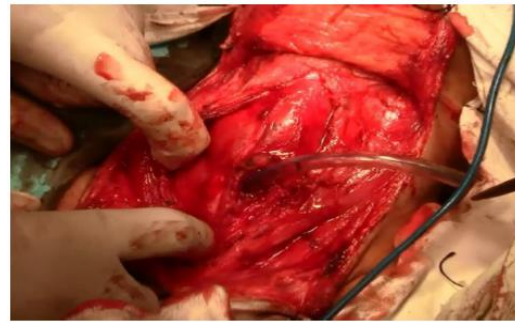
**Fig.5:** Upper flap: 2 centimetres above the hyoid bone for suprahyoid release.



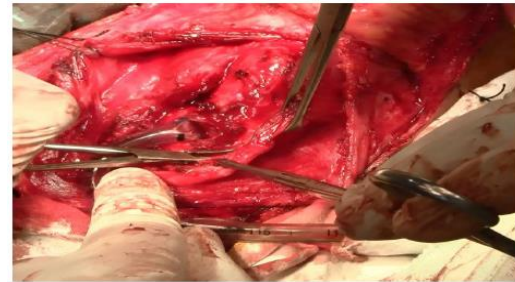
**Fig.6:** Dissection of Lower flap: to the clavicle.



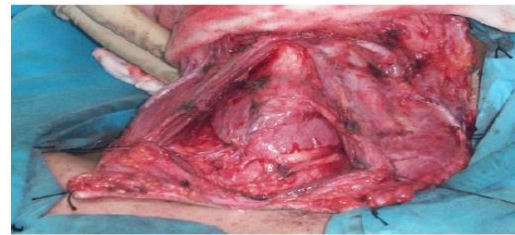**Fig.7:** Ligation of the AJV and Dissection of the fascia in the midline. Dissection of the fascia in the midline (from the level of clavicle to the hyoid bone) and Ligation of the AJV.



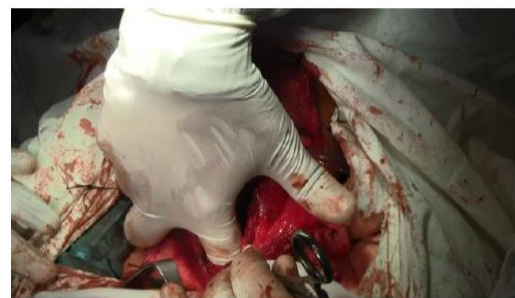**Fig.8:** Dissection of the sternohyoid in the midline.



**Fig.9:** The sternohyoid muscle is separated from the sternothyroid muscle.



**Fig.10:** The cervical trachea is exposed, the thyroid isthmus is split and ligated, and the strap muscles are retracted laterally using stay sutures. Splitting and ligating the thyroid isthmus to expose the cervical trachea's front side. Strap muscles are retracted laterally with stay sutures. Dissection of the strap muscles from each other can provide 2-cm of release.



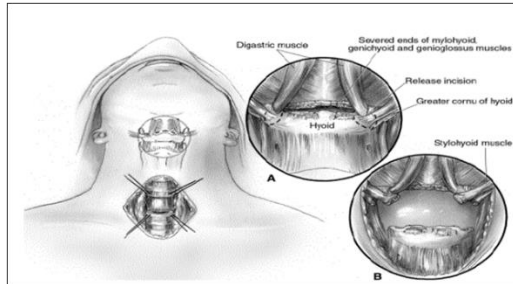
**Fig.11:** The sternohyoid muscle is separated from the sternothyroid muscle. Finger dissection of the cervical trachea.

Lenthening of the trachea. Finger dissection of the cervical trachea with a smooth rocking movement of the index finger, the dissection continues deep into the innominate artery, leading to the carina, because

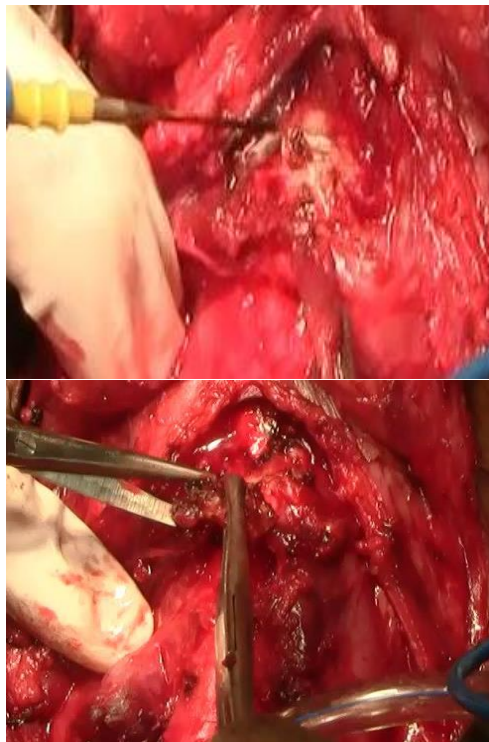


the trachea receives arterial blood supply in a segmental pattern from lateral vascular stalks.

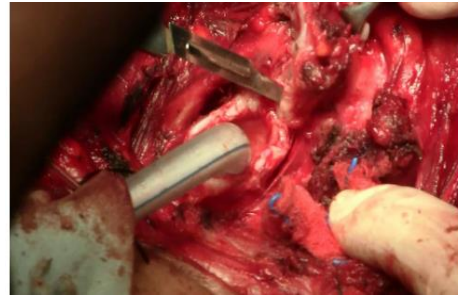
**Suprahyoid release (Montgomery):**



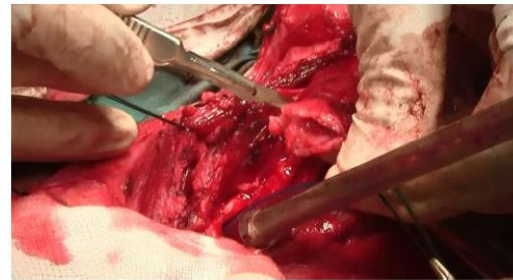**Fig.12:** Release of Suprahyoid release <sup>6</sup>.



**Fig.13:** Release of the suprahyoid. Muscle connections to the superior aspect of the hyoid bone are severed, and the central hyoid is removed. The larynx and cervical trachea are allowed to drop inferiorly, allowing for a 2-3 cm length gain.



**Fig.14:** a transverse incision is made between the tracheal rings.

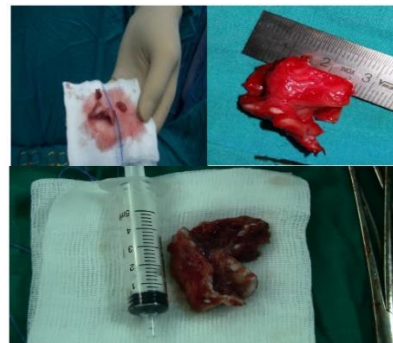

**Fig.15:** transverse incision between the tracheal rings.

**Tracheal cut**

Dissection is continuing above the stenotic part of the trachea until a healthy trachea.

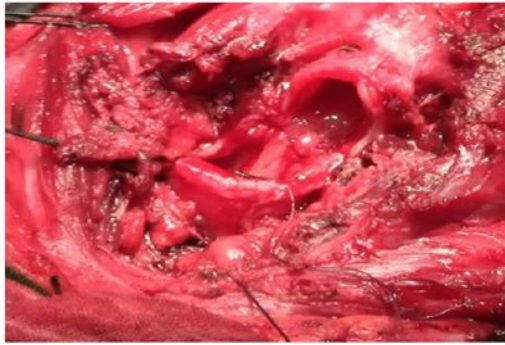
After define the stenotic area, transversal incision between the tracheal rings (Figure 14, 15).



**Fig.16:** Stenotic parts of tracheal after resection. The stenotic area is now cut. It is important to make sure the tracheal cut ends are typical in size and as healthy as possible.

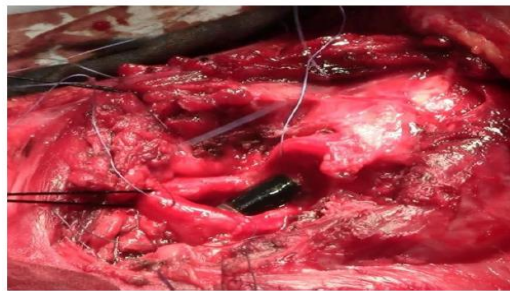
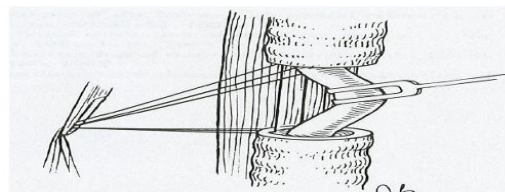
**Anastomosis**

The suture never tied under tension. Intra-operatively, to relief the tension and sustain the anastomosis Remove the shoulder blanket and Bend the neck forward. Vicryl suture is used to reduce the occurrence of granulation tissue formation.



**Fig.17:** Suturing posterior wall of trachea.

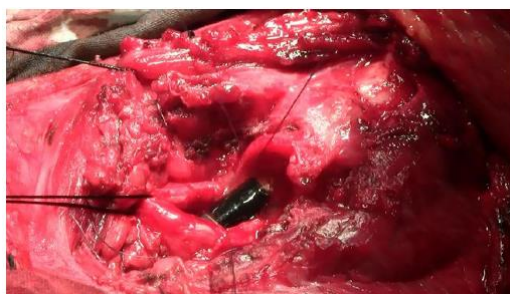
Vicryl suture 3/0, rounded is used & 3 mm suture apart. Ligation is left untied till all the posterior sutures are in place.



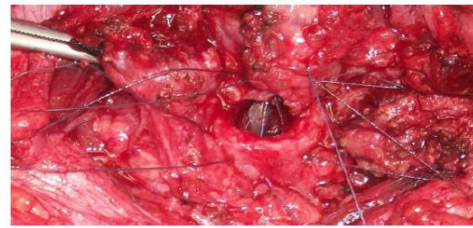
**Fig.18:** Oral endotracheal tube is introduced after closure of the posterior wall and before the anterior wall closure.

Oral endotracheal tube

It is introduced after closure of the posterior wall & before closure of the anterior wall closure (Figure 18).

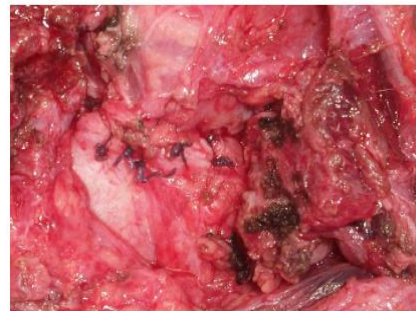

**Fig.19:** Closure of the anterior wall by using 3/0 Vicryl, rounded suture.



**Fig.20:** Closure of the anterior wall, 3-mm apart and Left untied till all sutures are in place.

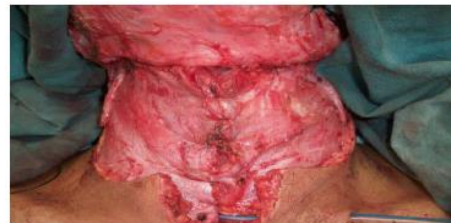Closure of the anterior wall (Figure 19, 20) Vicryl suture 3/0, rounded is used & 3 mm suture apart and Left untied till all sutures are in place.



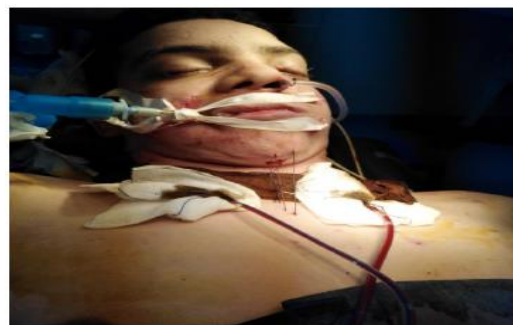**Fig.21:** The completed anastomosis.

Complete closure of the anterior wall (Figure 20)

Test for anastomosis: after tying the sutures, saline is poured into the field, then valsalva is done to define any air leak.



**Fig.22:** Drains are put and closure of Strap muscles, thyroid isthmus is sutured over the anastomosis, Closure of the strap muscles in midline and Skin closure in 2 layers.



**Fig.23:** Chin-chest suture: inserted between the submental crease and the presternal skin.

Guardian suture

Chin-chest suture is retained for at least 1 week to 2 weeks between the presternal skin and the submental crease to avoid hyperextension by O/Proleine (Figure 22).

**Postoperative period and follow-up**

Extubation:

Immediate extubation in the OR is the ultimate goal.

Leave the patient with a small, uncuffed endotracheal tube for 24 hours: in case of post-operative anastomotic leaking or laryngeal edema.

Tracheostomy placed 2 cm distal to the anastomosis: if the surgeon judges that immediate extubation is unlikely.

Gentle neck flexion, neck is maintained in gentle flexion by guardian suture during the postoperative period to decrease any tension on the anastomosis for 2 weeks.

Antiemetics & Anti-reflux measures, Because vomiting and aspiration of gastric contents can be fatal in a patient with a new tracheal anastomosis, empiric antibiotic treatment and pain medication were given for 5–7 days.

Voice rest: for 1 week to lower glottic pressure and therefore airflow at the anastomosis site and prevent laryngeal edoema.

Carful observation: stridor, subcutaneous air, excessive secretions or wound infection are Consider indicators of an anastomotic issue as a cause for immediate investigation.

Routine bronchoscopy: performed after 1 week of surgery to visualize the anastomosis.

Unless extensive releasing manoeuvres are performed, Feeding tubes are only used in a small percentage of cases after surgery.

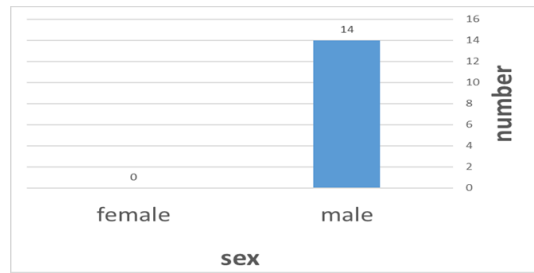
The suction drain is removed on day 3 if there are no issues or evidence of an air leak/crepitus.

Sutures for the skin and chin flexion are removed after one week and two weeks, respectively.

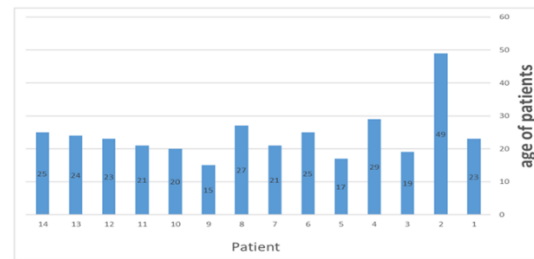
**Statistical Analysis**

Before being documented and analysed using an IBM-compatible PC with the SPSS (Statistical Package for the Social Sciences) application version 22.0.0, Microsoft Office Excel 2007, and GraphPad Prism 6, all of the data were corrected and validated. Descriptive statistics were computed and given as numbers, percentages, means, standard deviations (SD), and ranges for all parameters examined in the three groups.

**RESULTS**

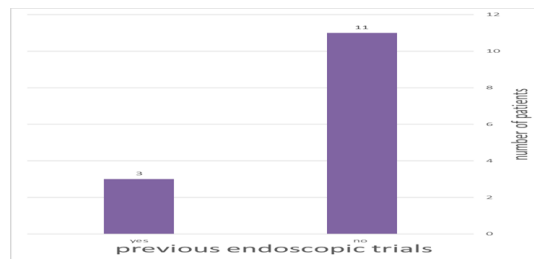


**Fig.24:** This diagram showing the ratio between male and female in our study 14/0.



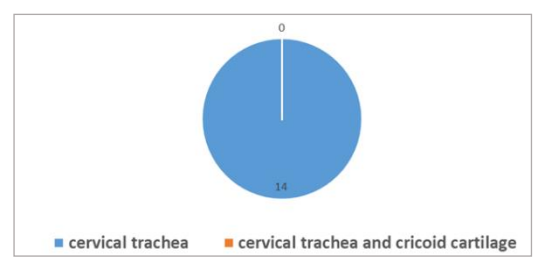
**Fig.25:** This diagram showing the ratio between male and female in our study 14/0.

There were 14 male patients, ages 15–49, with an average age of 24.14 years. All of the cases were caused by extended intubation, primarily as a result of head trauma. (Figure 24, 25, Table 1).



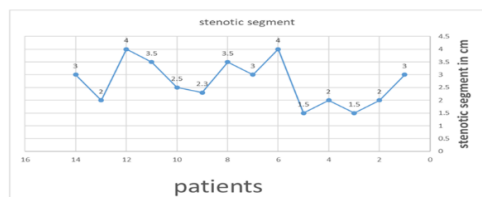
**Fig.26:** This diagram showing number of the patients had previous failed endoscopic trials n=3 (21.4%).

Three patients (21.4%) had previously failed stenosis treatment attempts, comprising one or more trials of endoscopic partial stenosis excision and (if present) granulation through endoscopic dilatation (Figure 26).

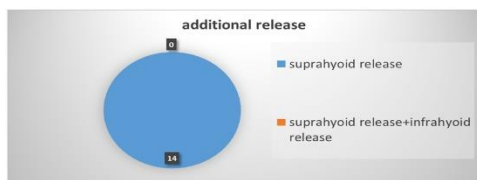


**Fig.27:** This diagram showing that in all individuals, the stenosis was limited to the cervical trachea. The stenotic segment's preoperative length was estimated to be 1.5 to 4 cm (mean=2.7 cm).





**Fig.28:** This diagram demonstrating the The predicted length of the stenotic segment was 1.5 to 4 cm. In all cases, suprahyoid release was accomplished.



**Fig.29:** This diagram showing Suprahyoid release was done as an extra release in all instances.

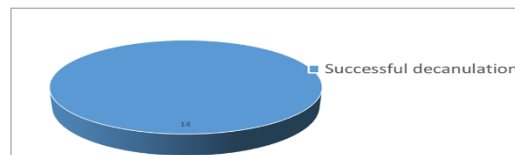
At the time of operation, 11 patients (78.57 percent) had a previous tracheostomy. All of the patients exhibited movable vocal folds on both sides.

There were one case of second grade stenosis and two cases of third grade stenosis, and eleven cases with fourth grade stenosis, all of whom had a pre-existing tracheostomy at the time of operation (Figure 27). In all individuals, stenosis was exclusively seen in the cervical trachea (Figure 28).

(Figure 29), this diagram showing there were one instance of second grade stenosis, two cases of third grade stenosis, and eleven cases of fourth grade

stenosis, all of whom had a pre-existing tracheostomy at the time of surgery.

As regards Complications, It is defined as either anastomotic or non-anastomotic. Anastomotic problems include granulation tissue development, tracheal restenosis, different degrees of anastomotic separation, and fistulae to adjacent tissues such as the innominate artery [tracheoinnominate fistula (TIF)] and oesophagus [tracheoesophageal fistula (TEF)].



**Fig.30:** This diagram showing Successful decanulation was achieved in 14 (100%) cases.

Laryngeal edoema and glottic dysfunction, either with relation to phonation or swallowing, are non-anastomotic complications peculiar to upper airway reconstruction.

In our study, there isn't any one of these complications or others, in our study, 14 patients achieved an excellent result, and decanulation was successful in 14 (100%) of the 14 instances. (Figure 30). A successful patient was one who didn't need recanulation throughout the six month follow up period; they were monitored using flexible fibre optic tracheobronchoscopy under local anaesthesia.

Careful patient selection and surgical approach should help to reduce postoperative problems after tracheal resection..

	n (%)
<b>Sex</b>	
Female	0 (0%)
Male	14 (100%)
<b>Previous endoscopic trials</b>	
No	11 (78.6%)
Yes	3 (21.4%)
<b>Location</b>	
Present in the trachea and cricoid cartilage	0 (0%)
Only present in the trachea	14 (100%)
<b>Grade</b>	
first	1 (7.1%)
third	2 (14.2%)
fourth	11 (78.7%)
<b>Additional release</b>	
Suprhyoid	14 (100%)
Suprhyoid+ infrahyoid	0 (0%)
<b>Age</b>	
mean± SD	24.14286
Range	15 – 49
<b>Length</b>	
mean± SD	2.7 ± 1.6
Range	1.5 - 4

**Table 1:** Demographic and clinical features of study participants (n=14). This table showing Demographic and clinical features of study participants in this study.

## DISCUSSION

Patients with tracheal stenosis can have life-threatening dyspnea; nevertheless, specialist methods for excision and repair of high tracheal lesions are available and provide significant symptom alleviation. It is critical to have a thorough understanding of the anatomy, the amount of the stenosis, and to pay close attention to surgical technique. Excellent outcomes can be obtained in skilled clinics that can predict and hence avoid issues that can be difficult to control.<sup>7</sup>

We have 14 male patients in our study, with an average age of 24.14286 (range 15–49) years and only tracheal stenosis after prolonged intubation, 11 patients fourth grade, 2 patients third grade, one patient second grade (stenosis in this patient was 70%) according to Myer and Cotton grade, they underwent tracheal resection and anastomosis and suprahyoid release for treatment of tracheal stenosis after prolonged intubation. The stenotic segment varied in length from 1.5 to 4 cm (mean=2.7 cm). We had a perfect overall success rate of 100 percent.

The success rate in the previous studies ranged between 90.0% and 97.3%.

In the study with the same number of patient the success rate was 92.85%, twelve male and two female patients (aged 16-30 years, mean age 24 years) had tracheal resection anastomosis for postintubation stenosis (78.57%) and trauma (78.57%) (21.42%). One to five tracheal rings (i.e. 1-2.5 cm of cervical trachea) are resected.<sup>8</sup>

In another study with the same number of patients with tracheal invasive thyroid cancer and laryngotracheal stenosis. Tracheal or cricotracheal resection and primary end-to-end anastomosis were performed on all patients. The stenosis measured 1.7-4 cm in length. Four patients had Myer and Cotton grade two stenosis, six had Myer and Cotton grade three stenosis, and two had Myer and Cotton grade four stenosis. Tracheotracheal end-to-end anastomosis (n = 4), were among the surgical operations performed. Patients with invasive thyroid cancer had tracheal or cricotracheal end-to-end anastomosis and segmental excision of the affected segment with tumor-free margins. Thirteen patients had successful decannulation (93 percent). Wound infection (n = 1), subcutaneous emphysema (n = 1), temporary unilateral vocal fold palsy (n = 1), granulation tissue formation (n = 1), and restenosis (n = 2) were the post-operative complications.<sup>9</sup>

In another study, twelve patients ranging in age from 15 to 79 years old were enrolled in the study. Prolonged tracheal intubation was the most prevalent cause of stenosis (eleven patients), which was graded using the Myer-Cotton classification (Ann Otol Rhinol Laryngol. 1994; 103: 319-323) as follows: grade two (25 percent), grade three (58 percent), and

grade four (25 percent) (17 percent). The stenosis varied in length from 1 to 6 cm. The operations conducted were tracheal end-to-end anastomosis (n = 5), cricotracheal anastomosis (n = 4), and thyrotracheal anastomosis (n = 3). Eleven patients were extubated successfully (92 percent). One patient is still using a T tube stent. There was a lot of granulation tissue at the anastomosis site (33 percent). Because there was no cause-related death, we can say that there was no one.<sup>10</sup>

In the study with 12 male patients with postintubation cervical tracheal stenosis (grade III-IV) were treated at Mansoura University Hospitals' otolaryngology department. At the time of presentation, all patients had a tracheostomy, and all underwent tracheal resection with primary cricotracheal anastomosis and suprahyoid release. Five patients (41.7 percent) had third grade stenosis, while seven had fourth grade stenosis (58.3 percent). The trachea removed ranged in length from 2 to 4 cm, representing one to four tracheal rings. The technique resulted in effective tracheotomy decannulation in all 12 patients. Minor complications included surgical emphysema (n = 2) and wound infection (n = 1), all of which were treated conservatively. Restenosis (n = 3) was the most serious consequence, which was treated in two patients with repeated dilatation; one patient was lost to follow up. In 11/12 (92 percent) of patients with severe cervical tracheal stenosis, segmental tracheal resection with cricotracheal anastomosis was effective. The treatment technique for airway stenosis is now well established, and success rates are high, with few or no sequelae.<sup>11</sup>

Resection and reconstruction are the preferred therapies for postintubation tracheal stenosis, as evidenced by 94 percent excellent or satisfactory outcomes in over 500 patients. In these therapies, accurate diagnosis, adequate patient selection, and competent and precise surgical care are critical.<sup>12</sup>

In the study, they performed around 800 tracheal surgeries, 76 conventional cervical tracheal resections. Resections were performed through direct anastomosis, with no intraoperative tracheotomy or intralaryngeal stenting. Patient records were evaluated retrospectively for perioperative data. All patients' postoperative tracheostomies were closed within three months, however one patient died from pulmonary problems.<sup>13</sup>

In our study, we excluded tracheal stenosis caused by other causes such as respiratory infections, external trauma, tumors, or rheumatologic disease (only post intubation).

We excluded the lesion that is more than half the length of the trachea and if there is glottic stenosis or involvement of the cricoid cartilage (only tracheal stenosis).



We excluded the patient with impaired pulmonary function.

Our cases are 14 male patients, with an average age of 24.14286 (range: 15–49) years. and there are differences between male and female trachea and differences between small children and adult in anatomy of trachea, pediatric trachea does not tolerate tension, Up to half percentage of the adult trachea can be resected whereas in children closer to 30%.

Thus, our study and other studies confirm the high efficiency of tracheal resection and re anastomosis in the treatment of tracheal stenosis, particularly third and fourth grade. Our success rate is slightly higher than other studies due to careful patient selection, judicious surgical technique, and good postoperative care and follow up.

### CONCLUSION

Through this study, we concluded that Tracheal excision and anastomosis is a relatively risk-free surgical treatment for treating grade two iatrogenic tracheal stenosis that has not responded to endoscopic treatment, as well as grade three and four iatrogenic tracheal stenosis. Male patients benefit the most from this procedure when the stenosis is short and does not involve the cricoid cartilage. The degree of stenosis or the number of prior endoscopic treatments had no effect on surgical results.

Conflict of interest : none

### REFERENCES

1. Wain JC. Postintubation tracheal stenosis. *Semin Thorac Cardiovasc Surg.* 2009; 21: 284–9.
2. Monnier P. Subglottic and tracheal stenosis. In *Surgery of larynx and trachea.* Springer, Berlin, Heidelberg. 2009; 137-58.
3. Yamamoto K, Kojima F, Tomiyama K, et al. Metaanalysis of therapeutic procedures for acquired subglottic stenosis in adults. *Ann Thorac Surg.* 2011; 91: 1747–53.
4. Bibas BJ, Terra RM, Junior AL, et al. Predictors for postoperative complications after tracheal resection. *Ann Thorac Surg.* 2014; 98: 277–82.
5. Zeeshan A, Detterbeck F, Hecker E. Laryngotracheal resection and reconstruction. *Thoracic Surgery Clinics.* 2014; 24(1): 67-71.
6. Nandakumar R, Jagdish C, Prathibha CB, et al. Tracheal resection with end-to-end anastomosis for post-intubation cervical tracheal stenosis: study of 14 cases. *J Laryngol Otol.* 2011; 125: 958–61.
7. Gozen ED, Yener M, Erdur ZB, et al. End-to-end anastomosis in the management of laryngotracheal defects. *The Journal of Laryngology & Otology.* 2017; 131(5): 447-54.
8. Marques P, Leal L, Spratly J, et al. Tracheal resection with primary anastomosis: 10 years experience. *Am J Otolaryngol.* 2009; 30: 415–418.
9. El-Fattah AM, Kamal E, Amer HE, et al. Cervical tracheal resection with cricotracheal anastomosis: experience in adults with grade III–IV tracheal stenosis. *The Journal of Laryngology & Otology.* 2011; 125(6): 614-9.
10. Grillo HC and Donahue DM. Post intubation tracheal stenosis. *In Seminars in thoracic and cardiovascular surgery.* 1996; 8(4): 370-80.
11. Aleksanyan A, Stoelben E. Die laryngotracheale Resektion als Alternative zum permanenten Tracheostoma. *Pneumologie.* 2019; 73(4): 211-8.