

RADIOGRAPHIC EVALUATION OF CRESTAL BONE LOSS AROUND ONE- PIECE VERSUS TWO-PIECE IMPLANT WITH BAR RETAINING MANDIBULAR OVERDENTURE. (A RANDOMIZED CLINICAL TRIAL)

Amr Mohamed Ismail Badr* and Mohamed Zaki**

ABSTRACT

Two mandibular splinted implants offer better denture support and load distribution.

Methodology: completely edentulous patients divided into two groups receiving two implants at canine region splinted by bar, group I (two-piece implant) and group II (one-piece implant). Radiographic assessment of marginal bone loss mesially and distally to implants in both groups was measured using Digora software.

Purpose: was to evaluate and compare the effect of using one -piece versus two-piece implants with bar retaining mandibular overdentures on the crestal bone loss.

Results: A statistically significant increase of marginal bone loss after 3,6,9 and 12 months within each group and also between the one-piece and two- piece implant groups favoring the one-piece group which gives less crestal bone loss.

Conclusion: within the limitation of this study it was concluded that: both implant systems reveal high success rate and within range crestal bone loss over a one-year follow-up study but in favor of the one-piece implant design.

KEYWORDS: one-piece and two-piece dental implants; bar and clip; mandibular overdenture; crestal bone loss.

* Associate Professor, Prosthodontics Department, Faculty of Dentistry, Minia University

** Assistant Professor, Prosthodontics Department , Faculty of Dentistry, Pharos University

INTRODUCTION

Edentulism is a complicated status that leads to several intra-oral changes as progressive alveolar bone loss, impaired chewing ability, poor esthetics and phonetics and finally affects the psychological status of the patient.¹

The traditional lines of treatment for completely edentulous patients is conventional denture however the adaptation to complete dentures is a complex process.²

With further bone resorption; stability and retention of the denture are severely affected resulting in, discomfort, diminished biting force, chewing ability and defected esthetics with senile appearance. As a sequela of that; patients reveal dissatisfaction especially with mandibular dentures, making them seeking a denture replacement.³

Implant retained overdenture proved to be a predictable method in the management of edentulous patients.⁴

It was well known that placement of two interforaminal implants for the retention of a mandibular overdenture is considered the golden standard for rehabilitation of edentulism.⁵

Implant retained overdenture with bar and sleeve is preferred as much cheaper alternative to those of fixed-prosthetic implant restorations, offers retention and stability and can be removed at night. Also, the exact implant position to obtain the ideal aesthetics is not such critical as in case of fixed prosthesis.⁶

In a systematic review in 2011 stumpies et al, reported that; no significant difference in the peri-implant outcome, soft tissue health status or patient satisfaction between splinted and un-splinted designs.⁷

However, Bar attachment provides better advantages as It acts as a splint between abutments, distribute stresses between implants, can also provide either rotational movement between the

bar and the overlying sleeve (bar joint) also can overcome the problem of divergence between implants or the non-parallel implants.⁸

Crestal bone level is one of the important measuring data for implant success and many factors can affect this bone level. one of these factors is the implant type either one- piece or two-piece implant

One piece-implant has the advantage of no second surgery after osseointegration and two-piece implant has the advantage of being submerged preventing the bacterial invasion.

Therefore, the purpose of this study was to evaluate and compare the effect of using one -piece versus two-piece implants with bar retaining mandibular overdentures on the crestal bone loss.

MATERIAL AND METHODS

Study protocol

A Prospective comparative study was conducted on 14 completely edentulous patients 10 males and 4 females. they selected from the Department of Prosthetic Dentistry, Faculty of Dentistry, Minia University. each patient received an implant with bar retained mandibular overdenture which fabricated by minimally invasive flapless surgical technique.

The study was performed after gaining the approval of the research ethics committee. Patients were informed about the research procedures and follow-up examination schedule. Informed consent was signed by each patient in accordance with the regulation of the Ethics Committee in Faculty of Dentistry, Minia University.

The participating subjects in this study were selected according to the following inclusion and exclusion criteria:

Inclusion criteria

patients age ranging from 55-65 years old, sufficient residual alveolar bone quantity and quality as determined by CBCT, Maxillary and

mandibular residual alveolar ridges covered with healthy firmly attached mucosa, U-shaped lower ridge, Angle's class I maxilla-mandibular relation, Sufficient interarch space greater than 12 mm and good oral hygiene.

Exclusion criteria

Temporo mandibular joint or neuromuscular disorders, Bone metabolic disorders e.g. Uncontrolled Diabetes, History of radiation therapy in the head and neck region and abnormal habits, e.g. bruxism, clenching, smoking and alcoholism.

Before any intervention, all patients were thoroughly evaluated medically and dentally by a sheet record which was registered for each patient.

All patients who participated in the study received:

Cone-beam computed tomography (CBCT) (SORDEX 3DX. Nahkelantin 160, Tuusula. P.O. Box 148, F1-04301 Tuusula. Finland) to check the quality and quantity of the available alveolar bone at the planned implant site.

Panoramic Radiograph to give an overall view of the cases and to exclude the presence of impaction, remaining roots and any pathological condition.

Conventional Complete maxillary and mandibular dentures before surgeries were fabricated for every patient with all the conventional steps of construction in addition to over contouring of waxing-up at the lingual flange opposite to the area of bar and abutments.

Computer-generated surgical guides were fabricated using CAD/CAM technology. Fabricated surgical guides were made from clear acrylic resin and containing two metallic sleeves, over the virtually planned implants sites. Three lateral anchor pins with cylinders were provided in each guide to allow for fixation.

For randomization a software program was used (Minitab 17.0, Pennsylvania, USA). All patients were randomly divided into two equal groups

(seven patients each).group A Received one piece implant inserted at the cuspid region bilaterally (screw indirect one-piece implant system -Spectra system, implant direct LLC, 27030 Malibu Hills Road, Calabasas Hills, CA 913101, US) while group B received two piece implants (screw plant two-piece implant system -Spectra system, implant direct LLC, 27030 Malibu Hills Road, Calabasas Hills, CA 913101, US) inserted at the cuspid region bilaterally. For standardization, all implants were of the same length (13 mm) and the same diameter (3.7 mm).

Surgical stage

Infiltration anesthesia was injected to the planned implant sites.

To dissect the gingival tissue covering the planned implants sites Punch technique⁹ via 5 mm diameter tissue punch was used.

With the surgical guide seated in place intra-orally, three holes were drilled through the lateral cylinders of the guides, to allow for the insertion of the anchor pins for the fixation of the surgical guide thought-out the drilling steps.

Drilling started with the pilot drill till the final drill at the planned implants' sites bilaterally using serial drills (2.3, 2.8 and 3.4-mm drills respectively) to the proper depth marked on the drills which is 13 mm.

Surgical guide was removed after complete osteotomy preparations and implants were inserted as decided

The implants were inserted first manually then complete implant placement was done flushing with the bone crest using the torque wrench.

Denture relining

Relief the fitting surface of the denture opposite to the implant sites.

Application of tissue conditioning material (Alpha dent products Co., subsidiary of Wallace A.

Erickson & Co. 1920N. Clybourn Ave., Chicago, IL 60614, USA) to the fitting surface of mandibular denture to avoid tissue traumatization or implant overloading.

Bar attachment fabrication:

A plastic castable abutment was fastened to each implant head using fixation screw.

A ready-made plastic bar (bar joint design) was placed between the two copings and its length was marked and modified.

Retaining slots were made in the mesial aspect of each plastic abutment using a fissure or round bur. These prepared slots guided the bar positioning occluso-gingivally and facilitated its fixation.

Burn-out self-cured acrylic resin (Duralay, Reliance Dental Manufacturing Co., Chicago, USA.) was used for bar fixation with the two plastic abutments (**fig 1A&B**)

The two fixation screws were removed and the whole assembly was removed as one piece; after setting of the burn-out self cured acrylic resin.

The two plastic burn-out abutments and bar assembly were cast as one piece into cobalt chromium alloy (Niadure, DFS Diamon, Germany) by the commonly recommended casting technique. Trial insertion with passive fitness of the bar was checked intraorally by using the one screw test. (**fig 2A&B**)

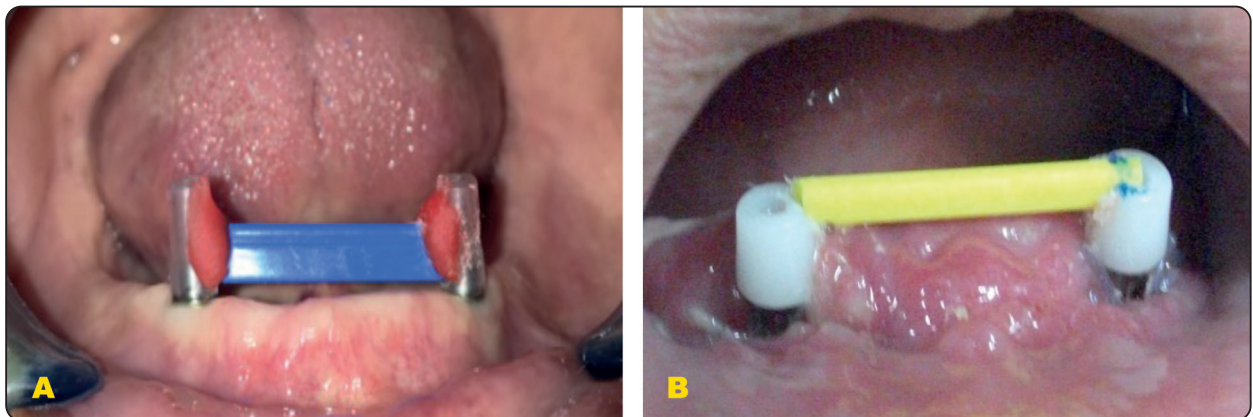


Fig. (1) A) burn-out plastic bar is adjusted between the two plastic abutments and fixed in position with duralay in two-piece implants group. B) burn-out plastic bar is adjusted between the two plastic abutments and fixed in position with duralay in one-piece implants group.

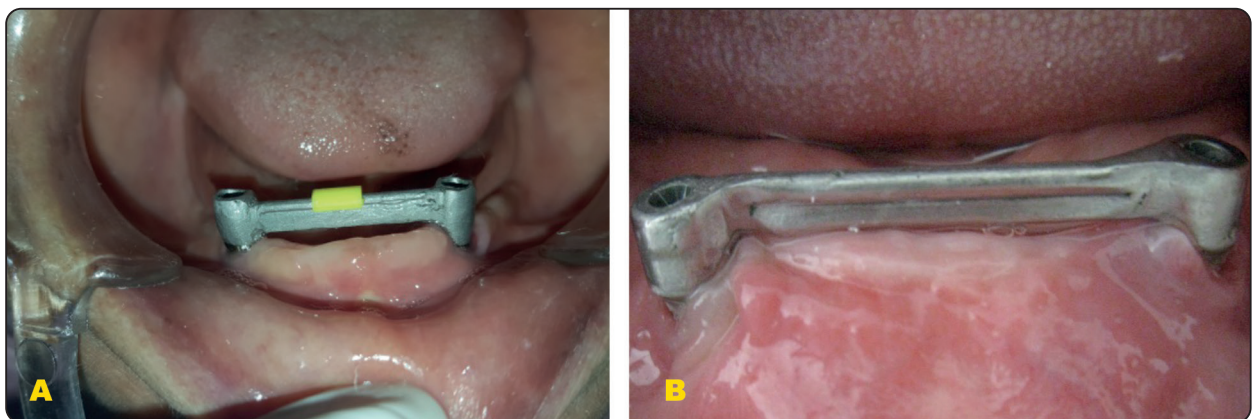


Fig. (2) A) The metallic bar was finished and polished then screwed onto the two-piece implants intraorally. B) The metallic bar was finished and polished then screwed onto the one-piece implants intraorally.

Direct pick-up of attachments to the existing Mandibular Complete Denture:

The intra-oral direct picking-up procedure was typically the same for both groups. The idea of that was to attach the sleeve to the fitting surface of the mandibular denture under maximum biting force.

The metal sleeve with its plastic clip was attached on top of the bar.

A relief room in the denture fitting surface was created opposite to the bar and abutments to allow for complete seating of the denture. In addition, two small holes were created at the lingual flange for excess pick-up material escape.

The undercuts beneath the bar and copings was blocked out using smooth casting wax (Glattes Gusswachs, smooth casting wax 0.3 mm., Ref. no. 40092, BEGO, Germany).

The direct picking-up was made by using cold curing Methyl Metha Acrylate monomer-free and heat free rebase material (Tokuyama Rebase II Fast, Tokuyama Dental Corporation, Japan). Hence the rebase material was set; finishing and polishing of denture was made and final occlusal adjustments were done.

Radiographic evaluation:

The peri-implant bone changes mesial and distal to the implants were monitored by peri-apical radiographs taken with standardized long cone paralleling technique.¹⁰

Radiographic stent or template was used for standardization.

On Digora software (fig. 3), linear measurements were obtained by calculation of: length of radiographic individual implant, length of mesial and distal crestal bone height from the 1st implant thread to the most coronal portion of the crestal bone.

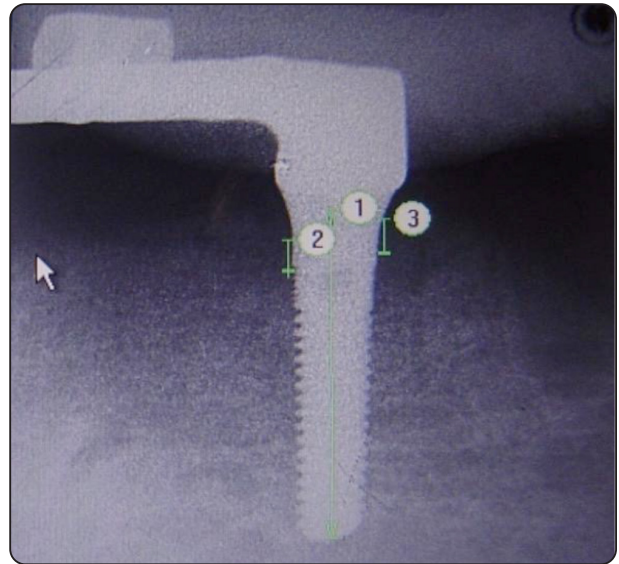


Fig. (3) periapical radiograph for measuring the crestal bone loss.

RESULTS

As both implants right and left are at the same position at canine region; After statistical comparison between the marginal bone loss at each side

There was no statistically significant difference. Accordingly, the data of right and left implants in both groups were added together and presented in the form of mean and standard deviation.

The results of mean marginal bone loss in each group were affected by time; in another way there was a statistically significant increase of marginal bone loss after 3,6,9 and 12 months at each group as shown in (Table 1).

Also comparing the marginal bone loss between the two groups

At each follow-up interval; there was a statistically significant difference

Between the both groups. As the less mean values recorded at the one-piece implants while is slightly higher in two-piece implants group. (fig.4)

TABLE (1): Comparison between mean values of marginal bone loss in group I (two- piece implant) and group II (one-piece implant) at different follow up intervals.

	Maginal Bone loss	At Insertion	After 3 months	After 6 months	After 9 months	After 12 months	p-value
Two -pieces	Mean	0	0.539 ^b	0.664 ^c	0.786 ^d	0.900 ^e	0.01*
	S.D.	0	0.028	0.044	0.038	0.036	
One – piece	Mean	0	0.299 ^a	0.494 ^b	0.681 ^c	0.802 ^d	0.01*
	S.D.	0	0.031	0.032	0.038	0.021	
	p-value	1	0.01*	0.022*	0.035*	0.034*	

* significant at level 0.05

*Means with Common letters are not significant

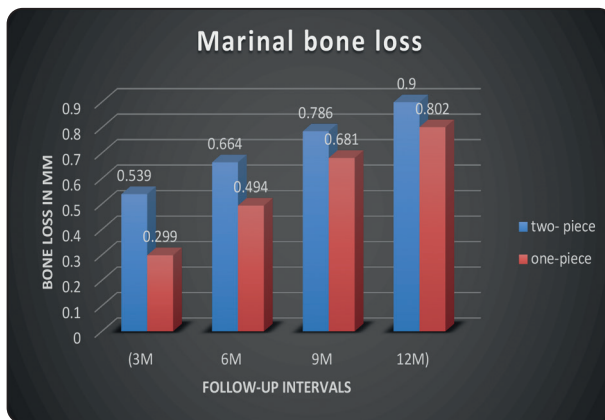


Fig. (4) Bar chart comparing the crestal bone loss in both groups during the whole follow-up intervals.

DISCUSSION

This study was to evaluate immediately loaded single piece versus two-piece implants connected together with co-cr bar joint attachment on the supporting structures.

Only two inter-foraminal implants with bar were used in the current study, as it is considered the standard for mandibular overdentures especially when the opposing arch is rehabilitated with conventional complete denture.

The insertion of two implants in the mandibular edentulous jaw is considered the standard, changing the mode of support to be implant mucosa supported instead of totally mucosa supported as in

cases of complete denture. this mode change may help to relieve the ridge mucosa, especially at the anterior mandibular ridge from excessive pressure, diminishing the susceptibility of trauma and sore spots which are common complaints in conventional complete dentures wearers.

Standardization of all other factors as bone density, implant stability. Implant length and patients' arch size and shape is very important to clarify the effect on the marginal bone loss.

Flapless implant installation with CAD/CAM surgical guide simplify the implant placement accurately and ensure the implants parallelism.

Splinting of implants may help in stress reduction around implants and distribute the load widely between them. So the free-standing implants can relatively have subjected to more stresses than that of splinted ones.

All patients strictly instructed to use soft tooth brush regularly and interdental brushes under the bar and to follow the oral hygiene measures.

The crestal bone area is considered the prime indicator of implant success. As this area bears the maximum stresses around implants, moreover it is the area of plaque accumulation.

In the current study, all the implants were successful clinically and radiographically. All the cases presented with high success rate as: no clinical mobility, peri-implant radiolucency, pain or paresthesia.

As there is no implant mobility, pain or paresthesia, no radiolucency and within the first-year marginal bone loss doesn't exceed 1mm in both groups.

It is worthy to mention that no implants showed any degree of peri-implant radiolucency and/or any degree of clinical mobility as this is considered a failure.

Long cone paralleling periapical radiography technique was used in this study for standardization, less radiation exposure and accurate determination of bone loss.

General speaking, no implant failure was detected and all patients participated in this study were satisfied with their dentures nearly to the same extent.

This study is followed for only 12 months which is a reasonable period to give an idea about the behavior of bone towards these treatment modalities; however, longer periods of follow up are necessary to reach a final conclusion.

The low levels of crestal bone loss in both groups could be attributed to: flapless placement of implants which minimize the disruption of periosteum, preservation of blood supply.

One-piece dental implant introduced with the aim of simplifying and increasing the effectiveness of treatment surgery and has been providing greater comfort for the patient.

One-piece implant systems were fabricated to minimize crestal bone resorption based on the theory that bacterial colonization at implant-abutment junction and violation of the biological

width are the main causes of initial bone loss in two-piece implants.

More and above, shifting the implant-abutment connection to a supra-crestal position permits the patient to perform a good oral hygiene measures and diminish the effect of plaque accumulation thus limiting the crestal bone loss at the one-piece implants.

Both implant systems reveal high survival rates on the implant and prosthetic level. Both groups showed no clinical nor radiographic signs of mobility or implant failure. according to retrospective studies, average crestal bone loss adjacent to implants of approximately 1.2 mm 1.5 mm at the end of the first-year and 0.1 mm annually were reported successfully.¹¹

Two piece implants showed significant crestal bone loss than that of one piece implants, this might be attributed to the micro-gap.¹²⁻²⁰

This was in agreement with Hermann js, et al in 1997 who demonstrated that the rough/smooth implant interface as well as the location of the micro-gap has a significant effect on marginal bone resorption as evaluated by standardized peri-apical long cone radiography.¹⁴

Several studies investigated the effect of using one versus two-piece implant with ball attachment retaining mandibular overdentures; reveal that there was insignificant difference between the two implant designs.²¹⁻²³

CONCLUSION

Through limitations of this study it was concluded that:

Both implant designs reveal high success rate and within range crestal bone loss over a one-year follow-up study but in favor of the one-piece implant.

REFERENCES

1. Mañes JF, Selva EJ, De-Barutell A, Bouazza K. Comparison of the retention strengths of three complete denture adhesives: an in vivo study. *Med Oral Patol Oral Cir Bucal*. 2011 Jan 1; 16(1):e132-6.
2. Jallad WA, Owda J. Implant Overdenture - A Review to Highlight the Concept. *J Dent Oral Health Cosmesis* 2020;5: 015.
3. Yu-Haw pan, Lance C. Ramp, Perng-Ru Liu: Patient Responses to Dental Implant-retained Mandibular Overdenture Therapy: A 6-year Clinical study, *Chang Gung Med J* 2007; 30:363-369.
4. Raghoebar GM, Friberg B et al. 3-year prospective multicenter study on one-stage implant surgery and early loading in the edentulous mandible. *Clin Implant Dent Relat Res*. 2003; 5(1): 39-46.
5. The McGill consensus statement on overdentures. Mandibular two-implant overdentures as first choice standard of care for edentulous patients. Montreal, Quebec, May24-25, 2002
6. Bueno-Samper A, Hernández-Aliaga M, Calvo-Guirado JL.: The implant supported milled bar overdenture: A literature review. *Med Oral Patol Oral Cir Bucal*.2010; 15 (2):375-378.
7. Stoumpis C, Kohal RJ. To splint or not to splint oral implants in the implant-supported overdenture therapy? A systematic literature review. *J Oral Rehabil*. 2011; 38(11): 857-869.
8. Carpentieri J. Treatment options for the edentulous mandible: clinical application of the twoimplant overdenture. *Pract. Proced. Aesthet. Dent*. 2004 Mar; 16:105-112,114.
9. Lee DH,Jeong SM, Xuan F, Kim HR, Mo DY. Effects of soft tissue punch size on the healing of peri-implant tissue in flapless implant surgery. *Oral Surg Oral Med Oral Pathol Oral Radiol Endod*.2010; 109:525-30.
10. Plotnick I., Beresin V. and Simkins A.: A technique for standardized serial dental radiographs. *J. Clin. Periodont*.5: 297-299, 1971.
11. Wowern N, Gotfredsen K. Implant supported overdentures, a prevention of bone loss in edentulous mandibles? *Clinical Oral Implants Research*. 2001; 12: 19-25.
12. Jang BJ, Pena ML, Eskow R, Elian N, Cho SC, et al. (2008) The effect of implant design on crestal bone levels. 23rd Annual Meeting of Academy of Osseointegration in Boston.
13. Parel SM, Schow SR. Early clinical experience with a new one-piece implant system in single tooth sites. *Journal of Oral and Maxillofacial Surgery*. 2005; 63: 2-10.
14. Hermann JS, Cochran DL, Nummikoski PV, Buser D. Crestal bone changes around titanium implants. A radiographic evaluation of unloaded non submerged and submerged implants in the canine mandible. *Journal of Periodontology*. 1997; 68: 1117-1130.
15. Broggini N, McManus LM, Hermann JS, Medina RU, Oates TW, et al. Persistent acute inflammation at the implant-abutment interface. *Journal of Dental Research*. 2003; 82: 232-237.
16. Jones AA, Cochran DL. Consequences of implant design. *Dental Clinics of North America*. 2006; 50: 339-360.
17. Quirynen M, Van Steenberghe D. Bacterial colonization of the internal part of two-stage implants. An in vivo study. *Clinical Oral Implants Research*. 1993; 4: 158-161.
18. Jansen VK, Conrads G, Richter EJ. Microbial leakage and marginal fit of the implant-abutment interface. *International Journal of Oral and Maxillofacial Implants*. 1997; 12: 527-40.
19. Callan DP, Cobb CM, Williams KB. DNA probe identification of bacteria colonizing internal surfaces of the implant abutment interface: A preliminary study. *Journal of Periodontology*. 2005; 76: 115-120.
20. Do Nascimento C, Pedrazzi V, Miani PK, Moreira LD, de Albuquerque Junior RF. Influence of repeated screw tightening on bacterial leakage along the implant-abutment interface. *Clinical Oral Implants Research*. 2009; 20: 1394-1397.
21. João Pedro et al. A clinical comparison of 1-piece versus 2-piece implants: A systematic review and meta-analysis *The Journal of prosthetic dentistry* 124(4) December 2019
22. El damarisy el al. Effect of One Piece versus Two Piece Mini Implants on Bone Height of Implant Retained Mandibular Overdenture. *J oral health and dental management*. 2017;16(4)
23. Wu AY, Hsu JT, Chee W, Lin YT, Fuh LJ, et al. Biomechanical evaluation of one-piece and two-piece small-diameter dental implants: In-vitro experimental and three-dimensional finite element analyses. *Journal of the Formosan Medical Association*. 2016; 115: 794-800.