

## A comparative Study between Laparoscopic Nissen and Toupet Fundoplication in Management of Hiatus Hernia

General Surgery

Mahmoud Nabih Abdel Fattah Ghazy El-Basiouny<sup>1\*</sup> M.B.B.Ch, Mohamed Ibrahim El-Anany<sup>1</sup> MD and Ahmed Abd El Aal Elsayed Sultan<sup>1</sup> MD

### \*Corresponding Author:

Mahmoud Nabih Abdel Fattah Ghazy El-Basiouny  
[ahmeddr061@gmail.com](mailto:ahmeddr061@gmail.com)

Received for publication April 02, 2022; Accepted October 26, 2022;  
Published online October 26, 2022.

doi: 10.21608/aimj.2022.130497.1889

**Citation:** Mahmoud N. , Mohamed I. and Ahmed A. , A comparative Study between Laparoscopic Nissen and Toupet Fundoplication in Management of Hiatus Hernia. AIMJ. 2022; Vol.3-Issue10 : 182-186.

<sup>1</sup>General Surgery Department, Faculty of Medicine, Al-Azhar University Cairo, Egypt.

### ABSTRACT

**Background:** Gastroesophageal reflux disease (GERD) is a frequent clinical disorder characterized by the reflux of gastric constituents into the esophagus or oropharynx via lower esophageal sphincter (LES), leading to complications and/or injury to esophageal tissue fatal enough to disrupt a patient's life and necessitating long-term management with medicines and lifestyle changes.

**Aim of the work:** To evaluate and contrasting the surgical results of a 270° wrap (Toupet, T) versus a 360° wrap (Nissen, N) in patients with gastroesophageal reflux disease (GERD) in accordance with symptom alleviation, therapeutic response, and postoperative complications like dysphagia, gas bloat disorder, and recurrence.

**Patients and methods:** Laparoscopic antireflux surgery was performed on a sum of 20 individuals with extreme GERD and/or hiatal hernia. Participants were separated into two groups: group I underwent Nissen fundoplication, with ten patients, and group II underwent Toupet fundoplication, with ten patients. Age, gender, BMI, functional esophageal test before surgery, symptom alleviation, post-operative complications, and inpatient duration were all similar across the two groups.

**Results:** Toupet fundoplication (TF) was related with considerably reduced postoperative dysphagia than Nissen fundoplication in patients with GERD and concurrent preoperative esophageal dysmotility (NF).

**Conclusion:** The findings of this research show that laparoscopic fundoplication is a secure and effective management for GERD. Despite the fact that laparoscopic Nissen fundoplication is regarded the benchmark for anti-reflux surgeries, our research found that Toupet Fundoplication (TF) is linked with considerably reduced postoperative dysphagia in GERD patients than Nissen Fundoplication (NF).

**Keywords:** GERD; Nissen fundoplication; Toupet fundoplication; esophageal dysmotility; Antireflux surgery.

**Disclosure:** The authors have no financial interest to declare in relation to the content of this article. The Article Processing Charge was paid for by the authors.

**Authorship:** All authors have a substantial contribution to the article.

**Copyright** The Authors published by Al-Azhar University, Faculty of Medicine, Cairo, Egypt. Users have the right to read, download, copy, distribute, print, search, or link to the full texts of articles under the following conditions: Creative Commons Attribution-Share Alike 4.0 International Public License (CC BY-SA 4.0).

### INTRODUCTION

Gastroesophageal reflux disease (GERD) is a frequent clinical condition characterized by the reflux of gastric constituents into the esophagus or oropharynx via the lower esophageal sphincter (LES), producing discomfort and/or harm to esophageal tissue serious enough to disturb a patient's life.<sup>1</sup>

A combination of clinical manifestation, responsiveness to acidity suppression medication, and objective testing using a pH probe is used to diagnose GERD (upper endoscopy, esophageal pH monitor, Barium esophagram and esophageal manometry).<sup>2</sup>

GERD is a chronic illness that requires ongoing treatment with drugs and lifestyle changes. The natural history of GERD has most likely been altered by pharmacotherapy, notably the use of antisecretory drugs. Patients with severe illness, on the other hand, may benefit from surgery to avoid recurrence.<sup>3</sup>

Gastroesophageal reflux surgery attempts to correct anatomic and functional defects of the esophagogastric junction. Corrective techniques include the reduction of a hiatal hernia, the creation of a fundal wrap to enhance the lower esophageal sphincter (LES) and enhance its resting pressure, and the proximity of the diaphragmatic crura.<sup>4</sup>

Since 1991, laparoscopic surgery has been used to treat gastroesophageal reflux disorder (GORD). Because of the positive results of laparoscopic Nissen fundoplication (NF) in the treatment of

GERD, various Anti reflux treatments are now being performed laparoscopically. Toupet rear partial fundoplication (TF), anterior partial fundoplication (APF), and Hill gastropexy are some of the procedures available.<sup>5</sup>

### PATIENTS AND METHODS

The major reason for antireflux surgery is to enhance disease-related quality of life. Hunter, in 2000 listed the following indications for patients with GERD who are candidate for surgery which involves around 10-20% of GERD patients: Refractory to medical therapy: Persistent symptoms after 12 weeks of maximal medical therapies, recurrence upon cessation of medications, non-compliance with medical therapies or inability to tolerate medical therapies and patient requesting for surgery. Development of complications: like: Peptic stricture, intractable esophagitis, esophageal ulcers, Barrett's esophagus & bleeding and pulmonary complications (recurrent aspiration). Others: Patients with hiatal hernias have been proven endoscopically or radiologically (big hiatal hernia >5 cm) despite good medical care (Pharmaceutical costs are growing as a result of lifestyle changes, lifelong medical treatment, and higher doses)

**Inclusion criteria:** Patients with a preoperative diagnosis of GERD and inadequate symptoms and illness control may benefit from surgical therapy.

**Exclusion criteria:** Achalasia, morbidly obese individuals (BMI more than 35 kg/m<sup>2</sup>), recent upper abdominal surgery, and a severely shortened esophagus are all examples of esophageal motility problems.

**Sampling method:** All patients (convenience) undergoing surgical treatment for gastroesophageal reflux disease at Al-Hussein and Sayed Galal university hospitals, Faculty of Medicine, Al Azhar University, between June and December 2021.

**Preoperative evaluation:** The patient who has completely resolved symptoms when treated with contemporary anti-reflux medication is the greatest candidate for surgery. Specific anatomic and functional characteristics that may impact technical surgical decision-making should be the focus of preoperative examination, such as diagnosing GERD and excluding other conditions such as esophageal or stomach lesions, measuring reflux severity (in quantity and quality), and defining esophageal and gastroesophageal junction anatomy.

In general, numerous tests are employed to achieve these goals, the most common of which being contrast studies (with barium swallows) and endoscopy. Esophagogastroduodenoscopy, which includes a biopsy and histological study of the gastroesophageal junction, as well as esophageal manometry (for determining the exact position of the gastroesophageal junction and excluding primary motor impairments such as achalasia). When an obstructive or volvulized paraesophageal hernia is suspected, CT scanning might be beneficial. In most patients with great esophageal contractility and normal esophageal length, the laparoscopic Nissen fundoplication is the method of choice for a basic antireflux treatment.

**Technique: Surgical technique:** For both operations, LARS was quite standard. All of the

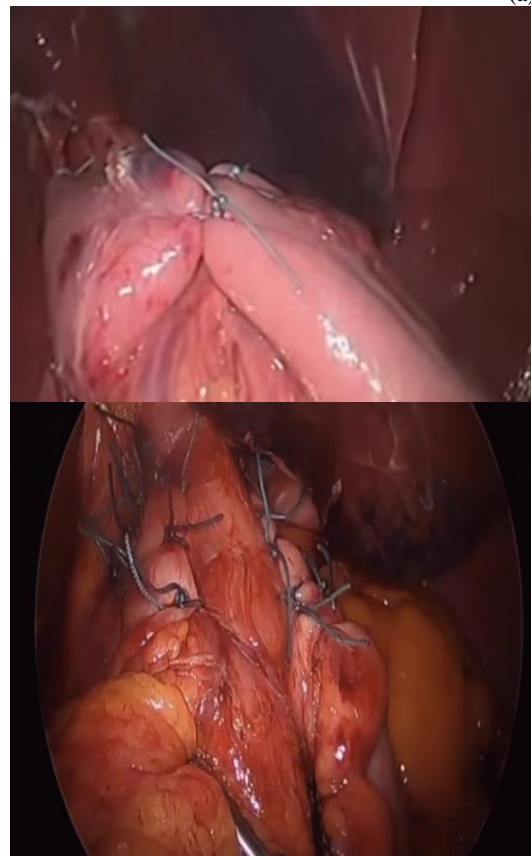
operations were done with the patient in a modified lithotomy posture and under general anesthesia. A total of six trocars were deployed. The diaphragmatic cruras were meticulously dissected in both procedures, as was the hiatal hernia's resection into the belly and crural repair with silk sutures. A V-shaped monofilament polypropylene graft was employed to create the graft (Prolene; Ethicon Ltd.).

#### Laparoscopic Nissen fundoplication

NF was accomplished by wrapping a 360 floppy wrap over a 60F esophageal bougie and using LigaSure to divide the small gastric arteries. Four/five stitches were used to secure a 1–2-cm short floppy wrap around the esophagus, two of them securing the anterior esophageal wall and two/three anchoring the right crura. (Fig. 1a).

#### Laparoscopic Toupet fundoplication

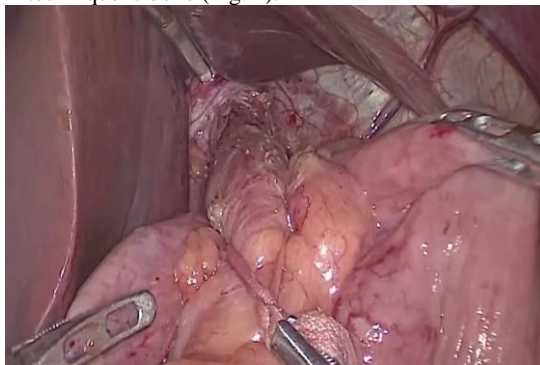
A posterior 270 wrap without bougie was used to accomplish TF. The choice to divide short gastric veins during the Toupet treatment was made based on the stomach fundus' mobility, and it was only used extremely seldom. Two/three sutures were used to secure the wrap's posterior (right) side to the right crura. After that, two/three silk sutures were used to secure the right side of the wrap to the esophagus. The left side of the wrap was secured to the anterior side of the esophagus with two or three sutures, and the top side of the wrap was secured to the upper border of the left crura with a single stitch (Fig. 1b).



**Fig 1:** (a) Nissen fundoplication. (b) Toupet fundoplication.

The surgeon decided whether or not to use drains. The patient is supine on the surgery table, arms tucked behind their backs. After intubation and induction of general anesthesia, a urinary catheter is

placed. The small intestine and omentum drop inferiorly when the top of the bed is raised 20°–30°, providing for the highest hiatal exposure. The hiatal closure may be stiff when correcting a large hiatal or paraesophageal hernia, but it should be rather flexible while doing a fundoplication, particularly in a patient with a motility problem like achalasia. The posterior wall of the fundus is grabbed and pulled behind the posterior vagus and posterior distal oesophagus to form a retroesophageal window. To ensure that there is no twisting of the oesophagus, a "shoeshine" technique is done (Fig. 2).



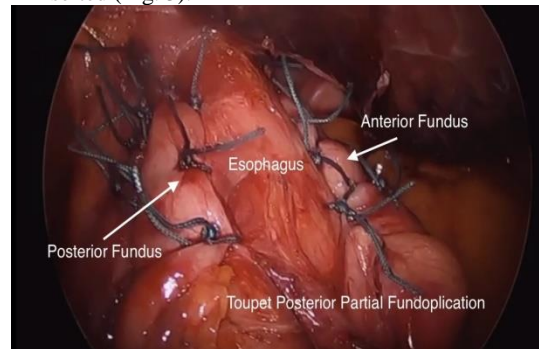
**Fig. 2:** "Shoe shine" maneuver (Broeders et al., 2011).

When the fundus is properly grabbed and pulled, it should lay to the right of the oesophagus without retreating.

The esophagus retracts and the posterior hiatus is exposed when the gastric fundus retracts towards the midline.

During posterior gastropexy, the posterior fundus is sutured to the inferior crus using one to three interrupted permanent sutures.

After that, a bougie is gently positioned. The shoulders of the fundus are secured to the diaphragmatic hiatus with two coronal sutures at 10 and 2 o'clock. Then, from the esophagus to the left and right fundus, two to three interrupted sutures are inserted (Fig. 3).<sup>6</sup>



**Fig. 3:** Completed posterior partial fundoplication (Broeders et al., 2011).

Statistical analysis: The statistical software for social sciences, version 20.0, was used to gather and preserve all data, containing demographics, perioperative information, operative/postoperative problems, and early/late outcome characteristics (SPSS Inc., Chicago, Illinois, USA). The mean and standard deviation were used to express quantitative data (SD). The frequency and percentage of qualitative data were used to represent the data.

**RESULTS**

The following tables and figures show the findings of the current research.

According to demographic statistics, there was no statistically substantial distinction between groups. Table (1)

Demographic data	Group I: Nissen (n=10)	Group II: Toupet (n=10)	t/x2#	p-value
<b>Age (years)</b>				
Mean±SD	34.70±7.12	36.00±7.59	0.156	0.697
Range	24-46	25-49		
<b>Sex</b>				
Female	5 (50.0%)	5 (50.0%)	0.000	1.000
Male	5 (50.0%)	5 (50.0%)		
<b>Residence</b>				
Giza	1 (10.0%)	0 (0.0%)	1.587	0.662
Kaliobeya	4 (40.0%)	5 (50.0%)		
Menoufia	4 (40.0%)	3 (30.0%)		
Sharqiya	1 (10.0%)	2 (20.0%)		

T-Independent Sample t-test; #x2: Chi-square test

P-value >0.05 NS

**Table 1:** Comparison of groupings based on demographic information

According to anatomical failure and recurrence, there was no statistically substantial distinction between groups.

Table (2)

	Group I: Nissen (n=10)	Group II: Toupet (n=10)	x2	p-value
<b>Anatomical Failure</b>				
Negative	10 (100.0%)	10 (100.0%)	0.000	1.000
Positive	0 (0.0%)	0 (0.0%)		
<b>Recurrence</b>				
Negative	10 (100.0%)	10 (100.0%)	0.000	1.000
Positive	0 (0.0%)	0 (0.0%)		

x2: Chi-square test; p-value >0.05 NS

Table (2): Comparison of groupings based on anatomical failure & recurrence

When compared to group II: Nissen, group I: Nissen had more symptoms relieved. According to Toupet, there is no statistically substantial distinction between groups in terms of symptom relief. Table (3)

Symptoms Relieve	Group I: Nissen (n=10)	Group II: Toupet (n=10)	x <sup>2</sup>	p-value
<b>Heart Burn</b>				
Negative	8 (90.0%)	5 (50.0%)	0.879	0.348
Positive	2 (10.0%)	5 (50.0%)		
<b>Regurge</b>				
Negative	9 (90.0%)	7 (70.0%)	0.312	0.576
Positive	1 (10.0%)	3 (30.0%)		
<b>Chest Pain</b>				
Negative	7 (70.0%)	8 (80.0%)	0.267	0.606
Positive	3 (30.0%)	2 (20.0%)		

**Table 3:** Comparison of groupings based on symptoms relieve

When compared to group II: Nissen, group I: Nissen had more problems. There is no statistically substantial distinction between groups when it comes to problems, according to toupet. Table (4)

Complications	Group I: Nissen (n=10)	Group II: Toupet (n=10)	x <sup>2</sup>	p-value
<b>Dysphagia</b>				
Negative	7 (70.0%)	8 (80.0%)	0.267	0.606
Positive	3 (30.0%)	2 (20.0%)		
<b>Chest pain on eating</b>				
Negative	7 (70.0%)	8 (80.0%)	0.267	0.606
Positive	3 (30.0%)	2 (20.0%)		
<b>Gas-Bloat</b>				
Negative	7 (70.0%)	9 (90.0%)	1.250	0.264
Positive	3 (30.0%)	1 (10.0%)		
<b>Postprandial fullness</b>				
Negative	1 (10.0%)	2 (20.0%)	0.392	0.531
Positive	9 (90.0%)	8 (80.0%)		
<b>Restriction in belching</b>				
Negative	5 (50.0%)	6 (60.0%)	0.202	0.653
Positive	5 (50.0%)	4 (40.0%)		
<b>Increased flatus</b>				
Negative	1 (10.0%)	2 (20.0%)	0.392	0.531
Positive	9 (90.0%)	8 (80.0%)		

x<sup>2</sup>: Chi-square test; p-value >0.05 NS

**Table 4:** Comparison of groupings based on complications

## DISCUSSION

The ultimate objective of Laparoscopic Anti-reflux Surgeries (LARS) is to enhance the Quality of Life (QoL) of GERD patients by reducing or eliminating reflux symptoms and reflux-related problems. However, whether subjective statements or objective examination results are more suited for assessing the success of laparoscopic anti-reflux surgery is a point of contention (LARS).

The result and postoperative complications of 20 patients who had Laparoscopic Nissen Fundoplication (LNF) and Laparoscopic Toupet Fundoplication (LTF) were investigated in this research. The following conclusions may be formed based on the results of this investigation. For starters, patient satisfaction was excellent and comparable across LNF and LTF (LNF, 89.17 percent ; LTF, 87.42 percent ). Second, in terms of symptom management, LTF was just as successful as LNF. Third, following LNF, the incidence of postoperative dysphagia was greater.

Although laparoscopic anti-reflux surgery may successfully reduce reflux symptoms, it is not without risks, the most prevalent of which is dysphagia.

A weaker LES is thought to be the cause of gastroesophageal reflux. Both LNF and LTF substantially decreased Lower Esophageal Sphincter Pressure (LESP) 6 months following surgery in the current investigation, however the improvement was greater with LNF than with LTF. It's unclear how much LESP is needed to prevent reflux while also preventing dysphagia. Furthermore, even though the rise in LESP after LTF was substantially lower than after LNF, it seemed to be adequate to avoid gastric reflux. The findings of this research also support the idea that LTF may help with GERD symptoms.

In contrast, Mickevicius et al. <sup>7</sup> study observed that the length of the wrap, not the kind of fundoplication, was shown to be the most important factor in postoperative dysphagia. Recent research, conducted by Qin et al. <sup>8</sup>, demonstrated that the prevalence of dysphagia was greater following LNF compared to

LTF in the near term (4 days after surgery), but the difference was dramatically reduced at 1 year after surgery.

Recurrence of GERD signs were not observed to be associated with GERD recurrent in this research. Acid reflux, esophageal hypersensitivity, persistent esophageal spasms, and aberrant tissue impedance may all cause GERD symptoms. Esophageal hypersensitivity may be a separate condition or it may coexist with GERD. It's a situation in which esophageal stimulation causes GERD symptoms but no damage to the esophagus. Patients with esophageal hypersensitivity, in other words, have a reduced threshold for perceiving physiological non – painful stimuli.

In our research, GERD symptoms (heart discomfort and regurge) reappeared in 30% of patients after LNF and 20% of patients after LTF. The DeMeester scores following LNF and LTF, on the other hand, were not measured. As a result, numerous recent articles have advocated that pH measurements, rather than subjective symptoms, should be used to detect GERD recurrence.<sup>9</sup>

Concerns about GERD recurrence has led surgeons to choose the Nissen approach over the Toupet approach for a long time. However, in our experience, there is insufficient evidence of reflux recurrence with LNF and LTF. Lack of objective testing and a short follow-up time. In contrast, Farrell et al.,<sup>10</sup> showed a greater likelihood of recurrence following LTF after one year, although the significance of their findings is hampered by considerable sample size discrepancies between the two groups. After Laparoscopic Anti-Reflux Surgery, the risk of postoperative heartburn and regurgitation is directly connected to the laparoscopic method and is currently extremely minimal in expert hands. To make an educated choice regarding these surgical alternatives, patients should be informed about the anticipated advantages of fundoplication on recurrence as well as the possible risk of complications.

The current research has certain limitations. The sample size was tiny, it came from just two centers, and all of the patients declined to have objective postoperative examinations. During the postoperative clinical examination, a subjective questionnaire was utilized to identify whether patients had dysphagia or not. Dysphagia was graded using a Likert scale. Furthermore, the follow-up was quite brief. Larger multicenter studies are needed to prove the effectiveness of these two methods in comparison.

### CONCLUSION

Finally, this research demonstrates that laparoscopic fundoplication is a secure and effective therapy for GERD. Technical considerations are critical for better results, with important factors being sufficient

intraabdominal esophagus formation, reduced hiatal dissection, tension-free and suitable orientation, and wrap alignment.

Conflict of interest : none

### REFERENCES

1. Aziz Q, Fass R, Gyawali CP. Esophageal disorders. *Gastroenterology*. 2016; 150:1368–79.
2. Katz PO, Gerson LB and Vela MF. Guidelines for the diagnosis and management of gastroesophageal reflux disease. *Am J Gastroenterol*. 2013; 108:308–28.
3. Gyawali CP and Fass R. Management of gastroesophageal reflux disease. *Gastroenterology*. 2018; 154:302–18.
4. Duke MC and Farrell TM. Surgery for gastroesophageal reflux disease in the morbidly obese patient. *J Laparoendosc Adv Surg Tech A*. 2017; 27:12
5. Gunter RL, Shada AL, Funk LM, Wang X, Greenberg JA, Lidor AO. Long-term quality of life outcomes following Nissen versus Toupet fundoplication in patients with gastroesophageal reflux disease. *J Laparoendosc Adv Surg Tech A*. 2021; 27:931–6.
6. Stefanidis D, Richardson W, Farrell TM. SAGES guidelines for the surgical treatment of esophageal achalasia. *Surg Endosc*. 2012; 26:296–311.
7. Mickevicius A, Endzinas Z, Kiudelis M. Influence of wrap length on the effectiveness of Nissen and Toupet fundoplication: a prospective randomized study. *Surgical endoscopy*. 2013; 22: 2269–76.
8. Qin M, Ding G and Yang H. A clinical comparison of laparoscopic nissen and toupet fundoplication for gastroesophageal reflux disease. *Journal of Laparoendoscopic & Advanced Surgical Techniques*. 2013; 23: 601–4.
9. Thompson SK, Jamieson GG, Myers JC. Recurrent heartburn after laparoscopic fundoplication is not always true reflux. *Journal of gastrointestinal surgery: official journal of the Society for Surgery of the Alimentary Tract*. 2017; 11(5): 642–7.
10. Farrell TM, Archer SB, Galloway KD. Heartburn is more likely to recur after Toupet fundoplication than Nissen fundoplication. *The American surgeon*. 2010; 66: 229–36.