



## Refractive changes with corneal incision 2.8mm after phacoemulsification

Somayya Mohammad Ahmed Mohamed Yasser Sayed<sup>a</sup> and Waleed Mohammed Mahran<sup>b</sup>

<sup>a</sup> Professor of ophthalmology Faculty of Medicine Beni Suf University, Egypt

<sup>b</sup> Lecturer of Ophthalmology Faculty of Medicine Beni Suf University, Egypt

### Abstract:

There are numerous techniques for dealing with astigmatism both during and after cataract surgery. Good uncorrected post-operative distance visual acuity can be obtained for high percentage of cataract patients with pre-existing corneal astigmatism. The goal of this study is to determine the keratometric change and resultant post-operative refraction of routine cataract patients, after a clear corneal incision of 2.8mm on the steeper meridian. Place and Duration of Study: This was a general free hospital-based prospective study. The study was started from May 2016 and was completed by May 2018. **Methodology:** A total of 30 cataract patients were included in this study. Pre-operative keratometric readings were compared with post-operative readings, after a clear corneal incision (CCI) of 2.8mm made during phacoemulsification procedure. **Results:** Patients were monitored for four weeks post-operatively. A total of thirty eyes underwent phacoemulsification cataract surgery with clear corneal incision on steep axis had mean residual astigmatism of 0.45 D and SD achieved 0.58.

### Keywords:

Clear corneal incision, incision on steep axis, phacoemulsification, and surgically induced astigmatism

## 1. Introduction:

A cataract is a clouding of the lens inside the eye which leads to a decrease in vision. It is the most common cause of blindness and is conventionally treated with surgery. Visual loss occurs because opacification of the lens obstructs light from passing and being focused on to the retina at the back of the eye. (1)

It is most commonly due to biological aging, but there are a wide variety of other causes. over time, yellow-brown pigment is deposited within the lens and this, together with disruption of the normal architecture of the

lens fibers, leads to reduced transmission of light, which in turn leads to visual problems.

(2). Those with cataracts commonly experience difficulty in appreciating colors and changes in contrast, driving, reading, recognizing faces, and coping with glare from bright lights.(3)

Ophthalmic astigmatism which the vertical and horizontal planes are identified as tangential and sagittal meridians, respectively. ophthalmic astigmatism is a refraction error of the eye in which there is a

difference in degree of refraction in different meridians. It is typically characterized by an aspherical, non-figure of revolution cornea in which the corneal profile slope and refractive power in one meridian is less than that of the perpendicular axis. (4) Astigmatism causes difficulties in seeing fine detail. Astigmatism can be often corrected by glasses with a lens that has different radii of curvature in different planes (a cylindrical lens), contact lenses, or refractive surgery. (5).

Astigmatism is quite common. Studies have shown that about one in three people suffers from it. The prevalence of astigmatism increases with age although a person may not notice mild astigmatism, higher amount of astigmatism may cause blurry vision, squinting, asthenopia, fatigue, or headaches. (6)

An optical system with astigmatism is one where rays that propagate in two perpendicular planes have different foci. If an optical system with astigmatism is used to form an image of a cross, the vertical and horizontal lines will be in sharp focus at two different distances. The term comes from the Greek  $\alpha$ - (a-) meaning "without" and  $\sigma\tau\acute{\iota}\gamma\mu\alpha$  (stigma), "a mark, spot, puncture".(7).

Phacoemulsification cataract surgery is a procedure in which an ultrasonic device is used to break up and then remove a cloudy lens, or cataract, from the eye to improve vision. The insertion of an intraocular lens (IOL) usually immediately follows phacoemulsification. (8)

Phacoemulsification is used to restore vision in patients whose vision has become cloudy from cataracts. In the first stages of a cataract, people may notice only a slight cloudiness as it affects only a small part of the lens, the part of the eye that focuses light on the retina. As the cataract grows, it blocks more light and vision becomes cloudier. As vision worsens, the surgeon will recommend cataract surgery, usually phaco, to restore clear vision. With advancements in cataract surgery such as the IOL patients can sometimes experience dramatic vision improvement. (9)

Modern extracapsular cataract extraction surgery involves removal of the lens fibers, which form the nucleus and cortex of the cataract, leaving the posterior capsule to hold the new artificial intraocular lens (IOL) and keep the vitreous humor away from the anterior chamber.

Extracapsular techniques of cataract extraction surgery originally involved manual nuclear expression. Phacoemulsification is a mechanically assisted extracapsular technique of cataract extraction surgery. (10)

Over the past several decades, a variety of materials and techniques have been implemented in the manufacturing of microsurgical blades (diamond, sapphire, black diamond, ceramic composites, stainless steel). The following are important properties that should be considered in these blades. (11) The sharper the blade the more control a surgeon has, there is reduced tissue trauma and the incisions are more reproducible. Two

techniques are employed to produce these blades. Hard crystalline blades made from different types of diamond and aluminum oxide are traditionally manufactured using a lapping process that can be thermally and chemically assisted. The manufacturing process involves initially cleaving the material along rough outlines of the desired shape. Once the rough shape is produced, grinding and lapping are used to manufacture the cutting edge.

The harder the material the sharper the blade and therefore diamond, being the hardest material known to man, produces the sharpest edge. (12)

Diamond blades can also be produced using lasers and acid to etch the edges which is a more economical process. The major drawback is that these laser and acid etched blades cannot be re honed and would need to be replaced if damaged. Stainless steel blades are manufactured through several different manufacturing processes. Traditionally, stainless steel blades were made through a multistep grinding and honing process that utilized methods such as ultrasonic slurring, mechanical abrasion, and lapping. This process can produce fairly high quality blades but suffers from large inconsistencies in blade quality and edge radius. (13)

More recently the manufacture of stainless steel blades has improved through the use of coining and electrochemical polishing. Coining is a cold forming process typically used to produce currency that involves

stamping steel into a near-net shape. The process is also easy to adapt to mass production for efficiency. After coining, the blades are cleaned up and sharpened using an electrochemical polishing technique. Despite these techniques, there remains some variation in quality and consistency from blade to blade and from manufacture to another. Ceramics and ceramic composites are currently developing but difficult to be designed as microsurgical blades. (14)

Access to the cataract is initiated through small incisions made into the peripheral cornea Known as Clear Corneal Incisions (CCI) they remain the preferred method for surgeons accessing the anterior chamber of the eye during cataract surgery. Previously large incisions (approximately 5-7mm in length) were made into the sclera these sutures need prolonged recovery. Routine CCIs are generally considered to be self-sealing. In comparison to scleral incisions, CCIs have reduced some potential complications and increase the speed of recovery. (15)

Routinely incisions are created manually by introducing a sharp, sterile blade into the cornea. Despite the perceived advantages of CCI's over large, scleral incisions there appears to have been an increase in the incidence of endophthalmitis , which has been directly linked to the use of these CCIs. (16)

The use of a manual blade makes it difficult to control the length and architecture of the incision which may affect the stability of the

wound under pressure. Following the surgery this could manifest by the corneal wound leaking increasing the potential risk of infection. Although the rate appears to be very low, endophthalmitis may be devastating with both clinical and financial implications arising from this complication. The additional cost of treating endophthalmitis. (17)

## **2. Patients and Methods:**

This was a general free hospital-based prospective study. About 30 patients were included in this study. All patients visiting the outpatients' clinic diagnosed with cataract. Pre-determined inclusion and exclusion criteria (as described below) were applied to all patients before a patient was accepted into the study to get 30 completed patients follow-up phase one month post-operative for every patient. The study was started from May 2016 and was completed by May 2018. Recruitment phase was two years follow up phase one month post-operative for every patient.

Pre-operative cataract evaluation included: measuring visual acuity by LogMAR chart, Cycloplegic refraction to rule out lenticular and corneal astigmatism. Corneal astigmatism by manual keratometry, we also ruled out conditions such as keratoconus and peripheral corneal degenerations. Slit lamp examination for cataract grading and funduscopy to exclude retinal pathology.

Inclusion criteria:

Patients in this study fulfilled the inclusion criteria namely

- senile cataract
- clear lens extraction

Exclusion criteria:

- Corneal opacity
- Patient with Keratocons
- Patient with pterygium
- Diabetics
- Thyroid disease
- Previous eye surgery
- Rheumatoid disease
- Eye trauma
- Corneal dystrophies

Written consent is taken from patient before the initiation of surgery, peribulbar anesthesia given, parts painted and draped, eye exposed with wire eye speculum. The incision was taken on steep axis, A 2.8mm keratome was used with entry is made on the steep axis, and the surgery is performed from that incision. Side port made at 90 from main incision, Visco injected in anterior chamber, capsulorhexies done with no. 26 bent needle\cystotome. hydrodissection done, phaco 1 used and trenching done, nucleus divided into 2, phaco 2 used and nucleus emulsified by stop and chop method, cortex irrigation aspiration done polishing of posterior capsule done, Visco injected, foldable hydrophilic PC IOL inserted in the bag, air bubble injected. Stromal hydration of all parts and main wound done with topical vegamox E.D, optipred E.D, eye patching done.

### 3. Results:

#### Statistical Analysis

Data were collected and coded to facilitate data manipulation and double entered into Microsoft Access and data analysis was performed using Statistical Package of Social Science (SPSS) software version 18 in windows 7.

Simple descriptive analysis in the form of numbers and percentages for qualitative data, and arithmetic means as central tendency measurement, standard deviations as measure of dispersion for quantitative parametric data.

Quantitative data included in the study was first tested for normality by one-Sample Kolmogorov-Smirnov test in each study group then inferential statistic tests were selected.

For quantitative parametric data:

In-depended student t-Test used to compare measures of two independent groups of quantitative data

Paired t-test in comparing two dependent quantitative data.

For qualitative data

Chi square test to compare two of more than two qualitative groups.

Mc-Nemar test for paired dependent qualitative data.

The P-value  $\leq 0.05$  was considered the cut-off value for significance.

**Table (1):** Description of demographic characters among study group.

Variables	Number (n=30)	
<b>Age (years)</b>		
Mean $\pm$ SD	59.9 $\pm$ 17.1	
<b>Sex</b>		
Male	20	66.7%
Female	10	33.3%

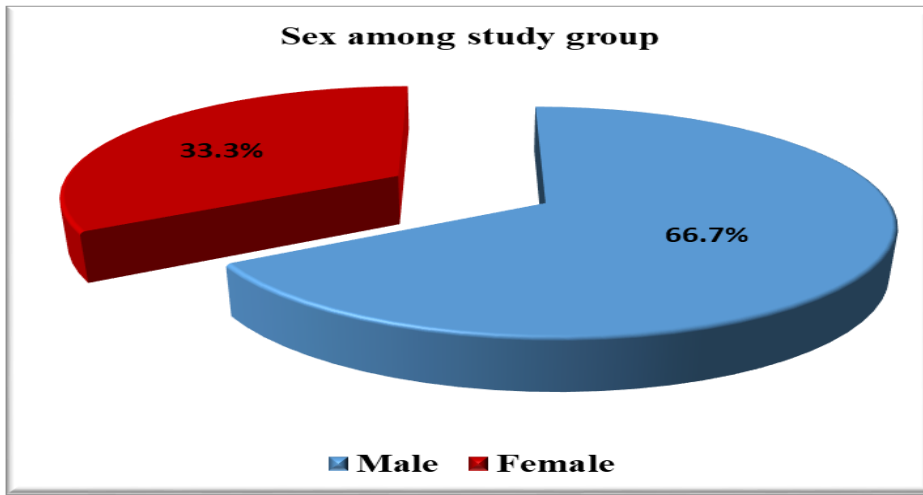


Figure (7)

Table illustrates that the mean age of study group was (59.9±17.1) years old, with 66.7% of them were males versus 33.3% were female.

Table (2): Description of side among study group.

Variables	Number (n=30)	%
Right	16	53.3%
Left	14	46.7%

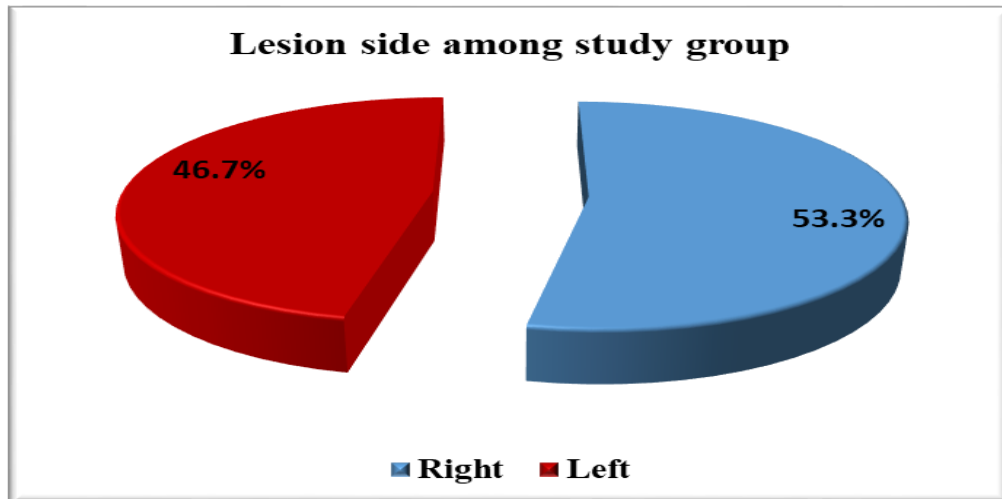


Figure (8)

Table illustrates that among study group 53.3% affected on right side versus 46.7% affected on left side.

**Table (3):** Description of K measure pre and postoperative among study group.

Variables	Mean	SD	Range
<b>Preoperative</b>			
K1	44.17	0.76	43-45.5
K2	44.4	0.57	43.75-46
<b>Postoperative</b>			
K1	44.08	0.78	43-45.25
K2	44.2	0.48	43.5-45.5

Table illustrates that the mean K1 measure preoperative was (44.17±0.76), and K2 preoperative was (44.4± 0.57). As regards postoperative K1 the mean was (44.08± 0.78), and mean K2 was (44.2± 0.48)

**Table (4):** Description of astigmatism measure pre and postoperative among study group.

Variables	Mean	SD	Range
<b>Preoperative</b>			
Astigmatism degree	-1.42	0.43	-2.25/-1
Astigmatism axis	122	53.6	35-180
<b>Postoperative</b>			
Astigmatism degree	-0.45	0.58	-1.25/0.75

Table illustrates that the mean astigmatism degree preoperative was (-1.42 ±0.43) with mean axis of (122±53.6), as regards mean astigmatism after operation was (-0.45±0.58).

**Table (5):** Frequency of visual accuracy level among study group.

Visual accuracy	Number (n=30)	%
<b>Preoperative</b>		
4/60	2	6.7%
5/60	14	46.7%
6/60	10	33.3%
6/36	4	13.3%

Postoperative		
6/36	8	26.7%
6/24	4	13.3%
6/18	10	33.3%
6/9	6	20%
6/6	2	6.7%

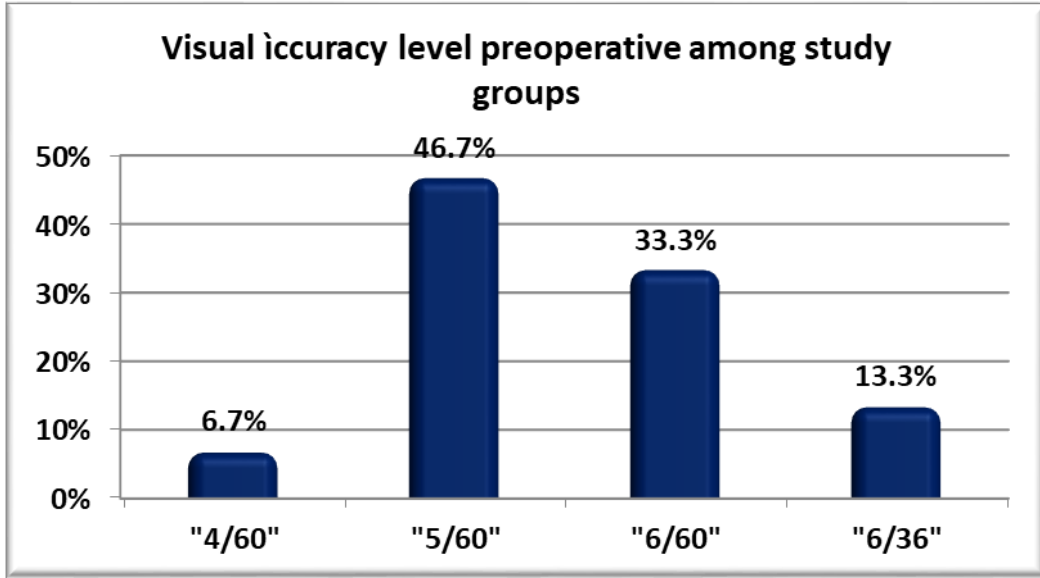


Figure (9)

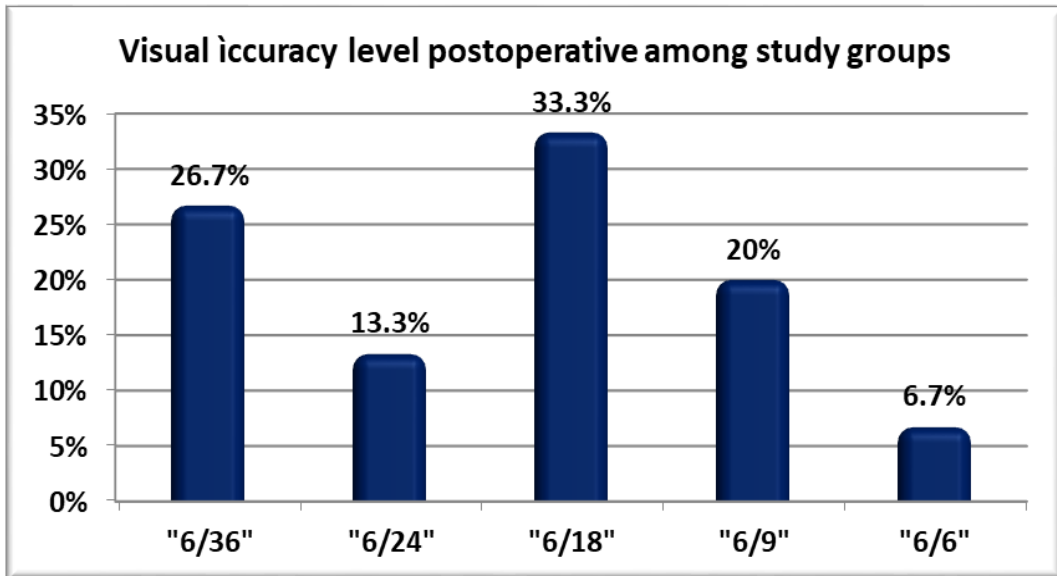


Figure (10)

Table illustrates that 46.7% of cases had visual accuracy of 5/60 before operation followed by 33.3% for 6/60, then 13.3% was 6/36, and 6.7% had visual accuracy of 4/60. But after operation the higher percentage of 33.3% was for 6/18, followed by 26.7% for measure 6/36, then 20% for 6/9, and 13.3% for 6/24, and finally 6.7% for measure of 6.6.



**Table (6):** Comparisons of K measure and astigmatism pre and postoperative among study group.

Variables	Preoperative		Postoperative		p-value	Sig.
	Mean	SD	Mean	SD		
<b>K1</b>	44.17	0.76	44.08	0.78	0.1	NS
<b>K2</b>	44.4	0.57	<u>44.2</u>	0.48	<b>0.001</b>	<b>hS</b>
<b>Astigmatism degree</b>	-1.42	0.43	<u>-0.45</u>	0.58	<b>0.001</b>	<b>hS</b>

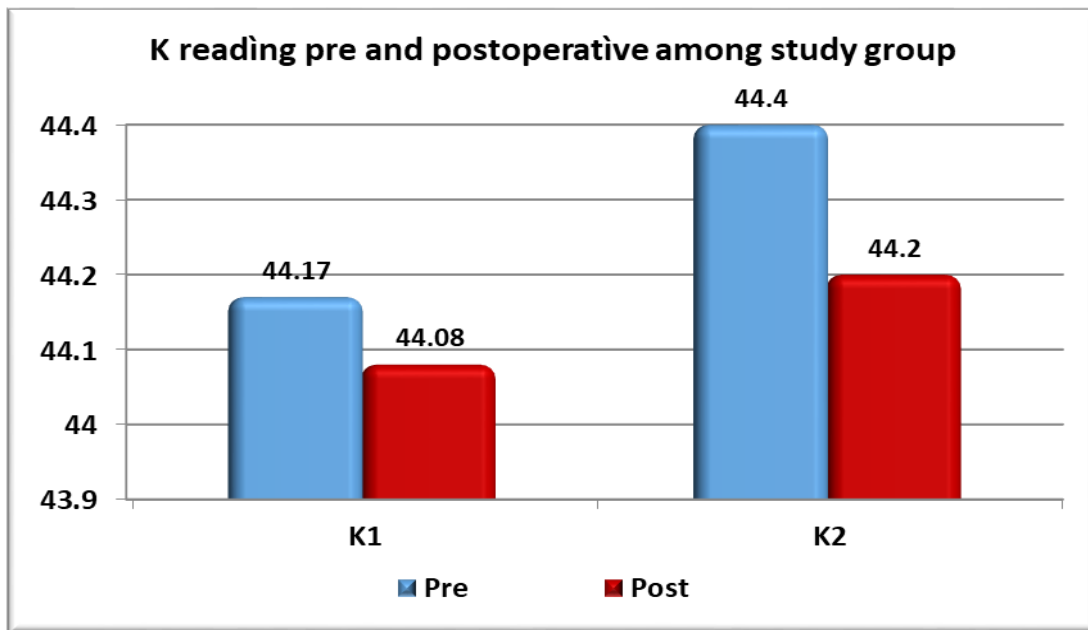


Figure (11)

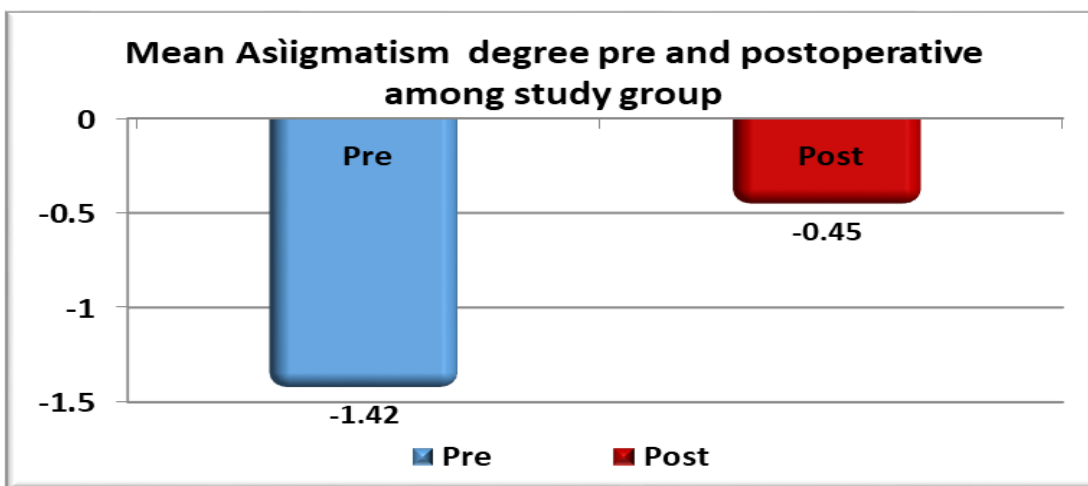


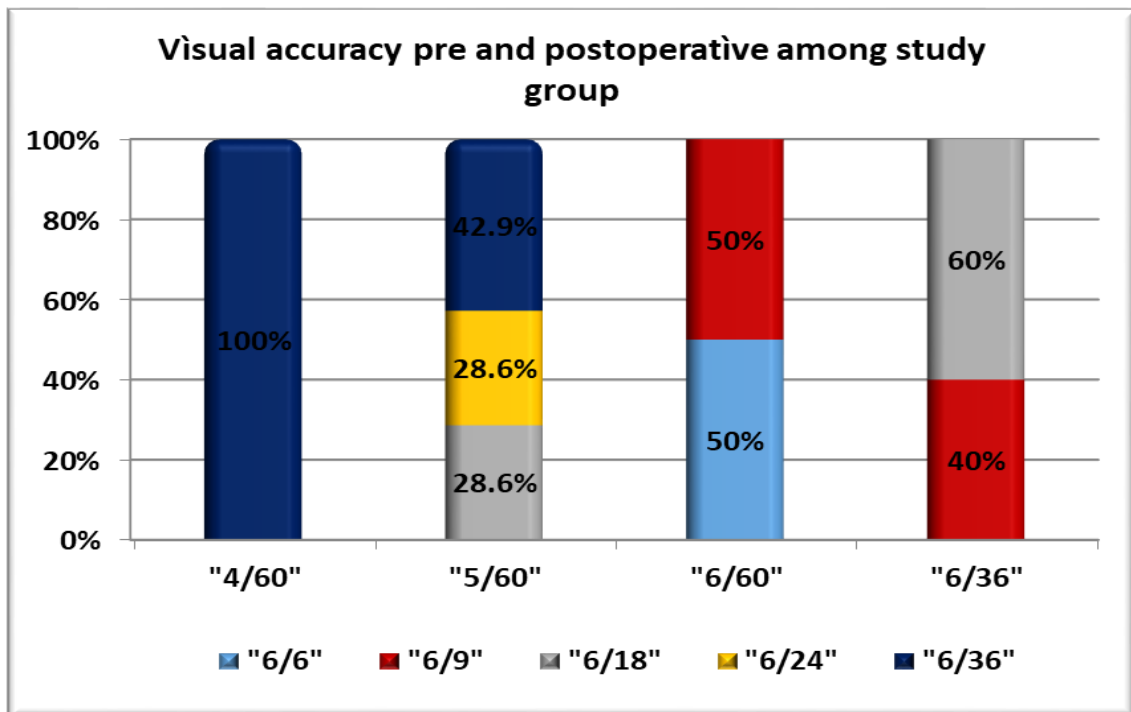
Figure (12)

Table illustrates that there is statistically significant **decrease** in K2 , and astigmatism degree after operation with p-value <0.05

on the other hand there is no statistically significant difference with p-value >0.05 as regards K1 reading after operation.

**Table (7):** Comparison of visual accuracy level among study groups.

Preoperative \ Postoperative	4/60 (n=2)	5/60 (n=14)	6/60 (n=10)	6/36 (n=4)	p-value	Sig.
	No. (%)	No. (%)	No. (%)	No. (%)		
6/6 (n=2)	0(0%)	0(0%)	<b>2(50%)</b>	0(0%)	<b>&lt; 0.001</b>	<b>hS</b>
6/9 (n=6)	0(0%)	0(0%)	<b>2(50%)</b>	<b>4(40%)</b>		
6/18 (n=10)	0(0%)	<b>4(28.6%)</b>	0(0%)	<b>6(60%)</b>		
6/24 (n=4)	0(0%)	<b>4(28.6%)</b>	0(0%)	0(0%)		
6/36 (n=8)	<b>2(100%)</b>	<b>6(42.9%)</b>	0(0%)	0(0%)		



**Figure (13)**

Table illustrates that there is statistically significant improvement in visual accuracy after operation with p-value <0.05; cases with 4/60 visual accuracy were improved to 6/36, patients with 5/60 visual accuracy improved to 6/36, 6/24, and 6/18; for patient with visual accuracy 6/60 were improved to 6/6 and 6/9, finally patients with 6/36 were improved to 6/9 and 6/18.

**4. Discussion:**

Phacoemulsification surgery is one of the most gratifying rehabilitative procedures, whereby a person may be relegated upto

complete 6/6 vision. Despite its great potential, cataract surgery has often in the past failed to achieve this target because of surgically induced astigmatism (SIA).

Recently, renewed interest has been directed towards the wound structure, starting from the vascular region because of its stability and rapidity of healing.

In our study we have found that a clear corneal incision on steep axis 2.8 mm incision hardly cause surgically induces any significant change in the existing preoperative astigmatism, i.e less than -0.45 diopters generally, when followed over long of time. This correlates with a similar study carried out by S C Moon (18).

Comparative study of the clear corneal incision trough steep meridian on phacoemulsification showed a keratometric average decreased by  $1.31 \pm 0.59$  diopters in superior clear corneal incisions and  $1.19 \pm 0.64$  diopters in temporal clear corneal incisions (19).

Research on the effects of incisions on phacoemulsification with a history of astigmatism was found that incision in steep meridian astigmatism was effective in reducing the history of astigmatism. The value of astigmatism before the operation was  $1.90 \pm 0.49$  diopters with a range of 1.20 to 3.25 D. Astigmatism decreased in 92.92% of eyes, increased in 3.53% of eyes and remained in 3.53% of eyes. In this research, keratometric changes by  $0.54 \pm 0.27$  diopters, which is statistically significant (20).

Anwar's study in 2014, compared astigmatism after phacoemulsification cataract extraction through a 3.2 mm superotemporal clears

corneal incision. It was divided into 2 groups Group A astigmatism with the rule (WTR) and Group B astigmatism against the rule (ATR). Average astigmatism before phacoemulsification in Group A was 0.83 diopters and in Group B 0.76 diopters.

In groups, A and B median astigmatism after phacoemulsification was 1.10 and 0.75 diopters, respectively. This means that there was an increase in astigmatism as much as 0.27 and 0.34 diopters. In Group A (WTR), there was an increase in astigmatism of 33.33% cases, 20% of cases remained unchanged, and 20% cases converted to ATR, 13.33% cases were neutralized, and 13.33% cases experienced a decrease in WTR. And in Group B (ATR), there was an increase in astigmatism of 62.50% cases, 9.37% cases remained unchanged, and 12.50% cases converted to WTR, 3.12% cases were neutralized and 12.50% cases experienced a decrease in ATR astigmatism (21).

Harakuni in 2016 conducted a study to evaluate the effect of surgically induced astigmatism (SIA) after phacoemulsification clear corneal incision placed in the steepest meridian in patients with a history of astigmatism. Before phacoemulsification, 50% of cases were of WTR and 50% of cases were of ATR. After phacoemulsification there has been a change in the proportion, WTR decreased to 40% of cases, ATR decreased to 30% cases, and 30% of cases were of no astigmatism. In the group initially WTR, after

phacoemulsification 16% of cases remained unchanged, 18% of cases converted to ATR, and 14% cases were with no astigmatism. And in the ATR group 19% cases remained unchanged, 17% of cases converted to WTR and 16% of cases with no astigmatism. The average SIA was  $0.54 \pm 0.34$  D,  $p < 0.001$ .

SIA caused by superior incision was  $0.84 \pm 0.49$  D and by temporal incision was  $0.70 \pm 0.35$  D. Visual acuity examination on the 21st day after phacoemulsification was 25% (6/24-6/18), and 75% (6/12-6/6) (22-25).

The Rho's study in 2012 assessed surgically induced astigmatism (SIA) by a clear corneal incision on the steepest meridian. SIA in the temporal incision group was  $0.28 \pm 79$  D, the superotemporal group was  $0.40 \pm 85$  D, and the superior group was  $0.46 \pm 92$  D (26).

The he's study concluded that the temporal clear cornea incision shows a smaller astigmatism keratometric change than the superior sclera incision. And no astigmatism keratometric difference was found after phacoemulsification between a 1st month and 3rd months (27).

### 5. Conclusion and Recommendations:

Clear corneal 2.8 mm phacoemulsification guided by corneal keratometry can yield better visual acuity by reducing the pre-existing astigmatism and inducing less corneal aberrations

It should kept in mind that postoperative keratorefractive surgery may also be available to enhance the condition of patients who

achieve less-than-optimal astigmatic results. A small 2.8 mm corneal incision in phacoemulsification induces on average very small corneal refractive change.

If right modality to tackle pre-operative astigmatism along with cataract is considered, the patient can be given 6\6 vision and can enjoy life with no dependence on spectacles and also patient may not require another refractive surgery to tackle the residual astigmatism.

### 6. References:

1. Quillen DA (July 1999). "Common causes of vision loss in elderly patients". *Am Fam Physician* 60 (1): 99–108.
2. Courtney P (2002). "The National Cataract Surgery Survey: I. Method and descriptive features". *Eye (Lond)* 6
3. Allen D, Vasavada A (2006). "Cataract and surgery for cataract".–
4. Harper, Douglas (2001). . Retrieved 2007
5. Bobrow JC, Blecher MH, Glasser DB. Surgery for Cataract. In: *Lens and Cataract*. Section 11. 2010-2011. Singapore: American Academy of Ophthalmology; 2010:Chap 8.phaco
6. Kleinstein RN, Jones LA, Hullett S, Kwon S. (2003). "Refractive Error and Ethnicity in Children". *Arch Ophthalmol*.
7. Garcia CA, Oréface F, Nobre GF, Souza Dde B, Rocha ML, Vianna RN (2005). "[Prevalence of refractive errors in

- students in Northeastern Brazil.]. *Arq Bras Oftalmol*(in Portuguese) 68
8. Nichamin LD, Chang DF, Johnson SH, Mamalis N, Masket S, Packard RB, Rosenthal KJ; American Society of Cataract and Refractive Surgery Cataract Clinical Committee. ASCRS White Paper: What is the association between clear corneal cataract incisions and postoperative endophthalmitis? *J Cataract Refract Surg.* 2006 )
  9. Dick HB, Schwenn O, Krummenauer F, Krist R, Pfeiffer N. Inflammation after sclerocorneal versus clear corneal tunnel phacoemulsification. *Ophthalmology.* 2000
  10. Olsen T, Dam-Johansen M, Bek T, Hjortdal JO. Corneal versus scleral tunnel incision in cataract surgery: a randomized study. *J Cataract Refract Surg.* 1997
  11. Abrahamsson M, Sjostrand J. Astigmatic axis and amblyopia in childhood. *Acta Ophthalmol Scand.*2003;81:33–7.
  12. Brown SA, Weih LM, Fu CL, Dimitrov P, Taylor HR, McCarty CA. Prevalence of amblyopia and associated refractive errors in an adult population in Victoria, Australia. *Ophthalmic Epidemiol.* 2000;7:249–58.
  13. Fulton AB, Hansen RM, Petersen RA. The relation of myopia and astigmatism in developing eyes. *Ophthalmology.* 1982;89:298–302.
  14. Gwiazda J, Grice K, Held R, McLellan J, Thorn F. Astigmatism and the development of myopia in children. *Vision Res.* 2000;40:1019–26.
  15. Moon, Sung-Chur, Tarek Mohamed, and I. Howard Fine. “Comparison of surgically induced astigmatism after clear corneal incisions of different sizes.” *Korean Journal of Ophthalmology*, Vol. 21, No. 1, 2007, pp. 1-5.
  16. Lundström M. Endophthalmitis and incision construction. *Curr Opin Ophthalmol.* 2006
  17. Jaffe, Norman S., Mark S. Jaffe, and Gary F. Jaffe. *Cataract Surgery and Its Complications*, 6th Edition. St. Louis: Mosby, 1997.
  18. Gimbel HV, Sun R. Postoperative astigmatism following phacoemulsification with sutured vs. unsutured wounds. *Can J Ophthalmol.* 1993;28:259–262.
  19. Ermi<sup>o</sup> SS, Inan UU, Oztürk F. Surgically induced astigmatism after superotemporal and superonasal clear corneal incisions in phacoemulsification. *J Cataract Refract Surg.* 2004;30:1316–9.
  20. Duke-Elder S, Wybar KC. *System of Ophthalmology*. Vol. 2. London: Henry Kimpton; 1961. *The Anatomy of the Visual System.*
  21. Kohnen S, Neuber R, Kohnen T. Effect of temporal and nasal unsutured limbal tunnel incisions on induced astigmatism after phacoemulsification. *J Cataract Refract Surg.* 2002;28:821–5.

22. Bazzazi, Noushin. "Opposite clear corneal incisions versus steep meridian incision phacoemulsification for correction of pre-existing astigmatism." *Journal of Ophthalmic and Vision Research*, Vol. 3, No. 2, 2008, p. 87.
23. Khan, Akbar. "Effect of incision site on pre-existing astigmatism in phacoemulsification." *Pak J Ophthalmol*, Vol. 30, No. 1, 2014, pp. 45-48.
24. Anwar, M. Shakaib. "Comparison of Pre and Postoperative Astigmatism after Cataract Extraction by Phacoemulsification through a 3.2 MM Clear Corneal Superotemporal Incision." *Pakistan Journal of Ophthalmology*, Vol. 30, No. 3, 2014, p. 156.
25. Harakuni, Umesh. "A longitudinal study to evaluate the effect of surgically induced astigmatism after phacoemulsification clear corneal incision placed in the steepest meridian on eyes with preexisting astigmatism." *Indian Journal of Health Sciences and Biomedical Research*, Vol. 9, No. 2, 2016, p. 179.
26. Rho, Chang Rae, and Choun-Ki Joo. "Effects of the steep meridian incision on corneal astigmatism in phacoemulsification cataract surgery." *Journal of Cataract and Refractive Surgery*, Vol. 38, No. 4 2012, pp.666-71.
27. He, Y. "Comparison of the keratometric corneal astigmatic power phacoemulsification: clear temporal corneal incision versus superior scleral tunnel incision." *Journal of Ophthalmology*, 2009, pp. 1-3.