

Original Article

A Cross-Over Study to Evaluate Parkinsonism Patient's Satisfaction with Different Removable Partial Denture Bases

Enas Taha Ibrahim¹

¹Prosthodontics Department, Faculty of Dentistry, Cairo University.

Email: dr_enas81@live.com

Submitted: 25-5-2022

Accepted: 29-7-2022

Abstract

Aim: this study aims to compare Parkinson's patient's satisfaction with different partial dentures constructed materials (acrylic and flexible partial dentures)

Subjects and methods: The total number of patients who participated in this study was 10 patients suffering from Parkinson's disease, selected at the prosthetic department, faculty of dentistry, Cairo university, and estimated according to inclusion criteria that complained of missing more than three teeth of their upper or lower arch and require a removable partial denture (RPD). Initially, all patients received a hard acrylic resin partial denture and inserted for one month, then followed by a wash-out period for 7 days, and a cross-over protocol was carried out by placing the flexible removable partial denture for 1 month. after each study period (one month of hard acrylic and one month of flexible removable partial dentures) a modified structural questionnaire was used to collect data at a significance level of < 0.05 .

Results: there was a significant difference in patients' satisfaction with flexible RPD than with conventional acrylic RPD.

Conclusion: The results showed a significant difference in satisfaction for patients suffering from Parkinson's disease (PD) between the hard acrylic denture base and the flexible removable partial denture base.

Keywords: Parkinson's patients, removable partial denture, patient satisfaction.

Introduction:

Parkinson's disease (PD) is one the most widespread illnesses in the world, affecting up to 1% of the whole population above 60

years ⁽¹⁾. It is also considered the most frequent movement disorder and represents the central nervous system's second most common degenerative disease ⁽²⁾.

This disease is usually chronic and causes neurodegeneration in motor and non-motor showcases. In dentistry, the main goal of prosthodontists should be to guarantee a good quality of life for patients who have PD. One of the most common treatment methods is removable partial dentures, which increase the Oral health-related equality of life and also improve patients' masticatory efficiency⁽³⁾. It is important to estimate and repair the masticatory function of the patient as fast as possible, Where those Patients treated with the drug L-DOPA, with the international non-proprietary name "levodopa", and the masticatory efficiency is impaired when the patient is receiving this treatment⁽⁴⁾.

To assure a good oral health-related equality of life, patients' oral health needs to be addressed, a multidisciplinary approach is essential, and the treatment can be done with either fixed, or removable prosthesis. For Parkinson's patients, the replacement of missing natural teeth is mandatory to improve their appearance, speech, social confidence and self-esteem, ability to chew more comfortably and to preserve the remaining natural teeth⁽⁵⁾.

Functional and aesthetic restoration of the partially edentulous mouth may be done using a variety of treatment options, each with its advantages and disadvantages⁽⁶⁾. The options are removable partial dentures (RPDs), fixed partial dentures, and dental implants; The factors that may affect the choice of prosthesis used are the periodontal status, aesthetic requirements, cost, anatomical constraints, and patient's acceptability⁽⁷⁾.

Different RPDs have been introduced, which can be made with cast metal, hard acrylic resin, or thermoplastic resin^(8,9).

metal-free restorations and prostheses are being considered the future of dentistry⁽¹⁰⁾. Therefore, the study aimed to compare two types of denture base materials to provide a clinically satisfactory alternative for patients suffering from Parkinson's disease (PD).

Materials and methods:

A purposive sample of 10 patients suffering from parkinsonism disease participated in this study (6 males and 4 females), they were selected and estimated 10 % from the total number of Parkinson's patients represented at the outpatient clinic, prosthetic department, faculty of dentistry, Cairo university, according to the following inclusion criteria.

- 1- Patients with parkinsonism disease with early symptoms such as tremors in hands, arms, legs, jaw, or head. Muscle stiffness, slowness of movement, and Impaired balance and coordination.
- 2- Age between 45-65 years.
- 3- Good periodontal health to the mild periodontal disease of standing teeth.
- 4- Edentulous areas are either free end or bounded sable.
- 5- Reassurance of oral health if Loss of teeth for more than 3 months, through the period of follow-up.
- 6- No previous history of partial denture use.
- 7- Patients with different socioeconomic statuses (low, moderate, and high social class).

Patients with the following criteria were excluded:

- 1- Patients receiving or with a history of chemotherapy, radiotherapy, or hormonal therapy.

- 2- severe ridge resorption and those with severe bony undercuts or bony exostosis.
- 3- the covering mucosa was free from any signs of inflammation or ulceration.

The patients agreed with written informed consent. The study was conducted by the Helsinki Declaration of 1975 for medical studies, as revised in 2000.

Patients were diagnosed and examined on a dental chair. Intra-oral examination of the edentulous ridge was done to ensure it was well-formed and free from any anomalies (**Figure 1**). Appropriate infection control was applied.

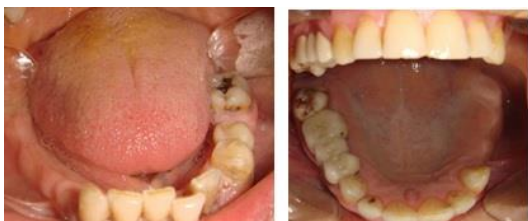

Figure 1: an intra-oral examination of the partially edentulous lower arch

A cross-over design was done in this study, with a wash-out period of 7 days between the study periods, where patients received the hard acrylic partial denture first, and satisfaction was assessed after 1 month of use, followed by a wash-out period of 1 week where all patients were without a removable partial denture and followed-up for prediction of any signs and symptoms of any inflammation or/and presence of ulcers, and how far was the daily care of oral hygiene, and to allow more time for the effects of prior treatments to dissipate. Then, a crossover was performed where the subjects received the flexible partial denture for one month and satisfaction was assessed in a patient satisfaction chart.

For the construction of hard acrylic partial denture, a primary impression of both

arches was taken in a sterile well-fitting stock tray using irreversible hydrocolloid impression material (Cavex Holland B.V., P.O Box 852-2006 RW Harlem, Holland) and poured to obtain the diagnostic casts (Type III dental stone) The cast was duplicated to produce two working casts for the acrylic and the flexible partial dentures to ensure the exact dimension for both partial dentures. self-cured acrylic resin (Peka tray Acrostone . England) special tray was constructed and a final impression was made using rubber base impression material (Gollene Speedex Dental Vertrieb G murrbt Konster. Germany), boxed and poured in dental stone. Occlusion blocks were constructed on the master cast. mount the upper cast on a semi-adjustable articulator (Whip Mix # 8500; Louisville, KY.U.S.A) the mandibular cast was mounted according to a centric relation record obtained from the patient using the check bite technique (**Figure 2**).



Figure 2: mounting upper and lower cast on articulator

Acrylic resin teeth (Vertex quint teeth vertex. dental, Netherland) were selected and were of the same brand, size, and shade for both partial dentures. to standardize the arrangement of teeth for the partial dentures

used, an over-impression of teeth on the working cast of the initial acrylic partial denture was putty impression material, which was used to locate the exact position of the teeth on the second flexible partial denture. Try-in was done for trial dentures of both partial dentures and found satisfactory before processing the partial dentures. The initial acrylic partial denture using heat-cured acrylic resin was processed, while for the second flexible partial dentures, Valplast (dentiflex-roko, Poland) was used (**Figure 3**).

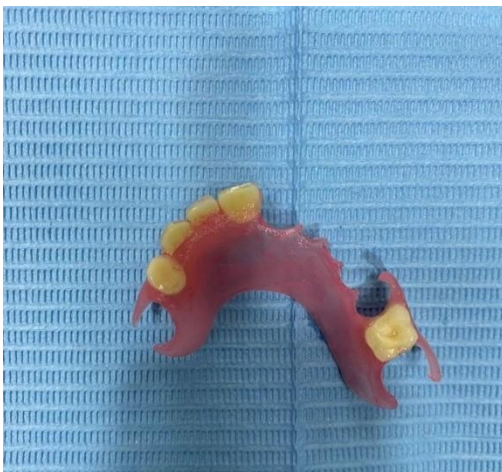

Figure 3: finished and polished flexible partial denture

All laboratory procedures were carried out by one dental technologist, 10 acrylic and 10 flexible partial dentures were fabricated. Oral prophylaxis was done for all patients before partial denture fitting, Insertion and checked for retention, extension, esthetics, and function, and occlusal adjustment was performed to achieve harmonious occlusion.

post-insertion instructions were given to all Parkinson's patients showed them how to insert and remove the denture, taught them the importance of keeping it clean after each meal, besides instructed them

on how to be adapted to the new dentures during function.

A follow-up period was done for all patients at 24 hours, 1 week, and 1-month post-insertion of the initial conventional acrylic partial denture.

Patients' assessment:

Patient satisfaction was assessed after 1 month of hard acrylic partial denture insertion and the second flexible one was fitted and assessed thereafter, where the patients can give an unbiased judgment about the RPD.

A visual analog scale (VAS) was used for expressing or analyzing patients feeling quantitative, before and after seeking any kind of treatment, and to rate the intensity of sensations such as pain.

Patients rated their RPD in terms of appearance, ease of cleaning, ability to speak, ability to insert and remove the RPD, and comfort while eating and talking, according to keywords used "dissatisfied" at 0 mm and "totally satisfied" at 100 mm. a pencil was marked across the horizontal line at a point corresponding to patient subjective feeling. Satisfaction was measured as the distance in millimeters from the left end limit to the point of the pencil mark representing the VAS score of the patient. The higher the score, the better satisfaction with the prosthesis. Satisfaction levels using the VAS scores were classified as: slightly dissatisfied, slightly satisfied, and satisfied.

Questions were asked twice, one with conventional acrylic, then with flexible acrylic partial dentures, as follows:

Q1: do you feel any difficulty during insertion and removal?

Q2: do you feel heaviness?

Q3: is it seems esthetically accepted?

Q4: do you face problems during cleaning?

Q5: do you feel any difficulty in chewing?

Q6: is there any difficulty during speaking?

All data were collected, tabulated, and statistically analyzed.

Statistical Methods:

Data were presented as mean & standard deviation. Data were presented in 1 table & 1 graph. Statistical analysis was performed with SPSS 24 ® (Statistical Package for Scientific Studies), Graph pad prism & windows excel. Data were explored using the Shapiro-Wilk test and Kolmogorov-Smirnov test for normality which revealed that the significant level (P -value) was insignificant as P -value >0.05 .

Results:

In assessing the level of satisfaction regarding all parameters such as (the ability of insertion and removal, appearance, cleanliness, speech, comfort, and heaviness) (**figure 4**), (According to Clara Arianta Akinyamoju et al 2017)⁽¹¹⁾, it was found that more than 70% of participating patients were totally satisfied with flexible partial dentures than conventional hard acrylic partial dentures. (**Table 1**)

A comparison between two types of removable partial denture base materials (conventional hard acrylic and flexible partial denture) on the level of satisfaction for Parkinson's patients was performed (**table 2**), by using the one-way ANOVA test. It revealed a significant difference between all parameters for satisfaction as $P < 0.05$, except for cleanliness, where there was a non-significant difference for both hard acrylic and flexible partial dentures

Discussion:

Parkinson's disease has various signs and symptoms due to insufficient formation and action of dopamine produced in dopaminergic neurons of the midbrain⁽¹²⁾, patients were selected with mild or early symptoms in order to control the physical symptoms where it represents a challenge for the daily routine of the patients, including dental care and home care program. tremors and the associated loss of digital dexterity, muscle-eye coordination, and tongue, cheek, and lip control, mitigate against effective oral hygiene procedures⁽¹³⁾. Because of the poor motor function, nearly half of all people with PD have difficulty with their daily oral hygiene regimen, for example, they are less likely than others in their age group to clean their dentures daily. Weakened swallowing ability can increase the risk of aspiration.⁽¹⁴⁾

Cross-over design is done for this study to allow the response of the subject treated with a hard acrylic removable partial denture, to be contrasted to the response of the same subject treated with a flexible acrylic partial denture to be more efficient than parallel-group trials and for accuracy of the results obtained⁽¹⁵⁾.

The motivation of the patient played a major part for the treatment prognosis. The importance of the initial removable partial denture inserted was to give a positive indication of the motivation level of the patient. Rehabilitation of the missing natural teeth with the most popular conventional line of treatment with hard acrylic partial denture is introduced due to its low cost than the flexible one to make sure that the patients will follow the given instructions post delivered and keep a good and daily oral hygiene program.⁽¹⁶⁾

Table (1): levels of satisfaction with the partial dentures (n=10)

Parameters for satisfaction	Type of partial denture	Slightly dissatisfied	Slightly satisfied	Satisfied
Ability to insert and remo	Flexible	1(10%)	2(20%)	7(70%)
	acrylic	1(10%)	3(30%)	6(60%)
Appearance	Flexible	1(10%)	2(20%)	7(70%)
	acrylic	1(10%)	5(50%)	4(40%)
Cleanliness	Flexible	0 (0%)	10(100%)	10(100%)
	Acrylic	0(0%)	4(40%)	6(60%)
Speech	Flexible	2(20%)	3(30%)	5(50%)
	Acrylic	2(20%)	5(50%)	3(30%)
Comfort with eating	Flexible	0(0%)	3(30%)	7(70%)
	Acrylic	1(10%)	4(40%)	5(50%)
Heaviness	Flexible	1(10%)	2(20%)	7(70%)
	acrylic	1(10%)	3(30%)	6(60%)

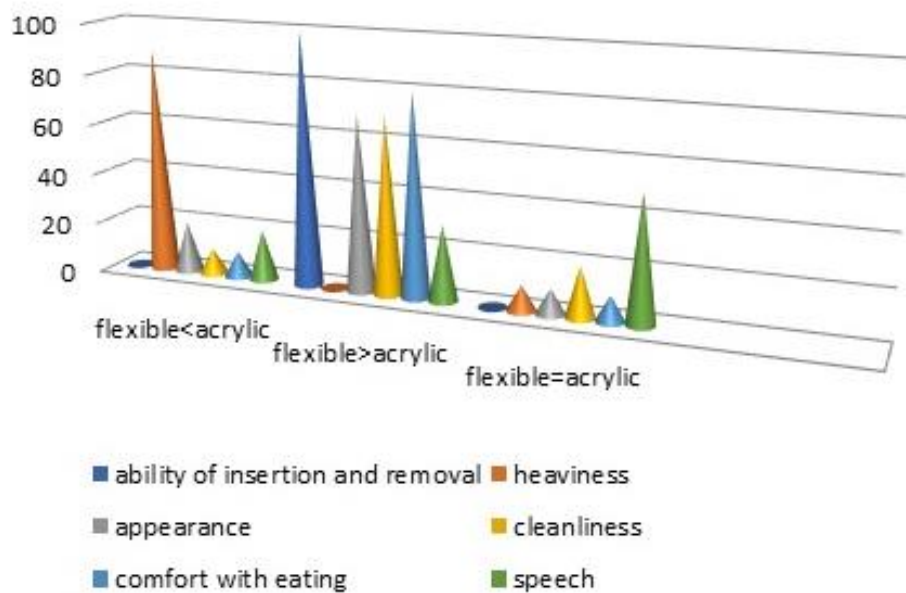
**Figure 4:** Representing parameters of satisfaction levels of Parkinson's patients

Table 2: comparing Parkinson's patient's visual analogue scale scores for acrylic and flexible partial dentures.

Parameters of satisfaction	N	Mean rank	P
<u>Insertion and removal</u>			
Flexible<acrylic	0	0.0	0.01*
Flexible>acrylic	10	11.2	
Flexible=acrylic	0	0.0	
<u>heaviness</u>			
Flexible<acrylic		10.0	0.01*
Flexible>acrylic	0	0.0	
Flexible=acrylic	1	8.0	
<u>appearance</u>			
Flexible<acrylic	2	12.0	0.00*
Flexible>acrylic	7	17.05	
Flexible=acrylic	1	10.0	
<u>Cleanliness</u>			
Flexible<acrylic	1	10.0	0.22*
Flexible>acrylic	7	18.0	
Flexible=acrylic	2	20.0	
<u>Comfort with eating</u>			
Flexible<acrylic	1	11.0	0.01*
Flexible>acrylic	8	18.0	
Flexible=acrylic	1	10.0	
<u>Speech</u>			
Flexible<acrylic	2	20.0	0.01*
Flexible>acrylic	3	30.0	
Flexible=acrylic	5	15.0	

Patients' satisfaction was assessed at 1 month after insertion of the hard acrylic removable partial denture then with the flexible partial denture at the end of the following month, as where this period was considered sufficient to make patients informed and largely unbiased judgments about the partial dentures ⁽¹⁷⁾.

Different socioeconomic statuses of the participated patients were included in the

study to investigate the difference between each status for the need for replacement of their missing teeth and whether to restore them with fixed, removable, or even implants retained prosthesis. The low-moderate social class came and require restoring their missing teeth with removable partial dentures due to the high cost of other treatment plans such as fixed or implants retained fixed prosthesis ⁽¹⁸⁾.

The age of the patients ranged from 45 and 65 years with a mean age of 54 to eliminate the effect of senility.

The motivation of the patient played a major part in the treatment prognosis in this case. The importance of the removable partial denture will give a positive indication of the motivation level of the patient. ⁽¹⁹⁾

Using the Visual Analogue Scale (VAS) in this study is one of the pain rating scales used and is often used in epidemiologic and clinical research to measure the intensity or frequency of various symptoms. For example, the amount of pain that a patient feels ranges across a continuum from none to an extreme amount of pain. ⁽²⁰⁾

The limitations of the present study were the limited sample size and short follow-up period. It is recommended to evaluate patients' outcomes with longer-term follow-up with a larger population. Despite this, the present study brings new insights that improve the comprehension of factors that influence patient satisfaction with different partial denture base materials.

This study showed a significant difference between hard acrylic and flexible partial denture during the follow-up period almost in all parameters of satisfaction level introduced to the Parkinson's patients except for the cleanliness of the partial dentures. Both types showed to be easily cleaned and disinfected after each meal, where all of them were instructed to follow daily home care program by using mouth wash and keep all of the supporting structures healthy because using the all-acrylic resin dentures are increased risk of developing caries, gingivitis and periodontal disease relative to other RPD. ⁽²¹⁻²²⁾

On the other hand, RPDs made from flexible resins because of their inherent flexibility and ability to engage hard and soft tissue undercuts for retention thus made easier for those patients to place and remove it during the day and are more natural and comfortable in the mouth. Also, because the material is translucent, it picks up underlying tissue tones, making it almost impossible to be detected in the mouth. No clasping is visible on tooth surfaces when used in the manufacturing of clear clasps, thereby improving aesthetics⁽²³⁾. also this material blends with the surrounding tissue beside being comfortable to use as it is made of thinner sections, The flexibility of the material provides balanced masticatory forces over the entire supporting ridge instead of individual support points⁽²⁴⁾.

Also, patients showed satisfaction regarding the heaviness of the flexible partial denture, as they are made from a thermoplastic nylon resin that is ultra-thin, very flexible (think more comfortable for chewing and speaking), and is so durable that one company – Valplast – offers a lifetime warranty for fractures or breaks⁽²⁵⁾, unlike hard acrylic partial dentures, made in thicker sections to compensate for their low impact strength, and this makes them bulky⁽²⁶⁾. This also may interfere with speech, where this study showed a significant difference in satisfaction with speech parameter, which may be due to over bulked denture base which interferes with lip movement during speech ⁽²⁷⁾.

Conclusion:

In the present study, It could be concluded that a flexible partial denture base showed general significant satisfaction for patients suffering from Parkinson's disease

(PD) in comparison with hard acrylic one for all clinical variables assessed.

Conflict of Interest:

The authors declare no conflict of interest.

Source of Funding:

This research received no specific grant from any funding agency in the public, commercial, or not-for-profit sectors.

References

1. Pringsheim T, Jette N, Frolkis A, Steeves TD. The prevalence of Parkinson's disease: a systematic review and meta-analysis. *Mov Disord*. 2014;29(13):1583–1590.
2. Tysnes O, Storstein A. Epidemiology of Parkinson's disease. *J Neural Transm*. 2018; 124:901-905.
3. Giselle R Ribeiro, Camila H Campos, Renata Cunha Matheus Rodrigues Garcia. Influence of a removable prosthesis on oral health-related quality of life and mastication in elders with Parkinson's disease. *J Prosthet Dent* 2017 Nov; 118(5):637-642.
4. George DeMaagd, and Ashok Philip. Parkinson's Disease and Its Management Part 1: Disease Entity, Risk Factors, Pathophysiology, Clinical Presentation, and Diagnosis. 2015 Aug; 40(8): 504-510, 532.
5. Ilen PF, Jepson NJ, Doughty J, Bond S. Attitudes and practice in the provision of removable partial dentures. *Br Dent J* 2018;204:E2.
6. Ewoldsen NO, Kurtzman GM, Sundar V. New Options in Metal-Free Partial Dentures. Vol. 7. *AEGIS Commun*; 2019. p. 1-6.
7. Thakral GK, Aeran H, Yadav B, Thakral R. Flexible partial dentures – A hope for the challenged mouth. *Peoples J Sci Res* 2016;5:17-23.
8. Bengt EO, Taylor RL. A survey of dentitions and removable partial dentures constructed for patients in North America. *J Prosthet Dent* 1989; 61:465-70.
9. Negrutiu M, Sinescu C, Romanu M, Pop D, Lakatos S. Thermoplastic resins for flexible framework removable partial dentures. *TMJ* 2005;55:295-9
10. Thakral GK, Aeran H, Yadav B, Thakral R. Flexible partial dentures – A hope for the challenged mouth. *Peoples J Sci Res* 2012;5:17-23
11. Clara Arianta Akinyamoju, Tunde Joshua Ogunrinde, Juliana Obontu Taiwo, Oluwole Oyekunle Dosumu. Comparison of Patient Satisfaction with Acrylic and Flexible Partial Dentures. *Niger Postgrad Med J*; Jul-Sep 2017;24(3):143-149.
12. C. A. Davie, "A review of Parkinson's disease," *British Medical Bulletin*, vol. 86, 2008; pp. 109–127.
13. J. Jankovic, "Parkinson's disease: clinical features and diagnosis," *Journal of Neurology, Neurosurgery & Psychiatry*, vol. 79, no. 4, 2018; pp. 368–376.
14. W. Poewe and G. Wenning. "The differential diagnosis of Parkinson's disease," *European Journal of Neurology*, no. 32, supplement 3, 2012; p. 30.
15. Bonnie Sibbald, Chris Roberts. Understanding controlled trials cross-over trials. *BMJ*, v.316, 2019; (7146).
16. V. Bhat, K. Prasad, S. S. Balaji, and A. Bhat, "Partial denture treatment protocol in Parkinson's disease. A case report," *Journal of Indian Academy of Dental Specialists*, vol. 2, no. 2, pp. 63–65, 2018.
17. Montero J, Castillo-Oyagüe R, Lynch CD, Albaladejo A, Castaño A. Self-perceived changes in oral health-related quality of life after receiving different types of conventional prosthetic treatments: A cohort follow-up study. *J Dent* 2017; 41:493-503.

- 18-Petricević N, Celebić A, Rener-Sitar K. Improvement of patient's satisfaction and oral health-related quality of life by the implant and prosthodontic treatment; 2017. Available from: <http://www.intechopen.com>. [Last accessed on 2013 Dec 10].
- 19.Fouad A. Al-Omari, Mohammed M. Al Moaleem, Sulaiman S. Al-Qahtani, Abdullah S. Al Garni, Syed Sadatullah, and Master Luqman. Oral Rehabilitation of Parkinson's Disease Patient: A Review and Case Report. *Case Rep Dent*. 2017; 432475.
20. Delgado DA, Lambert BS, Boutris N, McCulloch PC, Robbins AB, Moreno MR, Harris JD. Validation of digital visual analog scale pain scoring with a traditional paper-based visual analog scale in adults. *Journal of the American Academy of Orthopaedic Surgeons*. Global research & reviews. 2018 Mar;2(3).
- 21-Dyer SR, Lassila LV, Jokinen M, Vallittu PK. Effect of cross-sectional design on the modulus of elasticity and toughness of fiber-reinforced composite materials. *J Prosthet Dent* 2019;94:219-26.
22. Zlatarić DK, Celebić A, Valentić-Peruzović M. The effect of removable partial dentures on periodontal health of abutment and non-abutment teeth. *J Periodontol* 2020;73:137-44.
23. Singh L, Kaira SL, Dayakara HR, Singh R. Flexible denture for partially edentulous arches – A case report. *J Dentofacial Sci* 2012; 1:39-42
24. Phoenix RD, Mansueto MA, Ackerman NA, Jones RE. Evaluation of mechanical and thermal properties of commonly used denture base resins. *J Prosthodont* 2018; 13:17-27.
25. The Pros and Cons of Thermoplastic Partial Dentures
By Mary Anne Salcetti on June 16, 2021.
- 26- Lanier A. Partial Dentures. *Dental Procedures, Dental Articles*; 2012.
- 27-Bilhan H, Erdogan O, Ergin S, Celik M, Ates G, Geckili O. Complication rates and patient satisfaction with removable dentures. *The journal of advanced prosthodontics*. 2018;4(2):109-15.