



Effect of Two Designs of Extracoronary Attachments on Supporting Structures in Kennedy Class II Mandibular Partial Denture

Menna A. Mohamed^{1*}, Shereen M. Kabeel², Dina M. Kholief³

Codex : 02/22.10

azhardentj@azhar.edu.eg

http://adjg.journals.ekb.eg

DOI: 10.21608/adjg.2022.76192.1381

Restorative Dentistry
(Removable Prosthodontics, Fixed
Prosthodontics, Endodontics, Dental
Biomaterials, Operative Dentistry)

ABSTRACT

Purpose: The aim of this study was to compare between the effects of using two different designs of extra coronal precision attachments on supporting structures of the abutment teeth in unilateral free end saddle partial denture. **Material and Methods:** Ten Kennedy class II partially edentulous patients with the last second premolar which is lasting abutment tooth were selected. The patients were divided into two groups (each group five patients), group I; patients were received unilateral partial denture retained by OT unilateral extra coronal attachment, group II; patients were received partial denture retained by OT cap extra coronal attachment with bilateral cross arch stabilization. Clinical evaluation including pocket depth measurements at four sides of last abutment tooth and radiographic evaluation using cone beam computed tomography (CBCT) was done at time of partial denture delivery, after 6, 9 and 12 months. **Results:** Inspection of radiographic evaluation revealed non-statistical significant difference between the two groups at the time of insertion, 6 and 9 months while after 12 months group II showed more bone loss than group I. Regarding the clinical evaluation showed non-statistical significant difference in pocket depth between two groups at time of insertion, 6 and 9 months and more pocket depth in group II at 12 months. **Conclusions:** Using special design of extra coronal castable precision attachment (OT unilateral) exerts less stresses on the abutments and their supporting structures in comparison with OT cap attachment, in addition to it is simple and more comfortable to the patients.

KEYWORDS

OT Unilateral Extra coronal attachment,
OT CAP attachment,
attachment-retained partial denture, Kennedy class II.

INTRODUCTION

The problems of unilateral distal extension cases had several designs concepts, which were suggested to solve these conditions. The conventional removable partial denture that was considered the most

1. Dentist at Ministry of Health, Cairo, Egypt
2. Assistant Professor at Removable Prosthodontic Department, Faculty of dental medicine for Girls, Al-Azhar University, Cairo, Egypt
3. Professor at Removable Prosthodontic Department, Faculty of dental medicine for Girls, Al-Azhar University, Cairo, Egypt

* Corresponding author email: dentist.menna@hotmail.com

commonly used restoration, despite the problems which associated with its use such as increased gingivitis, periodontitis, and abutment mobility.

Implants can be considered another treatment option, but it is not recommended in case of insufficient bone and for economic reasons, in this situation the best treatment option is combined prosthesis as removable partial denture retained with precision attachment ⁽¹⁾.

Successful prosthetic rehabilitation needs delicate awareness and accurate treatment plan in order to achieve esthetically and functionally effective prosthesis. Distal extension cases as Kennedy's class (I, II) are considered complex situations, treatment with conventional partial denture is considered a situation that presents many problems due to the lack of distal dental support ⁽²⁾.

The dual nature of support, dental and mucosal support with different resiliency generates a system of levers around the last supporting tooth during the occlusal forces, which is destructive to the abutments, especially the pier abutment, surrounding tissues, and causing discomfort to the patient ⁽³⁾.

Removable partial dentures fabricated with precision attachments which improve both esthetic and mechanical functions. Precision attachment is a connector has two components. The male component is fixed to a root, tooth, or implant and corresponding female section is incorporated into the prosthesis giving a mechanical connection between them. These attachments give prosthesis the ability to combine the advantages of both removable and fixed restorations ⁽⁴⁾.

According to the method of manufacturing; Attachments are classified into precision or semi precision, internal or external, according to their location into intra-coronal or extra coronal in relation to the abutment tooth, and rigid or resilient, according to the amount of movement allowed between the component parts ⁽⁵⁾.

Extra-coronal attachments are preferred in case of short clinical crowns, non-parallel abutments, and long edentulous span partial denture, splinting of natural abutments next to the edentulous area is recommended to help in favorable distribution of stresses; fixed splinting of last abutment teeth with crowns will be of great importance especially in case of long lever arm of the prosthesis which apply excessive torque on the abutment teeth ⁽⁶⁾.

Different types of extra coronal attachments were incorporated in combined prosthesis to enhance stability, retention, and equal distribution of applied forces to the abutment teeth with great success ⁽⁷⁾.

This study aimed to investigate effect of two different designs of extra-coronal attachments-retained partial dentures on the abutment teeth and their supporting structure in cases of unilateral free end saddle to answer the question, which is more superior, regarding less change in bone height and preservation of health state of periodontal structure of the abutments.

MATERIAL AND METHODS

Selection of Participants

Ten partially edentulous patients were selected following the inclusion criteria of our study from the Outpatient Clinic of the Prosthodontic Department, Faculty of Dental medicine for Girls, Al-Azhar University. Patients signed an informed consent and ethics committee approval of faculty of dental medicine of girls was obtained (REC-PR-21-02) their ages ranged from (40-45) years. All patients were partially edentulous mandibular arch with the second bicuspid tooth being the most posterior abutment with appropriate crown height. The present unextracted teeth were periodontally and structurally healthy with no signs of active diseases.

All patients were free from any systemic diseases that affect integrity of the bone and had no Para functional habits that may affect prognosis of

the prosthetic treatment. Sufficient inter-occlusal distance was important to be proportional to removable prosthesis. Edentulous span area covered by healthy firm mucosa, with no bony exostosis or deep lingual pouch with unfavorable extension. All patients were easily handled to maintain good oral hygiene that helps in improve prognosis of the treatment.

Prosthetic Treatment

Preliminary impression were made for the maxillary and mandibular arches using alginate impression material and the mounted primary casts were examined for occlusion, inter-occlusal distance, any teeth interference, and condition of the remaining teeth then special trays were constructed.

For both groups reduction of first and second premolars in the edentulous side were done for the purpose of construction of porcelain full veneered metal crowns. The secondary impression for prepared teeth were taken by using putty and light rubber base impression material then poured into extra-hard dental stone master casts. Wax patterns of both crowns were built-up on the dies on the cast which was put on the table of the milling machine.

For both groups the male component of the attachment was attached to the distal surface of the last abutment tooth using paralleling mandrel as follow parallel to the long axis of the abutment tooth perpendicular to the underlying ridge and above the residual ridge by about 1mm, by using parallelometer. Ledge was prepared on the lingual surface of the wax pattern of the second premolar to accommodate the lingual bracing arm. Final wax pattern of the crown-attachment unite was invested and casted, tried-in of the metal crown-attachment unites intraorally in both groups. (Fig.1)

In group I, pick-up impression of the porcelain crown-attachment structure was taken then final removable prosthesis including the female component of the attachment was processed, finished and polished. Finally, each patient was

received removable partial denture (RPD) retained by OT Unilateral attachment. (Fig.2).




Figure (1): Installment the unilateral OT attachment using OT patric positioning tool and fixing of patric with wax.

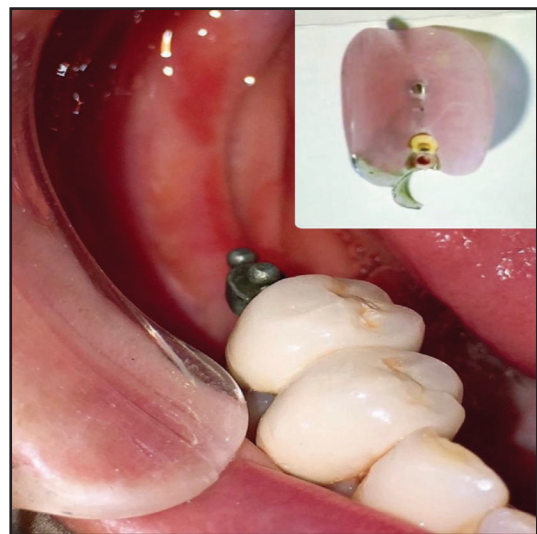

Figure (2): Try-in porcelain crowns-OT Unilateral attachment-assembly and final prosthesis from fitting surface.

In group II, this design provides crossing the midline for stabilization of the prosthesis through lingual bar major connector retained by a double Aker clasp at the dentulous side was done for cross arch stabilization as follow, second premolar was prepared to receive occluso - distal rest seat and occluso-mesial rest seat on first molar to accommodate double Aker's clasp, occluso-mesial rest seat on first premolar was prepared for the terminal end of lingual bar as indirect retainer, try-in the final porcelain crowns-attachment unite was done intraorally after selection of proper porcelain shade for each patient.

Pick-up impression of the porcelain crown-attachment structure was taken. Cast modification and duplication were performed to result in a duplicate cast from refractory material. The duplicate cast was waxed for RPD framework in group II according to the previous design.

In group II, try-in the metal framework was carried out in patient's mouth to check proper seating of occlusal rests in their rest seats and passive path of insertion and removal, then altered cast impression for the area of free end saddle was made, centric relation was recorded by suitable method then setting of artificial teeth, try in, processing and finishing of the prosthesis were done (Fig.3).

All patients were instructed to follow strict good oral hygiene measurements and were recalled one week later after delivery to eliminate any complaints that might appear during the first period of prosthesis adaptation.

Clinical Evaluation

Gingival and periodontal condition was checked for all patients by measuring the probing depth using Williams graduated periodontal probe. Probing depth measurements were taken at all sides of the last abutment tooth, and the mean value of each patient at each period was taken and then was statistically analyzed.

Radiographic Evaluation

Patients were evaluated radiographically by CBCT at the time of prosthesis delivery, 6, 9 and 12 months, the bone height changes were measured at mesial and distal proximal aspects of the last abutment tooth in addition to the site of second molar area representing free end saddle area.

The CBCT digital images were analyzed using blue sky plan software taking the following sections, first section mesio-distal view, second section bucco-lingual view (cross section view) to evaluate the alveolar bone level mesial and distal to the second premolar abutment, at the first molar

and second molar are as follow, First line was drawn as upper highest reference point at the peak of crest bone mesial to the second premolar to the lower reference point at inferior border of mandible, second line at distal surface area, third line at first molar area making mesio-buccal cusp of upper first molar as reference point, mesio-buccal cusp of upper second molar as reference to the fourth line, third and fourth lines represent the free end saddle area under the denture base, All lines were parallel to each other and perpendicular to the inferior border of mandible. All data were collected and statistically analyzed. (Fig .4)

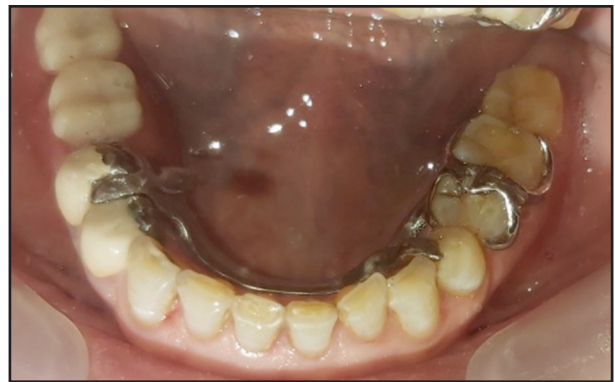

Figure (3): Final prosthesis of OT cap with metal framework.

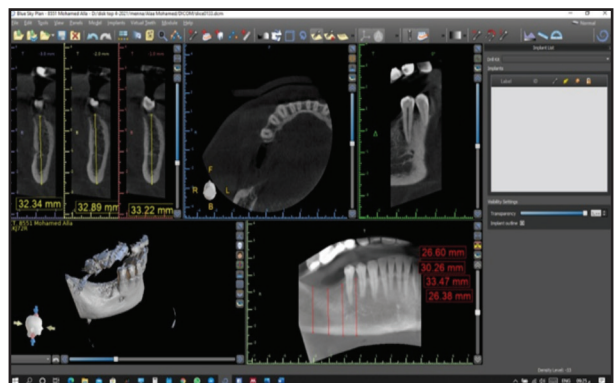


Figure (4): Image analysis using blue sky plane software.

STATISTICAL ANALYSIS

Recorded data were analyzed using the statistical package for social sciences, version 20.0 (SPSS Inc., Chicago, Illinois, USA). Quantitative data were expressed as mean \pm standard deviation (SD).

Qualitative data were expressed as frequency and percentage. Data were explored for normality using Kolmogorov-Smirnov and Shapiro-Wilk Test.

The confidence interval was set to 95% and the margin of error accepted was set to 5%. So, the p-value was considered significant as $P\text{-value} \leq 0.05$, $P\text{-value} > 0.05$ was considered insignificant.

RESULTS

The present study included 2 groups (a total of 10 participants) first group: included 5 participants, group I: Patients with unilateral removable partial denture retained by double head extra-coronal precision attachment with combined function (OT unilateral), second group included 5 participants, group II: Patients with unilateral removable partial

denture retained by ball and socket extra-coronal precision (OT cap attachment) with the same inclusion and exclusion criteria.

The results revealed that at baseline, 6 months and 9 months there was non-statistically significant difference between measurements of bone height in both groups (p-value: 0.861, 0.420, and 0.486). After 12 months; group II (OT cap attachment) clarify statistically significant difference in mean value (p-value: 0.048) than group I (OT unilateral). (Table.1).

Pocket Depth Measurements

At base line, after 6, 9 and 12 months there was statistically non-significant difference between PD measurements of both groups (p-value: 0.930, 0.758, 0.526, 0.080). (Table.2)

TABLE (1) Student's *t*-test showing the mean, standard deviation (SD) values and results for comparison between bone height measurements in the two groups.

| Bone height (mm) | Group I (n=5) | Group II (n=5) | t-test | p-value |
|------------------|---------------|----------------|--------|----------|
| Baseline | 29.87±2.20 | 30.12±2.17 | 0.181 | 0.861 NS |
| After 6 months | 28.97±1.93 | 28.01±1.63 | 0.850 | 0.420 NS |
| After 9 months | 28.08±1.79 | 27.16±2.17 | 0.731 | 0.486 NS |
| After 12 months | 27.23±1.77 | 25.03±1.16 | 2.325 | 0.048 S |

P-value >0.05 NS; *p*-value <0.05 S

TABLE (2) Mann-Whitney *U* test showing the mean, standard deviation (SD) values and results in comparison between pocket depth measurements in both groups

| Pocket depth (PD) | Group I (n=5) | Group II (n=5) | t-test | p-value |
|-------------------|---------------|----------------|--------|----------|
| Baseline | 0.75±0.34 | 0.73±0.36 | 0.090 | 0.930 NS |
| After 6 months | 1.16±0.51 | 1.06±0.48 | 0.319 | 0.758 NS |
| After 9 months | 1.46±0.65 | 1.72±0.59 | 0.662 | 0.526 NS |
| After 12 months | 1.72±0.51 | 2.29±0.56 | 1.983 | 0.080 NS |

P-value >0.05 NS

DISCUSSION

Ten participants whose have their mandibular arches with unilateral distal extension were selected with second premolars is the last standing teeth, their ages between 40-45 years. Age variation between patients was closely approximate to eliminate the effect age variation on bone metabolism.

In all selected patients the upper arch was either dentulous or partially edentulous restored with fixed prosthesis for standardizing the effect of opposing occlusion and their effect on distribution of applied forces, All patients were free from any systemic diseases that may affect the results of the study.

Treatment options for the partially edentulous patients were conventional (RPD), fixed partial denture, partial denture retained with attachments or implant-retained prosthesis. Taking the decision is critical in choosing the most appropriate treatment option for each condition⁽⁸⁾.

Implant retained fixed or partial dentures were not considered a treatment options as the patient was not ready for the surgical procedure. Therefore, attachments and cast partial denture were selected as the treatment of choice⁽⁹⁾.

Precision attachment has exceptional feature of being a removable prosthesis with improved aesthetics as it eliminates the appearance of metal clasps, less post-operative adjustments, better patient comfort and overcome disadvantages of (RPD)⁽¹⁰⁾.

Splinting of the last abutment teeth were used on the experimental side by porcelain fused to metal crowns for better distribution of forces; enhance support and improving the prognosis of partial denture, centralization of the attachment in buccolingual dimension with minimal lingual tilting is very important for esthetics, patient's comfort, and equal distribution of stresses on attachment-prosthesis structure during construction of wax pattern of crowns-attachment assembly^(11,12).

Measuring the pocket depth by using periodontal probe at all sides of the Last abutment teeth and mean value of four readings was taken at 0, 6, 9 and 12 months intervals as important parameter in evaluation of periodontal condition.

In this study the digital images were analyzed using blue sky plan dental planning software to evaluate marginal bone level at mesial and distal proximal sides of the last abutment (second premolar) in addition to two linear measurements in two different points (at the first molar area and second molar area) which represents free end saddle area.

Evaluating of bone height and measuring amount of bone loss by using (CBCT) which used to quantitatively assess bone height and amount of bone loss with high precision and accuracy which overcome errors and limitations of two-dimensional radiograph as absence of distortion, overlapping of anatomical structures and the dimensions are compatible with the actual size⁽¹³⁻¹⁴⁾.

Group II showed higher percentage of bone height changes than group I after 12 months, this noticeable changes may be due to the special design of the OT Unilateral attachment as, its elasticity, the presence of two heads in two different levels (horizontal and vertical planes) that help in even distribution of applied stresses more favorably under masticatory forces and improve stability of prosthesis, retention, comfort, and facilitate the ability to bite without fear from the loss of retention⁽¹⁵⁾.

The result of this study came in agreement of other researches as, OT Unilateral attachment show minimal effect on supporting structures of the abutments this may be due to there was no importance in extending of the prosthesis across the arch that add the advantage of no need to prepare more abutment teeth, minimizing the bulk of material in the mouth and, therefore, decreasing the areas of soft and hard tissue coverage unlike OT cap attachment that need cross arch stabilization so state of supporting structure has good condition in case of OT unilateral attachment^(16,17).

Recent study compared the effect of two unilateral (RPD) one retained by OT Unilateral and other conventional (RPD) on the alveolar bone height and efficiency of biting force, they stated that use of OT Unilateral attachment as a retainer in cases of unilateral partial denture gave better retention, stability and load distribution which positively affects the masticatory function and therefore enhance biting force and less bone loss in comparison with conventional type, it could be a predictable modality in treatment of distal extension ridge ⁽¹⁸⁾.

CONCLUSION

Using of OT unilateral attachment with unilateral design is preferred to OT cap attachment with bilateral design as the OT unilateral attachment provides lateral stability and distal support to the prosthesis and provides superior retention, controlled resiliency.

ACKNOWLEDGMENTS

I would like to express my special thanks of gratitude to Removable Prosthodontic department members in faculty of dental medicine of Al-Azhar University (Girls branch).

RECOMMENDATIONS

It is recommended that, for future research:

1. Increasing sample size.
2. Extending duration of study.

Conflict of Interest:

There was no conflict of interests and opinions between my study and other research.

Fund Received For This Study:

There was no fund received for this study.

REFERENCES

3. Elsaih E A. Effect of flexible acrylic to substitute metal in implant supported removable partial denture on abutments clinical and radiographic outcome. *EDJ* .2020; 66:1373-82.
4. Helal M A, Amin H K, Alkhairy Y M. Stress analysis of different designs of distal extension partial dentures with pure abutments: (a finite element analysis). *EDJ*.2015; 61:1451-7.
5. Nayar S, Bhuminathan S, Mahadevan R. Combination restoration in full mouth rehabilitatio. *J Pharm Bioallied Sci*. 2015; 7:288-90.
6. Angadi PB, Aras M A, Williams C. Precision attachments; applications and limitations. *J Evol Med Dent Sci*.2012; 1:1118-26.
7. Limeira F I R, Yamauti M. Rehabilitation with fixed prosthodontics associated with removable partial prosthesis: a 5-year follow-up clinical evaluation. *Con temp Clin Dent*.2019; 10:561-4.
8. Shetty NB, Shetty S E N, Shetty O, D'souza R. Precision attachments for aesthetics and function: a case report. *J Clin Diagn Res*. 2014; 8:268-70.
9. Darwish E T, El khourazaty N. Evaluation of bone height changes and biting forces in distal extension prosthesis with different denture base materials. *EDJ*.2018; 64: 1397-404.
10. Mardolkar S, Patil R, Karni P. Unique, cost-effective, and retentive removable prosthesis to rehabilitate long span kennedy's class I edentulism with custom attachment system: a case report. *J Contemp Dent Pract*.2020; 21:215-8.
11. El-asfahani I A, Nawar N H. The effect of using different designs on distal implant for treatment of mandibular kennedy class II cases. *EDJ*.2019; 65: 1897-905.
12. Agdive S B, Shah R J, Shrof S N. Equilibrating functional stability with aesthetic harmony in kennedy class II saddle area using precision attachment: a dexterous alternative to implants. *Int J Recent Sci Res*. 2017; 8: 15769-72.
13. El-Okl A B, El Samahy M, Amin H K. Stresses induced by integrated and' nonintegrated extracoronal semi-precision attachments for maxillary distal extension bases. *ADJG*.2018; 5:297-304.
14. Gupta S, Kumar V, Krishnan Y. Tooth supported overdenture- A preventive approach in prosthodontics. *Int J Oral Health Dent*.2018; 4; 184-7.

15. Kapila S D, Nervina J M. Cbet in orthodontics: assessment of treatment outcomes and indications for its use. *Dento maxilla fac Radiol.*2015; 44:20140282.
16. Khedr M F, Amer A M, Keibah S M. Comparison between cone-beam computed tomography and intraoral radiography to diagnose periodontal bone defect and treatment response. *AJDSM.*2017; 20:130-7.
17. AlmEldeen H I. Effect of reciprocal arm on the supporting structures of the abutments in cases retained by unilateral attachment. *EDJ.*2017; 63:933-9.
18. Nayakar R P, Simha Y N. Prosthodontic rehabilitation of a patient with kennedy's class I and class II using an extended precision attachment. *wjd.*2020; 3:226-30.
19. Afify M, Helmy M. Evaluation of biting force of new design of extra coronal castable precision attachment versus conventional partial denture for treatment of unilateral mandibular distal extension area: a randomized controlled trial. *OA Maced J Med Sci.*2020; 8:23-8.
20. Helal E, Esmat A M, Eissa S M. Amount of bone loss and digital occlusal analysis of different attachment designs in bilateral distal extension partial denture cases. *IJAR .*2020; 12:431-8.