



## Comparison between Two Computer Designed Custom Made Miniplates for The Treatment of Mandibular Angle Fractures

Aya A. Ahmed <sup>1\*</sup>, Susan A. Hassan <sup>2</sup>, Fatma I. Mohamed <sup>3</sup>, Usama A. El Dakrory <sup>4</sup>

Codex : 12/22.10

azhardentj@azhar.edu.eg

http://adjg.journals.ekb.eg

DOI: 10.21608/adjg.2022.104155.1453

Oral Medicine & Surgical Sciences  
(Oral Medicine, Oral & Maxillofacial  
Surgery, Oral Pathology, Oral Biology)

### ABSTRACT

**Purpose:** To evaluate the clinical and radiographic outcomes of mandibular angle fractures (MAF), which were managed with two different computer designed custom made miniplates. **Materials and Methods:** Eight patients complaining of MAF were included in this study and divided into two equal groups. In group 1, the MAF were fixed with regular design custom made miniplates that were adapted at the superior border of external oblique ridge. Patients in group 2 received custom made miniplates with one straight section adapted to the superior border of external oblique ridge and two lateral extensions adapted to the buccal cortex; proximal and distal to the fracture line. Reduction and fixation were performed through intraoral approach. Preoperative evaluation comprised assessment of subjective pain using a visual analogue scale (VAS), maximal interincisal opening (MIO), occlusal relation, maximal bite-force (MBF), and radiographic measures of fractured segments displacement. Follow up was performed along 6 months to detect changes in the same preoperative parameters. Demographic, clinical, and radiographic data were recorded and analyzed statistically. **Results:** No statistical significant difference was observed between the two computer designed custom made miniplate designs. **Conclusion:** Using a traditional and modified design custom-made miniplate, MAF may be appropriately managed. The newly designed miniplate is considered a treatment modality in management of MAF.

### KEYWORDS

*Custom Made Miniplate,  
Patient Specific Plate,  
Mandibular Angle Fractures.*

- Paper extracted from Master thesis titled “Comparison between Two Computer Designed Custom Made Miniplates for The Treatment of Mandibular Angle Fractures”
- 1. Demonstrator at Oral and Maxillofacial Surgery Department, Faculty of Oral and Dental Surgery, Misr University for Science and Technology, Cairo, Egypt
- 2. Professor of Oral and Maxillofacial Surgery, Faculty of Dental Medicine for Girls, Al-Azhar University, Cairo, Egypt
- 3. Professor and Head of Oral and Maxillofacial Surgery Department, Faculty of Dental Medicine, Deraya University, Menya, Egypt
- 4. Lecturer of Oral and Maxillofacial Surgery, Faculty of Oral and Dental Medicine, Misr University for Science and Technology, Cairo, Egypt

\* Corresponding author email: aya.ayman@must.edu.eg

## INTRODUCTION

Mandibular angle fracture (MAF) treatment aims to restore the anatomy and function with consideration to re-establish the pre-trauma occlusal relation<sup>(1,2)</sup>. The use of plates and screws for open reduction and rigid internal fixation (ORIF) has been considered a cornerstone for maxillofacial fracture treatment, as it eliminates the requirement for intermaxillary fixation (IMF) and allows for early function with rapid osseous healing<sup>(3)</sup>.

Champy<sup>(4)</sup> stated that the miniplates system provides appropriate support and stability for the bone segments to function immediately. In comparing one miniplate to two miniplates fixation, it was found that using of one miniplate placed on the external oblique ridge through intraoral approach is associated with about 30% reduction in surgical complications associated with ORIF performed through extraoral approach such as, flap dehiscence, failure of plates, scar formation, weakening of the facial nerve, and tissue morbidity<sup>(5)</sup>. A new miniplate has been designed, which basically has one straight section adapted to the superior border of the external oblique ridge and two lateral extensions adapted to the buccal cortex, proximally and distally to the fracture line to had the advantage of reduction of lateral displacing forces exerted on the miniplate<sup>(6)</sup>.

The innovation of advanced technologies such as additive manufacturing (AM) and three-dimensional (3D) printing, computer-assisted surgical simulation (CAS), and their applications in the field of oral and maxillofacial surgery (OMFS) has contributed to develop virtual implementations to simulate the cutting, manipulation, and reduction of bone segments, then based on computer-designed digital files from patient's Computed Tomography (CT), custom made plate or patient-specific implant (PSI) is designed with precise reduction and fixation. As a result, custom made plate or PSI can be applied without bending, in addition to advantages of providing rigid fixation, facilitating intraoperative surgical procedures, reducing operation time, and improving surgical accuracy, making it safer, more dependable, and predictable<sup>(7,8)</sup>. Custom made

plates are currently used in the field of OMFS for management of facial fractures, total temporomandibular joint (TMJ) replacement, orthognathic surgery, and reconstruction of maxillofacial skeleton<sup>(9)</sup>.

Therefore, the aim of this study was to evaluate the clinical and radiographic outcomes of MAF managed with two different computer designed custom made miniplates based on clinical parameters including assessment of subjective pain using visual analogue scale (VAS), maximal interincisal opening (MIO), occlusion relation, maximal bite-force (MBF), and radiographic linear measurements of the displaced fractured segments using CT.

## MATERIAL AND METHODS

This prospective comparative study included eight adult patients who had criteria of; displaced MAF requiring ORIF, ability to attend regular follow-up visits, seek for intervention in time less than four weeks from trauma, and ability to complete clinical and radiographic records. The patients were excluded if they had comminuted MAF, infected fracture line, and if they receive radio- or chemotherapy. Patients with systemic diseases that could interfere with bone healing or lead to pathological fracture were also excluded. All patients were informed about the research and a written informed consent was obtained from all patients. The local ethics review committee of the Faculty of Dental Medicine for Girls at Al-Azhar University has approved the study with Code: REC-SU-21-05. Patients were randomly divided into two equal groups based on the design of the bone plate. Group I, in which MAF was reduced and fixed with computer designed straight custom made titanium miniplate that was adapted to the superior border of the external oblique ridge according to the Champy principle. Group II, where MAF was fixed using computer designed custom made miniplate which has one straight part and two lateral extensions. The straight miniplate was adapted to the superior border of the external oblique ridge while the two lateral extensions were adapted to the buccal cortex proximal and distal to the fracture line.

Preoperative clinical examination was performed for all patients. A high-resolution multi-slice CT (field of view, 20 cm; pitch, 0.5 mm slice thickness Aquilion 64 computed tomography, Toshiba, Japan) was requested and scan data were imported as Digital Imaging and Communications in Medicine (DICOM) which loaded into Materialise Interactive Medical Image Control System Mimics19.0 (Materialise, Leuven, Belgium) to illustrate the axial, coronal, and sagittal views, then 3D model of patient's skull was computed. Segmentation process was performed to reduce the fractured mandibular segments virtually in centric occlusion position with mandibular condyles in centric relation to glenoid fossa. Each fracture segment became a separate object that could be moved or rotated in all directions for the virtual operation.

Once the fractured segments were realigned, 3-matic11.0 (x64) software was used to perform the virtual titanium miniplate according to the mandibular 3D reduced model. Both plate designs had intimately adapted fitting surfaces so, the straight section of the plate fits on the superior border of the external oblique ridge. The mandible wrapped on software to allow local smoothening of the mandible at the site of plate to be performed to smoothen the fitting surface of the plate. Elliptical patches were placed at the site of the 6 holes with minimum diameter of 5 mm, the six holes were designed so that, three holes proximal to the fracture line and three holes distal to the fracture line. Elliptical patches

were connected by smooth curve and merged with a uniform offset of the plate design of 1mm. The superior surface was finished to have a smooth edge, screws were placed then merged together to be subtracted from the plate (Fig. 1), then projects was extracted as Standard Tessellation Language (STL) files.

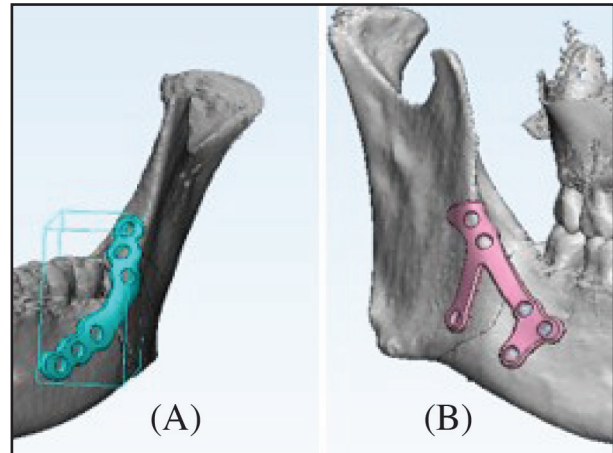


Figure (1) Designed plates for group 1 (A) and group 2 (B)

The STL file was sent to Arab Engineering company (Egypt) to be manufactured, a computer numerical control (CNC) milling machines used to cut the shape of each CT 'slice' from a solid block of titanium using Computer-aided design and computer-aided manufacturing (CAD/CAM), that reconstruct a plate with six screw holes with diameters of 3.0 mm and spacing of 2.0-.3.0 mm. (Fig. 2).




Figure (2) (A) STL and (B) printed 6-holes custom made plate for group I , (C) STL and (D) printed 6-holes custom made plate for group II.

All patients were hospitalized to receive the preoperative preliminary treatment, in addition to reduce the bone segments using intermaxillary fixation (IMF). The custom made miniplates were sterilized before operation. Surgical procedures were performed under general anesthesia and MAF were approached in all patients through an intraoral vestibular incision. Bone segments were manipulated to ensure free mobility at the fracture line. Manual reduction to the proper anatomical position was performed with guidance of occlusion. In group I, a straight six holes custom made titanium miniplate was properly seated on the superior border of the external oblique ridge with equal numbers of screw-holes on each side of the fracture line with broad bone contact underneath each screw hole. In group II, six holes custom made straight titanium miniplate with two lateral extensions was used. The straight miniplate was seated on the superior border of the external oblique ridge while the two lateral extensions were seated on the buccal cortex proximal and distal to fracture line, with equal numbers of screw holes on each side of fracture line (Fig.3). Monocortical screws were used to avoid damage to the mandibular canal. With the aid of transbuccal trochar, screws were inserted into the buccal arms holes. In all patients, closure of the wound was carried out in one layer using Vicryl 3-0 suture.

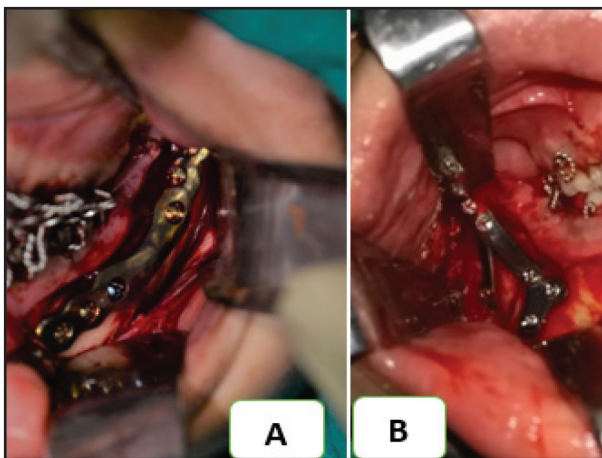


Figure (3): A. fixation of plate group I and B. fixation of plate group II

Clinical examination were performed for all patients, immediately postoperatively, one, three, and six months postoperative. VAS was used to assess for pain magnitude, and MIO was measured in mm. Also, occlusion was examined to detect the maximal intercuspal position to ensure proper pretraumatic occlusal relationship and midline centralization. Lastly, MBF was recorded through a custom bite force gauge using an “Arduino Uno board and load cell” (Arduino Uno R3, Load Cell - 200kg, Disc (TAS606) and Load Cell Amplifier - HX711, Spark Fun Electronics Inc, USA).

Radiographic examination was performed immediately and at six months postoperatively. Postoperative CT data was collected as DICOM file to be converted into 3D model on MIMICS software. Anatomical landmarks placed on the 3D model<sup>(10)</sup> including, lateral condyle (La) which is the most lateral point of the condyle while, medial condyle (MC) is the most medial point of the condyle. Gonial point (Go) represents the mandibular angle, and intercondylar angle (ICA) is the angle between two mediolateral condylar lines and is measured in the axial plane. Distances between the corresponding anatomical landmarks were measured, M1 (right and left La), M2 (right and left MC), M3 (right and left Go), M4 (right MC and left Go), and M5 (left MC and right Go). (Fig. 4)

### Statistical Analysis

Numerical data were shown as mean and standard deviation (SD) values. Data showed parametric distribution, based on this, data analysis were performed using independent t-test in case of intergroup comparisons, while intragroup comparisons were analyzed using one-way repeated measures ANOVA followed by Bonferroni post hoc test. Significance level was set at ( $p \leq 0.05$ ). Statistical analysis was performed with R statistical analysis software version 4.1.1 for Windows (R Core Team (2021). R: A language and environment for statistical computing. R Foundation for Statistical Computing, Vienna, Austria. URL: <https://www.R-project.org/>



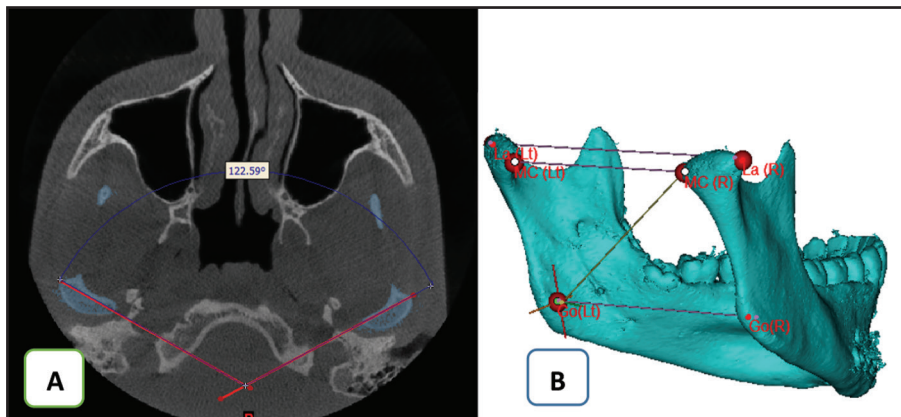


Figure 4: (A) Intercondylar angle (ICA) and (B) linear of measurements (M1, M2, M3 and M4)

**RESULTS**

A total of eight patients (5 males and 3 females) with MAFs were included in this study, seven patients with unilateral MAFs with or without contralateral parasymphaseal fracture and one patient with bilateral MAF. The mean age of the patients was  $22.6 \pm 5.7$  years at the time of surgery. All patients underwent ORIF by custom made six holes bone miniplates through intraoral incision, four patients in group I and four patients in group II. The most frequent cause of trauma was motor vehicle accident (MVA) in five patients (62.5 %), followed by interpersonal violence (IPV) in two cases (25%), and fall from height (FFH) in one patient (12.5%), two cases had isolated right MAF, two cases had right MAF with contralateral parasymphaseal fracture, three cases had left MAF with contralateral parasymphaseal fracture and one patient had bilateral MAFs. The time interval between the trauma and the primary surgical intervention ranged from 3 to 18 days. Regarding the affection of the inferior alveolar nerve (IAN), preoperative numbness was observed in all patients, which gradually improved by time and completely resolved in the first postoperative month in six patients, by third month in one patients and one patient by the end of the follow up period. Preoperative malocclusion was observed in all cases that improved completely postoperatively, two patients had skeletal cl III malocclusion as a

pretraumatic occlusion. Wound dehiscence was observed immediately postoperative in only one patient in group I. The demographic and clinical features of the study’s patients are summarized in table (1).

**Table (1)** Demographic data for the two groups

Study variables	Group I	Group II
Age (years):	22.6±5.7	22.6±3.1
Male/Female	1/3	4/0
<b>Etiology:</b>		
MVA	3	3
IPV	0	1
FFH	1	0
<b>IAN numbness:</b>		
Preoperative	4	4
3 month post	0	1
6 months post	0	0
<b>Associated OMF injuries:</b>		
Bilateral MAF	0	1
Parasymphaseal	3	2
ZMC and orbit	0	2
<b>Wound dehiscence</b>	1	0
<b>MIO:</b>		
Preoperative (normal/limited)	2/2	1/3
After follow-up period (normal/limited)	4/0	4/0

VAS scores, in every group, showed significant difference between values measured at different follow-up periods ( $p < 0.05$ ). In group I, the mean value of the preoperative VAS was significantly

greater than the value of the other follow-up periods, except the immediate postoperative records. Also in group II, there was significant increase in the immediate post-operative values of VAS when compared to the other postoperative follow-up periods. However, there was no significant difference between both groups ( $p>0.05$ ) along the follow-up periods, as shown in table (2).

**Table (2)** VAS mean values for the two groups

Interval	VAS		p-value
	Group (I)	Group (II)	
Pre-operative	5.5±1.3 <sup>A</sup>	4.8±0.9 <sup>AB</sup>	<b>0.5</b>
Immediately post-operative	5.3±1.5 <sup>AB</sup>	5±1.4 <sup>A</sup>	<b>0.9</b>
After 1 month	1±0.8 <sup>AB</sup>	1.3±0.5 <sup>AB</sup>	<b>0.7</b>
After 3 months	0.3±0.5 <sup>AB</sup>	0 <sup>B</sup>	<b>0.5</b>
After 6 months	0 <sup>B</sup>	0 <sup>B</sup>	<b>1</b>
<b>p-value</b>	<b>0.005*</b>	<b>0.004*</b>	

Data presented as mean±SD.

\* Significant  $p$ -value  $\leq 0.05$

Different superscript letters indicate a statistically significant difference within the same group.

Regarding the MIO results, patients in both groups showed reduction in MIO values during the preoperative and immediate postoperative periods to be improved along the whole follow-up periods with maximum improvement at the 6 months follow-up period. The mean value of MIO within both groups showed a significant difference ( $p<0.001$ ) along the different follow-up periods. Comparison of MIO values between the two groups showed no statistical significance difference during the whole periods of follow-up except at the period of 6 month postoperatively where one case in group I showed inflammation related to ipsilateral impacted lower third molar, which was associated with pain and trismus that affected the MIO of this patient resulting in significant difference between both groups at that specific period of follow-up ( $P=0.02$ )(Table 3).

**Table (3)** Mean values of MIO (mm) for the two groups

Interval	Maximum mouth opening (mm)		p-value
	Group I	Group II	
Pre-operative	26.00±6.48 <sup>CD</sup>	28.75±4.35 <sup>CD</sup>	<b>0.5</b>
Immediately post-operative	24.00±6.98 <sup>D</sup>	26.50±5.20 <sup>D</sup>	<b>0.6</b>
After 1 month	31.75±6.65 <sup>BC</sup>	34.00±2.71 <sup>C</sup>	<b>0.6</b>
After 3 months	33.75±7.89 <sup>AB</sup>	46.25±7.76 <sup>B</sup>	<b>0.1</b>
After 6 months	40.00±8.64 <sup>A</sup>	54.50±4.36 <sup>A</sup>	<b>0.02*</b>
<b>P- value</b>	<b>&lt;0.001*</b>	<b>&lt;0.001*</b>	

Data presented as mean±SD.

\*Significant  $p$ -value  $\leq 0.05$

Different superscript letters indicate a statistically significant difference within the same group.

Occlusal relationship including upper and lower molars relation and midline centralization was examined within each group along the whole period of follow-up. In group I, one case showed disturbed occlusion immediately postoperatively which improved by elastics by the end of the first follow up month. On the other hand, two patients in group II showed unaccepted occlusal relationship immediately postoperative, one of them improved on elastics on the first week and the other improved by the end of first follow up month. At the 6 months post-operatively, all patients showed improvement of the occlusal relationship with accepted results. Within each group, there was a significant difference between values recorded at pre- and postoperative follow-up periods ( $p<0.05$ ). On comparing results between the two groups in all follow up periods, no significant difference was observed (Table 4).

The value of MBF, within each group, showed a significant difference at different follow up periods ( $p<0.001$ ). At 6 months postoperative, the values for the fractured side within group I and II, were found to be significantly higher than all other follow-up periods, while there was no significant difference between the values that measured

preoperatively, immediate and one month postoperatively ( $p < 0.001$ ). For non-fractured side in group I, the recorded value after 6 months was significantly higher than other follow-up periods except after 3 months ( $p < 0.001$ ). In group II, the measured values, at 6 months, were significantly higher than other follow-up periods ( $p < 0.001$ ). When comparing the values of MBF between the two groups, there was no significant difference for all time follow-up periods in both fractured and non-fractured sides ( $p > 0.05$ ) (Table 5).

**Table (4)** Number of patients with unacceptable occlusion in the two groups

Interval	Group I	Group II
Pre-operative	3	4
Immediately post-operative	1	2
Along follow up period	0	0
<b>p-value</b>	<b>0.046*</b>	<b>0.012*</b>

Data presented numbers of patients.

\* Significant  $p$ -value  $\leq 0.05$ .

**Radiographic linear measurements:**

Within each group, the values of M1, M3, M4 and M5 showed no significant difference along all follow-up periods ( $p > 0.05$ ). On the other hand, M2 showed that, for group I there was no significant difference between values measured at the follow-up periods ( $p = 0.645$ ), while results within group II showed statistically significant difference ( $p = 0.009$ ) as, value measured immediately postoperative was significantly higher than preoperative value ( $p < 0.001$ ) (Table 6).

**Table (6)** The mean values of M2 for the two groups

Interval			p-value
	Group (I)	Group (II)	
Pre-operative	75.87±5.48 <sup>A</sup>	78.85±1.64 <sup>B</sup>	<b>0.337</b>
Immediately post-operative	76.47±4.19 <sup>A</sup>	83.24±3.09 <sup>A</sup>	<b>0.041*</b>
After 6 months	75.63±4.02 <sup>A</sup>	81.01±1.18 <sup>AB</sup>	<b>0.042*</b>
<b>p-value</b>	<b>0.645</b>	<b>0.009*</b>	

Data presented as mean±SD.

\* Significant  $p$ -value  $\leq 0.05$ .

**Table (5)** Values of MBF for fractured and non-fractured sides for the two groups.

Interval	Non- Fractured side			Fractured side		
	Group I	Group II	p-value	Group I	Group II	p-value
Pre-operative	6.62±10.19 <sup>B</sup>	5.55±7.60 <sup>B</sup>	<b>0.871</b>	2.65±3.97 <sup>C</sup>	2.32±0.81 <sup>C</sup>	<b>0.876</b>
Immediately post-operative	3.31±2.36 <sup>B</sup>	6.13±9.39 <sup>B</sup>	<b>0.582</b>	2.32±1.18 <sup>C</sup>	4.97±7.08 <sup>BC</sup>	<b>0.488</b>
After 1 month	9.89±10.71 <sup>B</sup>	14.17±11.03 <sup>B</sup>	<b>0.597</b>	10.64±5.37 <sup>BC</sup>	9.69±4.26 <sup>BC</sup>	<b>0.790</b>
After 3 months	16.64±15.28 <sup>AB</sup>	19.54±14.13 <sup>B</sup>	<b>0.790</b>	16.97±9.12 <sup>B</sup>	12.58±3.63 <sup>B</sup>	<b>0.406</b>
After 6 months	33.44±21.07 <sup>A</sup>	50.00±24.14 <sup>A</sup>	<b>0.341</b>	31.54±11.62 <sup>A</sup>	29.06±9.49 <sup>A</sup>	<b>0.752</b>
<b>P-value</b>	<b>&lt;0.001*</b>	<b>&lt;0.001*</b>		<b>&lt;0.001*</b>	<b>&lt;0.001*</b>	

Data presented as mean±SD.

\* Significant  $p$ -value  $\leq 0.05$ .

Different superscript letters indicate a statistically significant difference within the same column.

Different superscript letters indicate a statistically significant difference within the same column.

Regarding linear measurements between the two groups recorded preoperative, immediately and 6 months postoperative, M1 results showed no significant difference along follow-up periods. On the contrary, M2, M3, M4 and M5 values were significantly higher in group II than in group I at different follow-up periods ( $p < 0.05$ ).

Regarding ICA, there was statistically significant difference ( $p = 0.044$ ) within group I, as the preoperative value was significantly higher than immediately postoperative value ( $p < 0.001$ ). On the other hand, group II showed no significant difference all over the follow-up periods ( $p = 0.303$ ). Comparison between both groups showed no significant difference ( $p > 0.05$ ). (Table 7).

**Table (7)** Shows the mean values of ICA for the two groups

Interval	Group		p-value
	Group (I)	Group (II)	
Pre-operative	147.22±13.88 <sub>A</sub>	135.23±5.99 <sup>A</sup>	<b>0.164</b>
Immediately post-operative	141.59±9.92 <sup>B</sup>	132.66±9.40 <sup>A</sup>	<b>0.239</b>
After 6 months	144.28±12.77 <sub>AB</sub>	139.59±0.80 <sup>A</sup>	<b>0.491</b>
p-value	0.044*	0.303	

Data presented as mean±SD

\* Significant p-value ≤ 0.05.

Different superscript letters indicate a statistically significant difference within the same column.

## DISCUSSION

Many treatment modalities have been used in management of MAF but ORIF still the gold standard<sup>(11)</sup>. Common complications associated with extraoral approach as facial scar, facial nerve affection, and prolonged intraoperative time<sup>(12)</sup>, making intraoral approach more favorable. According to Champy technique, intraoral incision and fixation

along the external oblique ridge is performed, but due to associated disadvantages<sup>(13)</sup> as splaying due to muscle force, facial widening with the possibility of malunion, low resistance to torsional lateral forces, poor rigidity, and reduced stability of angle fracture, modification of Champy technique was needed.

Selection of custom made plates was supported by many studies<sup>(7,14-16)</sup> as it provides the surgeon with a predesigned hardware with high accuracy that requires less intraoperative time and precise adaptation to bone which is linked to less tissue morbidity and reduced surgical complication which are important factors that influence the surgical outcome. This study presents a comparison between two computer designed custom made miniplates, one with standard design and the other with a newly design that had one straight section adapted to the superior border of external oblique ridge and two lateral extensions adapted to the buccal cortex; proximal and distal to the fracture line. The addition of the two buccal arms was tried to reduce the drawbacks linked with Champy technique such as inferior border distraction, and to reduce screws strain, counteract the masticatory muscles forces, reduce the lateral displacing forces exerted on the miniplate and improve healing as presented in many studies<sup>(6,17)</sup>.

VAS, for both groups, showed great improvement during the follow-up periods. Pain with higher VAS readings was recorded immediately postoperatively as a normal finding due to surgical manipulation of the soft tissues, fixation of the fractured segments and postoperative edema. Different studies<sup>(16,18,19)</sup> reported noticeable reduction of pain by the end of the first month, which is matching with the results of this study. On the contrary, another study<sup>(20)</sup> mentioned that pain was reduced directly on the first week postoperatively in 50% of patients. In the present study, VAS scores showed no significant difference between the two group along the whole follow up periods, this might be due to the effectiveness with which both custom made plate designs match.



Generally, both groups showed reduced MIO readings during the preoperative and immediate postoperative periods to be improved along the whole follow-up periods with maximum improvement at the 6 months follow-up. This is accordance to the results of many authors,<sup>(21,22)</sup> who observed that the reduction in the MIO immediately postoperatively is due to surgical interference with subsequent muscle stripping and trauma leading to muscle spasm, edema, and pain.

The improvement of MIO is due to establishment of proper alignment of the fractured segments, restoration of proper mandibular mechanics, and tissue healing, as also reported by Amr et al.,<sup>(18)</sup> This study reveals significantly higher value of MIO in group II than group I after 6 months, as MIO measurements affected by trismus occurred in one patient as a result from inflammation related to lower impacted third molar at the ipsilateral side, and hence the statistical significance. For other follow-up periods, there was no significant difference between both groups which mainly attributed to the comparable efficiency of the design in both plates.

Mild occlusal derangement was observed in in one patient in group I and two patients in group II immediately postoperatively that improved gradually and all patients showed a satisfactory occlusal relation with no significant differences between the two groups. These results are matching with the findings of Subramaniyan et al.<sup>(22)</sup>. On the other hand, another study<sup>(20)</sup> stated that about 83% of cases required postoperative IMF for maximum of two weeks to attain satisfactory occlusion.

In the current study, we used MBF as an assessment measurement which was also used in different studies<sup>(23,24)</sup>. The low recorded MBF at the preoperative and immediate postoperative periods is due to pain, discomfort and decreased intrinsic strength or size of the related muscles of mastication. This explanation is coincident with what reported by Khiabani et al.,<sup>(23)</sup> who also added that, the low observed values may be a result of protective neuro-

vascular mechanism performed by the central nervous system. Generally, in both groups, values measured at 6 months postoperatively are significantly higher than values recorded at all follow-up periods which is also mentioned in another study<sup>(19)</sup>. Our results showed that, for all follow-up periods, fractured and non-fractured sides showed no significant difference between both groups, we can relate this again to the matching efficiency of both designs of custom made plates.

According to this study, the linear radiographic measurements (M1, M3, M4 and M5) showed that there is no significant difference within each group along the follow-up periods, this means that fractured segments maintain their postoperative positions along the whole follow-up periods. This can be attributed to the stability of the fractured bone segments, resistance of torsion and splaying achieved by both custom made plate designs. Only M2 in group II and ICA in group I showed significant difference between the immediate postoperative and preoperative measures which may be due to minor discrepancy in the radiographic points recording during usage of software, resulting in change in the linear radiographic measurements or ICA, this is coinciding with what reported in another study<sup>(10)</sup>.

## CONCLUSION

Using a traditional and modified design custom-made miniplate, MAF may be appropriately managed. The newly designed miniplate is considered a treatment modality in management of MAF.

## ACKNOWLEDGMENT

I would like to thank Professor Tamer M. Nassef head of computer and software Engineering, Misr University for science and technology, Professor Ashraf Mahroos Said Professor of Computer and Software engineering, Misr University for science and technology for helping me in building the force measuring system. Also, I would like to thank Eng. Mazen M. Yassin research assistant at Biomedical

engineering department, faculty of engineering, Minia University for calibrating our system, Dr Ahmed Morad assistant lecturer in Misr University for science and technology for his valuable work in computer-assisted design and rapid prototyping.

## RECOMMENDATION

Incorporation of a readymade plate with the new design in the commercial plating system to benefit from the advantages associated with its usage in treatment of MAF.

## Funding:

This research is self-funded.

## Conflict of Interest:

The authors have no conflict of interest relevant to this study.

## REFERENCES

- Cleveland CN, Kelly A, DeGiovanni J, Ong AA, Carr MM. Maxillofacial trauma in children: Association between age and mandibular fracture site. *American J Otolaryngol.* 2021; 42:102-9.
- Chodroff J, Elias N, Whitcomb M, Vo C, Bell RB. Secondary Correction of Midface Fractures. *Atlas of the oral and maxillofacial surgery clinics of North America.* 2021; 29:139-50.
- Pal US, Ganguly R. *Angle and Ramus Fractures.* In *Maxillofacial Trauma 1st ed* Springer, Singapore.2021; 203-15.
- Champy M, Lodde JP, Schmitt R, Jaeger JH, Muster D. Mandibular osteosynthesis by miniature screwed plates via a buccal approach. *Journal of maxillofacial surgery.* 1978; 6:14-21.
- Rai A. Fractures of the Mandible. *Oral Maxillofac Surg Clinician.* 2021; 1:1053-84.
- Suer B, Kocyigit I, Kaman S, Tuz H, Tekin U and Atil F. Biomechanical evaluation of a new design titanium mini-plate for the treatment of mandibular angle fractures. *Int J oral maxillofac surg.* 2014; 43: 841-5.
- Alauddin MS, Baharuddin AS, Mohd Ghazali MI. The Modern and Digital Transformation of Oral Health Care: A Mini Review. *InHealthcare, Multidisciplinary Digital Publishing Institute.* 2021; 9:118-9.
- Panneerselvam E, Ravi P, Sasikala B. Fractures of the Zygomaticomaxillary Complex. In: *Oral Maxillofac Surg Clinician.* 2021: 1151-99.
- Goodson AM, Parmar S, Ganesh S, Zakai D, Shafi A, Wicks C, et al. Printed titanium implants in UK cranio-maxillofacial surgery. Part I: access to digital planning and perceived scope for use in common procedures. *British J Oral Maxillofac Surg.* 2021; 59:312-9.
- Naros A, Weise H, Tilsen F, Hoefert S, Naros G, Krimmel M, et al. Three-dimensional accuracy of mandibular reconstruction by patient-specific pre-bent reconstruction plates using an "in-house" 3D-printer. *J Cranio-Maxillofac Surg.* 2018; 46:1645-51.
- Kazi AA, Lee TS, Vincent A, Sokoya M, Sheen D, Ducic Y. The role of external fixation in trauma and reconstruction of the mandible in the age of rigid fixation. *Facial Plast Surg.* 2019; 35:614-22.
- Bruneau S, Courvoisier DS, Scolozzi P. Facial nerve injury and other complications following retromandibular subparotid approach for the management of condylar fractures. *J Oral Maxillofac Surg.* 2018; 76:812-8.
- Mannan R, Farooq A, Mukhtar H. Comparison of single vs double miniplates in the management of mandibular angle fractures. *Pakistan J Medic Health Science.* 2018; 12:662-4.
- Yang WF, Zhang CY, Choi WS, Zhu WY, Li DT, Chen XS, et al. A novel surgeon-dominated approach to the design of 3D-printed patient-specific surgical plates in mandibular reconstruction. *Int J Oral Maxillofac Surg.* 2020; 49:13-21.
- Lee ZH, Avraham T, Monaco C, Patel AA, Hirsch DL, Levine JP. Optimizing functional outcomes in mandibular condyle reconstruction with the free fibula flap using computer-aided design and manufacturing technology. *J Oral Maxillofac Surg.* 2018; 76:1098-106.
- Elsayed SA, Mohamed FI, Khalifa GA. Clinical outcomes of three different types of hardware for the treatment of mandibular angle fractures: a comparative retrospective study. *Int J Oral Maxillofac Surg.* 2015; 44:1260-7.
- Ramos A, Semedo T, Mesnard M. Study of fixation of a mandibular plate for favourable fractures of the mandibular angle: numerical predictions. *Br J Oral Maxillofac Surg.* 2020; 58:652-8.
- Amr K, Hatem H, Shehab MF. Patient-specific Computer modified titanium plate in Unilateral angle fractures. *Egypt Dent.* 2019; 65:135-41.

19. Yadav S, Mohanty S, Sharma P, Kohli S, Singh C, Dabas J. Conventional 2D miniplate versus 3D four-holed and eight-holed miniplates in the management of mandibular angle fractures. *J Oral Maxillofac Surg.* 2020; 32:336-41.
20. Mathew N, Singh I, Gandhi S, Solanki M, Bedi NS. The Efficacy of Fixation of Unilateral Mandibular Angle Fracture with Single 3D Plate vs Single Miniplate Using Transbuccal Approach. *J Maxillofac Oral Surg.* 2020; 19:1-8.
21. El-Anwar MW, El-Ahl S and Amer HS. Open reduction and internal fixation of mandibular fracture without rigid maxilla-mandibular fixation. *Int Arch Otorhinolaryngol.* 2015; 19:314-8.
22. Subramaniyan D, Sathyanarayanan R, Suresh V, Subramaniyan M, Guna TP. A comparative study evaluating the efficacy of 2.0-mm mini locking plate and 2.0-mm three-dimensional locking miniplates in mandibular angle fractures. *Formosan J Surg.* 2021; 54:61-7.
23. Khiabani K, Keyhan SO, Razmdideh R, Chaleh ZC, Amirzade-Iranaq MH. Effect of different miniplate osteosynthesis in different mandibular angle fracture patterns on bite force: A 3D finite element analysis. *J Oral Maxillofacial Surg Med Pathol.* 2018; 30:324-9.
24. Schaller A, Voigt C, Huempfer-Hierl H, Hemprich A, Hierl T. Transient finite element analysis of a traumatic fracture of the zygomatic bone caused by a head collision. *International journal of oral and maxillofacial surgery.* 2012; 41:66-73.