



Efficacy of Aloe vera in Treatment of Experimentally Induced Oral Lichenoid Reaction

Hind M. Mohmed^{1*}, Mai Sh. Attia², Lobna M. Abd-Alaziz³, Aya M. Dawaba⁴, Noura M. Bakr⁵

Codex : 13/22.10

azhardentj@azhar.edu.eg

http://adjg.journals.ekb.eg

DOI: 10.21608/adjg.2022.124429.1472

Oral Medicine & Surgical Sciences
(Oral Medicine, Oral & Maxillofacial
Surgery, Oral Pathology, Oral Biology)

ABSTRACT

Purpose: the present study was conducted to compare the efficacy of herbal treatment using Aloe Vera in induced lichenoid reaction versus topical steroids. **Materials and methods:** thirty-six rats were divided into four groups: **1stgroup** control normal group with no induced oral lesions, **2ndgroup** (Negative control group) with induced oral lesions but no treatment was used, **3rdgroup** (Positive control group) treated with triamcinolone acetonide 0.1% paste, in the **4thgroup**(Aloe vera group) treated with topical Aloe vera gel, rats in the 3rd and 4th groups are treated topically for 15 days, samples were taken from the buccal mucosa after the end of the study and sent for histological examination. **Results:** Histological sections revealed there was a decrease of inflammatory and dysplastic changes of the 3rd and 4th groups in comparison to the 2nd group which received no treatment. **Conclusion:** Aloe vera might be considered as an accepted alternative treatment option due to their anti-inflammatory, anti-oxidant and anti-neoplastic properties with compared to steroid therapy.

KEYWORDS

Captopril, Aloe Vera,
Steroid, Histological Study

- A paper extracted from Master Thesis titled “Expression of CD8 in Experimentally Induced Lichenoid reaction after Treatment with Aloe vera versus Curcumin”

- 1.
2. Dentist at Al-Azhar Medical Teaching Hospitals.
3. Professor of Oral medicine, Periodontology, Diagnosis and Radiology, Faculty of Dental medicine for girls Al-Azhar University, Faculty of Oral and Dental medicine, Misr International University, Cairo, Egypt.
4. Lecturer of Oral medicine, Periodontology, Diagnosis and Radiology. Faculty of Dental medicine for girls, Al-Azhar University, Cairo, Egypt.
5. Associated professor of pharmaceuticals and industrial pharmacy, Faculty of pharmacy for girls, Al-Azhar University, Cairo, Egypt.
6. Lecturer of Oral and Dental Biology, Faculty of Dental medicine for girls, Al-Azhar University, Cairo, Egypt.

* Corresponding author email: drhind26@gmail.com

INTRODUCTION

Drug-induced oral lichenoid reactions (OLR) are lesions that resemble oral lichen planus clinically and histologically. Angiotensin-converting enzyme inhibitors (ACEI) and non-steroidal anti-inflammatory medicines (NSAIDs) are the most usually implicated pharmaceuticals in the incidence of Lichenoid reaction^(1,2).

Buccal mucosa, tongue, gingiva, lips, and palate are affected by OLR. OLR occurs in different patterns including reticular, erythematous, erosive, ulcerative, bullous and atrophic. Some research showed that, the prevalence of OLR in general population has been estimated to be about 2.4 percent with a higher prevalence identified among women, and among adults 40 years and older⁽¹⁾.

Drug-induced lesions are difficult to manage, especially when they occur in patients with systemic diseases who are taking multiple medications that cannot be replaced because they put the patient's health at risk. These patients require alternative treatment methods because some of these medications are life-saving⁽³⁾.

Steroids recognised as the gold standard medications and the most extensively utilised for treatment of this illness. The most common treatments for LP and OLR are topical and systemic steroids⁽⁴⁾. However, because of the chronic nature of the disease, which necessitates long-term use of these drugs, many patients experience severe side effects, necessitating an ongoing search for an effective herbal drug as an alternative effective and safe treatment⁽⁴⁾.

Due to its anti-inflammatory, anti-oxidant, antimicrobial, and anti-neoplastic properties, Aloe vera may be considered an acceptable alternative treatment option in this condition with minimal or no side effects^(5,6,7,8). Aloe vera was found to be efficient in treating different inflammatory diseases includ-

ing OLR. Different studies evaluate different forms of topical Aloe vera and reported the effectiveness of Aloe vera in treatment of oral symptomatic lichen planus with minimal side effects^(5,9). Therefore, this study was conducted to evaluate the effect of topical Aloe vera gel in treating orally induced lichenoid lesions.

MATERIAL AND METHODS

Study design

The study conducted on a 36 healthy, pathogen-free adult male Wister rats weighting 175-210 grams with a mean age of 7-8 weeks. Rats were kept in a standard temperature (22+/-3), humidity (50+/-5%) and atmosphere in a well-ventilated housing room in stainless steel cages (5 rats / cages) and fed a standard balanced commercial pelleted diet, dry row chow and water.

The procedures conducted in accordance with the committee for the purpose of control and supervision on experiments performed on animals. The experiment was approved by ethical committee of faculty of dental medicine for girls of, Al-Azhar University (REC-ME-21-02).

The following materials were used:

- Captopril commercially available as capotril 50mg from Egyptian International Pharmaceuticals Industries Company, Egypt
- Aloe vera gel which prepared by the Faculty of Pharmaceutical Sciences Al-Azhar University for Girls as follows (70% Aloe vera mucilage, sorbitol, potassium sorbate, sodium metabisulphite and hydroxy ethyl cellulose). One-half gram was used for each application.
- Triamcinolone acetonide paste 0.1% commercially available as topicort from Pharco Pharmaceuticals, Egypt. One-half gram was used for each application.

Study grouping

The thirty-six rats were divided into four groups:

- **1stgroup** (Control normal group) with no induced oral lesions.
- **2ndgroup** (Negative control group) with induced oral lesions but no treatment was used.
- **3rdgroup** (positive control group) treated with triamcinolone acetonide 0.1% paste.
- **4thgroup** (Aloe vera group) treated with topical Aloe vera gel.

Lichenoid reactions were induced by injecting the rats by captopril daily with a dose equivalent to 450 mg human dose, we use (**Paget and Barnes formula**, 1964) for calculation of animal dose which was be =human dose x .018 /200g of the rat⁽⁸⁾.

Unlike other groups, rats in the first group were not given captopril injections, hence they did not develop any lesions. These normal rats were utilised to demonstrate the normal histologic characteristics of the oral tissues. Rats of 2nd group developed lesions after captopril injection but no treatment was used in this group, it was utilised to display the lesion's histopathologic characteristics and to contrast it with the two previously treated groups, which were anticipated to exhibit some degree of healing.

Minor clinical changes start to appear after 2 weeks of injection in the form of white areas which may reflect hyperkeratosis. By the end of sixth week all rats required by the study developed pronounced white areas intermixed with erythematous areas mainly in the buccal mucosa and minority in the palate. After 7 weeks of captopril injection rats of the 3rd and 4rd groups received topical treatments for 15 days, the treatment applied topically using ear cotton cores in two circles each of which last about three minutes for each rat. By the end of the ninth week, rats were euthanized using large dose of

ether. Samples were taken from the buccal mucosa for histological examination after fixation in 10% formaldehyde, kept in wax blocks and then slices were taken and stained with haematoxylin & Eosin.

RESULTS

Histological sections of the 1st group (Control normal group) showing intact keratinized (blue arrow) epithelium with intact regular basal layer (green arrows), normal lamina propria with normal architecture of blood vessel (green arrow) and collagen fibers (fig.1-A).

While 2nd group (Negative group) showed; hyper keratinized epithelium, loss of basal cells polarity (yellow arrows), civatte bodies were observed indicating dead keratinocytes, mild dysplastic changes of epithelial cells, loss of normal architecture of rete pegs, disrupted basement membrane integrity (red arrows), intraepithelial lymphocytic infiltrate (green arrows), intense mixed inflammatory cells infiltrate in the C.T. (blue arrows) (fig.1-B).

As regards the 3rd group (Steroid group) showed; Slightly hyperplastic stratified squamous epithelium, there is no civatte bodies or basal cell degeneration, B.M appears to be disrupted in some areas and intact in the others (blue arrows), moderate inflammatory cell infiltrate (green arrows), dilated B. Vs engorged by RBCs (yellow arrows), some vacuolated area also appears in the C.T (green arrows) (fig.1-C).

Moreover, in the 4th group (Aloe vera group) there was; Slightly normal stratified squamous epithelium; relatively normal thickness of keratin layer (green arrow), return integrity of basal cell layer (black arrows), there is no or mild hyperplasia of epithelial cells, there are no signs of epithelial dysplasia, uniform thickness of rete pegs (yellow arrows), and mild inflammatory cell infiltrate (blue arrows) (fig.1-D).

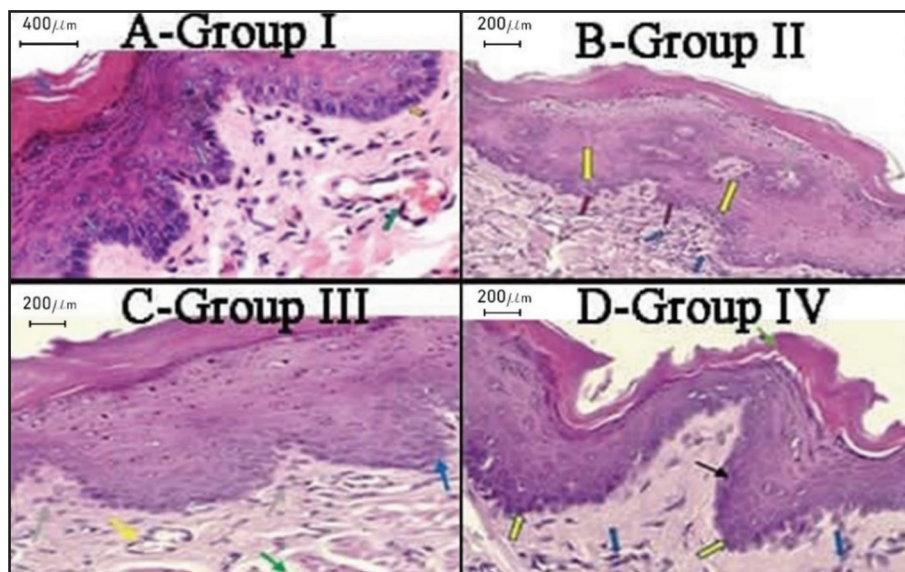


Figure (1) Photomicrograph of the buccal mucosa showing. A-Normal stratified squamous epithelium, B-Group II which received no treatment, C-Group III which treated by topical steroid, D- Group IV which treated by topical Aloe vera gel.

DISCUSSION

Lichenoid reactions (LR) have been linked to a variety of medicines, although the most prevalent are NSAIDs and ACEIs. Captopril is an ACEI that has many adverse effects, one of which being drug-induced lichenoid reactions. (2) Drug-induced reactions was reported to occur with various dosages of captopril, 450mg captopril selected to induce the reaction as the reaction appear pronounced with this dose according to the result of pilot study which carried out using different doses of the drug.

Rats were chosen for this study for a variety of reasons. First, they are a mammal with physiological body processes that are quite comparable to those of humans. They were also simple to obtain, house, breed, handle, control, and test (11).

The time interval between the initiation of the drug and development of the reaction ranged from weeks to months in different studies and even years. By the end of the sixth week pronounced white and erythematous changes developed in the mainly in the buccal mucosa and minority in the palate, the buccal mucosa was chosen because it was the primary site of lesion development (2).

Aloe vera are considered one of the most herbals used to treat different diseases due to their anti-inflammatory and antioxidant effects (6,7,12).

Examination of 2nd group (control negative group) showed; intense inflammatory and destructive changes affecting the connective tissue and the epithelium respectively.

The basic mechanism to develop this reaction is due to the drug and or its metabolites which bind to the surface protein of keratinocytes and act as a hapten, activating cytotoxic T-cells and various types of antigen-presenting cells, which secrete a number of cytokines that cause local tissue damage and attract other inflammatory cells to the reaction site (1,13).

On the other hand, there was a marked decrease in inflammatory and destructive changes upon application of topical steroid. This could be attributed to steroids' anti-inflammatory, antiproliferative, and anti-suppressive properties, which reduced the severity of inflammatory and hyperplastic changes. Inhibition of phospholipase A2 and cyclooxygenase pass ways, which are responsible for the production of numerous inflammatory mediators such as tumor necrosis factor alpha, IL6 and various interleukins, resulted in anti-inflammatory effects (14).

The steroid group's histological sections also revealed dilated blood vessels engorged by RBCs, as well as some vacuolated areas in the C.T. This could be due to topical steroids suppressing fibroblastic

cell proliferation and inhibiting the synthesis of collagen and mucopolysaccharides ground substance in the C.T, resulting in a loss of connective tissue support for dermal vasculature, resulting in telangiectasia and erythema, Steroids also stimulate human microvascular endothelial cells⁽¹⁵⁾.

Upon application of Aloe vera on the diseased tissues the intensity of inflammatory, hyperplastic and dysplastic changes appeared to be mild.

This could be attributed to Aloe vera richen components of vitamins, minerals and enzymes which possess anti-inflammatory and anticarcinogenic effect on tissues. Aloe vera appears to inhibits COX pathway and prostaglandin E2 production, reduce production of cytokines, reducing edema, hemorrhage, and inflammatory cell migration, inhibit lipid peroxidation and hence inhibit cell damage, Aloe vera contains antioxidant substances that get rid of the toxins and carcinogenic components also, Aloe vera reduce cell viability of cancer cell lines through apoptosis induction and reduce cell proliferation and increasing cell differentiation^(6,12).

Also, Aloe vera promoting wound healing by increasing keratinocyte migration, proliferation and differentiation by increasing stability of lysosomal membrane so Aloe vera seems to minimize the loss of membrane integrity, promote DNA synthesis and reduce its damage and increased epidermal growth factor improving epidermal thickness⁽⁶⁾. Also, Aloe vera gel improved wound healing by increasing blood supply⁽¹²⁾.

Different studies report different findings (complete remission, good response, poor response, no response) after usage of the same treatment (Aloe vera), according to Pol et al (2016), this difference can be attributed to the heterogeneous nature of aloe vera and the use of different formulations (gel, juice) with different concentrations also, could be attributed to different frequencies (once, twice, thrice) and duration of application of Aloe vera^(5,9).

CONCLUSION

Aloe vera herb provided accepted alternative treatment strategy in restoring the normal integrity of the damaged altered tissues, and suppressing the inflammatory and dysplastic process of lichenoid reaction in comparison to standard steroid therapy which possess many side effects. Future recommendation: further studies involving longer periods of treatment are needed with removal of the causative agent.

Conflict of Interest

No conflict of interest

Funding

No funding was received

REFERENCES

1. Agha-Hosseini F, Samami M, Tavakol F, Ghasemzadeh Hoseini E. Oral Lichen Planus or Oral Lichenoid Reaction? A Literature Review. *J Islam Dent Assoc Iran*. 2019; 31:40-57.
2. Müller S. Oral lichenoid lesions: distinguishing the benign from the deadly. *Mod Pathol*. 2017; 30:54-67.
3. Paswach W, Patamaporn N, Kobkan T. Challenge Management of Oral Lichenoid Drug Reaction. *Adv Dent & Oral Health*. 2017; 5: 555656.
4. Kia SJ, Basirat M, Mortezaie T, Moosavi MS. Comparison of oral Nano-Curcumin with oral prednisolone on oral lichen planus: a randomized double-blinded clinical trial. *BMC Complementary Medicine and Therapies*. 2020; 20:328.
5. Pol JS, Patil BA, Sodhi A, Tadiparthi J. Evaluation of therapeutic effect of Aloe Vera juice and gel in the management of symptomatic oral lichen planus. *Int J Med and Dent Sci*. 2016; 5:1138-44.
6. Sánchez M, González-Burgos E, Iglesias I, Gómez-Serranillos MP. Pharmacological Update Properties of Aloe Vera and its Major Active Constituents. *Molecules J*. 2020; 13:25-1324
7. Ceravolo I, Mannino F, Irrera N, Squadrito F, Altavilla D, Ceravolo G et al. Health Potential of Aloe vera against Oxidative Stress Induced Corneal Damage: An "In Vitro" Study. *Antioxidants (Basel)*. 2021; 10:318.

8. Kalaskar AR, Bhowate RR, Kalaskar RR, Walde SR, Ramteke RD, Banode PP. Efficacy of herbal interventions in oral lichen planus: A systematic review. *Contemp Clin Dent.* 2020; 11:311-9.
9. Ahmed SS, Gadalla LM, Elmeadawy SH, Badria F. The efficacy of Aloe vera gel in treatment of oral lichen planus. *Int Dent Med J Adv Res* 2018; 4:1-6.
10. Yousry El-Bolkiny, Mohamed M. Nasef, Maha A. El-Sayed and Ibrahim K. El-Shourbagy. Inptake of ω 3 fatty acids reduces obesity and prevents anemia in mice. *IJCBR* .2021; 5: 95-107.
11. Bakr NM, Farid MH, Adawy HA. The Anticipated Effect of Both Zamzam Water and Epidermal Growth Factor (EGF) Separately on Tongue Tissues and Lingual Salivary Glands of Diabetic Albino Rats. *ADJ.*2019;6:329-335.
12. Neena IE, Ganesh E, Poornima P, Korishettar R. An ancient herb Aloe vera in dentistry: A review. *J Oral Res Rev.* 2015; 7:25-30.
13. Fortuna G, Aria M, Schiavo JH. Drug-induced oral lichenoid reactions: a real clinical entity? A systematic review. *Eur J Clin Pharmacol.* 2017; 73:1523-1537.
14. Ferrara G, Petrillo MG, Giani T, Marrani E, Filippeschi C, Oranges T, Simonini G, Cimaz R. Clinical Use and Molecular Action of Corticosteroids in the Pediatric Age. *Int J Mol Sci.* 2019; 20:444.
15. Coondoo A, Phiske M, Verma S, Lahiri K. Side-effects of topical steroids: A long overdue revisit. *Indian Dermatol Online J.* 2014; 5:416-25.