



Patient Satisfaction with Complete Denture Constructed Using Modified Windows Impression Technique with Custom Dual Tray for hypermobile Maxillary Residual Ridge

Aisha Z. Mostafa^{1*}, Noha H. El-Shaheed²

Codex : 09/22.10

azhardentj@azhar.edu.eg

http://adjg.journals.ekb.eg

DOI: 10.21608/adjg.2022.138322.1513

Restorative Dentistry
(Removable Prosthodontics, Fixed
Prosthodontics, Endodontics, Dental
Biomaterials, Operative Dentistry)

ABSTRACT

Purpose: Patient satisfaction for the complete denture constructed by using two impression techniques was assessed. A custom dual tray was used as a modification of window impression technique versus the conventional impression technique. **Subjects and methods:** Ten completely edentulous patients with anterior hypermobile tissues were included in this study, using a non-randomized cross-over study design. The aim of the study was to evaluate patient satisfaction with two maxillary complete dentures constructed for each patient, one using the windows impression approach with a custom-made dual tray and the other using the conventional impression technique with a custom single tray. The time interval for using each set was about 3 and 6 months. Patients' satisfactions were assessed at every time interval. Data was analyzed to determine the patient satisfaction with the different complete dentures using the SPSS.ver.23 and Wilcoxon signed rank test at ($\alpha = 0.05$). **Results:** Patients' satisfaction survey showed that the 2 different maxillary dentures were not statistically equivalent, where the maxillary complete denture constructed with windows technique using the dual custom tray demonstrated greater patient satisfaction. **Conclusion:** Within this study, complete denture constructed with windows technique using the dual custom tray improves the denture function and subsequently the patient satisfaction.

INTRODUCTION

Complete dentures can be complicated by flabby or hypermobile soft tissues in the denture-supporting structure, which can lead to pain when wearing them and denture displacement. The main problem of this case is movement or distortion of flabby tissues caused by the force applied during impression generation is the primary concern. It's possible that dentures manufactured from this impression will not fit properly ^(1,2).

KEYWORDS

Patient Satisfaction, OHIP-14,
Dual Custom Tray, Window
Technique.

1. Associate professor of prosthodontic, Faculty of Dentistry, Mansoura University, Egypt.

2. Lecturer of prosthodontic, Faculty of Dentistry, Mansoura University, Egypt.

* Corresponding author email: dr.aishazakaria25@yahoo.com

A prosthetic or surgical approach can be used to correct flabby ridges. Ridge augmentation, excision, and sclerosing solution injection are some of the surgical options for flabby ridges⁽²⁾. Prosthodontically, flabby tissue can be controlled by monitoring hypermobile soft tissues and preserving even occlusal position. There's an argument about whether compressive or static recording is better for hypermobile tissue impressions. Prosthodontists have endorsed the idea of recording tissues using static methods. A variety of techniques have been used to record tissues in a static state. Controlling the force required to make an imprint by adjusting numerous elements as the design of the tray, nature of impression material, and rapidity of impression taking can result in static impressions with minimum tissue displacement. To vary the tray design, you can use spacers or puncturing trays, scratching impression trays, using open trays using the window technique, and using separable trays⁽³⁻⁸⁾.

Tissue displacement is reduced using trays through more spacers and vents, or trays that exposed at the hypermobile ridge area. Exposed window trays yielded the smallest amount of tissue shift. The extent of force applied through the impression record is directly related to the viscosity of the impression medium⁽³⁾. While sturdy custom-made trays are essential for perfect impressions,⁽⁹⁾ using an exposed window tray with vinyl polysiloxane (VPS) without anterior tray sustenance may disturb the accuracy of impression. As a result, additional keyed tray can be done to be used during recording the hypermobile tissue⁽¹⁰⁾. The trays helps with dimensional accuracy by ensuring that the impression material is of consistent thickness⁽¹¹⁾. Polysiloxane impressions made with customized trays were more precise and consistent than impressions made with the stock trays⁽¹²⁾. The use of a dual custom tray and windows approach principles allowed for accurate recording of the flabby tissue, resulting in the case's successful prosthodontic care⁽¹⁰⁾.

The Oral Health Impact Profile (OHIP) is a test that is used to identify oral cavity disorders. The OHIP questionnaire is a simple and reliable tool for

determining the quality of life related to oral health. The OHIP-14sp proved to be a useful quality of life indicator, as it clearly distinguished between the individuals in the study (dentate vs. edentate patients restored with complete dentures or implant overdentures)⁽¹³⁾. OHIP assesses the frequency of oral difficulties and provides a profile of how these issues may affect a patient's life. The OHIP-14 is a precise, valid, and trustworthy tool for evaluating oral health-associated quality of life.

The satisfaction of patients with two maxillary full dentures in the presence of a hypermobile maxillary ridge was assessed in this study. Acrylic resin custom dual tray, two-step impression procedure, modified windows technique with Vinyl polysiloxane (VPS) elastomeric impression material was used to make one maxillary denture. The other maxillary denture was made with a single custom tray, one-step impression technique, and mucostatic impression substance made from zinc oxide eugenol.

The null hypothesis for this study is that there are no differences in patient satisfaction for maxillary complete dentures constructed using a dual custom tray or a traditional single custom tray for the maxillary anterior hypermobile tissues.

SUBJECTS AND METHODS

This prospective clinical investigation compared patient satisfaction with two maxillary full dentures created with two distinct impression procedures, using a non-randomized cross-over study design.

This study followed the clinical research guidelines. The ethical committee of the University of Mansoura, Faculty of Dentistry, approved this study with code number of (A37080622). After being briefed about the study's full information, the patients signed an informed permission form to participate in it.

This study included ten fully edentulous patients (5 male and 5 female) who offered to the Prosthodontic clinic of dentistry with maxillary anterior hypermobile soft tissues and were seeking complete denture manufacture. The sample size of

10 participants was calculated using PASS 2021 Software for Wilcoxon-test, has an alpha (α) of 0.05 and power of 0.80. Also, $n=10$ were used by Rues et al, 2021,⁽¹⁴⁾ to compare impression accuracy using a plastic or metal tray.

Every patient's treatment approach included constructing two maxillary complete dentures against a mandibular complete denture. The first maxillary complete denture was made with a special dual tray and a modified window impression technique, with the final impression made with vinyl polysiloxane (VPS) material. The second maxillary complete denture was made with a single customized tray and zinc oxide eugenol impression material utilizing a mucostatic impression technique.

The following procedures were performed to every patient:

Primary impressions were created with alginate material (Cavex CA37, Germany) on stock plastic trays for edentulous cases in patient-specific sizes.

Maxillary and mandibular primary cast (Dental stone, Type IV, Kulzer, UK) were obtained from impression pouring. The maxillary hyper mobile ridge area on the cast was recognized. For standardization, two self-cure acrylic resin custom trays were created on the same maxillary cast:

One single tray was done with self-cure acrylic resin and wax spacer for mucostatic impression technique. Extra- spacer was used at the hypermobile tissue area.

The other tray was a dual custom tray for impression using the modified windows impression

technique. It was constructed according to the following procedure:

- A wax sheet was placed to the cast to make a custom tray with spacer and stoppers for the single custom tray (four stopper were created, two on each side).
- A one-layer wax spacer was applied on the maxillary cast for the double customized tray, except in the hypermobile ridge area, where a twin sheet of wax (Cavex Set Up Regular, 110° Modeling wax, Germany) was used. Two on each side, a total of four stoppers were made. A straight handgrip was created in the horizontal palatine area to include the maxillary cast excluding the area of the hypermobile area. The hypermobile area and horizontal palatine area of the first tray were covered by the additional acrylic resin tray. It was modified to make a keyway with the original tray's handgrip (Key).
- Perforations were created in both the single and dual custom trays to allow the impression material to be mechanically retained while also allowing excess impression material to escape.

The flanges of the custom imprint trays were altered to be 2 mm smaller than the depth of the vestibule after they were assessed in the patient's mouth.

For the single tray mucostatic impression technique, a low fusing modelling plastic impression compound (Green Tracing sticks, Kerr, Germany) was used for border molding, followed by Zinc Oxide Eugenol Impression Paste (DPI, impression material, India) (Fig. 1).

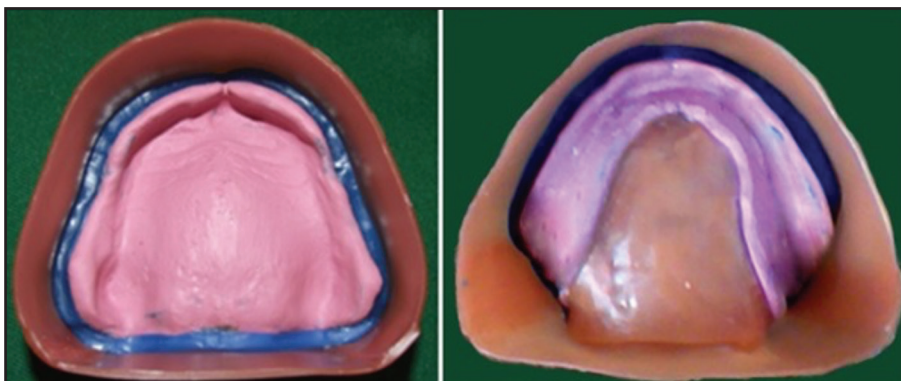


Figure (1) Maxillary and mandibular mucostatic impression using zinc oxide eugenol paste.

For the dual tray modified windows approach, border molding was done utilizing silicon impression material (putty material). The impression of the first half of the dual custom tray were then performed using silicon impression material (light body VPS) (Sildent Putty, light body, Hydrophilic Vinyl Polysiloxane impression material, Korea). The impressions were thoroughly examined for defects. Before the second part impression, any extra impression material in the zone of the hypermobile area was warily detached using a cutting edge of blade. Then the impression was repositioned in the oral cavity, and the second custom tray was used to record the hypermobile zone using injectable light body VPS elastomeric impression material (Sildent Putty, light body, Hydrophilic Vinyl Polysiloxane impression material, Korea) (Fig. 2).

Definitive impressions were boxed to be poured for obtaining definitive casts. Record blocks were constructed. The centric maxilla-mandibular relationship was recorded using one maxillary record and one mandibular record. Only the fitting surface of the two maxillary dentures differed, but the polished and occlusal surfaces were identical.

The patients received a maxillary complete denture made with dual custom trays or a maxillary complete denture made using single custom tray in a crossover design. Two groups of patients

(5 patients each) were created using randomly generated numbers generated by a computer software (Excel sheet). The first five patients had a maxillary full denture made using the single tray and mucostatic impression method. The remaining five patients had a maxillary complete denture made utilizing a modified window approach and dual customized trays.

The patients were given instructions on how to care for and utilize their complete dentures at home. Following that, the patients were given three and six months to use the dentures before having follow-ups. Following this period, the first group received the complete denture constructed using a modified windows maxillary denture as well as a dual custom-made tray. The maxillary complete denture that was received by the second group was done utilizing a single tray and mucostatic impression technique. Patients wore the dentures for the same amount of time and then had follow-up appointments.

Measurements of patient satisfaction and oral health impact profile (OHIP-14):

Patients received a patient satisfaction questionnaire and OHIP-14 after receiving complete dentures and wearing them. There were two parts to this questionnaire survey. The first section includes a visual evaluation scale, patient satisfaction including that about denture retention, and therapy

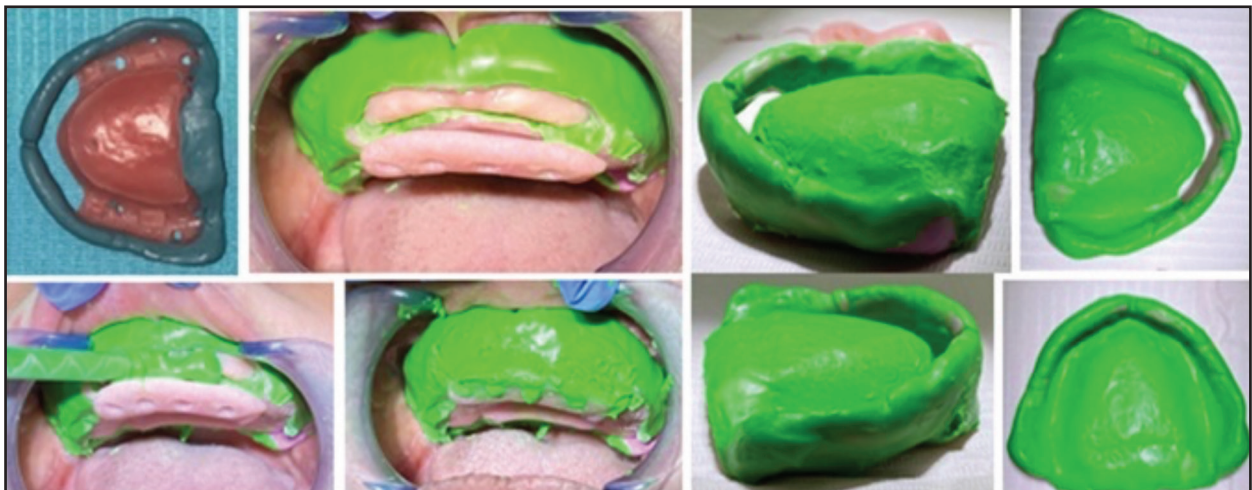


Figure (2) Maxillary impression using dual custom trays and modified windows technique

recommendations. The replies were evaluated on a Likert scale of 1 to 5, with a total score ranging from 7 to 35 points (1, highly unsatisfied; 2, practically none satisfied; 3, indifferent; 4, satisfied; and 5, extremely satisfied). The patients' dental and oral health-related quality of life was assessed in the second portion. This questionnaire includes 14 questions divided into seven categories: function restrictions (difficulty with sound pronunciation, bad taste sensations), physical pain (painful aching, uncomfortable eating), psychological discomfort (self-consciousness, feeling tense), physical problems (unsatisfactory diet, interrupting meals), psychological restrictions (difficulty relaxing, embarrassing), social disability (irritability with people, difficulty in jobs), and handicap (life in general less satisfying). Patients were asked to consider speech

function, taste, chewing discomfort, and dentures, among other things. The responses were scored on a Likert scale of 1 to 5, with a total score ranging from 14 to 70 points (1, never; 2, virtually none; 3, rare; 4, regular; and 5, extremely frequent).

RESULT

Statistical analysis:

For comparison of two maxillary complete denture, the non-parametric data was tabulated and descriptive analysis was done using median (minimum – maximum). Wilcoxon signed rank test was done to compare the statistical significant difference. SPSS ver.23. Software was used for data analysis. $P < 0.05$ was considered significant.

Table (1) Shows the median (minimum-maximum) and satisfaction percent for the visual evaluation scale, as well as patient satisfaction and recommendations for both single (mucostatic impression technique) and dual custom tray impressions employing windows principles.

Domain	maxillary denture mu- costatic impression	maxillary denture win- dow impression	Wilcoxon signed rank test	
	Median (min-max) - Satisfaction %	Median (min-max) - Satisfaction %	Z value	P value
Satisfaction with the denture	4.5 (3-5) – 88%	4 (2-5) - 88%	2.000 ^b	.046*
Comfortable with the denture	5 (3-5) – 90%	4 (2-5) - 78%	2.449 ^b	.014*
Feel the taste of food with the denture	4 (4-5) – 84%	4 (4-5) - 82%	1.000 ^b	.317
Feel any bad smell with the denture	4 (3-5) -78%	4 (3-5) - 76%	.577 ^c	.564
Retention and stability during function	5 (3-5) - 96%	5 (2-5) - 88%	2.000 ^b	.046*
Difficulty of speaking	4.5 (3-5) - 88%	4 (3-5) – 84%	1.414 ^b	.157
Recommendation of this treatment to your family and friends	4.5 (3-5) - 88%	4 (2-5) – 78%	2.236 ^b	.025*

a. Wilcoxon Signed Ranks Test

b. Based on negative ranks.

* statistically significant when ($P < 0.05$)

Table (2) Show the median (minimum- maximum) and satisfaction percent for oral health impact profile (OHIP-14) of both maxillary dentures with single (mucostatic impression technique) and double custom tray impression using windows principles.

Domain	Maxillary denture mucostatic impression		Maxillary denture window impression		Wilcoxon signed rank test	
	Median (min-max)-	Non Satisfaction%	Median (min-max)-	Non Satisfaction%	Z	P value
Function restrictions:						
Trouble sound pronunciation,	1.5 (1-2)	15%	2.0 (1-3)	19%	-1.633-b	.102
Bad taste sensation	2.0 (1-2)	16%	2.0 (1-3)	17%	-.577-b	.564
Physical pain:						
Painful aching,	2.0 (1-3)	17%	2.0 (1-3)	22%	-2.236-b	.025*
Uncomfortable eating	1.0 (1-3)	14%	2.0 (1-3)	20%	-2.121-b	.034*
Psychological discomfort						
Self-consciousness	2.0 (1-2)	17%	2.0 (1-3)	20%	-1.134-b	.257
Feeling tense	2.0 (1-3)	17%	2.0 (1-3)	20%	-1.732-b	.083
Physical problems Unsatisfactory diet	1.0 (1-2)	13%	1.0 (1-3)	15%	-1.414-b	.157
Interrupting meals	1.0 (1-3)	15%	2.0 (1-3)	17%	-.707-b	.480
Psychological restrictions Difficult to relax	1.0 (1-2)	14%	2.0 (1-3)	18%	-1.414-b	.157
Embarrassing	1.5 (1-3)	16%	2.0 (1-3)	17%	-.378-b	.705
Social disability						
irritability with people	1.0 (1-3)	13%	1.5 (1-3)	17%	-1.300-b	.194
difficulty in jobs	1.0 (1-3)	15%	2.0 (1-3)	17%	-1.134-b	.257
Handicap						
Life generally less satisfactory	1.0 (1-3)	14%	1.5 (1-3)	16%	-.276-b	.783
Inability to function	1.0 (1-3)	15%	1.5 (1-3)	17%	-1.134-b	.257

a. Wilcoxon Signed Ranks Test

b. Based on negative ranks.

* statistically significant when ($P < 0.05$)

In contrast to the maxillary complete dentures that were constructed using mucostatic impression technique and single tray, the patients were satisfied with the denture made utilizing modified windows technique and dual custom tray. This maxillary single denture was discovered to be more comfortable. The dentures constructed using the window special impression technique and custom dual tray were more steady and retentive, according to clinical assessment.

DISCUSSION

The fundamental goal of removable denture rehabilitation is to reestablish function and appearance while also keeping the patient healthy. It might be difficult and stressful to treat a patient with a hypermobile area. The hypermobile ridge can be treated either through surgical, prosthetic methods, or both⁽¹⁻³⁾. When surgery is not a possibility, impression procedures and the preservation of

established occlusal relationships are the mainstays of prosthodontic care ⁽⁴⁻⁹⁾.

In successful prosthodontic treatment of any type of prosthesis, an accurate impression is essential. Impression techniques using an intraoral scanner are frequently applied in the partially edentulous mouth; in the completely edentulous mouth, different faults may develop owing to an absence of structural landmarks, and portable soft tissues like the vestibule and soft palate were especially unsteady in some situations. Furthermore, capturing an impression of the entire edentulous arches is difficult due to the scanner's poor design and size ⁽¹⁵⁾.

For complete dentures and removable partial dentures, there is no strong evidence that one procedure or material offers a significant benefit over another. There is a limitation of evidence on the relative benefits of various denture production procedures and final-impression materials ⁽¹⁶⁾.

The one-step impression technique was used in this study, with additional relief space at the flabby tissue area using zinc oxide eugenol impression material. The other tray was a dual tray that used a two-step impression technique based on the window technique (modified) using PVS.

The one-step impression technique with an extra relief space at the flabby tissue area can reduce lateral flabby tissue displacement, whereas the two-step impression technique with an open window can minimize overall flabby tissue displacement. The three impression materials used for hypermobile tissue impression (light-body polysulfide, light-body vinylpolysiloxane, and zinc oxide eugenol paste) had no significant differences in flabby tissue displacement. Soft tissue displacement does not differ between the evenly spaced tray and the tray with extra space used for hypermobile tissue impression. However, there is a distinction between these two tray designs and the open window tray. The open tray design provides an impression without displacing any tissue ⁽⁷⁾.

Tissue displacement during impression formation was influenced by tray design, with impressions with more spacers and vents, or trays that not cover the hypermobile soft tissue ensuing in reduced tissue movement ⁽⁷⁾. The least magnitude of displacement is produced by open window impressions. The extent of hypermobile tissue movement was affected by the impression technique; the two-step impression technique induced less tissue displacement than the one-step impression approach ⁽⁸⁾.

Depending on the facts given above, the window technique is favored. The impression may be deformed during casting if you utilize an open window trays with VPS and no tray exist in anterior area of the hypermobile tissue. As a result, having a second tray that is related to the first tray avoids the deformation throughout the casting process ⁽¹⁰⁾. The presence of a tray also assures that the impression material is of uniform thickness, resulting in dimensional correctness. The constant impression material thickness ensures the accurateness of the impression ⁽¹¹⁾.

Two maxillary dentures were produced in this present clinical investigation, one utilizing the mucostatic impression technique with a single tray and the other using the modified windows technique with a dual custom tray. After that, both built maxillary dentures were evaluated for patient satisfaction and OHIP-14. The patients were statistically more satisfied with the maxillary denture made using the dual impression procedure, according to the findings. They felt more at ease with it, and their retention and stability improved. This treatment was also recommended for complete dentures in the same situation.

In terms of the OHIP-14, patients who have a maxillary denture made using the windows principles and a double custom tray have fewer problems than those who have a maxillary denture made using the mucostatic impression technique and a single tray. Physical pain was found to have statistically significant differences. Uncomfortable eating and painful ache.

Using the stated modified window technique, the customized two-step dual tray technique, the hypermobile tissue was exactly recorded without tissue shift. The hypermobile area is recorded in the undisturbed posture using simple and stable designed twin trays. The equal thickness of impression material in the hypermobile tissue area increase the correctness of the impression ⁽¹⁰⁾.

Through a 2 mm space between them, the customized dual tray employed in this study may be easily constructed and correctly assembled to each other. The dual tray, modified window technique provides for mucostatic recordings of hypermobile tissue while maintaining the thickness of the imprint material and dimensional precision. It may also help to keep the impression material from deforming in the open tray zone ⁽¹⁰⁾.

The denture foundation was exact and allowed for superior tissue adaptation because it was made this way. Without diminishing the hypermobile tissue's vascularity or interfering with its viscoelasticity, inactive denture base adaptations was performed, preserving tissue health, denture fitting, and, as a consequence, patient preferences, satisfactory retaining, and no pain with the denture.

When comparing the border molding for complete dentures using two distinct border molding techniques: "traditional green stick" and "polyvinyl siloxane material." The study discovered that the stability, retention, and comfort of these two procedures were identical ⁽¹⁶⁾.

On the other hands, Putty silicone material allows faster, easier and effective border molding procedure rather than low fusing compound ⁽¹⁷⁾.

Prostodontics uses polyvinyl siloxane impression materials in a variety of ways. Their prevalence in clinical practice is due to their favorable handling features, strong patient acceptance, and great physical properties ⁽¹⁸⁾. Several researchers have suggested replacing older and more traditional materials with newer elastomeric polymers such as

polyvinylsiloxane and polyether for complete denture final impressions ⁽¹⁹⁻²¹⁾.

There were distinct trends in the increased usage of polyvinylsiloxane and polyether for border molding techniques and edentulous arches impressions. They're ideal for taking impressions for complete dentures ⁽²⁰⁾. The technique used to make the impression may be more important than the material used itself. Impressions created on custom trays were more accurate than impressions made on stock trays. The material may be applied evenly and quickly to the tray borders with just one tray insertion to provide accurate record. Casts made with polyether and hydrophilic addition silicone had more soft tissue features than those made with low-viscosity polysulfide or ZOE.

Although impression materials vary in many characteristics and impression techniques vary, there is no evidence to suggest that the clinical long-term result of dentures made with different materials and methods would differ significantly. In a review of the evidence base for complete dentures, these and other issues of variance in methods and techniques are reviewed. For a positive outcome, psychosocial elements, particularly a positive relationship between the dentist and the patient, are more significant than prosthodontic considerations ⁽²²⁾.

In a completely edentulous maxillary arch, the accuracy of scanning acquired from polyvinylsiloxane, polysulfide, and polyether impressions is equivalent ⁽²³⁾. The displacement of flabby tissue did not differ significantly amongst the three types of impression materials used: light-body polysulfide, light-body vinylpolysiloxane, and zinc oxide eugenol paste. Except for the anterior and posterior areas of the flabby tissues at the 8-mm sagittal sections bilaterally, there were no significant changes in tissue displacement between the three impressions materials when the tray design was kept constant ⁽⁷⁾. The pressures reported when impressions were made with ZOE paste and light-body type of VPS were similar in maxillary edentulous patients

⁽²²⁾. According to these previous finding, this study compared the patient satisfaction in two different techniques using two comparable materials.

The impression techniques for prosthetic disciplines with a flabby ridge differ from the traditional method in that they use techniques that involve two steps: the impression of the flabby ridge areas, which must be done without pressure in its resting position, and the impression of the prosthetic fields with a flabby ridge. This impression procedure produced dentures that provided the patient with the desired functional comfort. The use of fluid impression material for the flabby ridge in a resting posture, as well as a fenestrated bespoke tray, resulted in a high level of adaptability, maintenance, and stability for the final dentures⁽²⁴⁾.

This research found that there was a statistical significant differences between both complete dentures in patient satisfaction related to the denture retention and stability. Other research ⁽²⁵⁾, found that Patient satisfaction with complete dentures was unaffected by age, gender, or degree of resorption. Patient satisfaction with complete dentures was linked to their degree of comfort and denture aesthetics, and patient comfort was linked to denture stability.

The result of this research come in agreement with one research⁽²⁶⁾, who found that to avoid compression and rebounding of the mobile tissue, a modified imprint technique was utilized to record the flabby edentulous ridge in an un-displaced form and this provide a satisfactory result.

Dentures made from traditional muco-compressive impression techniques may displace hypermobile maxillary anterior ridge tissue when loaded and become loose when unloaded ⁽³⁾. According to this statement, the muco-compressive impression technique was not included in this study. More research can be conducted to compare muco-compressive versus mucostatic impression techniques.

CONCLUSION

Within the limitation of this study, in the event of hypermobile tissue, the patient chose the maxillary single denture constructed with a custom dual tray over the one made with a single tray for mucostatic recording of these tissues. They were more satisfied with the maxillary denture construction employing dual custom tray in terms of comfort and oral health.

RECOMMENDATION

In cases of anterior hypermobile or flabby ridge area for completely edentulous individuals, an acrylic dual custom tray is preferable for recording maxillary impressions using the modified window impression technique.

Funding

None

Availability of Data And Materials

The data are available with the authors upon reasonable request.

Conflict of Interest

The authors declare that there was no conflict interests

REFERENCES

1. Labban N. Management of the flabby ridge using a modified window technique and polyvinylsiloxane impression material. *Saudi Dent J.* 2018;30:89-93.
2. Zarb GA, Hobkirk JA, Eckert SE, Jacob RF: *Prosthodontic Treatment for Edentulous Patients. Complete dentures and implant supported prosthesis*, 14th edition. St. Louis, Mosby ,2017 p:48, 80
3. Antonelli J, Guerrero M, Georgescu M, Ortiz J. Quantifying Flabby Ridge Tissue Displacement During Impression-Making for Patients With Combination Syndrome. *Compend Contin Educ Dent.* 2019;40:e1-e7.
4. Srivastava S, Mishra S, Chopra D. Modified Tray with Mesh Design for the Management of Flabby Ridge: A Case Report. *Front Dent.* 2019;16:149-52.

5. Srivastava S, Mishra S, Chopra D. Modified Tray with Mesh Design for the Management of Flabby Ridge: A Case Report. *Front Dent.* 2019;16:149-152.
6. Sikri A, Sikri J. Prosthetic management of flabby ridge using customized prefabricated metal mesh custom tray impression technique: A case report. *IP Annals of Prosthodontics and Restorative Dentistry.* 2022;8: 50-60
7. Shin JO, Ko KH, Huh YH, et al. Displacement of simulated flabby tissue by different tray designs and impression materials. *J Prosthodont* 2019;28:444–51
8. Showkat R, Sharma A, Kumar S, Kaura S. Management of flabby ridge using hobkirk's technique: a case report. *European Journal of Dental and Oral Health* 2020;1:1-4
9. Parameshwari G, Chittaranjan B, Sudhir N, Anulekha-Avinash CK, Taruna M, Ramureddy M. Evaluation of accuracy of various impression techniques and impression materials in recording multiple implants placed unilaterally in a partially edentulous mandible- An in vitro study. *J Clin Exp Dent.* 2018;10:e388-e95.
10. Mostafa AZH, Alanazi SM, Almarshedy SM. Custom double tray for a special impression technique for flabby maxillary residual ridge: Case report. *Clin Case Rep.* 2022;10:e05593.
11. Mudliar VL, Li KC, van Vuuren LJ, Waddell JN. The influence of undercut depths on the accuracy of casts poured from irreversible hydrocolloid impression materials. *Heliyon.* 2020;6:e03143.
12. Stevens CD. Impression-Making in 2020: How Long Before Analog Methods Are Obsolete?. *Compend Contin Educ Dent.* 2020;41:178-9.
13. García-Minguillán G, Preciado A, Romeo M, Río JD, Lynch CD, Castillo-Oyagüe R. Differences in self-perceived OHRQoL between fully dentate subjects and edentulous patients depending on their prosthesis type, socio-demographic profile, and clinical features. *J Dent.* 2021;114:103756.
14. Rues S, Stober T, Bargum T, Rammelsberg P, Zenthöfer A. Disposable plastic trays and their effect on polyether and vinyl polysiloxane impression accuracy-an in vitro study. *Clin Oral Investig.* 2021;25(3):1475-84.
15. Jung S, Park C, Yang HS, et al. Comparison of different impression techniques for edentulous jaws using three-dimensional analysis. *J Adv Prosthodont.* 2019;11:179-86.
16. Jayaraman S, Singh BP, Ramanathan B, Pazhaniappan Pillai M, MacDonald L, Kirubakaran R. Final-impression techniques and materials for making complete and removable partial dentures. *Cochrane Database Syst Rev.* 2018;4:CD012256.
17. Pachar RB, Singla Y, Kumar P. Evaluation and Comparison of the Effect of Different Border Molding Materials on Complete Denture Retention: An in vivo Study. *J Contemp Dent Pract.* 2018;19:982-7.
18. Rady AA and El Naby NA. The influence of border molding on retention and time of complete denture impression. *EDJ* 2017, 63, 2863: 9.
19. Garg S, Kumar S, Jain S, Aggarwal R, Choudhary S, Reddy NK. Comparison of Dimensional Accuracy of Stone Models Fabricated by Three Different Impression Techniques Using Two Brands of Polyvinyl Siloxane Impression Materials. *J Contemp Dent Pract.* 2019;20:928-34.
20. Kalberer N, Chebib N, Wachter W, Lee H, Müller F, Srinivasan M. In silico evaluation of the peripheral and inner seals in complete denture master impressions using a custom-developed 3D software. *Clin Oral Investig.* 2021;25:125-32.
21. Rameez M, Razi SS, Farhan F, Kumar B, Rashid H. Clinical implications of elastomeric impression materials used for complete denture construction. *Dent Med Res* 2018;6:19-23.
22. Dadarwal A, Paliwal J, Sharma V, Meena KK, Raigar RL, Gaziwala M. Microstrain Analysis of Selective Pressure Techniques for Mandibular Complete Denture Impression: An In Vivo Study. *Cureus.* 2022;14:e23673. Published 2022 Mar 31.
23. Ștefănescu CL, Zaharia A, Murineanu RM, Gabriela C, Sachelarie L, Grigorian M. Flabby Ridge, a Challenge for Making Complete Dentures. *Appl. Sci.* 2021, 11: 7386.
24. Zarone F, Ruggiero G, Di Mauro MI, Spagnuolo G, Ferrari M, Sorrentino R. Accuracy of Three Impression Materials on the Totally Edentulous Maxilla: In Vitro/In Silico Comparative Analysis. *Materials (Basel).* 2020;13:515.
25. Soboleva U, Rogovska I. Edentulous Patient Satisfaction with Conventional Complete Dentures. *Medicina (Kaunas).* 2022;58:344.
26. Rathee M, Jain P, Shetya AG and Wakhure P. Rehabilitation of an Edentulous Patient with Flabby Ridge Using Modified Window Technique - A Case Report. *J Dent & Oral Disord.* 2020; 6:1149:51.