

The Antioxidant Effects of Cerium Oxide Nanoparticles and Echinacea Purpurea against Lead-induced Immunosuppression in Male Albino Rats

Amal H. Mahmoud*, Manal M. Abbas, Hanan A. AbdElmonem

Biological Application Department, Nuclear Research Centre, Egyptian Atomic Energy Authority, Cairo, Egypt

*Corresponding author: Amal H. Mahmoud, Mobile: (+20) 01112408081, Mail: dr.amalhanafi.1@gmail.com

ABSTRACT

Background: Lead is an environmental pollutant has a negative effect on the immune system. Echinacea (*E. purpurea*) is an immunostimulant. Also, cerium oxide nanoparticles (CeONPs) are potential antioxidant elements.

Objective: The current study was intended to assess the antioxidant and immunostimulant influences of CeONPs and Echinacea against lead induced immune toxicity.

Methods: Forty nine male rats were allocated into 7 groups. Group1 served as the control group. Group2 rats were orally treated with lead acetate 60 mg/ kg b.wt/day. Group3 rats were intraperitoneally (i.p.) injected with CeONPs 0.5 mg/kg b.wt/day. Group4 rats were orally treated with E.P. 150 mg/ kg b.wt/day. Group5 rats were given lead as group2 in addition injected i.p with 0.5 mg/kg b.wt/day CeONPs. Group6 rats gained the above mentioned dose of lead plus 150 mg/kg b.wt E.P orally. Group7 rats were given Lead & Echinacea and CeONPs by doses as mentioned above, rats were treated for 2 weeks (5 days/week). **Results:** lead intake resulted in anemia with significant leukopenia and lymphopenia. Additionally, lead injected rats showed a significant increase in interleukin-6, and tumor necrosis factor- α (TNF- α). In contrast, sera-immunological parameters (interleukin-10, IgG, IgM) and testosterone levels were significantly reduced. Moreover, lead-induced spleen oxidative injury was detected by a significant increase in malondialdehyde level with notable reduction in reduced glutathione content and catalase activity. Treatment with Echinacea and CeONPs improved the hematological, immunological and histological alterations induced by lead.

Conclusion: Echinacea. and CeONPs have antioxidant, anti-inflammatory and immunostimulatory effects and could ameliorate the lead-induced immunotoxicity and oxidative stress.

Keywords: Lead, Immune system, Echinacea, Cerium oxide nanoparticles, oxidative stress, Spleen.

INTRODUCTION

Lead is a heavy metal and one of the most harmful environmental contaminants in the world. Several evidences reported that lead causes different toxic biochemical effects on the liver, kidneys, nervous system and the hematopoietic system [1]. Oxidative stress is the main pathway implicated in lead-caused toxicity [2]. The immune system which is the major contributor to inflammation has been demonstrated to be adversely affected by lead [3].

Globally, there is an increasing attention with medicinal plants that can be considered as immune-modulators. *Echinacea purpurea* L. is a medicinal plant relates to the family *Asteraceae* recognized as coneflower [4]. The US food and Drug Administration (FDA) identifies it as a food, whereas commission E (Task Force E of the Federal Bureau of Health of Germany) authorized it as a medication. *E. purpurea* contains active components involving polysaccharides, polycetylenes, flavonoids, alkamides, caffeic acid derivatives and cichoric acid, so it has antioxidant, anti-inflammatory and immunomodulatory effects [5]. *E. purpurea* also, has an interferon (INF) like effect stimulating macrophages, increasing the production of interleukin-1 and INF [6]. Among *E. purpurea* components, echinacin, a particular glucose chain that attaches to the T-cells and macrophages surface to activate them [7].

Nanomedicine has appeared as a desirable treatment strategy to combat diseases such as inflammation, cancer, diabetes and fibrosis [8]. Cerium (Ce) is a rare chemical element present in two valence

states; Ce⁺⁴ (oxidized form) and Ce⁺³ (reduced form). It can alternate between the two in redox reactions with oxygen vacancies for acquiring or emitting electrons during changing from Ce⁺³ to Ce⁺⁴ states [9]. Cerium activity resembles function of enzymes within the body, superoxide dismutase [9] and catalase [10] in order to counteract different reactive oxygen species (ROS) molecules including superoxide, nitric oxide and peroxynitrite [11]. Many researches have reported the anti-inflammatory, antibacterial and antioxidant effects of CeONPs making them one of nanoparticles with therapeutic potential [12].

Therefore, providing an approach for inhibiting lead-immuno- toxicity is required. The study was conducted to assess the alleviating and modulatory impacts of CeONPs and *E. purpurea* and their combination on the hematological parameters, cytokines, immunoglobulins, antioxidants, and histological structure of the spleen of the lead injected rats.

MATERIALS AND METHODS

Chemicals

Cerium (IV) oxide (CAS Number: 1306-38-3), a nanopowder <25nm particle size obtained from Sigma-Aldrich Co., St.Louis USA. Cerium particles were suspended in distilled water at dose (0.5mg/kg b.wt) and sonicated. Lead acetate was purchased from NATCO, Laboratory chemical reagents. Lead dissolved in distilled water at a dose of 50mg/kg b.wt. Echinacea *Purpurea* was purchased from Puritan, as Pride's INC, (HoLbrook, NY 11741. USA.), as capsules each

containing 400mg from extracted natural whole herb. Echinacea prepared freshly by dissolving in demineralized water at a dose of 150mg/kg b.wt to be orally administrated to rats through gastric tube.

Animals

A total of 49 male albino rats weighting 180-240gm were provided by the Animal Breeding Unite at Nuclear Research Centre, Atomic Energy Authority. Animals were housed under normal conditions (25±C°, 12h light and dark cycle), allowed a regular diet and water during the experiment and left for acclimatization period for two weeks prior to starting the study.

The experimental animal procedures were authorized by the Research Ethical Committee of Ain Shams University, Egypt (REC-FS, Ino. 00033). Rats were handled according to National Institutes of Health (NIH) guidelines for animal experimentation.

Experimental design

The animals were partitioned into 7 groups (7rats/group) and accommodated in separate cages. Group 1 served as the control group, with rats receiving (1 ml i.p. saline and 1 ml dist. water orally). Group 2 rats were given lead acetate Pb (CH3COOH)2 (60mg/Kg b.wt/day) orally [13]. Group 3: rats were injected intraperitoneally with cerium oxide nanoparticles (CeONPs) (0.5mg/kg b.wt/day) [14]. Group4: rats orally administered with Echinacea *purpurea* extract (E.P.) (150mg/kg b.wt/day)[15]. Group 5 rats were given lead (60mg/kg body weight) and CeONPs (0.5mg/kg body weight). Group 6: rats were given lead (60mg/kg b.wt) and *E. purpurea* (150mg/kg b.wt) orally. Group 7: rats were given lead (60mg/kg b.wt), CeONPs (0.5 mg/kg b.wt), and *E. purpurea* (150gm/kg b.wt). All rats received their treatments for two weeks (five days/week).

Following treatment, animals were slaughtered under light anesthesia. Blood was collected from heart through cardiac puncture. One part of blood was collected in heparinized tubes for measurements of hematological indices by auto hematological counter, SweLab alpha and the other part of blood was collected in test tubes, after centrifugation the obtained serum were frozen at -20C° for biochemical analyses.

The spleen was detached and separated into two parts; one part in 50mM sodium phosphate buffer 2mM EDTA (pH 7.4) and homogenized then, centrifuged at 10.000Xg for 20 min at 4C° and the resultant supernatant was collected and maintained at -80C° for investigation of Malondialdehyde (MDA), Reduced glutathione (GSH) and catalase (CAT) using assay kits from Biodiagnostic Co, Egypt. The second part of spleen tissue was kept in formalin (10%) followed by washing in distilled water then in ascending grades of ethanol, clearing the samples in xylene and melted paraffin and finally embedding in paraffin wax at 65C°. Wax blocks were sectioned at 5µ and stained with (H&E) hematoxylin and eosin.

Levels of interleukin-6 (IL-6) and interleukin-10 (IL-10) were estimated using (ELISA) kits purchased from DRG international Inc., USA for IL-6 and Invitrogen Elisa kit for IL-10. Immunoglobulins (IgG) and (Ig M) levels were estimated using Elisa kits. Tumor Necrosis Factor-α (TNF-α) level evaluated using ELISA kit (Abcam Cambridge, UK; TNF-α_Cat# ab100785). Serum testosterone level was assessed by radioimmunoassay using kits obtained from DIA source immune assay S.A, Louvain-La-Neuve-Belgium.

Statistical analysis

Resulted data were analyzed using (ANOVA) one-way analysis of variance through COSTAT, program v3.03, 198, followed by Duncan’s test.

RESULTS

Table (1) shows hematological parameters. Lead acetate injection decreased RBC’s count, Hb content, and HCT value in comparison with the control group. Administration of *E. purpurea* to lead injected rats significantly increased RBC’s count, Hb and HCT values comparable to lead-injected group. Whereas treatment with CeONPs following lead injection insignificantly affected RBC’s count and Hb content relative to lead group. Platelet count increased markedly in lead-injected rats. Treatment with E.P. and CeONPs and their mixture significantly ameliorated platelet count.

Table (1): Effect of Cerium Oxide NPs and Echinacea on RBC’s, hemoglobin, hematocrit, and platelets in Lead-injected rats

Group Parameter	RBC’s (x 10 ¹² /L)	Hb (g/dl)	HCT (%)	Platelets (x10 ⁹ /L)
Control group	5.35±0.3 ^a	15.49±0.57 ^a	46.91±2.07 ^a	310±34.19 ^c
Lead group	2.61±0.18 ^f	11.96±0.41 ^e	35.94±1.41 ^e	465.43±45.96 ^a
CeONPs group	4.39±0.37 ^{cd}	13.37±0.84 ^d	44.53±189 ^b	309.28±36.75 ^c
Echinacea group	5.13±0.39 ^{ab}	14.98±0.55 ^{ab}	44.06±1.30 ^b	308.43±33.56 ^c
Lead+CeONPs group	3.58±0.4 ^e	13.22±0.56 ^d	39.65±1.56 ^d	388.14±24.46 ^b
Lead+ <i>E. purpurea</i> group	4.19±0.47 ^d	14.21±0.49 ^c	41.8±1.50 ^c	378.86±22.52 ^b
Lead+CeONPs +E.P.group	4.74±0.46 ^{bc}	14.77±0.49 ^{bc}	44.35±145 ^b	364.85±43.09 ^b

Results displayed as mean±SD (n=7). Distinct superscripts (a,b,c) in the same column imply significant difference at p(≤0.05)

Table (2) shows that the total counts of leukocytes and lymphocytes were significantly decreased with the monocyte count in lead-injected rats compared to the control group. Administration of E.P. and CeONPs ameliorated these parameters significantly and mixture treated rats demonstrated more alleviation and normalization of leukocytic profile.

Table (2): Effect of Cerium Oxide NPs and Echinacea on total and differential leucocytic counts in Lead-injected rats

Group	WBC'S (x10 ⁹ /L)	Lymphocytes	Monocytes	Neutrophils	Eosinophils	Basophils
Control group	9.96±0.85 ^b	6.23±0.65 ^b	0.25±0.05 ^b	3.43±0.64 ^a	0.0310.005 ^{ab}	0.02±0.005 ^{ab}
Lead group	6.76±0.67 ^e	3.3±0.32 ^f	0.13±0.03 ^d	3.3±0.62 ^a	0.02 0.004 ^c	0.01±0.003 ^b
CeONPs group	10.03±0.9 ^b	6.47±0.8 ^b	0.24±0.04 ^b	3.27±0.63 ^a	0.03±0.007 ^{ab}	0.02±0.004 ^a
Echinacea group	11.32±0.79 ^a	7.45±0.12 ^a	0.29±0.05 ^a	3.52±0.71 ^a	0.04±0.007 ^a	0.19±0.004 ^a
Lead+CeONPs group	7.66±0.59 ^d	4.13±0.51 ^e	0.18±0.02 ^c	3.31±0.34 ^a	0.02±0.005 ^c	0.19±0.004 ^{ab}
Lead+ <i>E. purpurea</i> group	8.53±0.4 ^c	4.79± 0.48 ^d	0.20±0.03 ^{bc}	3.5±0.42 ^a	0.03±0.003 ^{bc}	0.014±0.005 ^{ab}
Lead+CeONPs+E.P. group	9.26±0.53 ^{bc}	5.47± 0.51 ^c	0.23±0.03 ^{bc}	3.52±0.3 ^a	0.031±0.006 ^{ab}	0.014±0.005 ^{ab}

Results displayed as mean±SD (n=7)

Distinct superscripts (a,b,c) in the same column imply significant difference at p(≤0.05)

Table (3) indicated that lead-induced immune- toxicity reflected by a marked increase in IL-6 and TNF-α in lead-injected group, and notable decline in IL-10 with respect to control group. The effect of *E. purpurea* administration on interleukins levels was obvious where IL-6 and TNF-α were markedly reduced and IL-10 level was increased in lead-injected rats comparable to lead-group. CeONPs treatment restored IL-6 and TNF-α levels, decreasing their values significantly and elevate IL-10 level significantly as compared to lead group. The most improving effect was in mixture treated rats followed with *E. purpurea* administrated rats.

Table (3): Effects of Cerium Oxide NPs and Echinacea on IL-10, Il-6 and TNF-α in Lead-injected rats

Group	IL-10 (pg/ml)	IL-6 (pg/ml)	TNF-α(pg/ml)
Control group	14.41±1.33 ^b	17.59±0.91 ^e	242.14±20.58 ^d
Lead group	6.94±0.78 ^e	42.7±3.21 ^a	704±19.25 ^a
Cerium group (CeONPs)	14.11±1.46 ^b	17.39±0.75 ^e	236.85±19.36 ^c
Echinacea group(<i>E. purpurea</i>)	19.21±1.67 ^a	18.07±0.73 ^e	239.71±19.01 ^e
Lead+CeONPs group	9.98±0.55 ^d	30.35± 3.33 ^b	426.57±33.31 ^b
Lead+ <i>E. purpurea</i> group	10.71±0.42 ^d	24.41±1.55 ^c	390.71±18.86 ^c
Lead+CeONPs+ <i>E. purpurea</i> group	12.0±0.35 ^c	20.51±2.39 ^d	321.57±19.72 ^d

Results displayed as mean±SD (n=7)

Distinct superscripts (a,b,c) in the same column imply significant difference at p(≤0.05)

Table (4) serum levels of immunoglobulins IgG and IgM were reduced in lead-injected group in comparison with control group. *E. purpurea* administration displayed a strong immunomodulatory role against lead induced immuno-toxicity in lead-injected rats. E.P. ameliorated IgG and IgM levels in comparison with control group. Also, intraperitoneal injection with CeONPs to lead-injected rats corrected the levels of IgG and IgM as compared to Lead-injected rats. The results showed that the mixture tread group showed the best ameliorative effect. Serum testosterone level reduced significantly in lead-injected rats with respect to control group. Treatment with *E. purpurea* and CeONPs and their mixture to lead-injected rats significantly increased serum testosterone level. The highest effect was noticed in the group treated with both *E. purpurea* and CeONPs that nearly normalize testosterone.

Table (4) Effects of Cerium Oxide NPs and Echinacea on IgG, IgM and Testosterone levels in lead-injected rats

Group Parameter	IgG (ng/ml)	IgM (ng/ml)	Testosterone (ng/ml)
Control group	1241.57± 94.17 ^a	818.57±48.42 ^a	7.61±0.90 ^a
Lead group	637±5.69 ^f	464.29±47.48 ^d	0.44±0.1 ^d
Cerium group (CeONPs)	1195.57±119.08	787±47.97	7.32±0.86
Echinacea group(E.P.)	1133.14± 134.35 ^{ab}	803.29±49.29 ^a	7.7± 0.81 ^a
Lead+CeONPs group	821.86±58.15 ^{bc}	614.14± 56.04 ^a	4.15±0.65 ^a
Lead+E.P. group	921.43± 80.25 ^e	659.71± 56.88 ^c	4.5±0.56 ^c
Lead+CeONPs+E.P. group	1043.14±76.43 ^e	726.29±56.81 ^b	5.34±0.72 ^b

Results displayed as mean±SD (n=7)

Distinct superscripts (a,b,c) in the same column imply significant difference at p(≤0.05)

Table (5) revealed that lead induced an antioxidant distortion that arise as a marked increase of MDA level and a notable reduction in GSH content and CAT activity in the spleen of lead-injected rats parallel to control rats .Treatment with CeONPs and E.P. and their mixture demonstrated a notable reduction in MDA level and marked increase in CAT activity and GSH level in spleen of lead-injected rats. The best antioxidant effect was evaluated in rat group treared with the mixture after which CeONPs treated group.

Table (5) Effects of Cerium Oxide NPs and Echinacea on Catalase (CAT) activity, Reduced glutathione (GSH) and Malaondialdahyde (MDA) levels in spleen of lead-injected rats

Group Parameter	CAT (u/min/mg tissue)	GSH (mg/g tissue)	MDA (nmol/ g tissue)
Control group	0.57±0.003 ^{ab}	11.28±1.71 ^a	28.69±2.18 ^d
Lead group	0.32±0.050 ^c	3.23±0.66 ^c	67.4±2.76 ^a
Cerium group (CeONPs)	0.59±0.063 ^a	12.06±1.23 ^a	21.28±2.76 ^e
Echinacea group(E.P.)	0.64±0.095 ^a	11.77±1.15 ^a	26.84±2.56 ^d
Lead+CeONPs group	0.43±0.062 ^d	8.61±0.75 ^c	34.45±3.74 ^c
Lead+E.P. group	0.47±0.062 ^{cd}	7.34±0.80 ^d	38.87±4.17 ^b
Lead+CeONPs+E.P. group	0.51±0.060 ^{bc}	9.8±1.01 ^b	30.53±5.19 ^d

Results displayed as mean±SD (n=7).

Distinct superscripts (a,b,c) in the same column imply significant difference at p(≤0.05)

Histopathologic Findings

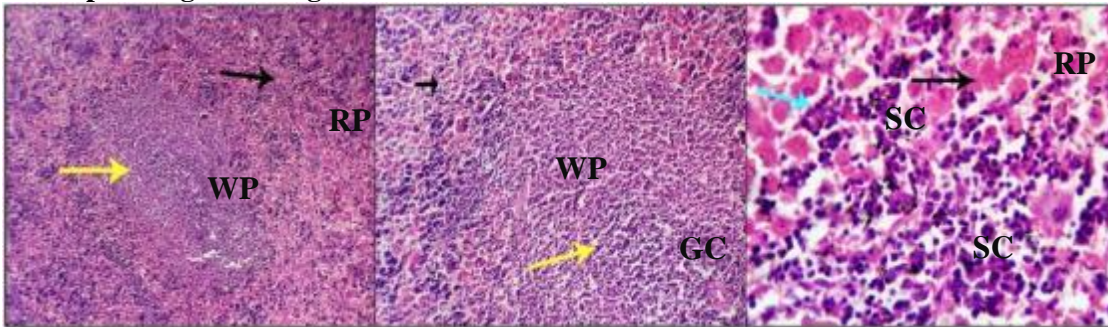


Fig. (1): Spleen cross sections of control group showing normal architecture with distinguished red, white pulp and splenic cords (black, yellow and light blue arrows) with a normal histo- morphological appearance. (H&E X 100, 200, 400, respectively)

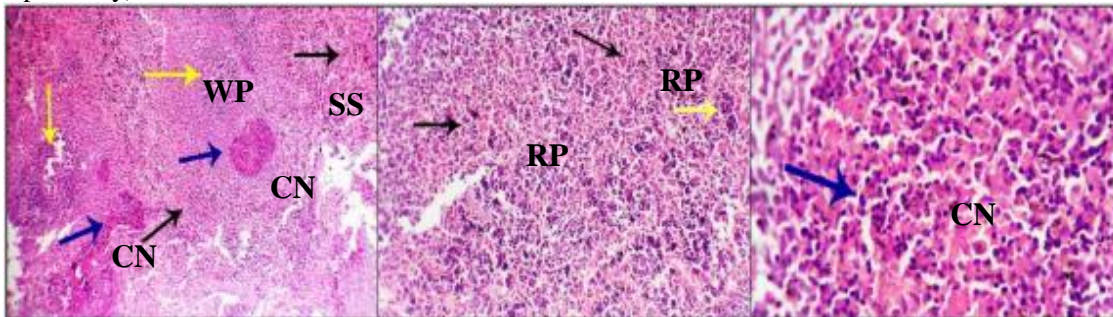


Fig. (2): Spleen cross sections of lead injected group showing severe dilation of splenic sinusoids (SS), multiple hemorrhages(H) , and decreased numbers of reticule endothelial cells. Coagulative necrosis with presence of many nuclear and cytoplasmic necrotic debris are seen, mostly in the area of the white germinal centers (dark blue arrows, CN). Decrease population of the lymphoid cells of the mantle and marginal zone are seen (WP, yellow arrows) . H&E X 100, 200, 400

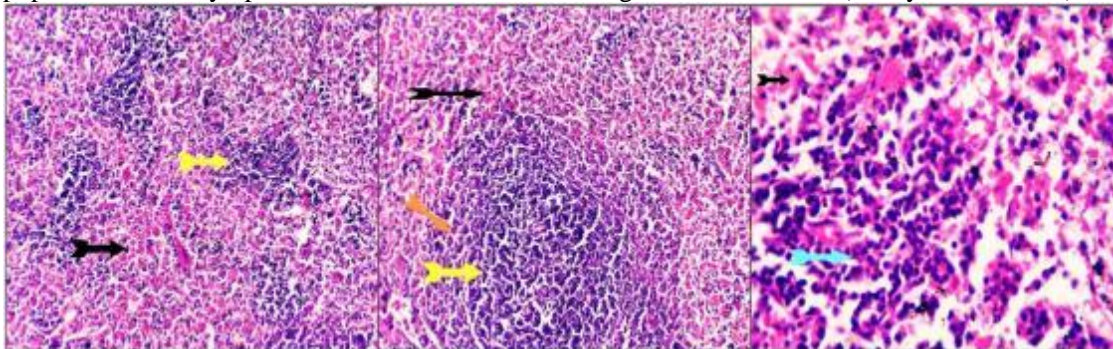


Fig. (3): Spleen cross sections of CeONPs group showing apparently normal histo-morphologic structures comparable to that of the control free group with a keeping features of the morphologic structures of white and red pulp. Activated germinal centers cells and marginal zone lymphoid cells (yellow and orange arrows)beside increase population of the circulating lymphoid and plasmacytoid cells of the splenic cords (light blue arrows) in addition to a more activated macrophages of the splenic sinusoidal reticulo-endothelial cells(M) are seen. H&E X100, 200, 400

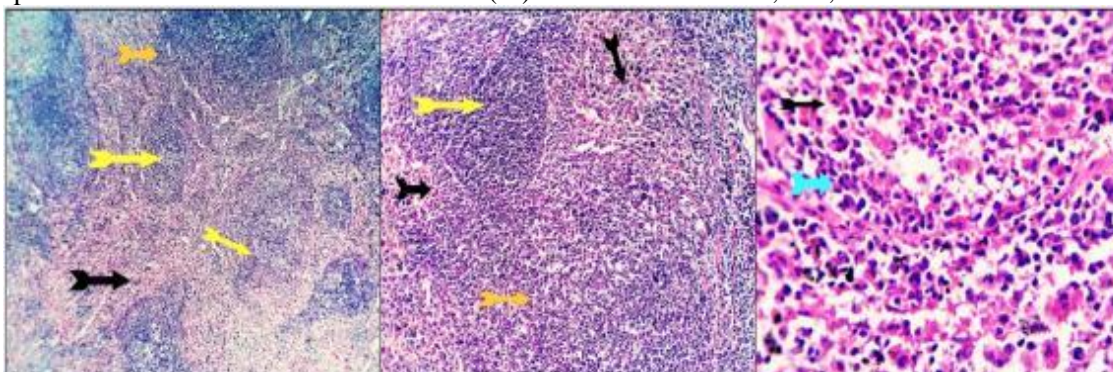


Fig. (4): Spleen cross sections of *E. purpurea* group showing a keeping features of the histo-morphologic structures of white and red pulp (yellow and black arrows). The germinal centers cells populations and marginal zone lymphoid cells appears prominent (orange arrow). Increase population of the circulating lymphoid and plasmacytoid cells of the splenic cords (light blue arrow) in addition to a more activated macrophages of the splenic sinusoidal reticulio-endothelial cells are (M) seen. H&E X100, 200, 400.

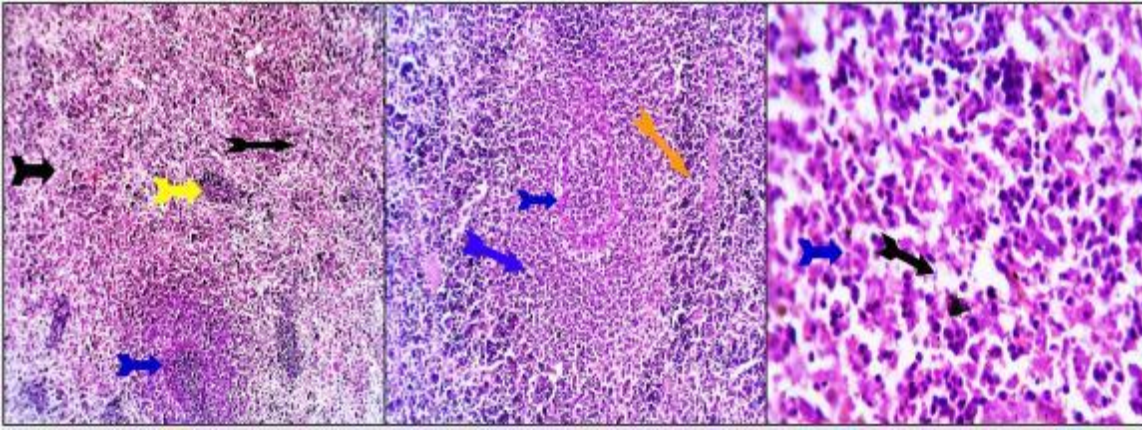


Fig. (5): Spleen cross sections of lead & CeONPs group showing germinal lymphoid cells necro-biotic changes (dark blue arrows) with the same effect on the marginal zonal cells (orange arrow), but with a lesser extent. Red pulp structures reveal moderate splenic sinusoidal dilatation and prominent macrophage hypertrophic and occasionally hyperplastic changes (black arrow). Hemosiderosis with a moderate number of hemosiderin-laden macrophages (HS) is seen. H&E X 100, 200, 400.

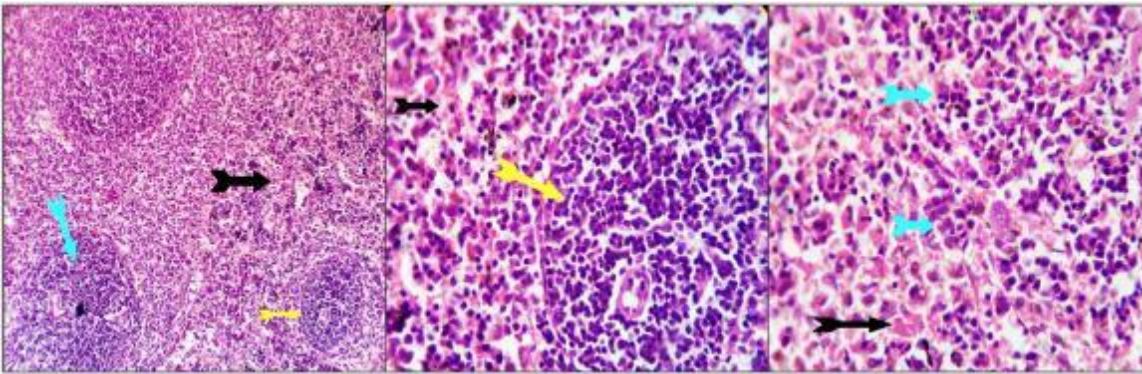


Fig. (6): Spleen cross sections of lead & *E. purpurea* group showing mild to moderate decrease in white pulp (yellow arrows). Lymphoid populations, this associated with unremarkable differentiation of the mantle and marginal zones (light blue arrow). The red pulp shows marked splenic sinusoidal dilatations, multi-focal hemorrhages and decrease population of the circulating lympho-plasmocytic cells together with a low intensity of the activated macrophages (black arrows). Occasional hemosiderosis is seen (HS). H&E X 100, 200, 400.

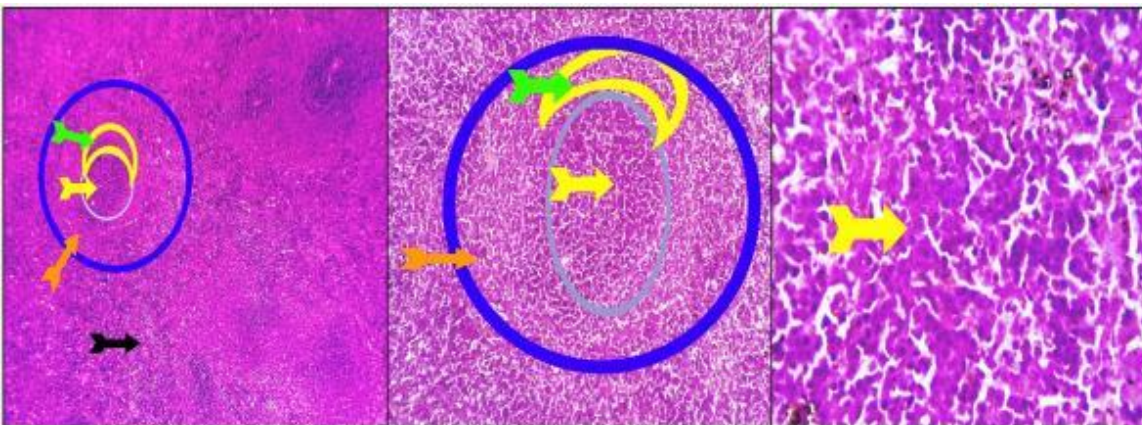


Fig. (7): Spleen cross sections of lead & CeONPs and E.P. group showing activated white pulp germinal centers (yellow arrow, light blue circle), mantle lymphocytes (green arrow, yellow hemisphere) and marginal zone lymphoid cells (orange arrow, dark blue circle), the red pulp shows an activated immune-reactive status with hypertrophic, high phagocytic reticulo-endothelial cells and increased population of the circulating mature lymphocytes and plasma cells (black arrow). H&E X 100, 200, 400.

DISCUSSION

The hematopoietic system is a highly sensitive system to evaluate toxicity. The current research intended to demonstrate the controversial impacts of lead-induced toxicity on oxidative stress considering its relations to hematopoietic system and immune functions and also to evaluate the potential effect of CeONPs and *E. purpurea* as exogenous supplementation in improving immune function and oxidative stress in lead-injected rats.

The current reduction of RBC's, Hb and HCT in lead-injected rats revealed that lead caused anemia that may be attributed to the effect of lead on haem biosynthesis by lowering aminolevulinic acid dehydratase and ferrochelatase activities [16].

Osterode et al. [17] reported that lead, decreased erythropoietin output resulting in reduction of bone marrow erythropoiesis. In addition, free radical and lipid peroxidation resulted from oxidative stress caused by lead injection were involved in RBC hemolysis and anemia. Also it is recognized that Pb binds-SH groups of various proteins involving enzymes, consequently decrease their activities and increases MDA and H₂O₂ in RBCs with consequent reduction in glutathione level [18]. Thrombocytosis appeared in lead injected rats could be due to inflammation caused by lead. Results, revealed leukopenia and lymphopenia in lead-injected rats, which may be attributed to decrease production from the lymphoid organs as a result of lead toxic effect on leucopoiesis lymphoid organs or increased lysis [19].

Current experiments revealed that treatment of lead-injected with E.P., CeONPs and their mixture ameliorated all hematological parameters comparable to lead-injected group. Also it was appeared that E.P. improved hematological parameters more than CeONPs. Administration of E.P. to lead-injected rats presented a significant correction in all hematological parameters. This improvement attributed to the contents of E.P. as cichoric acid and echinacin as they stimulate the hematopoietic system [7]. In addition, E.P. alters the proportions of lymphocyte sub populations; this confirmed that E.P. could enhance both innate and adaptive immune functions [15]. CeONPs treatment alleviated the altered hematological features against the negative effect of lead indicating antioxidant property for CeONPs.

Interleukin-10 is an anti-inflammatory cytokine, is delivered by Th2 (T-helper) cells, certain B-cells and activated macrophages. It effects on macrophages to suppress secretion of IL-1, IL-2, TNF- α and ROS [20]. The significant decline in IL-10 level in lead-injected rats could be attributed to the decrease in the immune cells after lead-injection. Administration of E.P. extract and CeONPs injection improved the reduction of anti-inflammatory IL-10 level in lead-injected rats. This results agreed with that reported by **Zhai, et al.** [15], as Echinacea increases IL-10 level in treated mice indicating high immuno modularly effect

of E.P. Also, CeONPs treatment increased IL-10 immuno reactivity confirming the anti-inflammatory effect of CeONPs. Interleukin-6 is a powerful pro-inflammatory cytokine that promotes prostaglandin formation, neutrophil influx stimulation and proliferation of T and B lymphocytes; monocytes and macrophages are responsible for its synthesis. IL-6 raises body temperature during infection by stimulating acute phase protein synthesis [21].

In present work results showed notable increase in IL-6 and TNF- α levels in lead-injected rats. Earlier studies revealed that lead treatment elevates inhibitory phosphorylation of adenosine monophosphate-activated protein kinase (AMPK) which increases free radicals and elevates the inflammatory cytokines in tissue and serum [22]. Similarly **Gargouri et al.** [23] demonstrated that lead-intoxication elevated IL-6 and TNF- α in rats. Oral administration of E.P. and CeONPs treatment and their mixture to lead-injected rats declined the inflammatory markers and their mixture success to decrease IL-6 and TNF- α level near control value in lead-injected rats.

Administration of E.P. decreases IL-6 and TNF- α result go in hand with results obtained by **Wang et al.** [24] that confirmed the positive impact of E. P. on the immune system. Similarly, CeONPs treatment lowered levels of pro-inflammatory cytokines, IL-6 and TNF- α which in agreement with [12]. This may be attributed to that CeONPs declines the generation of pro-inflammatory cytokines which known to generate free radicals and reduce oxidative stress by scavenging ROS.

Lead affects both cellular and humoral immune responses by decreasing production of IgG, IgM therefore increasing inflammatory diseases [25]. Immunoglobulin are molecules produced by white blood cells, protect against infections and representing first immune response [26]. The significant decrease in serum IgG, IgM in lead-injected rats explained lead ability to affect B and T lymphocytes functions. Lead results in oxidative stress that can influence the functions of immune system [2]. Under normal conditions, Th2 cells drive the humoral immunity and up regulate the production of antibodies via anti-inflammatory cytokines (IL-10, IL-6 and IL-4). These cytokines signal B cells to differentiate to antibodies IgG, IgM, and IgE [27]. Accordingly impaired Th2 Cell function can reduce IgG and IgM just as impaired B – cells [28]; this confirmed in our results by raising MDA levels and minimizing GSH content, these results confirmed histologically by severe lymphoid follicle size. This in line with previous studies that reported decrease in serum immunoglobulins levels following lead exposure [29]. Administration of E.P. to lead-injected rats ameliorated the levels of IgG, and IgM. Echinacea can stimulate macrophages to enhance IFN-gamma production in combination with the secondary stimulation of T-lymphocytes [30].

The data showed that lead-injected group developed oxidative stress, which caused damage to the antioxidant defense systems, as evidenced by increasing MAD (the oxidative stress biomarker) and free radicals scavenging enzymes; GSH and CAT decreased^[2]. Where lead binds to SH- group of proteins involving GSH, SOD and CAT lowering their actions and increases lipid peroxidation^[31].

Treatment with E.P. and CeONPs and their mixture significantly reduced MDA and significantly elevated GSH and CAT activities. CeONPs treated group showed more potent antioxidant activity than E.P. administrated group. This refers to the antioxidant effect of CeONPs to attenuate (ROS) and increase enzymatic antioxidant activity. CeONPs provide several sites for scavenging free radicals due to their paired valence states and their large surface/volume ratio also, CeONPs, reconstruct their catalytic function randomly by changing between the oxidation and the reduction states^[9] that permit CeONPs to react with hydrogen peroxide and superoxide mimics the effects the internal anti-oxidant enzymes. As expected, CeONPs could reduce lipid peroxidation in lead-injected rats and increase GSH level and CAT activity due to their scavenging ability.

Echinacea purpurea treatment to lead-injected rats decreased MDA and increased GSH level, CAT activity this may be due to the antioxidant effect of *E. purpurea* that including scavenging free radicals and chelating transition metal^[32]. Furthermore, E.P contains many active components such as caffeic acid and polyphenolics including cichoric acid and glycosylated flavonoids and polysaccharides that are responsible for the anti-inflammatory and antioxidant effects of E.P^[5].

Considering the present study, lead-injected-rats exhibited a significant decrease in testosterone level. This could be attributed to that lead toxicity affecting the pituitary and hypothalamus on secretion luteinizing hormone (LH). Lead also, causes direct damage in testis seminiferous tubules and decreased testosterone secretion from leydig cells^[33]. Also, **Biswas and Ghosh**^[34] reported that lead affects testis steroidogenic activity, as well as testosterone and gonadotropin serum levels in rats. Furthermore, lead can penetrate the blood testis barriers, affecting the germinal cell distinction and reducing serum testosterone level^[22]. Treatment with CeONPs, E.P. and their mixture ameliorated the significant reduction in testosterone level in lead-injected rats. Whereas CeONPs and E.P. treatment massively scavenged free radicals consequently reduced MDA level (the final product of lipid peroxidation) which could be considered as one of lead-induced toxicity mechanism and increased GSH and CAT activities.

CONCLUSION

Our results demonstrated that lead-induced toxic effects on immune system, blood and spleen histological alternations. The main tool of toxicity,

oxidative stress, was involved as an obvious reason in our study, causing impaired redox condition in the spleen of treated rats. Treatment with natural antioxidant and immune-modulatory E.P. and CeONPs can inhibit the toxic effects of lead by activating the suppressed immune response through their antioxidant and anti-inflammatory effects.

Acknowledgement: The authors would like to thank Prof. Dr. Al-Sayed R. Al-Attar Professor of Pathology, Faculty of Veterinary Medicine, Zagazig University, Egypt, for histopathological analysis of the current work.

Financial support and sponsorship: Nil.

Conflict of interest: Nil.

REFERENCES

1. **Ademuyiwa O, Ugbaja R, Rotimi S et al. (2007):** Erythrocyte acetylcholinesterase activity as a surrogate indicator of lead-induced neurotoxicity in occupational lead exposure in Abeokuta, Nigeria. *Environmental Toxicology and Pharmacology*, 24: 183-188.
2. **Matović V, Buha A, Dukić-Cosić et al. (2015):** Insight into the oxidative stress induced by lead and/or cadmium in blood, liver and kidneys. *Food Chem Toxicol.*, 78: 130-140.
3. **Skoczynska A, Poreba R, Sieradzki A et al. (2002):** The impact of lead and cadmium on the immune system. *Medycyna Pracy*, 53(3): 259-64.
4. **Kumar K, Ramaiah S (2011):** Pharmacological importance of *Echinacea purpurea*. *Int J Pharm Biol Sci.*, 2:304-14.
5. **Aarland R, Bañuelos-Hernández A, Fragosó-Serrano M (2017):** Studies on phytochemical, antioxidant, anti-inflammatory, hypoglycaemic and antiproliferative activities of *Echinacea purpurea* and *Echinacea angustifolia* extracts. *Pharmaceutical Biology*, 55(1): 649-56.
6. **Rininger J, Kickner S, Chigurupati P et al. (2000):** Immunopharmacological activity of *Echinacea* preparations following stimulated digestion on murine macrophages and human peripheral blood mononuclear cells. *J Leukoc Biol.*, 68: 503-510.
7. **Goel V, Chang C, Slama J et al. (2002):** Alkylamides of *Echinacea purpurea* stimulate alveolar macrophage function in normal rats. *International Immunopharmacology*, 2(2-3): 381-7.
8. **Allawadhi P, Singh V, Govindaraj K et al. (2021):** Biomedical applications of polysaccharide nanoparticles for chronic inflammatory disorders: Focus on rheumatoid arthritis, diabetes and organ fibrosis. *Carbohydrate Polymers*, 22: 118923. doi: 10.1016/j.carbpol.2021.118923.
9. **Korsvik C, Patil S, Seal S et al. (2007):** Superoxide dismutase mimetic properties exhibited by vacancy engineered ceria nanoparticles. *Chem Commun.*, 10:1056-1058.
10. **Pirmohamed T, Dowding J, Singh S et al. (2010):** Nanoceria exhibit redox state-dependent catalase mimetic activity. *Chemical Communications*, 46(16): 2736-8.

11. **Dowding J, Seal S, Self W (2013):** Cerium oxide nanoparticles accelerate the decay of peroxynitrite (ONOO-). *Drug Delivery Transl Res.*, 3(4): 375–379.
12. **Saifi M, Sangomla S, Khurana A et al. (2019):** Protective effect of nanoceria on cisplatin-induced nephrotoxicity by amelioration of oxidative stress and pro-inflammatory mechanisms. *Biol Trace Elem Res.*, 189:145–156.
13. **Cheong M, Roh Y (2006):** Protective effects of activated charcoal on the acute damages of kidney of mouse by lead. *Applied Microscopy*, 36(2): 57-72.
14. **Hajinezhad M, Shahri S, Rahdar A et al. (2020):** Effects of Cerium Oxide Nanoparticles on Biochemical Parameters and Histological Changes in Lead Intoxicated Rats. *Dis Diagn.*, 9(4): 134-139.
15. **Zhai Z, Liu Y, Wu L et al. (2007):** Enhancement of innate and adaptive immune functions by multiple Echinacea species. *Journal of Medicinal Food*, 10(3): 423-34.
16. **Suleiman F, Mary A, Muftau S et al. (2011):** Hematological changes induced by subchronic co-administration of chlorpyrifos and lead in Wistar rats: Alleviating effect of vitamin C. *Der Pharmacia Sinica*, 2 (2): 276-284.
17. **Osterode W, Barnas U, Geissle K (1999):** Dose dependent reduction of erythroid progenitor cells and inappropriate erythropoietin response in exposure to lead: new aspects of anaemia induced by lead. *Occupational Environmental Medicine*, 56: 106-109.
18. **Mladenovic J, Ognjanovic B, Đorđević N et al. (2014):** Protective effects of oestradiol against cadmium-induced changes in blood parameters and oxidative damage in rats. *Arhiv za higijenu rada i toksikologiju Toksikol.*, 65: 37–46
19. **Avadheshkumar R, Chauhan R, Singh N (1998):** Immunological effect of lead on cell mediated immunity in chicken. *Industrial Journal of Veterinary Pathology*, 22 (1): 22-28.
20. **Iyer S, Cheng G (2012):** Role of Interleukin 10 Transcriptional Regulation in Inflammation and Autoimmune Disease. *Crit Rev Immunol.*, 32(1): 23–63.
21. **Lee J, Laydon J, McDonnell P et al. (1994):** A protein kinase involved in the regulation of inflammatory cytokine biosynthesis. *Nature*, 372:739–746.
22. **BaSalamah M, Abdelghany A, El-Boshy M et al. (2018):** Vitamin D alleviates lead induced renal and testicular injuries by immunomodulatory and antioxidant mechanisms in rats. *Sci Rep.*, 8:1-13.
23. **Gargouri M, Hamed H, Akrouti A et al. (2017):** Immunomodulatory and antioxidant protective effect of *Sarcocornia perennis* L.(swampfire): in lead intoxicated rat. *Toxicol Mech Methods*, 27:697–706.
24. **Wang C, Hou Y, Lv Y et al. (2017):** Echinacea purpurea Extract Affects the Immune System, Global Metabolome, and Gut Microbiome in Wistar Rats. *Journal of Agricultural Science*, 9(4): 1-14.
25. **Anetor J, Adeniyi F (1998):** Decreased immune status in Nigerian workers occupationally exposed to lead. *Afr J Med Med Sci.*, 27:169–172.
26. **Suzuki K, Tomasi T (1979):** Immune Responses During Pregnancy. Evidence of Suppressor Cells for Splenic Antibody Response. *Journal of Experimental. Medicine*, 150(4): 898-908.
27. **Zhu J (2015):** T helper 2 (Th2): cell differentiations, type 2 innate lymphoid cell (ILC2): development and regulation of interleukin-4 (IL-4): and IL-13 production. *Cytokine*, 75(1): 14-24.
28. **Hassanen E, Khalaf A, Tohamy A et al. (2019):** Toxicopathological and immunological studies on different concentrations of chitosan-coated silver nanoparticles in rats. *Int J Nanomedicine*, 14: 4723-4739.
29. **Luster M, Faith R, Kimmel C (1978):** Depression of humoral immunity in rats following chronic developmental lead exposure. *J Environ Pathol Toxicol.*, 1:397-402.
30. **Mishima S, Saito K, Maruyama H et al. (2004):** Antioxidant and immuno-enhancing effects of Echinacea purpurea. *Biological and Pharmaceutical Bulletin*, 27(7): 1004-9.
31. **Andjelkovic M, Buha Djordjevic A, Antonijevic E et al. (2019):** Toxic effect of acute cadmium and lead exposure in rat blood, liver, and kidney. *Int J Environ Res Public Health*, 16: 274. doi: 10.3390/ijerph16020274
32. **Hu C, Kitts D (2000):** Studies on the antioxidant activity of Echinacea root extract. *J Agric Food Chem.*, 48:1466-72.
33. **Ahmad I, Sabir M, Yasin K (2003):** Study of the effect of lead poisoning on the testis in albino rats. *Pakistan J Med Res.*, 42(3): 97- 101.
34. **Biswas-N, Ghosh P (2004):** Effect of lead on male gonadal activity in Albino Rats. *Kathmandu Univ Med J.*, 2(1): 43-46.