

## Tube Thoracostomy Outcomes in COVID-19 Patients

Mohamed Elkhoully\*, Ahmed Fouad

Department of Cardiothoracic surgery, Faculty of Medicine, Cairo University, Egypt

\*Corresponding authors: Mohamed Elkhoully, Mobile: (+20) 01115551412, E-mail: elkhoullymohamed98@gmail.com

### ABSTRACT

**Background:** SARS-CoV-2 (severe acute respiratory syndrome coronavirus 2) is an extremely infectious virus causing COVID-19 illness. Respiratory failure is a consequence of COVID-19 illness related pneumonia, in which mechanical ventilation and endotracheal intubation are essential. Barotrauma is a chief complication due to mechanical ventilation, in which pneumothorax was established in 25% of COVID-19 barotrauma patients. The majority of complicated COVID-19 cases with a pleural effusion or pneumothorax require a thoracostomy.

**Objective:** To recognize and analyse tube thoracostomy consequences in COVID-19 complicated individuals through this pandemic. **Patients and Methods:** A retrospective study was accomplished in Thoracic Surgery Unit of Elkasr Elaini Medical Center, Cardiothoracic Surgery Department in Cairo University, Cairo, Egypt. We included fifteen COVID-19 individuals entered the ICU in the period between June 2020 and September 2021 requiring thoracic surgery consultation. Non-COVID-19 severe illness and iatrogenic pneumothorax were omitted from this study.

**Results:** Nine pneumothorax cases (73.3%), two surgical emphysema associated with pneumothorax cases (13.3%), three pleural effusion cases (20%) and one hydropneumothorax case (6.7%) as a total of fifteen patients needed thoracic surgery consultation. After tube thoracostomy, there were no harm consequences. From the total number of patients, 12 well improved and discharged (80%) and three were dead (20%) within three days after tube thoracostomy who were mechanically ventilated due to respiratory failure after ARDS.

**Conclusion:** COVID-19 complicated cases needed chest tube insertion is associated with good outcomes and improvement.

**Keywords:** COVID-19, SARS-COV-2, chest tube, pleural effusion, tube thoracostomy, pneumothorax.

### INTRODUCTION

A worldwide pandemic COVID-19 is the medical state generated by SARS-CoV-2 infection and is linked with considerable morbidity and death, involving acute respiratory failure necessitating ICU admission and sophisticated respiratory assistance <sup>(1)</sup>.

Respiratory failure with profound hypoxemia is a consequence of COVID-19 illness related pneumonia, in which mechanical ventilation and endotracheal intubation are essential <sup>(2)</sup>. An important complication of mechanical ventilation is barotrauma. Barotrauma is a significant complication of mechanical ventilation <sup>(3)</sup>.

Pneumothorax occurred in up to 25% of COVID-19 patients who experienced barotrauma, but only in 2% of patients with certain other reasons of acute respiratory distress syndrome (ARDS) <sup>(3,4)</sup>. Also, there is no agreement on how to manage ventilators and lung relaxation in COVID-19 related ARDS, as well as protecting additional lung injury. Mild COVID-19 individuals with pleural effusion is only 8%, however. It is occurred in 28% of severely ill covid 19 patients <sup>(5)</sup>.

Although controversial, it is presently suggested to implant a tube thoracostomy in critically sick patients on positive pressure ventilation when pneumothorax and pleural effusions are noted <sup>(6)</sup>. These complications are not rare, for example pneumothorax may occur by 5.9% through first day of intubation <sup>(7)</sup>.

There have been several reports stated that in cases of pneumothorax and pleural effusion complicated COVID-19 patients tube thoracostomy is required. However, these reports included individuals of limited sized and involved non-severely sick patients <sup>(6-10)</sup>.

Furthermore, there is no data on the frequency and post-operative prognosis of tube thoracostomy in

severely sick COVID-19 patients. Among these studies on ARDS, one was done on minor number of SARS patients stated that a tube thoracostomy was received in three out of six pneumothorax patients<sup>(11)</sup>.

### AIM OF THE STUDY

The aim of our research is to reveal the consequences of tube thoracostomy regarding morbidity and death in these covid-19 patients who have pneumothorax or pleural effusion.

### PATIENTS AND METHODS

A retrospective study was conducted in Thoracic Surgery Unit of Elkasr Elaini Medical Center Cardiothoracic Surgery Department in Cairo University, Cairo, Egypt. Fifteen COVID-19 cases (admitted in the time interval between June 2020 and September 2021) to ICU and needed thoracic surgery consultation, were included in our study.

### Ethical approval:

**The approval of this study was attained from Cairo University Academic and Ethical Committee. Written informed consent was taken from all participants. The study was conducted according to the Declaration of Helsinki.**

### Inclusion and exclusion criteria:

We involved all ICU entered COVID-19 individuals who needed thoracic surgery intervention by a tube thoracostomy. Iatrogenic pneumothorax and

severe illness patients other than COVID were excluded.

**Data collection:**

Patients' files were appraised and evaluated for all demographics, underline diseases, thoracic consequences outlines, controlling, intubation, re-intubation, ventilator settings, interventions, outcomes, and improvement. Pneumothorax patients inserting thoracostomy tubes were diagnosed in periodically chest X-ray or when this scan was implemented at any time when pneumothorax occurrence clinically suspected.

In the "Safety triangle" chest tubes were all inserted. All thoracic surgery personnel followed the AAST Acute Care Surgery and Critical Care Committees' instructions and recommendations for tube thoracostomy (including wearing protective equipment). All procedures were performed under local anesthesia (2% lignocaine injection) in both intubated and non-intubated patients.

**Statistical analysis:**

Statistical Package for Social Sciences (SPSS) software version 18.0 was used for results statistical analysis. The mean ± Standard deviation (SD) was used as a measure for clinical data. Chi-square, Fisher's exact test, and independent t-tests were used for differences examination. Also, multivariate correlation and regression were performed. In addition, the predicted time of death in this trial size was determined by using Kaplan-Meier test. P value < 0.05 was considered significant.

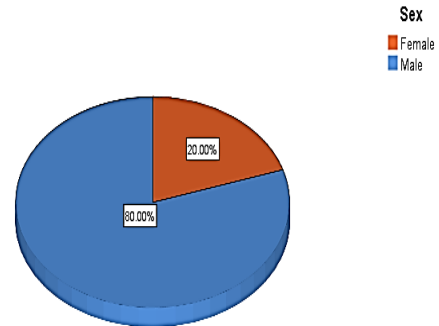
**RESULTS**

A retrospective study was conducted in Thoracic Surgery Unit of Elkasr Elaini Medical Center Cardiothoracic Surgery Department in Cairo University, Cairo, Egypt. Fifteen COVID-19 cases admitted in the time interval between June 2020 and September 2021 to ICU for thoracic operation therapy and consultation, were included in our study.

Twelve patients (80%) were males and three (20%) were females, with a male: female ratio of 4:1. Age was 66 ±10 years and BMI was 24 ± 4 in our study, as demonstrated in **Table (1)** and **Figure (1)**.

**Table (1): Demographic characteristics of study patients.**

		N (%)
Sex	Female	3 (20%)
	Male	12 (80%)
Age (year)	Mean ± SD	66 ± 10
BMI	Mean ± SD	24 ± 4



**Figure (1): Sex Distribution of Patients**

Causes of tube thoracostomy were including: pneumothorax were nine cases (60%), surgical emphysema and pneumothorax were two cases (13.3%), pleural effusion were 3 cases (20%) and hydropneumothorax was one case (6.7%) (**Table 2**).

**Table (2): Causes of tube thoracostomy.**

Cause	N	%
Pneumothorax	9	60 %
Surgical emphysema+ pneumothorax	2	13.3%
Pleural effusion	3	20.0%
Hydropneumothorax	1	6.7%

All cases were emergency, without routine cases or pleural Biopsy and pleurodesis. Detected co-morbidities in patients were HTN (2 cases 13.33%), Asthma (2 cases 13.33%), Coronary artery disease (CAD) (2 cases 13.33%), DM with CAD (1 case 6.66%), HTN with DM (1 case 6.66%), HTN with DM and renal disease (1 case 6.66%), active malignancy with DM (1 case 6.66%), active malignancy with DM, asthma and HTN (1 case 6.66%), DM with asthma and HTN (1 case 6.66%) (**Table 3**).

**Table (3): Distribution of patients' co-morbidities.**

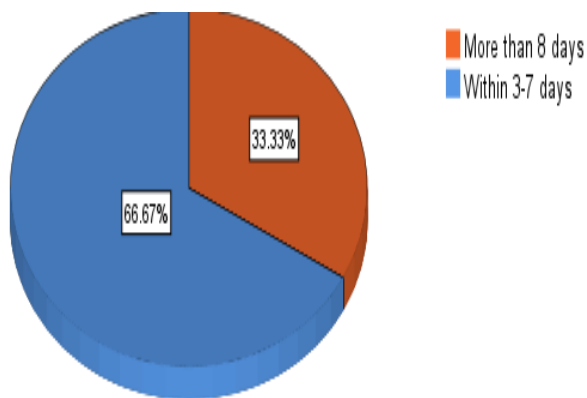
	N	%
Normal	3	20
Hypertension only	2	13.33
Asthma only	2	13.33
Coronary artery disease only	2	13.33
Coronary artery disease + Diabetes	1	6.66
Hypertension + Diabetes	1	6.66
Hypertension + Diabetes +Renal disease	1	6.66
Active malignancy + Diabetes	1	6.66
Active malignancy + Diabetes + Asthma + Hypertension	1	6.66
Hypertension + Diabetes + Asthma	1	6.66

Conditions of the patient during tube thoracostomy were including: 1 case on non-re-breather mask with 16 lit/m O<sub>2</sub> (6.6 %), 3 cases on high flow nasal cannula with 35-60 lit/m O<sub>2</sub> (20 %) 7 cases on biphasic positive airway pressure (BIPAP) 46.6 % and 4 cases on artificial ventilation (26.6 %). The majority of cases were on BIPAP 46.6 % of (Table 4).

**Table (4): Conditions of the patients during tube thoracostomy.**

Condition	N	%
On non-rebreathing mask	1	6.6 %
On high flow nasal cannula	3	20 %
On BIPAP mask	7	46.6 %
On mechanical ventilation	4	26.6 %

Figure 2 illustrated chest drain tube removal time, this was from three to seven days in 10 cases (66.67%) and more than 8 days in 5 cases (33.33%).



**Figure (2): Timing of removal of chest drain tube.**

From the total number of patients, 12 patients well improved and discharged (80%) and three of 4 patients who were mechanically ventilated were dead (20%) within three days after tube thoracostomy due to respiratory failure after ARDS. However, there was no complications resulting from tube thoracostomy (Table 5).

**Table (5): Outcome of patient's condition after tube thoracostomy.**

	N	%
Dead	3	20.0%
Improved	12	80.0%

**DISCUSSION**

In SARS-CoV-1, the mediastinal emphysema is an indicator for increased risk of intubation (12) Barotrauma and severe pneumothorax necessitating chest tube installation causes include failure to track lung dynamics changes and adjust ventilation parameters. Mechanical breathing data soon before chest tube implantation appears to corroborate the possibility of a fragile character among tube thoracostomy patients (13).

Regarding age and sex, our trial indicated that the majority pneumothorax trauma cases were elderly with an age range of 56-76 years old and most of them were males (80%). Other underline diseases as hypertension, coronary artery disease, diabetes, asthma, renal disease and active malignancy were present in 80% of the patients.

Similarly, in the United Arab Emirates study, the age of pneumothorax COVID-19 patients was 40-60 years in 50% of cases and >60 years in 30% of cases; additionally, the majority of the cases (78%) were males, and underline diseases such as hypertension, ischemic heart disease, arrhythmia, diabetes, asthma, and hyperlipidemia, occurred in 76% of the patients (38 out of 50 patients) in the COVID-19 infected individuals(14) which was same case in other studies (15-17).

Furthermore, our findings are consistent with earlier researches (18,19), indicating that pneumothorax is a prevalent and specific risk in COVID-19 patients, with pneumothorax accounting for the bulk of indications for chest tube insertion (73.3%).

In the present study, the removal of chest drain tube was within 3-7 days in 66.67% of patients, which similar to Tawil *et al.* (20) study. It demonstrated that physicians would withdraw a chest tube at 5 to 7 days after its implantation in patients who were on mechanical ventilation and satisfied the criteria for chest tube withdrawal.

Therefore in our trial, COVID-19 complicated patients who underwent thoracostomy tube placement had good prognosis, without complications and with a higher survival rate (80%). The three deaths in this study were not related to any complications.

This is in line with the results of Zantah *et al.* (6), who discovered that in all instances (66.6%), death was not directly associated to the pneumothorax. But, our results were opposite to Al-Ani and his colleagues(14) study, patients who need chest tubes had a higher death rate, a longer period of artificial breathing, and a longer hospital and ICU stay than patients who do not suffer a pneumothorax necessitating chest tube installation.

This study emphasized the necessity of evaluating the possibility of ventilator-related pulmonary damage and a bad recovery pattern in severely sick COVID-19 patients. It also implies that if lung damage occurs, delayed placement of a thoracic tube may signal a bad result and should be considered as an early decision in complicated COVID-19 critically ill patients.

**CONCLUSION**

Tube thoracostomy is a procedure required frequently in severely sick and complicated COVID-19 patients, and could be a negative prognostic sign for the course of the patients. However inserting a chest tube in COVID-19 may be lifesaving especially, in complicated cases. The procedure is associated with good outcomes and improvement. This recommended that, don't delay the intervention neither for fear of deterioration of the

patients' condition or subjecting thoracic surgery staff to the risk of contracting COVID-19, this is as long as protective equipment and guidelines of AAST during COVID-19 pandemic was followed strictly.

**Financial support and sponsorship:** Nil.

**Conflict of interest:** Nil.

## REFERENCES

1. **Yang W, Cao Q, Qin L et al. (2020):** Clinical characteristics and imaging manifestations of the 2019 novel coronavirus disease (COVID-19): A multi-center study in Wenzhou city, Zhejiang, China. *J Infect.*, 80(4): 388-393.
2. **Peters A, Chawla K, Turnbull Z (2020):** Transforming ORs into ICUs. *N Engl J Med.*, 382(19): 52. doi: 10.1056/NEJMc2010853.
3. **Gattinoni L, Coppola S, Cressoni M et al. (2020):** COVID-19 does not lead to a "typical" acute respiratory distress syndrome. *Am J Respir Crit Care Med.*, 201(10):1299-1300.
4. **Yang X, Yu Y, Xu J et al. (2020):** Clinical course and outcomes of critically ill patients with SARS-CoV-2 pneumonia in Wuhan, China: a single-centered, retrospective, observational study. *Lancet Respir Med.*, 8(5): 475-481.
5. **Han R, Huang L, Jiang H et al. (2020):** Early clinical and CT manifestations of coronavirus disease 2019 (COVID-19) Pneumonia. *Am J Roentgenol.*, 215(2): 338-42.
6. **Zantah M, Dominguez Castillo E, Townsend R et al. (2020):** Pneumothorax in COVID-19 disease- incidence and clinical characteristics. *Respir Res.*, 21(1): 1-9.
7. **Yao W, Wang T, Jiang B et al. (2020):** Emergency tracheal intubation in 202 patients with COVID-19 in Wuhan, China: lessons learnt and international expert recommendations. *Br J Anaesth.*, 125(1): 28-37.
8. **Sundaralingam A, Banka R, Rahman N (2021):** Management of Pleural Infection. *Pulmonary Therapy*, 7: 59-74.
9. **Yarmus L, Feller-Kopman D (2012):** Pneumothorax in the critically ill patient. *Chest*, 141(4): 1098-1105.
10. **Tang A, Velissaris T, Weeden D (2002):** An evidence-based approach to drainage of the pleural cavity: Evaluation of best practice. *J Eval Clin Pract.*, 8(3): 333-40.
11. **Sihoe A, Wong R, Lee A et al. (2004):** Severe acute respiratory syndrome complicated by spontaneous pneumothorax. *Chest*, 125(6): 2345-51.
12. **Wali A, Rizzo V, Bille A et al. (2020):** Pneumomediastinum following intubation in COVID-19 patients: a case series. *Anaesthesia*, 75(8): 1076-81.
13. **Grasselli G, Cattaneo E, Florio G et al. (2021):** Mechanical ventilation parameters in critically ill COVID-19 patients: a scoping review. *Critical Care*, 25: 1-11.
14. **Al-Ani A, AbuZayda H, Ahmed H et al. (2022):** Limitation of tube thoracostomy in treating pneumothorax in COVID-19 infected patients. A retrospective cohort study. *Ann Med Surg.*, 80:104171. doi: 10.1016/j.amsu.2022.104171.
15. **McGuinness G, Zhan C, Rosenberg N et al. (2020):** Increased incidence of barotrauma in patients with COVID-19 on invasive mechanical ventilation. *Radiology*, 297(2): 252-62.
16. **Oyetunji T, Jackson H, Obirieze A et al. (2013):** Associated Injuries in Traumatic Sternal Fractures: A Review of the National Trauma Data Bank. *Am Surg.*, 79(7):702-5.
17. **Housman B, Jacobi A, Carollo A et al. (2020):** COVID-19 ventilator barotrauma management: less is more. *Ann Transl Med.*, 8(23): 1575. doi: 10.21037/atm-20-3907
18. **Wang X, Duan J, Han X et al. (2021):** High incidence and mortality of pneumothorax in critically ill patients with COVID-19. *Heart Lung*, 50(1): 37-43.
19. **Chopra A, Al-Tarbsheh A, Shah N et al. (2021):** Pneumothorax in critically ill patients with COVID-19 infection: Incidence, clinical characteristics and outcomes in a case control multicenter study. *Respir Med.*, 184:106464. doi: 10.1016/j.rmed.2021.106464.
20. **Tawil I, Gonda J, King R et al. (2010):** Impact of positive pressure ventilation on thoracostomy tube removal. *J Trauma Inj Infect Crit Care*, 68(4): 818-21.