



Predictors of postnatal surgical intervention for Antenatally detected Ureteropelvic Junction Obstruction

Tarek Ahmed Mahmoud^{1*} Esam El din Salem Morsy¹ * Hany Abd Elraoof Ali Morsy² * Abdelmoneim Mohammed Abouzeid¹

1. Department of Urology, Faculty of Medicine, Sohag University
2. Kasr Al Ainy Faculty of medicine, Cairo university

Abstract

Antenatal hydronephrosis is prenatal ultrasonography's most often detected urologic anomaly. Its etiology is quite variable ranging from mild abnormalities of the urinary system such as transient hydronephrosis to more significant ones such as ureteropelvic junction obstruction (UPJO) or high-grade vesicoureteral reflux (VUR). UPJO comprises the most encountered etiology of antenatal hydronephrosis with variable postnatal clinical scenarios ranging from complete resolution to the need for surgical intervention. The therapeutic approach for antenatal hydronephrosis caused by UPJO has undergone a dramatic shift from primary surgical intervention to initial conservation and elective surgery when indicated. Although there is a consensus that sustained increase in the grade of hydronephrosis, significant loss in differential renal function, and the existence of symptoms (such as recurrent UTI, nausea, vomiting, and cyclic flank pain) are reasonable indications of surgical need, precise cutoffs for the previous factors are still debated. This review aims to argue this debate and offer an overview of the antenatal and postnatal evaluation of antenatally detected ureteropelvic junction obstruction.

Keywords: Anteroposterior diameter, Differential renal function, Pyeloplasty

Abbreviations: ANH: antenatal hydronephrosis; APD: Anteroposterior diameter; CAP: continuous antibiotic prophylaxis; DFR: differential renal function; (MeSH): Medical Subject Headings; SFUG: Society for Fetal Urology Grade; UTD: Urinary Tract Dilation; UTI: urinary tract infection; UPJO: ureteropelvic junction obstruction; VUR: vesicoureteral reflux.

Introduction

UPJO is considered to be the most prevalent etiology of neonatal hydronephrosis⁽¹⁾. Its incidence is about 1:1500 with a male-to-female ratio of 2:1. A dramatic change has occurred in the management strategy of ANH caused by UPJO from operative intervention to initial follow-up and elective surgery when indicated because of the high likelihood of

spontaneous resolution⁽²⁾. Indications for intervention and its timing are still controversial, and a lack of agreement exists about the ability of different imaging modalities to detect obstruction precisely or to select patients who will need surgery⁽³⁾.

Variable indications for surgical intervention for UPJO have been reported in

the literature including 1) Increased APD and urinary tract dilatation on serial ultrasonography. 2) Unilateral UPJO with $< 40\%$ DFR on diuretic renograms or there is sequential loss in DFR $>10\%$. 3) Bilateral severe UPJO with cortical thinning or impairment of overall renal function. 4) Obstructive renographic curve with abdominal swelling or recurrent UTI. 5) Parental choice in those children who require prolonged follow-up with frequent imaging⁽⁴⁻⁶⁾.

A major challenge in managing those patients in clinical practice is to pick up patients who require early intervention to preserve their renal function, from those in whom conservation is suitable as spontaneous improvement will occur without any deterioration of their renal function⁽⁷⁾. The clinician's role is to counsel the parents and to determine in which cases obstruction will eventually lead to renal damage and, thus, pretend surgical need, or to know which cases to monitor more aggressively⁽⁴⁾. This review aims to discuss the debate about different surgical predictors and offer an overview of the antenatal and postnatal evaluation of antenatally detected UPJO.

Methods

This is a non-systematic review of the literature mainly focusing on antenatal hydronephrosis caused by Ureteropelvic Junction Obstruction and the controversies of its management. Healthcare Databases were used for searching (inception to March 2021). The search was done using Medical Subject Headings (MeSH) terms: "Antenatal hydronephrosis – Ureteropelvic junction obstruction - Anteroposterior diameter – Differential renal function – Pyeloplasty". Only articles in English were used.

Prenatal evaluation

Nowadays, ultrasonographic examination is routinely carried out during pregnancy. The average rate of examination is usually two for low-risk and four for high-risk patients⁽⁸⁾. An anteroposterior diameter (APD) value of ≤ 4 mm in the 2nd and ≤ 7 mm in the 3rd trimester are the most widely agreeable cut points for prenatal ultrasonography. In 1993, the Society of Fetal Urology (SFU) provided a simple grading system encompassing mild, moderate, and severe antenatal hydronephrosis depending on the APD measurement during the 2nd and 3rd trimesters (Table 1)⁽⁹⁾.

Table 1: Grading of ANH by APD correlated with gestational age:

Degree of Hydronephrosis	Anteroposterior Diameter (APD)	
	2 nd Trimester	3 rd Trimester
Mild	4 - < 7 mm	4 - < 9 mm
Moderate	7 - ≤ 10 mm	9 - ≤ 15 mm
Severe	>10 mm	>15 mm

A recent classification of antenatal urinary tract dilatation (UTD) has been published taking into consideration the degree of calyceal dilatation, renal parenchymal thickness and quality, bladder, and ureteral anomalies plus the value of APD (Table 2)⁽⁸⁾. The course of antenatally detected UTD is quite variable, it

can resolute before delivery, stay stable or progress. The probability of resolution is linked to the value of the APD at the 1st postnatal examination. Accordingly, follow-up ultrasonography during the 3rd trimester in patients with moderate to severe hydronephrosis is advised.

Table 2: Antenatal UTD classification system:

Ultrasound finding	Antenatal	
	UTD A1	UTD A2-3
APD	4 -< 7 mm (< 28 W) 7 - < 10 mm (≥ 28W)	≥ 7 mm (< 28 W) ≥ 10 mm (≥ 28W)
Calyceal dilatation		
Central	Yes or no	Yes
Peripheral	No	Yes
Parenchymal thickness	Normal	Abnormal
Parenchymal appearance	Normal	Abnormal
Ureter (s)	Normal	Abnormal
Bladder	Normal	Abnormal
Unexplained oligohydramnios	No	Yes

A strong correlation is usually present between progressive antenatal UTD and significant postnatal urologic anomalies⁽¹⁰⁾. Several authors have evaluated infants postnatally based on their antenatal ultrasonographic examinations. Coplen et al.⁽¹¹⁾ stated that when an APD value of 15 mm is taken as a cut point, it can correctly diagnose obstruction with specificity and sensitivity of 82% and 73%, respectively. Furthermore, it was noticed that the higher the value of the APD, the most probably it to be caused by an obstructive anomaly and the lower the rate of spontaneous resolution⁽¹²⁾. Also, a meta-analysis done by Lee et. al. revealed that the degree of UTD according to the SFU classification is consistent with urological anomalies, except for VUR⁽¹³⁾. Figure 1⁽¹⁴⁾ demonstrates a protocol for the management of ante-

natally diagnosed hydronephrosis. Accordingly, in patients with isolated unilateral hydronephrosis in the 2nd trimester, the ultrasonographic examination should be performed once more in the 3rd trimester; and if APD is > 15 mm, the postnatal ultrasonographic examination should be done within 3– 7 days after birth. If ANH is mild to moderate in the 3rd trimester, it is better to do a postnatal ultrasonographic examination one week postnatal. If the APD is < 7 mm, another examination with ultrasonography at age of 3 to 6 months is usually sufficient. In the case of bilateral hydronephrosis, the most critical point is the presence or absence of oligohydramnios. If no oligohydramnios is present, serial ultrasonographic examinations should be done every 2 to 6 weeks

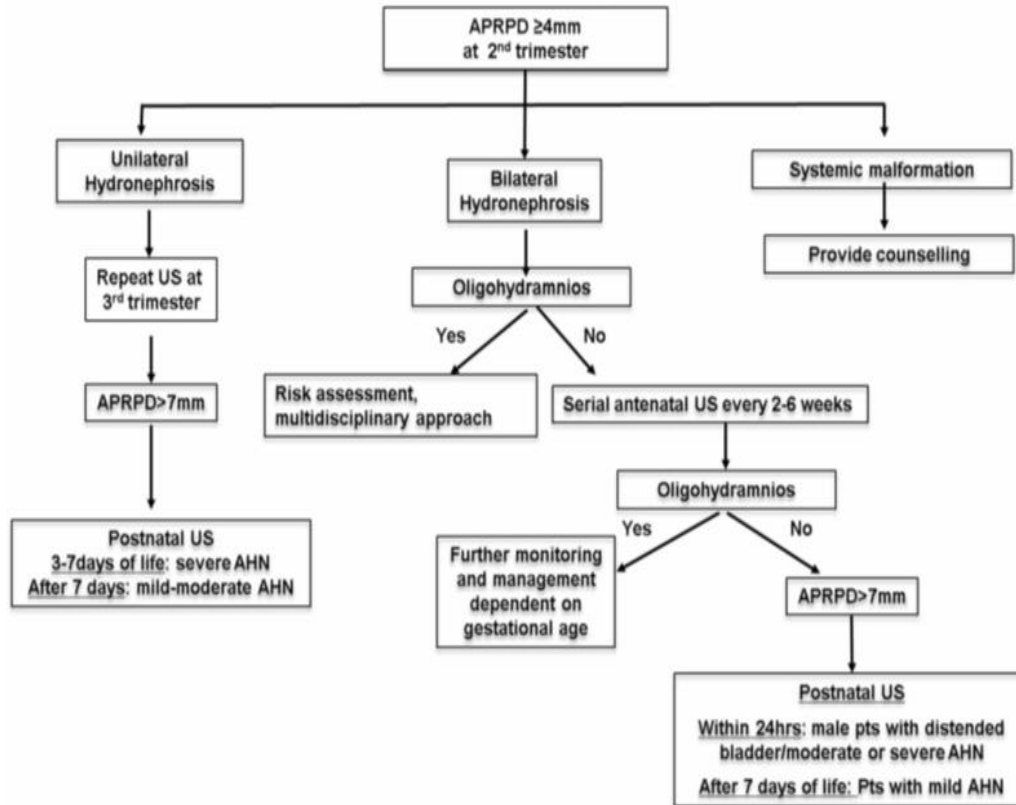


Figure 1: Evaluation of antenatal hydronephrosis

Postnatal evaluation

Ultrasonographic examination of the urinary system is the first standardized evaluation method for infants with antenatally detected hydronephrosis. It is a simple non-invasive method that can provide reliable data about the renal size, parenchyma, pelvicalyceal system dilatation, and lower tract anomalies if present. Several grading systems have been standardized for categorizing the UTD on postnatal ultrasonography. In 1978, a simple descriptive system that has categorized renal pelvicalyceal dilation into mild, moderate, and severe ⁽¹⁵⁾. In the

early 1990s, the SFU stated a semi-quantitative system (Figure 2) for ultrasonographic grading of hydronephrosis depending on the grade of pelvicalyceal dilatation and considering the quality of the renal parenchyma ⁽⁹⁾. Recently, a new multidisciplinary classification system that included multiple ultrasonographic parameters (Table 3) for grading UTD has been reported ^(8, 10). However, the application of these systems in clinical practice requires further validation in a large number of patients and training for both clinicians and radiologists.

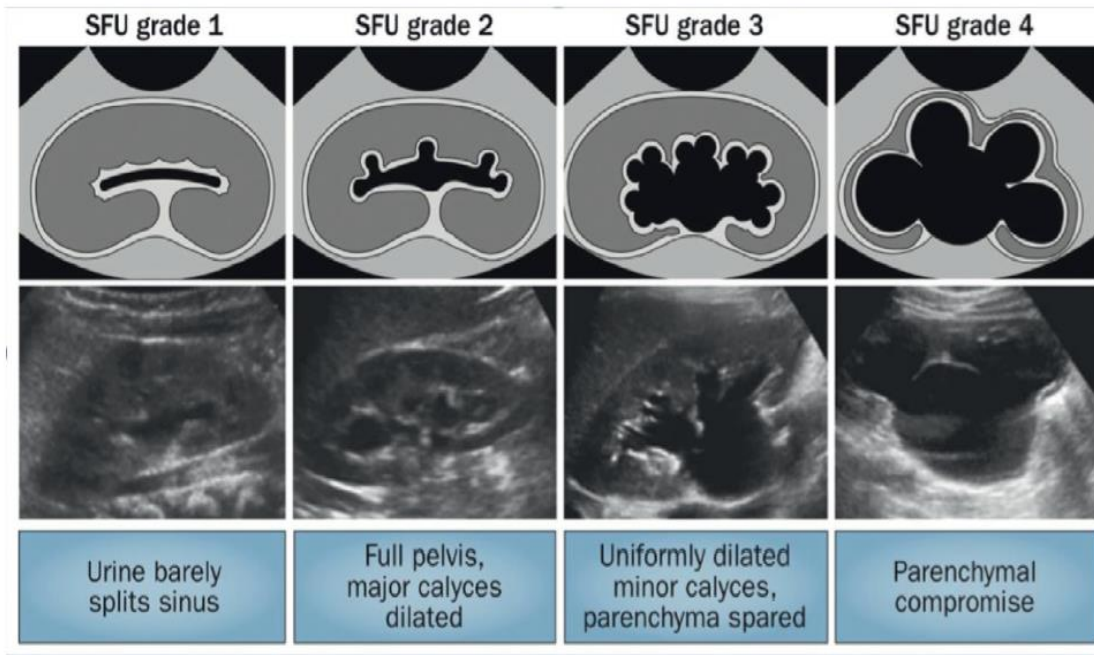


Figure 2: The Society for Fetal Urology (SFU) grading system.

Table 3: Postnatal UTD classification system:

Ultrasound finding	Postnatal (> 48 hours)		
	UTD P1	UTD P2	UTD P3
APD	10 -< 15 mm	≥ 15 mm	≥ 15 mm
Calyceal dilatation Central Peripheral	Yes	Yes	Yes
	No	Yes	Yes
Parenchymal thickness	Normal	Normal	Abnormal
Parenchymal appearance	Normal	Normal	Abnormal
Ureter (s)	Normal	Abnormal	Abnormal
Bladder	Normal	Normal	Abnormal

Documented prenatal ultrasonography is not available for all patients in current clinical practice. Parental history of prenatal urinary tract problems may be the only evidence, without any additional information. All patients with documented or history of ANH should be examined by ultrasonography after birth. However, a normal initial postnatal ultrasonographic examination may be fallacious. Aksu et al. ⁽¹⁶⁾ reported that 45% of the infants with a normal initial postnatal examination had an abnormal finding at follow-up ultrasonography.

Consequently, infants with ANH should have second postnatal ultrasonography to be done even if there was no abnormality in the first one. The ideal timing for the 1st ultrasonographic examination is after the 1st week of life to avoid the initial period of neonatal dehydration and 2nd one is usually preferred one month later ^(17, 18).

In addition to ultrasonography, the diuretic renogram is an integral part of the evaluation of infants diagnosed with UPJO. It is the most valuable technique that can determine the severity and func-

tional significance of obstruction⁽¹⁹⁾. It can provide quantitative data regarding differential renal function even in hydronephrotic renal units. It is better to be performed 6-8 weeks after birth allowing for sufficient renal maturation. In addition to the DRF, the diuretic renogram provides another advantage as a non-invasive method for the detection of obstruction depending on the T1/2 value⁽²⁰⁾ or the shape of the renographic curve. The idea of using certain urinary biomarkers that can detect obstruction and renal damage is appealing. In the last years, efforts were to evaluate certain biomarkers in infants with ANH, especially in UPJO. For example, the epidermal growth factor, monocyte chemotactic peptide, and transforming growth factor β 1. Urinary polypeptides were capable to pretend the clinical outcome in infants with UPJO⁽²¹⁾. Nowadays, the ideal role of these biomarkers in clinical practice has yet to be settled but shortly it may have a decisive role in the evaluation of those patients⁽²²⁾.

Discussion and Clinical Implications

Expectant management for antenatally diagnosed UPJO has been advocated by many authors⁽²³⁻²⁵⁾ and has become a standard at many centers. The main goal of follow-up in those patients is to avoid unnecessary surgeries with maintenance of their renal function. The argument for that is the high liability for spontaneous resolution in many cases. Most of this improvement is expected to happen in the 1st year after birth⁽²⁶⁾. On the other hand, the decisive problem with nonoperative management is to recognize infants in whom renal function will deteriorate if not managed surgically.

The decision to intervene while on conservative management also varied in different studies. In a study done by Onen, surgical intervention was advoca-

ted for progression of hydronephrosis, DFR loss, and a combination of both⁽⁵⁾. In another study, surgery was advocated for those who had; progression of hydronephrosis, a drop in the DFR > 10% in subsequent studies, or symptomatic cases such as febrile UTI⁽⁶⁾. The rate of surgical intervention also varied in different studies, some studies have reported a rate of intervention as low as 11.8% (5) 23% (4), and 24 % (6) others as high as 38 % (27), 48% (28) and 52 % (3).

The value of ultrasonography in identifying children at risk of surgery has been reported in many studies (8, 28-31). Hafez et al. stated that the progression of hydronephrosis on two sequential examinations is associated with renal function loss⁽²⁹⁾. Furthermore, Babu et al. stated that 80% of patients having antenatally diagnosed UPJO with SFUG 3-4 and obstructed renogram had renal function loss during follow-up (32). However, neither the SFU grade nor the APD is ideal for assessing the riskiness of hydronephrosis (30); especially in cases with intrarenal pelvis as in such situations, lower APD values are associated with higher parenchymal affection. The application of the UTD risk stratification system (8) can aid in making the decision easier, especially in low and high-risk groups. As the parenchymal quality (thickness and appearance) are taken into consideration this can provide a more realistic correlation between the anatomy and function.

The initial DFR has been utilized as an indicator for surgical intervention with different cutoff values, some have used a value of 35 %⁽⁴⁾, while others used a cutoff value of < 40 %^(3, 33). Also, a progressive decrease in the DRF has been used as an indicator for surgery. The cutoff ranged from > 5%⁽³⁾, to > 10%^(4, 6). However, the employment of a

diuretic renogram in assessing neonatal hydronephrosis is not without drawbacks. This is still a debatable issue as there are some drawbacks regarding renography in the assessment of renal obstruction in children. For instance, the lack of renal maturation in the 1st year of life, assessment of renal function during that period may be inaccurate⁽³⁴⁾. Also, in bilateral cases, the use of DRF as an indicator for an obstructive injury requires specification because there is no normal control renal unit⁽³⁰⁾

In a study done by Duong et. al.⁽³⁵⁾ comparing ultrasonographic parameters with diuretic renogram results for assessment of patients in whom diuretic renogram is borderline. They reported that a normal cortical thickness, APD < 30 mm, and calyceal dilatation of < 10 mm were more likely to be associated with a normal DFR and patent renal drainage. Accordingly, they recommended that only infants with APD > 30 mm major calyceal dilatation (> 10mm), and/or parenchymal thinning should have a diuretic renogram. Thus, it seems reasonable to follow infants with APD 20–30 mm closely and to perform a diuretic renogram on infants with APD > 30 mm.

Several authors have studied the relationship between different evaluation factors (e.g., APD, cortical thickness DFR, and UTI) and the need for surgical intervention. For instance, APD was found to be a significant predictor of surgical need in a univariate analysis done by Dias et al.,⁽³¹⁾. Also, Longpre et al., found that the initial APD was the only independent predictor of surgery⁽⁶⁾. Furthermore, urinary tract infections have been proposed as an indication for surgery in several studies^(6, 27, 32). In a multivariate analysis done by Arora et al., the only independent predictors for

surgical intervention were the initial APD and initial DRF. While Cortical thickness and SFU grade 4 hydronephrosis were not⁽⁴⁾. Regarding the APD value, different cutoff values have been used as predictors for surgery in the literature. Some authors have reported a low cutoff value of 16 mm⁽³¹⁾ and 20 mm⁽²⁸⁾. While others reported a slightly higher cutoff value of 24.3 mm.

Conclusion

No single approach is ideal for all patients. The approach of “surgery for all” can expose many children to unnecessary interventions. While the approach of “conservation for all” can result in irreversible renal function loss.

Initial conservative management can be safely offered for cases of antenatally diagnosed UPJO unless there is a prove of renal injury on initial assessment. For those patients who are on conservative management, meticulous follow-up is required to discover those who will develop an obstructive injury, with the initial APD and DFR being the most commonly used predictors for surgical intervention.

References

1. Lebowitz RL, Griscom NT. Neonatal hydronephrosis: 146 cases. *Radiol Clin North Am.* 1977;15(1):49-59.
2. Onen A, Jayanthi VR, Koff SA. Long-term follow-up of prenatally detected severe bilateral newborn hydronephrosis was initially managed nonoperatively. *J Urol.* 2002;168(3):1118-20.
3. Chertin B, Pollack A, Koulikov D, Rabinowitz R, Hain D, Hadas-Halpren I, et al. Conservative treatment of ureteropelvic junction obstruction in children with antenatal diagnosis of hydronephrosis: lessons learned after 16 years of follow-up. *Eur Urol.* 2006;49(4):734-8.

4. Arora S, Yadav P, Kumar M, Singh SK, Sureka SK, Mittal V, et al. Predictors for the need of surgery in antenatally detected hydronephrosis due to UPJ obstruction--a prospective multivariate analysis. *J Pediatr Urol.* 2015;11(5):248 e1-5.
5. Onen A. Treatment and outcome of prenatally detected newborn hydronephrosis. *J Pediatr Urol.* 2007;3(6):469-76.
6. Longpre M, Nguan A, Macneily AE, Afshar K. Prediction of the outcome of antenatally diagnosed hydronephrosis: a multivariable analysis. *J Pediatr Urol.* 2012;8(2):135-9.
7. Madsen MG, Norregaard R, Frokiaer J, Jorgensen TM. Urinary biomarkers in prenatally diagnosed unilateral hydronephrosis. *J Pediatr Urol.* 2011;7(2):105-12.
8. Nguyen HT, Benson CB, Bromley B, Campbell JB, Chow J, Coleman B, et al. Multidisciplinary consensus on the classification of prenatal and postnatal urinary tract dilation (UTD classification system). *J Pediatr Urol.* 2014;10(6):982-98.
9. Fernbach SK, Maizels M, Conway JJ. Ultrasound grading of hydronephrosis: introduction to the system used by the Society for Fetal Urology. *Pediatr Radiol.* 1993;23(6):478-80.
10. Nguyen HT, Herndon CD, Cooper C, Gatti J, Kirsch A, Kokorowski P, et al. The Society for Fetal Urology consensus statement on the evaluation and management of antenatal hydronephrosis. *J Pediatr Urol.* 2010;6(3):212-31.
11. Coplen DE, Austin PF, Yan Y, Blanco VM, Dicke JM. The magnitude of fetal renal pelvic dilatation can identify obstructive postnatal hydronephrosis, and direct postnatal evaluation and management. *J Urol.* 2006;176(2):724-7; discussion 7.
12. Kaspar CDW, Lo M, Bunchman TE, Xiao N. The antenatal urinary tract dilation classification system accurately predicts the severity of kidney and urinary tract abnormalities. *J Pediatr Urol.* 2017;13(5):485 e1- e7.
13. Lee RS, Cendron M, Kinnamon DD, Nguyen HT. Antenatal hydronephrosis as a predictor of postnatal outcome: a meta-analysis. *Pediatrics.* 2006;118(2):586-93.
14. Gyanendra Sharma AS. Postnatal management of antenatally detected hydronephrosis. *World J Clin Urol* 2014;283-94.
15. Ellenbogen PH, Scheible FW, Talner LB, Leopold GR. Sensitivity of grayscale ultrasound in detecting urinary tract obstruction. *AJR Am J Roentgenol.* 1978;130(4):731-3.
16. Aksu N, Yavascan O, Kangin M, Kara OD, Aydin Y, Erdogan H, et al. Postnatal management of infants with antenatally detected hydronephrosis. *Pediatr Nephrol.* 2005;20(9):1253-9.
17. Signorelli M, Cerri V, Taddei F, Groli C, Bianchi UA. Prenatal diagnosis and management of mild fetal pyelectasis: implications for neonatal outcome and follow-up. *Eur J Obstet Gynecol Reprod Biol.* 2005;118(2):154-9.
18. Timberlake MD, Herndon CD. Mild to moderate postnatal hydronephrosis--grading systems and management. *Nat Rev Urol.* 2013;10(11):649-56.
19. Boubaker A, Prior JO, Meyrat B, Bischof Delaloye A, McAleer IM, Frey P. Unilateral ureteropelvic junction obstruction in children: long-term follow-up after unilateral pyeloplasty. *J Urol.* 2003;170(2 Pt 1):575-9; discussion 9.
20. Ulman I, Jayanthi VR, Koff SA. The long-term follow-up of newborns with severe unilateral hydronephrosis was initially treated nonoperatively. *J Urol.* 2000;164(3 Pt 2):1101-5.

21. Decramer S, Wittke S, Mischak H, Zurbig P, Walden M, Bouissou F, et al. Predicting the clinical outcome of congenital unilateral ureteropelvic junction obstruction in newborn by urinary proteome analysis. *Nat Med.* 2006;12(4):398-400.
22. Papachristou F, Pavlaki A, Printza N. Urinary and serum biomarkers in ureteropelvic junction obstruction: a systematic review. *Biomarkers.* 2014;19(7):531-40.
23. Koff SA, Campbell KD. The nonoperative management of unilateral neonatal hydronephrosis: a natural history of poorly functioning kidneys. *J Urol.* 1994;152(2 Pt 2):593-5.
24. Chiodini B, Ghassemi M, Khelif K, Ismaili K. Clinical Outcome of Children With Antenatally Diagnosed Hydronephrosis. *Front Pediatr.* 2019;7:103.
25. Arnold AJ, Rickwood AM. Natural history of pelviureteric obstruction detected by prenatal sonography. *Br J Urol.* 1990;65(1):91-6.
26. Elmaci AM, Donmez MI. Time to resolution of isolated antenatal hydronephrosis with anteroposterior diameter \leq 20 mm. *Eur J Pediatr.* 2019;178(6):823-8.
27. Duong HP, Piepsz A, Collier F, Khelif K, Christophe C, Cassart M, et al. Predicting the clinical outcome of antenatally detected unilateral pelviureteric junction stenosis. *Urology.* 2013;82(3):691-6.
28. Killi I, Avlan D, Taskinlar H, Kara PP, Apaydin FD, Delibas A, et al. Effective predictors for surgical decision in antenatal hydronephrosis: a prospective multiparameter analysis. *Turk J Urol.* 2017;43(3):361-5.
29. Hafez AT, McLorie G, Bagli D, Khoury A. Analysis of trends on serial ultrasound for high-grade neonatal hydronephrosis. *J Urol.* 2002;168(4 Pt 1):1518-21.
30. Onen A. An alternative grading system to refine the criteria for severity of hydronephrosis and optimal treatment guidelines in neonates with primary UPJ-type hydronephrosis. *J Pediatr Urol.* 2007;3(3):200-5.
31. Dias CS, Silva JM, Pereira AK, Marino VS, Silva LA, Coelho AM, et al. Diagnostic accuracy of renal pelvic dilatation for detecting surgically managed ureteropelvic junction obstruction. *J Urol.* 2013;190(2):661-6.
32. Babu R, Rathish VR, Sai V. Functional outcomes of early versus delayed pyeloplasty in prenatally diagnosed pelvi-ureteric junction obstruction. *J Pediatr Urol.* 2015;11(2):63 e1-5.
33. Shokeir AA, El-Sherbiny MT, Gad HM, Dawaba M, Hafez AT, Taha MA, et al. Postnatal unilateral pelviureteral junction obstruction: impact of pyeloplasty and conservative management on renal function. *Urology.* 2005;65(5):980-5; discussion 5.
34. Lythgoe MF, Gordon I, Anderson PJ. Effect of renal maturation on the clearance of technetium-99m mercaptoacetyl triglycine. *Eur J Nucl Med.* 1994;21(12):1333-7.
35. Duong HP, Piepsz A, Khelif K, Collier F, de Man K, Damry N, et al. Transverse comparisons between ultrasound and radionuclide parameters in children with presumed antenatally detected pelvi-ureteric junction obstruction. *Eur J Nucl Med Mol Imaging.* 2015;42(6):940-6.