

Original article

**Adult Sex Identification from Sacral and Coccygeal Measurements
in Egyptian Sample Using Multi Detector Computed Tomography****Reham M. Shalaby¹, Shaimaa A. Shehata^{1*}, Walid Mosallam², Rehab I. Abdel-Karim¹**¹ Department of Forensic Medicine and Clinical Toxicology, Faculty of Medicine, Suez Canal University, 41522, Egypt, ² Department of Radio-diagnosis, Faculty of Medicine, Suez Canal University, Ismailia, 41522, Egypt.***Corresponding author**

Shaimaa A. Shehata, M.D.

E mail:

shaimaa_shehata@med.suez.edu.eg

dr_shaimaa84@yahoo.com

ORCID: 0000-0002-2810-3613**ABSTRACT**

Introduction Identification of sex is fundamental to identify unknown individuals. In situations where the body is fragmented or mutilated, sex can be estimated through examination of the sexually dimorphic characteristics of skeletal parts. The pelvic bones, particularly the sacrum and coccyx have been investigated and found characterized for sexual dimorphism. They were considered as an accurate tool to determine adult sex in some populations. **Aim:** to get an accurate method for adult sex determination among Egyptian population. **Objectives:** to identify sacral and coccygeal osteometric differences between sexes using Multi Detector Computed Tomography (MDCT) images in a sample of Egyptians. Furthermore, to set up a formula for sex identification from sacrococcygeal measurements in a sample of Egyptians. **Subjects and methods:** A cross-sectional comparative study was conducted on 220 Egyptian subjects (110 males and 110 females) who underwent pelviabdominal CT at Diagnostic Radiology Department, Suez Canal University Teaching Hospitals. Ten measurements of the sacrum and coccyx for each participant were obtained and assessed for sexual dimorphism. **Results:** All measurements were significantly larger for males except for the maximum breadth of alae of the sacrum (MBA) and the sacrococcygeal curve angle (SCCA). Antero-posterior diameter of the first sacral vertebra (APD) followed by anterior sacrococcygeal length (ASCL) provided accuracy for sex discrimination of 74.55% and 72.73% respectively using receiver operating characteristics (ROC) analysis. The Binary logistic regression (BLR) model correctly classified 87.3% of males and 85.5% of females, with an overall classification accuracy of 86.4%. The regression formula had a sensitivity of 83.6%, specificity of 82.7% and accuracy of 83.6%. **Conclusion:** sacrococcygeal parameters showed significant differences between males and females and could be useful for sex identification in forensic cases.

Keywords: sacrum, coccyx, forensic, anthropology, Binary Logistic Regression, identification

I. INTRODUCTION:

Sex identification is a very important step for establishing personal identity (Bakici et al., 2021). It rules out a large proportion of possible identifications (Austin and King, 2016). However, it represents a major problem when the body is putrefied, mutilated or fragmented (Akhlaghi et al., 2016). In such situations, sex can be estimated through examination of the sexually dimorphic characteristics of skeletal size and shape through metric and morphological methods (Austin and King, 2016; Krishan et al., 2016).

Although molecular methods are more accurate for sex identification than the former two methods, they have certain limitations such as DNA inhibition, degradation, and contamination, along with the higher cost and labor intensiveness (Cafiero et al., 2019). The major obstacle of morphologic methods is their subjectivity, need for an experienced examiner and lack of statistical analysis (Krishan et al., 2016). Metric methods are more objective and depend on sexual dimorphism of measured parameters. They use different statistical methods to produce formulae that can be used for sex estimation (Krishan et al., 2016). However, those formulae are considered population specific as several factors affect osteometric sexual dimorphism. These factors include genetic variations as well as environment and professional variations and even variations in lifestyle (Bakici et al., 2021). Among the skeletal parts, the pelvis provides the most accurate sex estimation structure (Steyn and İşcan, 2008; Naksuwan et al., 2021).

The sacrum is considered valuable for identifying sex due to the structural differences in pelvis between both sexes to accommodate for childbearing (Torimitsu et al., 2017). The human sacrum is a large triangular bone fusion of five vertebrae that forms the postero-superior wall of the pelvic cavity, wedged between the two hip bones (Kalsey et al., 2011). The coccyx is a small triangular bone located at the bottom of the vertebral column. It is formed of three to five (usually four) fused rudimentary vertebrae (Kayalioglu, 2009).

Some researchers have investigated sexual dimorphism of the sacrum and coccyx (Zhan et al., 2018 ; Etlı et al., 2019; Abdelsamiee et al., 2021; Naksuwan et al., 2021). However, search in the literature revealed a study that investigated the use of sacral and coccygeal measurements for sex identification in Egyptian population using magnetic resonance imaging technique (Elkhateeb et al., 2021). In Egypt, there is diversity among Egyptian population (AbdEl-Hafez et al., 2019). This indicates the need for further studies to assess sex identification from sacrum and coccyx according to the Egyptian population. The use of various imaging modalities is becoming progressively popular in forensic anthropology (Krishan et al., 2016). Computed tomography (CT) is an important imaging modality that provides unique data sources for examining human variations in a quantitative and non-invasive manner. Its speed in addition to its ability to capture high details of bone make it an ideal tool to save time, and to protect skeletal remains from physical manipulation (Decker et al., 2011). Moreover, records could be obtained for both living and dead individuals

(Kumar et al., 2015). Therefore, the current study aimed to get an accurate method for adult sex determination among Egyptian population. The objectives of the study were as follows: To identify sacral and coccygeal osteometric differences between sexes using MDCT images in a sample of Egyptians. Furthermore, to set up a formula for sex identification from sacrococcygeal measurements in a sample of Egyptians.

II. SUBJECTS AND METHODS:

This is a cross sectional comparative study that was conducted at the Diagnostic Radiology Department, Suez Canal University Hospital, Ismailia, Egypt.

II.1 Subjects:

Two hundred, twenty-two Egyptian subjects (110 males and 110 females) were enrolled in the study. Inclusion criteria: Males and non-pregnant females from Suez Canal Region who were referred to the Diagnostic Radiology Department at Suez Canal University Hospital to undergo pelviabdominal MDCT for diagnostic purposes. Their age started from 21 up to 70 years. In an attempt to equalize the research subjects regarding age and sex, stratified random sampling technique was performed, dividing the subjects into five equal age groups starting from 21 up to 70 years, with 22 males and 22 females included in each age group. Exclusion criteria: individuals with history or radiological evidence of conditions that would affect the dimensions of sacrum and coccyx. Those conditions included fractures (old or new), deformities, malignancy, severe inflammatory conditions or surgical operations in the pelvic region,

sacrum and coccyx, metabolic or endocrine bone diseases, and sacra that showed pathological fusions.

II.2 Image acquisition and processing:

The pelvi-abdominal MDCT images were obtained using Toshiba activation 16 multi-slice machine on a device of model number TSX-031A 2012 with standard accessories (Toshiba Medical Systems, made in Japan). Sacral and coccygeal osteometric parameters were measured using MDCT imaging without contrast according to the following procedures: The body was scanned in cranio-caudal direction, starting from 1 cm superior to diaphragm to lesser trochanters, with slice thickness = 1 mm, tube voltage of 120 kVp and tube current of 80–100 mAs. The obtained axial images were exported in the form of Digital Imaging and Communication in Medicine (DICOM) images to the CT workstation for processing. Axial images were re-formatted into sagittal images, afterthought, were used for the radiographic assessment of the anterior and posterior borders of the sacrum and coccyx. Ten sacrococcygeal parameters were measured for both sexes (five length measurements and two angles in sagittal plane, and three diameter measurements in axial plane). For lengths and diameters, measurements were recorded in centimeters, while for angles, measurements were recorded in degrees.

II.3 Sacrococcygeal parameters:

The eligible films were examined, and the radiometric parameters of the sacrum and coccyx were as follows:

A. lengths (in sagittal plane):

-Anterior sacral length (ASL): Linear distance that joins 1st sacral vertebra (S1)

antero-superior edge to 5th sacral vertebra (S5) antero-inferior edge (Fig. 1a) (Torimitsu et al., 2017).

-Posterior sacral length (PSL): Linear distance that joins S1 postero-superior edge to S5 antero-inferior edge (Fig. 1a) (Torimitsu et al., 2017).

-Anterior sacrococcygeal length (ASCL): Linear distance that joins S1 antero-superior edge to last coccygeal vertebra (LCV) antero-inferior edge (Fig. 1b) (Torimitsu et al., 2017).

-Posterior sacrococcygeal length (PSCL): Linear distance that joins S1 postero-superior edge to LCV antero-inferior edge (Fig. 1b) (Torimitsu et al., 2017).

-Sacral curve length (SCL): The length of the curve starting from mid-point of antero-superior margin of sacral promontory to the mid-point of antero-inferior margin of S5 (Fig. 1c) (Zhan et al., 2018).

B. Angels (in sagittal plane) according to (Etlı et al., 2019):

-Sacral curve angle (SCA): the angle between superior line of S1 corpus and inferior line of S5 corpus (Fig. 1d).

-Sacrococcygeal curve angle (SCCA): the angle between superior line of S1 corpus and the line of last inter-coccygeal joint (Fig. 1e).

C. Diameters (in axial plane) according to (Torimitsu et al., 2017):

-Maximum anterior-posterior diameter (APD): Linear distance that joins the most anterior to the most posterior points on S1 body (Fig. 1f).

-Maximum transverse diameter (MTD): Linear distance that joins the two most laterally projecting points on S1 body (Fig. 1f).

-Maximum breadth of sacral alae (MBA): Maximum transverse distance joins the two most lateral parts of alae of the sacrum together (Fig. 1f).

In order to avoid inter-observer bias, one observer obtained all readings. Moreover, to avoid intra-observer bias, 20 randomly selected MDCT images of both sexes were examined twice (two weeks apart) by the same observer.

II.4 Statistical analysis:

Data were entered into Microsoft Excel (Microsoft Office 365 Software Bundle of Microsoft Corporation, USA). Then they were analyzed using Statistical Package for Social Sciences (SPSS) version 25 (IBM Corporation, Chicago, USA). Test of normality (Kolmogorov–Smirnov test) was done to determine data distribution. For assessment of intra-observer reliability, Intraclass Correlation Coefficient (ICC) test was done, and was considered accurate at level >0.75 (Koo and Li, 2016). Data were tabulated in the form of mean and standard deviation (SD). Difference between the means of males and females' measurements was calculated using student t-test for parametric variables, while Mann-Whitney U test was used for non-parametric variables. Sex prediction from the measured sacrococcygeal parameters was done using the receiver operating characteristics (ROC) curve. Binary logistic regression (BLR) analysis was used to produce a model for sex prediction. The sensitivity, specificity and accuracy were calculated for the resultant BLR formula using ROC curve. Data were considered statistically significant at p value <0.05. Figure 2 summarized the graphical methodology for the study.

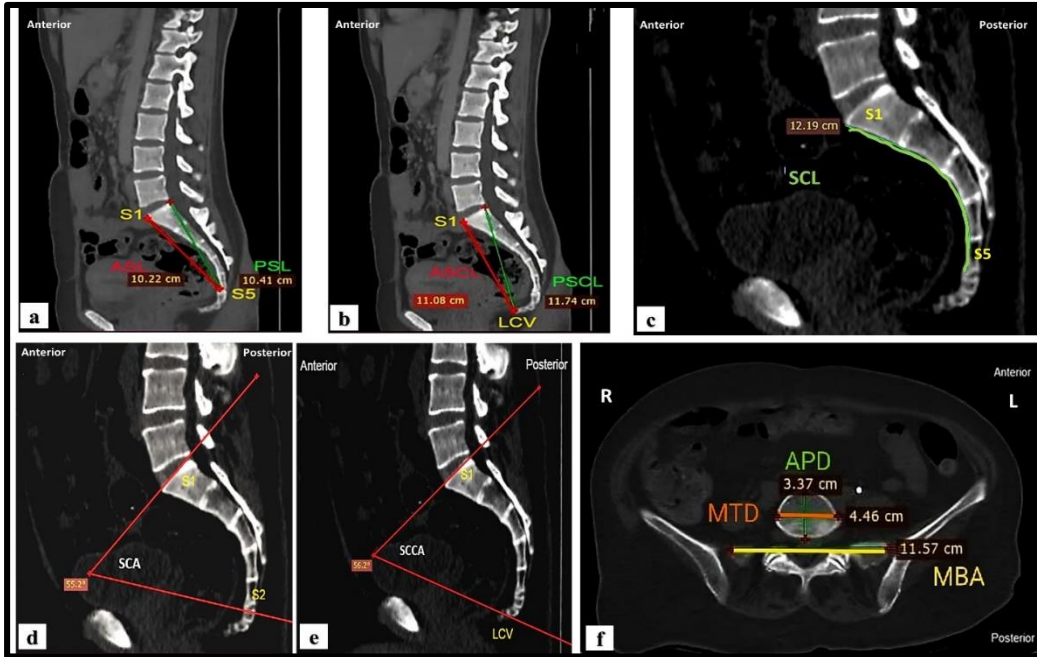


Figure 1: Multi-Detector Computed Tomography images for sacrococcygeal measurements used in the study. (a & b). Linear measurements of sacrum and coccyx in sagittal plane: **ASL**: anterior sacral length, **PSL**: posterior sacral length, **ASCL**: anterior sacrococcygeal length, **PSCL**: posterior sacrococcygeal length, **S1**: first sacral vertebra, **S5**: fifth sacral vertebra & **LCV**: last coccygeal vertebra. (c). curved measurement of the sacrum in sagittal plane: **SCL**: Sacral curve length, **S1** & **S5**. (d). Sacral curve angle measurement in sagittal plane: **SCA**: Sacral curve angle, **S1** & **S5**. (e). Sacrococcygeal curve angle measurement in sagittal plane: **SCCA**: Sacrococcygeal curve angle, **S1**, **S5** & **LCV**. (f). Linear measurements of the sacral base in axial plane: **MTD**: Maximum transverse diameter of S1, **APD**: anteroposterior diameter of S1 and **MBA**: Maximum breadth of sacral alae.

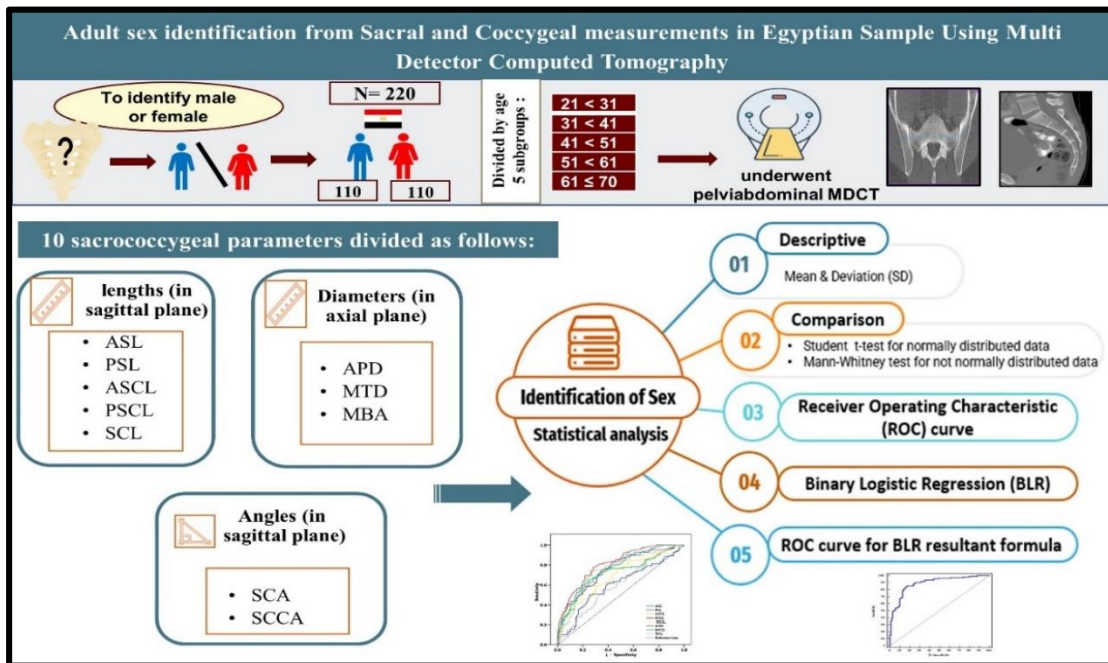


Figure 2: Graphical methodology of the study.

II.5 Ethical considerations:

Prior to the study, approval for conducting the study was obtained from Research Ethics Committee (REC), Faculty of Medicine, Suez Canal University, Ismailia, Egypt (Reference number: 4628#). Written informed consent was obtained from all study participants. Participants' privacy as well as confidentiality of their data were protected.

III. RESULTS

The reliability coefficient for intra-observer reliability ranged from 0.812 to 0.999 (good to excellent), which is considered an acceptable level intra-observer error.

The study included 110 males (age: 21-69 years) and 110 females (age: 21-68 years). Table 1 shows descriptive statistics and comparison of the radiometric parameters. ASL, PSL, ASCL, SCL, APD, MTD, MBA and SCCA were normally distributed variables, while PSCL and SCA were abnormally distributed. PSL, ASCL, PSCL, SCL, APD, and MTD showed high statistically significant difference between both sexes ($p < 0.001$), whereas ASL and SCA showed statistically significant differences ($p < 0.05$). However, MBA and SCCA did not significantly differ between both sexes ($p > 0.05$). All measured parameters were larger in males except for MBA.

ROC curve analysis demonstrated the area under curve (AUC), best cut-off point values, sensitivity, specificity, and accuracy for the eight significant measurements (ASL, PSL, ASCL, PSCL, SCL, APD, MTD and SCA) (table 2 and figure 3). The cut-off point value for each measurement is the value above which sex is considered as a male and the

value that equals or below which sex is considered as a female. AUC measures the ability of the tested parameter to discriminate between two groups correctly. The eight tested parameters had high diagnostic value in sex determination ($0.5 < \text{AUC} < 1.0$). It was observed that APD had the highest accuracy (74.55%), followed with ASCL (72.73%), MTD (70.46%) and PSCL (70.00%).

Binary logistic regression analysis was done using the eight significant measurements to develop the logistic regression formula for sex identification. Table (3) shows the results of simple logistic regression analysis of the sacrococcygeal variables; the regression Beta coefficient (β), the p-value based on Wald statistic to test the significance of individual logistic regression coefficients for each independent variable and the odds ratio (OR) for each variable. Each of the eight parameters had a statistically significant value when applied individually in a regression model. On entering the variables into a backward stepwise regression, only PSCL, SCL, APD, MTD and SCA were selected in the analysis as APD and MTD were highly statistically significant ($p < 0.01$), and PSCL, SCL and SCA were statistically significant ($p < 0.05$) (table 4). The resultant BLR model was significant with classification accuracy of 86.4% (85.5% for females and 87.3% for males) (table 5).

The previous five parameters (PSCL, SCL, APD, MTD and SCA) were used in the resultant equation constructed according to the study population's recruited data. It is presented as follows:

$$P(\text{sex}) = \frac{1}{1 + e^{(0.627(\text{PSCL}) + 0.613(\text{SCL}) + 2.712(\text{APD}) + 1.935(\text{MTD}) + 0.120(\text{SCA}) - 42.837)}}$$

Where if the calculated result is ≥ 0.5 , the predicted sex will be most probably a male. If the calculated result is < 0.5 , then the sex predicted by the equation will be most probably a female.

The diagnostic accuracy of the resultant formula from BLR model was further analyzed using ROC curve. The formula was significant with a sensitivity of 83.6%, specificity of 82.7% and accuracy of 83.6% at a cut-off point 0.5 (table 6 and figure 4).

Table (1) Descriptive statistics and comparison of sacrococcygeal radiometric parameters for both sexes among Egyptian population (N=220).

Variables	Male (n=110)	Female (n=110)	p-value
	Mean \pm SD	Mean \pm SD	
ASL (cm)	10.68 \pm 0.86	10.42 \pm 0.79	0.021 †*
PSL (cm)	11.17 \pm 0.89	10.57 \pm 0.71	<0.001 †**
ASCL (cm)	12.47 \pm 1.05	11.58 \pm 1.06	<0.001 †**
PSCL (cm)	13.33 \pm 1.11	12.3 \pm 0.88	<0.001 ¶**
SCL (cm)	11.94 \pm 0.82	11.33 \pm 0.66	<0.001 †**
APD (cm)	4.08 \pm 0.28	3.7 \pm 0.32	<0.001 †**
MTD (cm)	5.43 \pm 0.51	4.85 \pm 0.49	<0.001 †**
MBA (cm)	10.97 \pm 0.55	11.1 \pm 0.53	0.081 †
SCA (degree)	61.18 \pm 4.26	59.48 \pm 4.92	0.012 ¶*
SCCA (degree)	74.57 \pm 6.00	73.22 \pm 7.16	0.131 †

N: total number, n: number of each group, SD: standard deviation, *: statistically significant ($p < 0.05$), **: high statistical significant ($p < 0.001$), † student's t-test, ¶ Mann Whitney test, ASL: anterior sacral length, PSL: posterior sacral length, ASCL: anterior sacrococcygeal length, PSCL: posterior sacrococcygeal length, SCL: sacral curve length, SCA: sacral curve angle, SCCA: sacrococcygeal curve angle, APD: antero-posterior diameter of 1st sacral vertebra (S1), MTD: maximum transverse diameter of 1st sacral vertebra, MBA: maximum breadth of sacral alae.

Table 2: Receiver operating characteristics analysis results of sacrococcygeal parameters for sex prediction among Egyptian population (N=220).

Variables	AUC	Standard error	p-value	Cut-off # (cm & degree)	Sensitivity (%)	Specificity (%)	Accuracy (%)
ASL (cm)	0.601	0.038	0.009*	10.8	50.0	74.55	62.28
PSL (cm)	0.712	0.035	<0.001**	10.82	69.09	69.09	69.09
ASCL (cm)	0.744	0.034	<0.001**	11.96	73.64	71.82	72.73
PSCL (cm)	0.756	0.032	<0.001**	12.56	74.55	65.45	70.0
SCL (cm)	0.693	0.035	<0.001**	11.5	77.27	51.82	64.55
APD (cm)	0.809	0.028	<0.001**	3.86	77.27	71.82	74.55
MTD (cm)	0.765	0.031	<0.001**	5.27	60.0	80.91	70.46
SCA (degree)	0.602	0.038	0.009*	62.04	50.0	68.18	59.09

N: total number, #: sex is male if value > cut off point and female if value ≤ cut off point. *: Statistically significant (p<0.05), **: High statistically significant (p<0.001), AUC: area under the curve, **ASL**: anterior sacral length, **PSL**: posterior sacral length, **ASCL**: anterior sacrococcygeal length, **PSCL**: posterior sacrococcygeal length, **SCL**: sacral curve length, **APD**: antero-posterior diameter 1st sacral vertebra (S1), **MTD**: maximum transverse diameter of 1ST sacral vertebra and **SCA**: sacral curve angle.

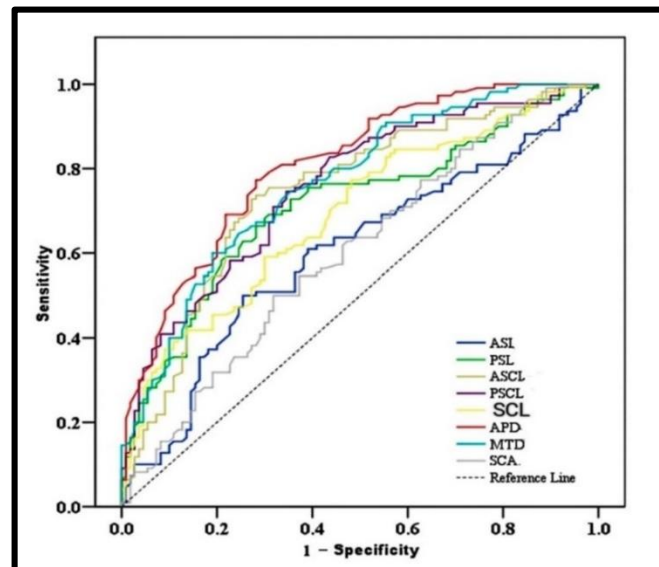


Figure (3) Receiver operating characteristics curve for sex predicted probabilities of sacrococcygeal parameters among Egyptian population (N=220). N: total number, ASL: anterior sacral length, PSL: posterior sacral length, ASCL: anterior sacrococcygeal length, PSCL: posterior sacrococcygeal length, SCL: sacral curve length, APD: antero-posterior diameter of 1st sacral vertebra, MTD: maximum transverse diameter of 1st sacral vertebra and SCA: sacral curve angle.

Table 3: Simple logistic regression analysis of the sacrococcygeal parameters in sex prediction among Egyptian population (N=220).

Model	Variable	β	p-value	Odds ratio	95% CI
1	ASL (cm)	0.383	0.023*	1.466	1.055 - 2.038
2	PSL (cm)	0.925	<0.001**	2.521	1.738 - 3.658
3	ASCL (cm)	0.805	<0.001**	2.237	1.666 - 3.003
4	PSCL (cm)	1.039	<0.001**	2.827	2.024 - 3.949
5	SCL (cm)	1.129	<0.001**	3.093	2.02 - 4.736
6	APD (cm)	4.081	<0.001**	59.227	18.157 - 193.189
7	MTD (cm)	2.419	<0.001**	11.231	5.454 - 23.126
8	SCA (degree)	0.08	0.008*	1.084	1.021 - 1.15

N: total number, β : Beta coefficient, CI: confidence interval, *: Statistically significant ($p < 0.05$); **: Highly statistically significant ($p < 0.001$) ASL: anterior sacral length, PSL: posterior sacral length, ASCL: anterior sacrococcygeal length, PSCL: posterior sacrococcygeal length, SCL: sacral curve length, APD: antero-posterior diameter of 1st sacral vertebra, MTD: maximum transverse diameter of 1st sacral vertebra and SCA: sacral curve angle.

Table 4: Best-fit multiple logistic regression analysis of the sacrococcygeal parameters in sex prediction among Egyptian population (N=220).

Variable	β	p-value	Odds ratio	95% CI
PSCL (cm)	0.627	0.003*	1.872	1.244 - 2.816
SCL (cm)	0.613	0.021*	1.845	1.097 - 3.102
APD (cm)	2.712	<0.001**	15.067	3.627 - 62.585
MTD (cm)	1.935	<0.001**	6.926	2.865 - 16.744
SCA (degree)	0.12	0.007*	1.127	1.033 - 1.23
Constant	42.837	<0.001**	0	-

N: total number, β : Beta coefficient, CI: confidence interval, *: Statistically significant ($p < 0.05$) **: Highly statistically significant ($p < 0.001$), PSCL: posterior sacrococcygeal length, SCL: sacral curve length, APD: antero-posterior diameter of first sacral vertebra, MTD: maximum transverse diameter of first sacral vertebra and SCA: sacral curve angle.

Table 5: Accuracy of Binary Logistic Regression model using sacrococcygeal parameters analysis in sex prediction among Egyptian population (N=220).

Observed		Predicted		
		Sex		Percentage correct (%)
		Female	Male	
Sex	Female(n=110)	94	16	85.5
	Male (n=110)	14	96	87.3
Overall percentage				86.4

N: total number, n: total number of each group

Table 6: Receiver Operating Characteristics ROC analysis of resultant binary logistic regression formula for sex prediction from sacrococcygeal parameters among Egyptian population (N=220).

Statistic	AUC	Standard error	p-value	Cut-off	Sensitivity	Specificity	Accuracy
	0.892	0.02	<0.001**	0.5	83.6	82.7	83.64

ROC: Receiver operating characteristics; AUC: Area under the curve; **: Highly statistically significant ($p < 0.001$)

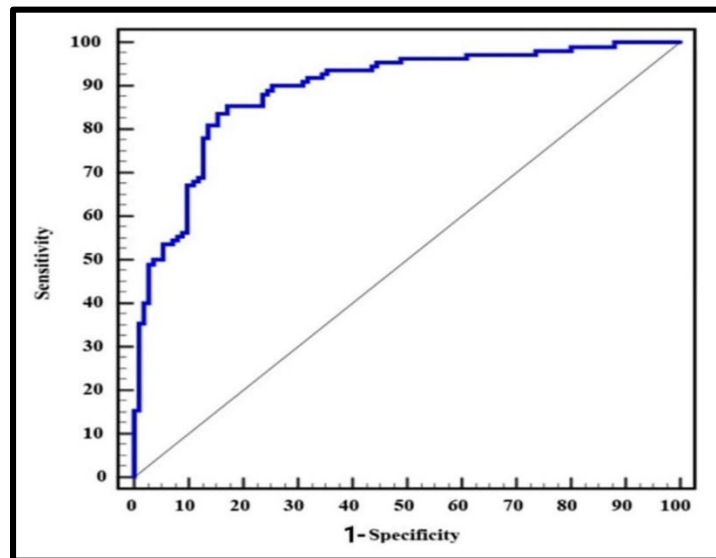


Figure (4): Receiver Operating Characteristics curve for the resultant logistic regression formula for sex prediction from sacrococcygeal parameters among Egyptian population (N=220).

IV. DISCUSSION

The determination of biological sex from skeletal remnants is a cornerstone of human identification in forensic science (Kumar et al., 2015; Ubelaker and DeGaglia, 2017). Sexual dimorphism of pelvic bones is well established in literature (Wagh, 2015; Spradley, 2016). In the same context, sacrum and coccyx are characterized by exhibiting apparent sexual dimorphism in order to accommodate physiologically reproductive function in childbearing among females (Wagh, 2015). It is known that metric approaches, as opposed to morphological ones, offer a higher level of reliability (Bakici et al., 2021). MDCT technique is considered a noninvasive, quick, accurate effective, available and reliable method for determining sex (Ubelaker and DeGaglia, 2017), moreover, records could be obtained for both living and dead individuals (Kumar et al., 2015). Therefore, the current study analyzed ten sacrococcygeal parameters to identify sex in Egyptian sample using MDCT.

The present study results revealed that ASL, PSL, ASCL, PSCL, SCL, APD, MTD and SCA were significantly larger in males. In accordance with our observations, (Elkhateeb et al., 2021) examined parameters of sacrum and coccyx using MRI method in 230 Egyptian individuals and found that ASL, PSL, ASCL, PSCL and APD were significantly larger in males ($p < 0.001$), however MTD did not exhibit significant difference between males and females. Recent Libyan study on CT images of 120 subjects reported that ASL, PSL, ASCL, PSCL, SCL and mid-sagittal diameter of the

base (MDB is equivalent to APD) were significantly larger in males ($p < 0.001$) (Abdelsamiee et al., 2021). The same results were reported in a study conducted on CT images of 350 Chinese subjects (Zhan et al., 2018). In agreement with our findings, a study conducted on 100 MDCT images of Turkish individuals revealed that ASL, PSL, ASCL, PSCL, anterior sacral curvature length (ASC), S1 sagittal length (S1-S) and S1 transverse length (S1-T) (equivalent to SCL, APD and MTD respectively) were significantly larger in males ($p < 0.005$) (Bakici et al., 2021). The same results were obtained from another study conducted on CT images of 480 Turkish subjects (Etli et al., 2019) and were also obtained from another study conducted on CT images of 230 cadavers in Japan (Torimitsu et al., 2017), however SCL was not measured in these two studies. In the present study, SCA was significantly larger in males ($p < 0.05$), however, it did not exhibit significant difference between both sexes in Turkish population (Etli et al., 2019).

The present work did not show significant difference in MBA between males and females, in accordance with previous studies (Benazzi et al., 2009; Zech et al., 2012; Hussein et al., 2016; Torimitsu et al., 2017; Etli et al., 2019; Bakici et al., 2021; Elkhateeb et al., 2021). However, studies on Libyan (Abdelsamiee et al., 2021) and Chinese populations (Zhan et al., 2018) reported that the maximum transverse diameter of the base (equivalent to MBA) was significantly larger in females. Ethnic and racial disparities, as well as different sample size and characteristics, different

methodological techniques and different environments could have resulted the differences between findings.

The differences in sacrum and coccyx measurements between males and females could be attributed to the adaption of pelvic morphology to fit childbearing process in females. Notably, the typical male sacrum is long and narrow, while the female sacrum is short and broad. In addition, MBA linear parameter is longer in females than in males due to the large female alae of the sacrum, which increases the dimensions of the female birth canal (Krenn et al., 2022).

In the present work, ROC curve showed that APD, ASCL, MTD and PSCL were the most accurate variables for sex discrimination with 74.55%, 72.73%, 70.46% and 70.00%, respectively. Furthermore, the derived BLR model based on PSCL, SCL, APD, MTD and SCA measurements was significant with classification accuracy of 86.4% (85.5% for females and 87.3% for males). Different studies assessed the accuracy of sacrococcygeal measurements for sex prediction and used different statistical methods. In Egyptians, ASL and PSL were the parameters that gave the highest accuracy for sex prediction based on univariate discriminant function analysis (DFA) (71.9 % and 71.5 % respectively). However, these two parameters achieved overall accuracy of 68.9% on stepwise DFA (Elkhateeb et al., 2021). In Libyan population, the most accurate parameters for sex discrimination using ROC analysis were CLS, PSCL and MDB (equivalent to APD) with accuracy rates of 99%, 98.3% and 90.5% respectively.

Those parameters also exhibited high statistically significant difference in sex prediction using logistic regression analysis (Abdelsamiee et al., 2021). In Turkish population, ROC analysis revealed that sacral area achieved the highest accuracy (80%); however, the accuracy rates of other parameters were comparable to their equivalents in the present study. DFA conducted on the 24 measured parameters revealed overall discrimination power of 94%, which is (Bakici et al., 2021), which is greater than the overall accuracy in the current work (86.4%). This discrepancy might be referred to the discrepancy in the number of variables included in analysis and to the different statistical methods used in both studies in addition to population specific differences. In another Turkish study, APD achieved the highest accuracy for sex discrimination (67.1 %), however, the accuracy rates were 65.8% and 64.6% for PSL and PSCL respectively. Linear DFA revealed total discrimination power of 82.5%, and stepwise DFA produced accuracy of 78.8% (Etili et al., 2019). Among the Chinese population, the highest accuracy (76.9%) was for MDB (equivalent to APD), however, the accuracy rate with stepwise DFA was 83.2% for males and 86.9% for females, with an overall accuracy of 84.9% (Zhan et al., 2018). In Japan, the most significant sex differences were for PSCL and PSL, with 77.0% and 73.0% accuracy rates respectively in univariate DFA. However, the total accuracy rate was 83.5% (81.7% for males and 85.2% for females) when calculated by stepwise DFA (Torimitsu et al., 2017). Flander 1978 analyzed samples from American populations (200 sacra of

known sex and age) and reported that MTD yielded a high classification accuracy for sex among black subjects (91%), however it yielded only 84% among white subjects using DFA (Flander, 1978). In Australia, Franklin et al., 2014 used MDCT scans of 400 individuals to determine sex and found that the accuracy of sex prediction was 70% using DFA (Franklin et al., 2014).

Importantly, environmental factors play a significant role in the manifestation of sexual dimorphism. This highlights the necessity for population-specific approaches and databases for skeletal sexual dimorphism (Ubelaker and DeGaglia, 2017).

Clearly, different populations, statistical methodologies, variables included in the study, sample size, radiographic modalities and race could all contribute to the variation in measurements' accuracy rates observed in various research studies (Etli et al., 2019; Agarwal et al., 2021).

V. CONCLUSION

The present study concluded that the measurements of sacrum and coccyx could be useful for sex identification in special forensic cases. ROC curve revealed that APD followed by ASCL provided the highest accuracy for sex identification (74.55% and 72.73% respectively). Binary logistic regression analysis was done and produced a significant model with overall accuracy of classification 86.4%. Sensitivity, specificity and accuracy of the resultant equation were of 83.6%, 82.7% and 83.6% respectively. However, the derived equation is population specific and cannot be applied on other populations.

VI. RECOMMENDATIONS

To confirm the findings of the present work, it is recommended that future research studies in different Egyptian governorates and with larger sample size be conducted.

VII. CONFLICTS OF INTEREST

The author declared that there was no conflict of interest.

VIII. REFERENCES

- Abdel-Hafez, A., El-Alfy, S., Swelim, H., & Hassan, N. (2019): Genetic Variation at 15 Autosomal STR Loci Among Seven Egyptian Populations. *Biochemical Genetics*, 57(1), 170–191.
- Abdelsamiee, E., Farahat, F., & Hamed, A. (2021): Estimation of Sex Using Sacrum and Coccyx Computed Tomography of Libyan Population in Benghazi. *Zagazig Journal of Forensic Medicine*, 19(1), 102–110.
- Agarwal, H., Setia, P., & Pandey, S. (2021): Virtual determination of sex: Estimating cut off value of digital metric traits of foramen magnum on three-dimensional computed tomography with receiver operating characteristic and logistic regression analysis. *Journal of Forensic Science and Medicine*, 7(1), 1–8.
- Akhlaghi, M., Bakhtavar, K., Moarefdoost, J., Kamali, A., & Rafeifar, S. (2016): Frontal sinus parameters in computed tomography and sex determination. *Legal Medicine*, 19, 22–27.

- Austin, D., & King, R. E. (2016): The Biological Profile of Unidentified Human Remains in a Forensic Context. *Academic Forensic Pathology*, 6(3), 370–390.
- Bakici, R. S., Oner, Z., & Oner, S. (2021): The analysis of sacrum and coccyx length measured with computerized tomography images depending on sex. *Egyptian Journal of Forensic Sciences*, 11(1), 1–13.
- Benazzi, S., Maestri, C., Parisini, S., Vecchi, F., & Gruppioni, G. (2009): Sex assessment from the sacral base by means of image processing. *Journal of Forensic Sciences*, 54(2), 249–254.
- Cafiero, C., Re, A., Stigliano, E., Bassotti, E., Moroni, R., & Grippaudo, C. (2019): Optimization of DNA extraction from dental remains. *ELECTROPHORESIS*, 40(14), 1820–1823.
- Decker, S., Davy-Jow, S., Ford, J., & Hilbelink, D. (2011): Virtual Determination of Sex: Metric and Nonmetric Traits of the Adult Pelvis from 3D Computed Tomography Models. *Journal of Forensic Sciences*, 56(5), 1107–1114.
- Elkhateeb, S., Abd Elhamed, M., Hamed, M., & Amer, M. (2021): Sex Determination from Sacrum and Coccyx measurements using Magnetic Resonance Imaging in a Sample of Egyptian Population. *Zagazig Journal of Forensic Medicine*, 19(1), 11–20.
- Etli, Y., Asirdizer, M., Hekimoglu, Y., Keskin, S., & Yavuz, A. (2019): Sex estimation from sacrum and coccyx with discriminant analyses and neural networks in an equally distributed population by age and sex. *Forensic Science International*, 303, 109955.
- Flander, L. (1978): Univariate and multivariate methods for sexing the sacrum. *American Journal of Physical Anthropology*, 49(1), 103–110.
- Franklin, D., Cardini, A., Flavel, A., & Marks, M. (2014): Morphometric analysis of pelvic sexual dimorphism in a contemporary Western Australian population. *International Journal of Legal Medicine*, 128(5), 861–872.
- Hussein, R., Shokry, D., Ismail, M., Abd-Elsatar, M., & Ibrahim, S. (2016): Sex identification from radiologic anthropometry of sacral and fifth lumbar vertebral measurements. *The Egyptian Journal of Forensic Sciences and Applied Toxicology*, 16(2), 117–126.
- Kalsey, G., Singla, R., & Sachdeva, K. (2011): Role of the greater sciatic notch of the hip bone in sexual dimorphism: A morphometric study of the North Indian population. *Medicine, Science and the Law*, 51(2), 81–86.
- Kayalioglu, G. (2009): The Vertebral Column and Spinal Meninges. In *The Spinal Cord* (pp. 17–36). Elsevier Ltd.
- Koo T. and Li M (2016). A guideline of selecting and reporting intraclass

- correlation coefficients for reliability research. *Journal of chiropractic medicine*. 1;15(2):155-63.
- Krenn, V., Webb, N., Fornai, C., & Haeusler, M. (2022): Sex classification using the human sacrum: Geometric morphometrics versus conventional approaches. *PLoS ONE*, 17(4), e0264770.
- Krishan, K., Chatterjee, P., Kanchan, T., Kaur, S., Baryah, N., & Singh, R. (2016): A review of sex estimation techniques during examination of skeletal remains in forensic anthropology casework. *Forensic Science International*, 261, 165.e1-165.e8.
- Kumar, R., Athota, A., Rastogi, T., & Karumuri, S. (2015): Forensic radiology: An emerging tool in identification. *Journal of Indian Academy of Oral Medicine and Radiology*, 27(3), 416–422.
- Naksuwan, N., Parasompong, N., Prahirunkit, P., Aobaom, S., & Khamphikham, P. (2021): Sacral morphometrics for sex estimation of dead cases in Central Thailand. *Legal Medicine*, 48, 101824.
- Spradley, M. K. (2016): Metric Methods for the Biological Profile in Forensic Anthropology: Sex, Ancestry, and Stature. *Academic Forensic Pathology*, 6(3), 391–399.
- Steyn, M., & İşcan, M. (2008): Metric sex determination from the pelvis in modern Greeks. *Forensic Science International*, 179(1), 86-e1.
- Torimitsu, S., Makino, Y., Saitoh, H., Sakuma, A., Chiba, F., Yajima, D., Inokuchi, G., Motomura, A., Yamaguchi, R., Hashimoto, M., Hoshioka, Y., & Iwase, H. (2017): Sex determination based on sacral and coccygeal measurements using multidetector computed tomography in a contemporary Japanese population. *Journal of Forensic Radiology and Imaging*, 9(October 2016), 8–12.
- Ubelaker, D., & DeGaglia, C. (2017): Population variation in skeletal sexual dimorphism. *Forensic Science International*, 278, 407.e1-407.e7.
- Wagh, M. (2015): Sexual Dimorphism with Help of Sacrum. *International Journal of Science and Research (IJSR)*, 4(10), 360–362.
- Zech, W., Hatch, G., Siegenthaler, L., Thali, M. & Löscher, S. (2012): Sex determination from os sacrum by postmortem CT. *Forensic Science International*, 221(1–3), 39–43.
- Zhan, M., Fan, F., Qiu, L., Peng, Z., Zhang, K., & Deng, Z. (2018): Estimation of stature and sex from sacrum and coccyx measurements by multidetector computed tomography in Chinese. *Legal Medicine*, 34, 21–26.

الملخص العربي

تحديد جنس البالغين من قياسات العظم العجزي والعصصي في عينة من المصريين باستخدام التصوير المقطعي المحوسب متعدد الكواشف

ريهام محمد جمال شلبي¹، شيماء أحمد علي شحاتة¹، وليد مسلم²، رحاب إبراهيم عبد الكريم¹

¹ قسم الطب الشرعي والسموم الاكلينيكية، كلية الطب، جامعة قناة السويس، الاسماعيلية، مصر

² قسم الأشعة التشخيصية، كلية الطب، جامعة قناة السويس، الاسماعيلية، مصر

المقدمة: يعتبر الاستعراف على الجنس أمر أساسي لتحديد هوية الأشخاص المجهولة. في الحالات التي يكون فيها الجسم مقطعا أو مشوهاً، يمكن تحديد الجنس من خلال فحص لأجزاء الهيكل العظمي والتي تتميز بفروقات بين الجنسين. وقد تم دراسة عظام الحوض وبالأخص عظم العجز والعصص ووجد انها تتميز بوجود فروقات بين الجنسين. كما وجد انها تعتبر وسيلة دقيقة للاستعراف على جنس البالغين في بعض الجنسيات **الهدف من الدراسة:** التوصل إلى طريقة دقيقة لتحديد جنس البالغين في المصريين. وكذلك الإستعراف على الجنس من خلال قياس فروقات العظام العجزية والعصصية بين الجنسين عن طريق استخدام التصوير المقطعي المحوسب متعدد الكواشف في عينة من المصريين. كما هدفت إلى وضع معادلة لتحديد الجنس باستخدام قياسات العجز والعصص في عينة من المصريين. **طريقة الدراسة:** أجريت هذه الدراسة المقطعية المقارنة على عينة من المشاركين المصريين وقد شملت الدراسة عدد 220 مريض بالغ معلومي الجنس (110 ذكور و110 إناث) ومن الذين أجروا تصوير مقطعي محوسب على منطقة الحوض والبطن بقسم الأشعة بمستشفيات جامعة قناة السويس التعليمية. تم دراسة عشر قياسات للعظمة العجزية والعصصية لكل مشترك في الدراسة لتحديد الفروقات بين الجنسين.

النتائج: قد خلصت النتائج إلى أن جميع القياسات المستخدمة في مجموعة الذكور كانت لديها قيم أعلى ذو دلالة إحصائية مقارنة بمجموعة الإناث ماعدا قياس أقصى اتساع لعلاء العجز وزاوية المنحنى العجزي العصصي. بالإضافة كان لقياس القطر الأمامي الخلفي للفقرة العجزية الأولى متبوعاً بالطول العجزي العصصي الأمامي دور في تحديد الجنس بمعدل دقة بلغت 74.55% و72.73% على التوالي وذلك باستخدام المنحنى المميز لأداء المستقبل. استطاع الانحدار اللوجستي الثنائي التنبؤ الصحيح للجنس بنسبة بلغت 87.3% للذكور و 85.5% للإناث. أيضا أظهرت معادلة الانحدار حساسية 83.6% ومعدل نوعية 82.7%. ومعدل دقة 83.6%.

الخلاصة: خلصت هذه الدراسة إلى أن القياسات العجزية العصصية أظهرت اختلافات ذات دلالة إحصائية بين الذكور والاناث، ويمكن أن تكون مفيدة لتحديد الجنس في حالات الطب الشرعي.