

Causes of Knee Joint Pain Related to Cartilage: Evaluation by MRI Cartilage Mapping of the Knee

Medhat M. Refaat, Mohamed A. Ali, Mohamed Abd Elsamie, Eslam M. Elshazly

Department of Radiology,
Benha faculty of medicine,
Benha university, Egypt.

Correspondence to:
Mohamed Abd Elsamie,
Department of Radiology,
Benha faculty of medicine,
Benha University, Egypt.

Email:

profmedo237@yahoo.com

Received: 17 September 2022

Accepted: 11 November 2022

Abstract

Background: The knee is a hinge joint made up of the articulations between the femoral and tibial condyles and between the patella and the patellar surface of the femur. In recent decades, magnetic resonance (MR) imaging has become the most important modality for assessment of pathologic changes in knee joint. One of the major advantages of MR imaging is that it highlights different tissue types. **Aim of the Work:** to elucidate the role of MRI cartilage mapping in evaluation of cartilaginous causes of painful knee joint. **Patients and Methods:** From June 2019 to July 2021, this pilot exploratory study was done to use axial or sagittal or coronal T2 mapping or all to visualize the articular cartilage of the knee on 3 T and 1.5 T MR Scanner using special advanced software to evaluate the effect of painful knee joint osteoarthritic changes on knee articular cartilage. **Results:** When comparing the overall diagnostic indices of conventional MRI and T2 mapping, 90% cases were correctly diagnosed by conventional MRI and 98.3% cases were correctly diagnosed by T2 mapping. **Conclusion:** The addition of sagittal T2 maps to standard views improved accuracy in diagnosing cartilage affection in early osteoarthritic painful knee joint. This imaging plane seems to provide a useful addition to

standard MR imaging when osteoarthritis is suspected as a cause of painful knee joint especially among the young population. It also provides an excellent screening tool for athletes. It provides a good monitoring tool for osteoarthritis process.

Key words: Knee Joint, pain, Cartilage, MRI

Introduction

Magnetic resonance imaging (MR imaging) has emerged as the most crucial technique for evaluating pathologic alterations in the knee joint in recent years. The fact that MR imaging distinguishes between various tissue types is one of its main advantages. With the development of several MR imaging techniques, cartilage can now be

morphologically assessed, its volume can be quantified, and its biochemical makeup may be evaluated⁽¹⁾.

It is necessary to use methods to keep track of the morphologic condition and chemical makeup of hyaline cartilage⁽²⁾. Assuring and focal or diffuse partial- or full-thickness cartilage degradation are two processes that

can be accurately assessed using morphologic MR imaging techniques for the knee joint ⁽³⁾.

T2 mapping of hyaline articular cartilage is particularly sensitive to changes in the cartilage matrix and reflects interactions between water molecules, as well as between water molecules and the surrounding macromolecules ⁽⁴⁾.

Axial, sagittal, or coronal T2 maps, or all three, were obtained utilizing a unique software technique after the standard imaging planes of the knee were examined while focusing on its articular cartilage at various imaging sequences. Then, articular cartilage was assessed using an orange to blue color scale, these standard planes were reviewed along with T2 maps for the same locations ⁽⁵⁾.

The accuracy of identifying cartilage affection in early osteoarthritic uncomfortable knee joints was increased by the inclusion of sagittal T2 maps to conventional views. When osteoarthritis is suspected as the reason of a painful knee joint, especially in the young population, this imaging plane appears to be a helpful supplement to regular MR imaging. Additionally, it offers athletes a great screening tool. It is a useful tool for tracking the progression of osteoarthritis ⁽⁶⁾.

Aim of the work

The aim of the current study is to elucidate the role of MRI cartilage mapping in evaluation of cartilaginous causes of painful knee joint.

Patients and Methods

This pilot exploratory study was conducted at Maadi Military Hospital, El Nozha International Hospital and or International Medical Center in the period from June 2019 to July 2021.

This study was conducted on 60 patients. 36 males and 24 females complaining of knee

joint pain referred by their clinicians to Radiology Department. The patients underwent MRI cartilage mapping of the knee joint.

All patients were submitted to the following:

Demographic and clinical data collection including, patient's name, age, residence, phone number, complaint, duration of illness and past history.

Clinical provisional diagnosis (Imaging procedure)

A total of 60 MRI scans and matching complementary T2 mappings were examined since each patient underwent a single MRI scan and one complementary T2 mapping.

The study included clinically suspected patients with knee joint pain with no age or gender predilection.

The following patients were excluded from the study:

1. Patients with surgical intervention to the knee joint.
2. Patients known to have contraindications for MRI e.g. an implanted magnetic device, pacemakers.

The MRI procedure that the patients would have:

- GE magnet 1.5 and 3Tesla are used.
- GE work station 1.5 Tesla is used.
- MR imaging is performed by using a phased array surface coil on the selected region.
- Small Field Of View (FOV) for high spatial resolution.
- No anesthesia was used.
- No Contrast media were used.

Tips & Tricks:

- Cushion the knee well (sandbags, wedges).
- To avoid repeatedly having to set up two scout sequences (in the off-center

position), have a right and left sagittal scout set up for the knee in the standard scout program; one scout always displays the joint while the other does not.

- In children, comparative images of the two knees may be performed with the knees in the head coil. Secure the knees with cushions and for the sequences either adjust TR according to the number of slices or run the sequences separately for each side.
- The anterior cruciate ligament is delineated best at 15–20° of external.
- Rotation, the posterior cruciate ligament at 0° or 5° internal rotation.

Protocol of MR imaging, Table (1):

- Preliminary scout localizers in axial, coronal and sagittal planes were done. The axial images serve as a localizer for prescribing the coronal and sagittal sections.
- The coronal sections are graphically prescribed on an axial image from the patella to the posterior surfaces of the femoral condyles. The planes is

oriented parallel to the anterior/posterior surfaces of the femoral condyles.

- The sagittal sections are graphically prescribed from the lateral to the medial collateral ligament and aligned parallel with the anterior cruciate ligament.
- The coverage should include all the anterior, posterior, medial, and lateral supporting structures of the knee. Superiorly, the distal aspects of the quadriceps tendon should be included. The distal insertions of the patellar tendon should be included inferiorly.
- The standard knee protocol (sagittal proton density-fat suppressed, coronal proton density-fat suppressed, axial T2 weighted image, sagittal T1 weighted image and sagittal T2 weighted image) was done.
- Complementary sagittal T2 maps were displayed by using the available software tools provided by the MR scanner manufacturer.

Table (1): MRI sequences used in the study

Sequence	TR (msec.)	TE (msec.)	FOV (mm)	Matrix	Slice thickness (mm)
T2 sagittal	3000	87.5	290 x290	208x 205	3
T2 axial	3000	87.6	288 x 350	292 x 180	4
T1 sagittal	435	9.3	260 x 216	263 x 171	3
PDFS sagittal	1549	29.2	240 x 240	240 x 190	3
PDFS coronal	1533	28.8	300x300	272x200	3
Axial merge	531	7.4	160 x 160	352 x 224	3
T2 maps axial, sagittal & coronal	1780	6.0	290x290	208x205	3

Image Analysis

- The ability to delineate the medial and lateral tibiofemoral articular cartilage was assessed.
- Firstly, the standard imaging planes of

the knee were evaluated with

assessment of articular cartilage as intact or thinned out. Thereafter, these standard planes were evaluated

together with T2 maps and articular cartilage was again assessed as of milliseconds.

- An intact articular cartilage was the one with uniform thickness and bright hyperintense signal on PDFS sequence covering tibial, femoral and patellar articular surfaces.
- On T2 maps, intact articular cartilage was the one with normal T2 values not exceeding 40 milliseconds delineated by color coded map, represented on a color coded scale with upper limit of 100 millisecond.
- Affected articular cartilage in early stages of osteoarthritis may appear in PDFS sequence as an area with non-

normal or elevated T2 signal in terms uniform thickness, or even of altered signal intensity.

- On T2 maps, cartilage affection in early osteoarthritis can be easily delineated as it takes a certain color corresponding to high T2 value on the color coded scale, also radiologist can measure the exact T2 value in terms of milliseconds for the suspected cartilage by using 'region of interest' property found in the scanner software.
- Any associated meniscal, ligamentous, muscular or bony abnormalities in the knee were reported.

Ethical Considerations:

The study protocol received ethical approval from the Research Ethics Committee, Maadi Military Hospital, El Nozha International Hospital and International Medical Center. The patients have the right to refuse participation without affecting the medical care expected to be offered to her. Confidentiality of all data of all the study population will be preserved.

Results

The ages ranged from 20–74-year-old with a mean age 38.42 ± 13.82 (Table 2). Cases were classified according to the clinical presentation. All patients presented with knee pain either following direct trauma or twisting. There were a 16 (26.7%) cases presented by knee pain following direct trauma and 44 (73.3%) cases presented by knee pain following knee twisting (Table 3).

Statistical analysis:

Recorded data were analyzed using the statistical package for social sciences, version 23.0 (SPSS Inc., Chicago, Illinois, USA). The quantitative data were presented as mean \pm standard deviation and ranges. Also qualitative variables were presented as number and percentages. P-value <0.05 was considered significant.

MRI Findings:

Cases were divided according to their findings by conventional MRI and post processing T2 mapping (Table 4).:-

- 47/60 (78.3%) cases were correctly diagnosed of having cartilage denudation, denoting osteoarthritis.
- 6/60 (10%) cases were misdiagnosed of being normal, while having alteration of cartilage composition thus denoting early osteoarthritis.

- 7/60 (11.7%) cases were diagnosed of having no cartilage abnormality.

T2 mapping findings: (Table 5).

- 1/60 (10%) cases were misdiagnosed of being normal, while having alteration of cartilage composition thus denoting early osteoarthritis.
- 7/60 (10 %) cases were diagnosed of having normal cartilage composition.

- 52/60 (90 %) cases were correctly diagnosed of having alteration of cartilage composition.

Comparison of the overall diagnostic indices of conventional MRI and T2 mapping: (Table 6).

- **54/60 (90%) cases were correctly diagnosed by conventional MRI.**
- 59/60 (98.3%) cases were correctly diagnosed by T2 mapping

Table (2): Age distribution of the patients participating in the study.

Age (years)	Total (n=60)
20-30 years	11 (18.3%)
>30-40 years	22 (36.7%)
>40-50 years	14 (23.3%)
>50-60 years	9 (15.0%)
>60-74 years	4 (6.7%)
Range	20-74
Mean±SD	38.42±13.82

Clinical Presentation:

Table (3): Distribution of cases according to clinical presentation

Clinical Presentation	Total (n=60)
Direct Trauma	16 (26.7%)
Knee twisting	44 (73.3%)

Conventional MRI findings:

Table (4): Conventional MRI findings.

True Positive (N=47)	False Positive (N=0)
False Negative (N=6)	True Negative (N=7)

Table (5): T2 mapping Findings.

True Positive (n=52)	False Positive (n=0)
False Negative (n=1)	True Negative (n=7)

Table (6): Comparison of diagnostic indices of conventional MRI and T2 mapping.

	Sensitivity	Specificity	Positive predictive value	Negative predictive value	Accuracy
Conventional MRI	88.7%	100%	100%	53.8%	90.0%
T2 mapping	98.1%	100 %	100 %	87.5%	98.3%

Example (1)

- **Clinical background:**

A male patient, 24-year-old, presenting with left sided knee pain after twisting.

- **Conventional MRI, sagittal PD FS revealed:**

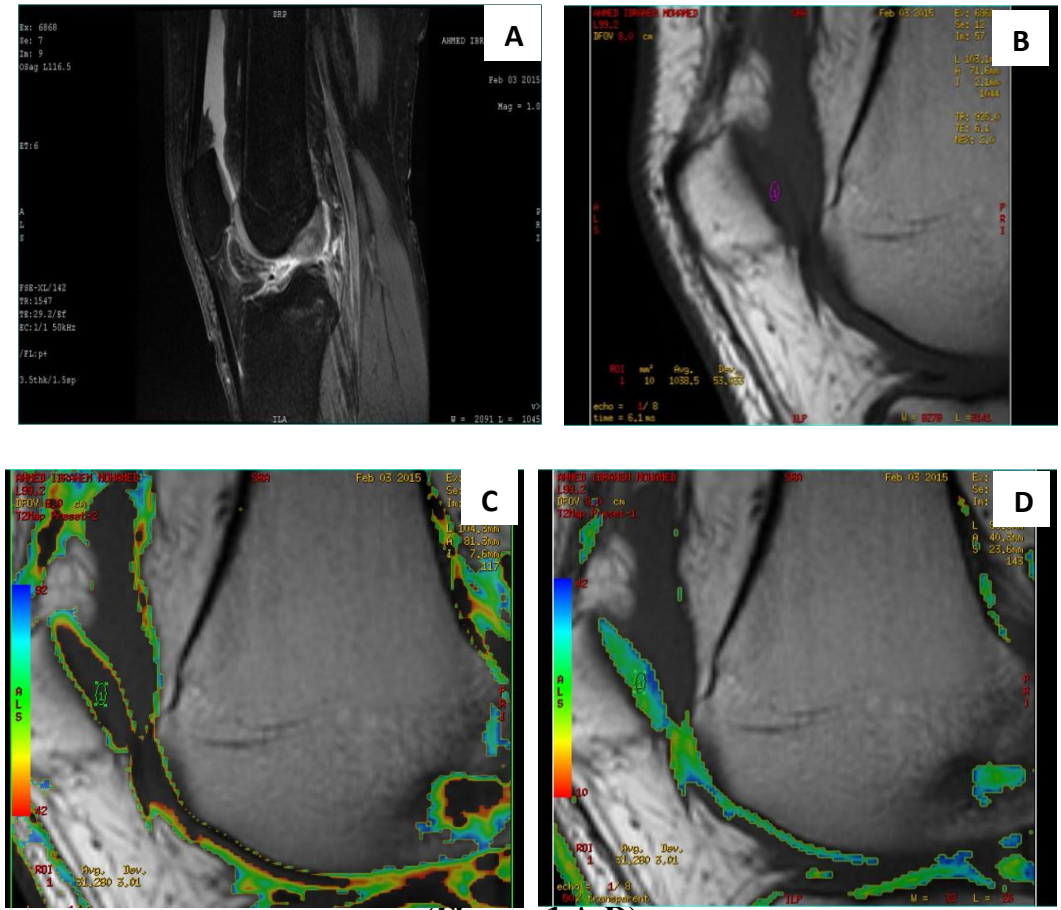
- Preserved signal intensity of the retro patellar cartilage with uniform cartilage thickness.

(Figure 1 A)

- **T2 mapping revealed:**

- Normal color coded values (31) of the retro patellar cartilage.

(Figures 1 B, C and D)



(Figures 1 A-D)

Example (2)

- **Clinical background:**

- A male patient, 33_ year - old, presenting with right sided knee pain after twisting.

- **Conventional MRI, coronal PD FS revealed:**

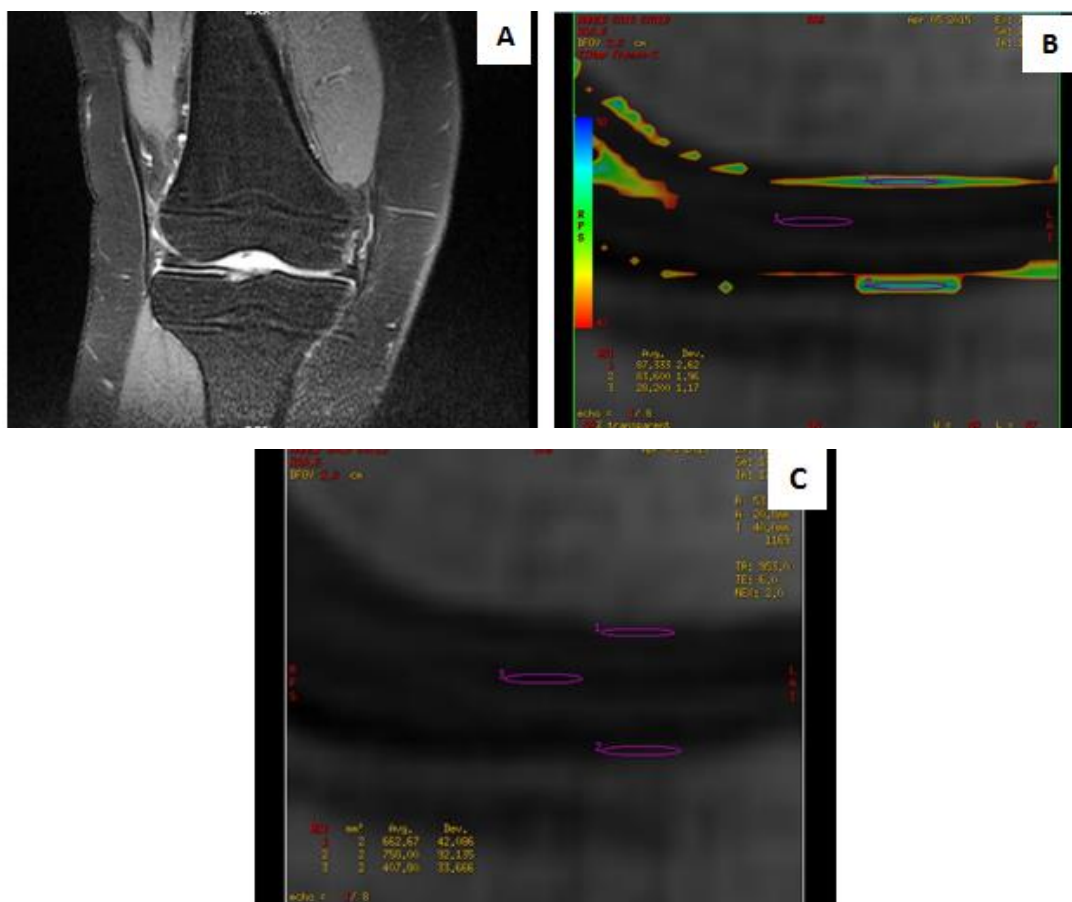
- Altered signal intensity of the cartilage capping the lateral tibiofemoral upper lateral tibial plateau with non- uniform cartilage thickness.

(Figures 2 A)

- **T2 mapping revealed:**

- Elevated color coded values of the cartilage covering the lateral tibiofemoral condyle (87) and the cartilage covering the lateral tibial plateau (83).

(Figures 2 B and C)



(Figures 2 A-C)

Discussion

While conventional magnetic resonance imaging (MRI) allows for macroscopic anatomic assessment of the cartilage, it is less sensitive to the biochemical changes associated with early OA, radiographs are frequently used to evaluate decreased joint space associated with cartilage thinning, but this approach is limited to moderate to severe diffuse cartilage loss ⁽⁷⁾.

T2 mapping is a crucial component of compositional MR imaging for assessing cartilage damage that is likely to be reversible and occurring early ⁽⁸⁾.

T2 mapping's primary clinical use is the early diagnosis of cartilage injury before symptoms appear and before it is discovered using traditional screening methods ⁽⁷⁾.

The ability to detect early cartilage degradation and distinguish between different stages of degeneration may be improved by combining the morphological and functional information ⁽⁹⁾.

On the basis of collagen structure and hydration, T2 mapping has been utilized to describe the composition of hyaline articular cartilage in the knee joint. T2 relaxation time analyses in the knee have been conducted, often at 1.5 T or, more recently, 3.0 T, revealing the capability to portray anomalies prior to the occurrence of morphologic change that is obvious ⁽⁸⁾.

T2 mapping is superior to other quantitative MRI methods in that it does not require the injection of contrast agents and may be conducted non-invasively. Additionally, this sequence and its post-processing software are readily available in many commercial MRI scanner systems ⁽⁷⁾.

The most frequently utilized quantitative MRI methods in the clinical setting right

now are T2 mapping and dGEMRIC. It is still unclear and changeable what exact values correspond to healthy and damaged cartilage. The incorporation of these approaches as part of conventional clinical care has been hampered by the lack of knowledge of factors that contribute to the varying values in the literature ⁽⁷⁾.

Our study included 60 cases; 48/60 (80 %) were diagnosed by conventional MRI as having cartilage abnormalities and 6/60 (10 %) were missed to be accurately diagnosed; This false negative result was considered to be due to minimal alteration of cartilage composition denoting early arthritic changes that were detected by T2 mapping findings.

This agrees with another study⁽¹⁰⁾ who reported that the potential value of T2 mapping as a biomarker for early cartilage degeneration is highlighted by its inclusion in the MRI protocol for the early osteoarthritis.

Advanced quantitative MRI techniques such as T2 mapping are sensitive to subtle cartilage matrix alterations that occur early in the course of OA and therefore, these imaging modalities have the potential to provide biomarkers for disease onset and progression, which could be a meaningful addition in the diagnosis and follow-up of cartilage abnormalities ⁽¹¹⁾.

A study by **Hesper et. al.**, ⁽¹¹⁾ concluded that “Biochemically sensitive” MRI techniques as T2 mapping, can add robust biomarkers for osteoarthritis onset and progression with varying degrees of sensitivity and specificity, and therefore could be meaningful assessment tools for the diagnosis and follow-up of cartilage abnormalities.

In our study the age of presentation of the cases ranged from 20 to 74 year-old, with a mean age 38.42 ± 13.82 .

Out of the 60 cases, 16 cases (26.7%) presented by knee pain following direct trauma, and 44 (73.3%) presented by knee pain following knee twisting. All cases underwent conventional MRI with complementary T2 mapping sequence.

T2 mapping despite all the enumerated advantages, and its contribution to enhancing cartilage status assessment, is still in its infancy, as its values are based on several factors, including the biochemical status of the cartilage, physics variables involved in obtaining the mapping, and the physiology of the individual patient. So the current literature still lacks clinical correlation.

In their study, they reported that the potential clinical applications of quantitative mapping are vast, but, before the clinical community can take full advantage of this tool, it must be automated, standardized, validated, and have proven reproducibility prior to its implementation into the standard clinical care routine ⁽⁷⁾.

T2 mapping may provide the basis for diagnosis and follow-up evaluation of cartilage injury and response to cartilage treatment and repair. Once a set of standardized protocols are developed and proposed, subsequent studies are needed to determine specific values or distribution of values, which are associated with healthy and damaged cartilage ⁽⁷⁾.

In their study, they added that much remains to be understood and certain points have become apparent with the studies that are crucial to the further applications of T2 mapping technique, also added that further studies are needed to address protocol issues for this technique ⁽¹¹⁾.

T2 mapping has proven to be a useful predictor of cartilage degeneration and repair tissue following surgical intervention in the knee ⁽⁷⁾.

However, long-term monitoring of any of the healing strategies has not yet been documented. Surgical approaches to repair localized cartilage damage were presented a number of years ago and have showed encouraging results. Microfracture, osteochondral transfer, and autologous chondrocyte implantation are the methods that are used the most frequently ⁽⁸⁾.

Conclusion:

The addition of sagittal T2 maps to standard views improved accuracy in diagnosing cartilage affection in early osteoarthritic painful knee joint. This imaging plane seems to provide a useful addition to standard MR imaging when osteoarthritis is suspected as a cause of painful knee joint especially among the young population. It also provides an excellent screening tool for athletes. It provides a good monitoring tool for osteoarthritis process.

References

1. **Jerban S, Chang EY, Du J.** Magnetic resonance imaging (MRI) studies of knee joint under mechanical loading. *Magn Reson Imaging*; (2020); 65:27-36.
2. **Black C, Clar C, Henderson RP.** The clinical effectiveness of glucosamine and chondroitin supplements in slowing or arresting progression of osteoarthritis of the knee: a systematic review and economic evaluation. *Health Technol Assess*; (2009); 13(52): 1-148.
3. **Argentieri EC, Burge AJ, Potter HG.** Magnetic resonance imaging of articular cartilage within the knee. *J Knee Surg*; (2018); 31(02):155-65.
4. **Martín Noguero T, Raya JG, Wessell DE, Vilanova JC, Rossi I, Luna A.** Functional MRI for evaluation of hyaline cartilage extracellular matrix, a physiopathological-based approach. *Br J Radiol*;

(2019); 92(1103): 20190443.

5. Kaneko Y, Nozaki T, Yu H, Chang A, Kaneshiro K, Schwarzkopf R, et al.: Normal T2 map profile of the entire femoral cartilage using an angle/layer-dependent approach. *J Magn Reson Imaging*; (2015); 42(6):1507-16.

6. Teoh YX, Lai KW, Usman J, Goh SL, Mohafez H, Hasikin K, et al.: Discovering Knee Osteoarthritis Imaging Features for Diagnosis and Prognosis: Review of Manual Imaging Grading and Machine Learning Approaches. *J Healthc Eng*; (2022); 4138666; 218-233.

7. Surowiec RK, Lucas EP and Ho CP: Quantitative MRI in the evaluation of articular cartilage health: reproducibility and variability with a focus on T2 mapping. *Knee Surg Sports Traumatol Arthrosc*. 2014 Jun;22(6):1385-95.

8. Crema MD, Roemer FW, Marra MD.: Articular cartilage in the knee: current MR imaging techniques and applications in clinical practice and research. *Radiographics*; (2011); 31(1):37-61.

9. Poh CL and Sheah K. Visualization of Articular Cartilage Using Magnetic Resonance Imaging Data. *ICBME 2009, Proceedings 23*, pp. 386–389.

10. Chang G, Regatte RR. Advanced MRI of Cartilage and Subchondral Bone in Osteoarthritis. In *Advanced Computational Approaches to Biomedical Engineering 2014* (pp. 177-191). Springer, Berlin, Heidelberg.

11. Hesper T, Hosalkar HS, Bittersohl D, Welsch GH, Krauspe R, Zilkens C, et al. T2* mapping for articular cartilage assessment: principles, current applications, and future prospects. *Skeletal Radiol*. 2014 Oct;43(10):1429-45.

To cite this article: Medhat M. Refaat, Mohamed A. Ali, Mohamed Abd Elsamie, Eslam M. Elshazly. Causes of Knee Joint Pain Related to Cartilage: Evaluation by MRI Cartilage Mapping of the Knee. *BMFJ* 2023;40(Radiology): 171-181.

