

INTERNATIONAL JOURNAL OF MEDICAL ARTS

Volume 4, Issue 8, August 2022

<https://ijma.journals.ekb.eg/>




Print ISSN: 2636-4174

Online ISSN: 2682-3780



Available online at Journal Website
<https://ijma.journals.ekb.eg/>
 Main Subject [Orthopedics]



Original Article

Evaluation of Adjustable Loop Fixation in Management of Acute Acromioclavicular Joint Dislocation

Aly Ahmed Eid ^{1*}, Ibrahim Ahmed Mostafa ², Lotfy Shwitter ²

¹ Department of Orthopedic Surgery, Alexandria Armed Forces Hospital, Ministry of Defense, Egypt

² Department of Orthopedic Surgery, Faculty of Medicine, Al-Azhar University, Cairo, Egypt.

ABSTRACT

Article information

Received: 24-08-2022

Accepted: 13-11-2022

DOI:
10.21608/IJMA.2022.158378.1500

* Corresponding author

Email: alyyyeid@gmail.com

Citation: Eid AA, Mostafa IA, Shwitter L. Evaluation of Adjustable Loop Fixation in Management of Acute Acromioclavicular Joint Dislocation. IJMA 2022 August; 4 [8]: 2570-2577. doi: 10.21608/IJMA.2022.158378.1500

Background: Surgical treatment procedures for acromioclavicular [AC] joint dislocation often manifests some complications. Numerous techniques are evaluated, but there is no gold standard method for management of such injuries yet.

The Aim of the work: The present study aims at evaluating the results of open single adjustable loop for management of acute AC joint dislocation of types: III, IV and V.

Patients and Methods: This study is a prospective cohort work conducted on 20 cases who were subjected to surgical intervention by the adjustable loop fixation system for acute AC joint dislocation. During the follow up phase, Age, sex, dominant hand, injury mechanism, injured side, duration of the monitoring period, shoulder and hand [DASH], time before surgery, pain scores. The average follow-up time was 16.17±4.38 weeks.

Results: Patients' mean age was 34.5±11.5 years, of which four patients [20%] were females, while the rest of them [60%] were males. Pre-operation VAS, post-operation measurements, and constant shoulder scores have all shown very significant differences. On the other hand, the study found no significant differences between right and left coracoclavicular, while two cases of shoulder stiffness were recorded.

Conclusion: As per the results, the adjustable loop fixation system used as a treatment procedure for acute acromioclavicular joint dislocation manifested suitable results and had minimal damage to the soft tissues surrounding the coracoclavicular ligaments.

Keywords: Acromioclavicular joint; Adjustable loop fixation; Dislocation.



This is an open-access article registered under the Creative Commons, ShareAlike 4.0 International license [CC BY-SA 4.0] [<https://creativecommons.org/licenses/by-sa/4.0/legalcode>].

INTRODUCTION

Dislocations of the acromioclavicular [AC] joint represent 9% of shoulder joint injuries. AC joint dislocation typically happens as a result of direct or indirect force [1]. Patients of all age groups can be involved in this type of injury, as it is a common injury caused by accidents related to traffic, sports [as in contact sports such as football players, with an incidence rate of 41%], military training, and falls [2, 3].

The AC joint dislocation is usually graded using Rockwood's classification [grades I to VI], which is based on the severity of damage [4]. Treatment plan for grade I and II AC joint dislocations might be conservative. Although non-operative treatments are advised for type III AC joint dislocations [5], recent research have revealed that surgical treatments for this kind of damage produce better functional results [6]. Thus, some patients with grade III, those with IV–VI types will require surgical intervention due to the disturbance of AC and coracoclavicular [CC] ligaments, leading to insecurity of the different directions of the joint [7, 8].

Various surgical procedures have been suggested for the treatment of AC joint dislocation. Reducing the gap between the clavicle and coracoid, which results in primary healing of the CC ligament, is the main goal of therapy [9, 10]. However, a gold standard for this damage has not yet been identified. The stabilization of this kind of injury is associated with trauma during surgery, non-anatomical repair, and numerous other consequences as a result of the surgery, as reported by several researches [11-14].

THE AIM OF THE WORK

The present work involves the evaluation of reconstructing the regular structure of the AC joint using adjustable loop stabilization technique in acute AC joint dislocation. This work is aims at evaluating the outcomes of open single adjustable loop as a treatment procedure of acute acromioclavicular joint dislocation type III to V.

PATIENTS AND METHODS

Patients subjected to surgical interventions with the adjustable loop stabilization procedure for acute AC joint dislocation were assessed in a prospective study carried out between June

2021 to June 2022, in Al-Azhar University Hospitals, Cairo and Alexandria Armed Forces Hospital, Alexandria. Twenty patients were enrolled into the study: 16 men and 4 women [age range: 22 to 50]. The following three radiographic views were used to determination the type of injury: AP view [with 10 degrees cranial tilt of the beam], stress view of both sides of the AC joint and CC ligament], and true axillary view in the supine position.

Inclusion criteria: Patients with acute AC joint dislocation grades III to V according to **Rockwood et al.** [4], who is free from previous shoulder injuries or surgical procedures, and completed follow-up duration of six months. Cases with frozen shoulder or had associated comorbidities were excluded. Cases of type III were included in this study if the radiographs' distal end of the clavicle was visible at a distance \geq to 75 to 100% of its articular surface width; also, the presence of painful palpation and clavicle protuberance during shoulder anterior elevation during clinical diagnosis. A senior surgeon handled every intervention, and the same adjustable loop approach was used in every case. Before surgery, age, sex, mechanism of injury, dominant hand, side of damage, and time before surgery were all noted.

Surgical technique: Once the patient is positioned in the deckchair posture, the integrity of the shoulder and AC joint reductions was assessed. Every test was carried out while under either local or general anesthesia. Before skin incision, all patients received doses of third-generation cephalosporin to prevent infection. The subject's wounded upper limb was initially prepped and draped in sterile conditions. The skin incision for this procedure was determined using anatomical markers like the coracoid process, distal clavicle, and the front region of the acromion. Following palpation of the coracoid process tip, a 4-6 cm long skin incision was performed. From the upper border of the trapezius down to the coracoids, a 2-3 cm medial incision was made to the AC joint. The incision line was then widened.

The gap in between coracoid process and the terminal section of the clavicle was separated at that point. A curving soft tissue lifter was used to medially and laterally slice the tissue. The AC joint was exposed by continuing the side flaps. Initially, two drill holes using 2.4 mm guide pin done, one on the clavicle [midway between anatomical attachments of

CCL] 2.5-3 cm medial to AC joint and another drill hole on the bottom of coracoid. Then, the guide pin was carefully over-drilled by a 4.5 mm drill. Then, the guide pin and drill were removed. At first, a button inserter was used to place the flexible loop through the coracoid hole and into the clavicle hole. The first button was then turned over and secured beneath the coracoid process by pulling a traction suture. This procedure involved applying pressure while employing fluoroscopic visualization to reduce the AC joint in the natural position. The second button was then positioned and attached on the upper side of the clavicle in this location, and while a helper held the reduction, the button was then fastened with approximately five knots. Shoulder mobilization was examined in accordance with post-operative guidelines.

Follow up: The final follow-up when the patient completing 6 months after operation. Visual analogue scale [VAS], constant ^[15], and shoulder and hand [DASH] scores ^[16] were recorded prior to and following surgery, and were used for functional assessments during the follow-up period. Additionally, on the standard view of the anteroposterior radiographs taken on both sides in the most recent follow-up, the vertical distance between the superior border of the coracoid process and the anterior-inferior border of the clavicle was measured. All complications were recorded.

Statistical analysis: Information was entered into the SPSS-16 program. Frequency,

percentage, mean, and standard deviation [SD] were employed for qualitative data. The t-test was applied to compare the quantitative data from before and after surgery. The significance level was set at a P-value of 0.05.

RESULTS

Table [1] shows the characteristics of each patient. Age ranged from 22 to 50 years, and the mean age of patients was 34.6 ± 11.5 years. 16 patients [80%] were males. 65% of injuries were on the left side, and 55% of them were the result of accident. The majority of cases had grade III dislocation [80%].

In Table [2], score distribution among studied cases is shown. The median pre-operative VAS score was 40.0 [30.0-70.0] decreased to 0.0 post-operatively [0.0-30; P. <0.001]. Constant scores increased from 34.0 ± 5.5 pre-operatively to 95.1 ± 6.96 postoperatively [P. <0.001]. Median DASH score was 14.6 preoperative [11.7-24.2] and 0.8 [0.0-10.0] post-operative [P. <0.001]. The reduction of the CC interval was statistically significant [P. 0.02]

All complications were recorded post-operatively and we found that 12 cases (60%), had no complications, 4 cases (20%) had Pin tract infection, two cases (10%) had shoulder stiffness, one case (5%) had wound infection and one case (5%) had wound sinus. There was no intraoperative complication [Table 3].

Table [1]: Characteristics of patients with acromio-clavicular dislocation

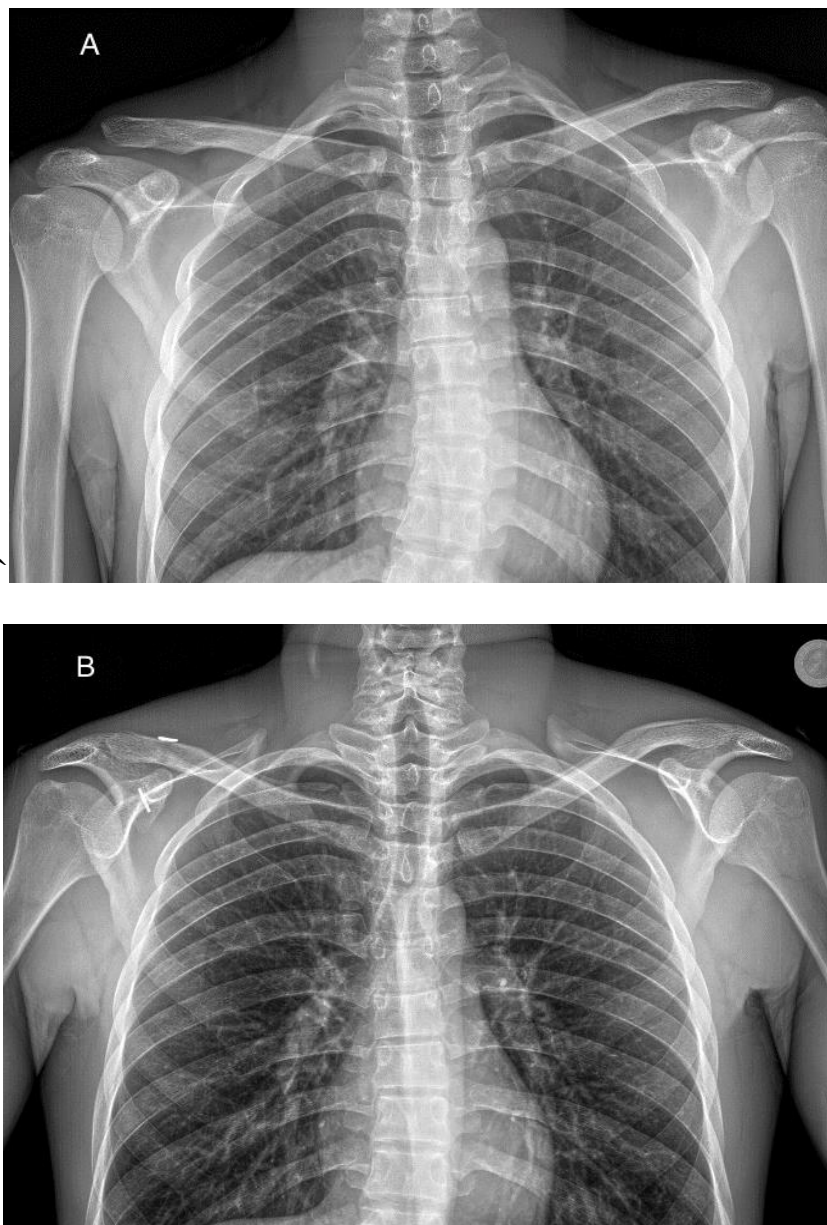
No.	Age	Sex	Side of injury	Mechanism of injury	Grade of dislocation	Pre-op period [days]	FU duration [weeks]
1	22	Male	Right	RTA	IV	5	20
2	40	Male	Right	RTA	III	4	17
3	29	Male	Left	Falling	III	5	23
4	31	Male	Left	Falling	III	3	24
5	33	Female	Left	Falling	III	5	24
6	27	Male	Left	Falling	III	2	20
7	32	Male	Right	RTA	III	1	17
8	24	Male	Left	RTA	III	5	17
9	34	Male	Left	RTA	III	4	18
10	33	Female	Right	RTA	III	5	18
11	39	Male	Left	RTA	III	3	19
12	30	Male	Left	Falling	III	2	24
13	30	Male	Left	Falling	IV	2	24
14	42	Male	Right	RTA	V	2	24
15	31	Female	Left	Falling	III	2	20
16	22	Male	Left	Falling	III	3	20
17	27	Male	Right	Sport Injury	III	3	24
18	27	Male	Left	RTA	III	3	24
19	35	Male	Left	RTA	III	4	24
20	36	Female	Right	RTA	IV	4	18

Table [2]: Score distribution among studied cases

	Pre-operative	Post-operative	Test	P value
Constant Score Mean \pm SD	34.0 \pm 5.5	95.1 \pm 6.96	Paired t=56.04	<0.001
ASES score Mean \pm SD	39.31 \pm 5.8	97.57 \pm 4.98	Paired t =51.5	<0.001
DASH sore Median [Min-Max]	14.6 [11.7 – 24.2]	0.8 [0.0 – 10.0]	z=3.9	<0.001
VAS score Median [Min-Max]	4 [3 – 7]	0.0 [0 – 3]	z=3.95	<0.001
Coraco-clavicular interval (mm) Mean \pm SD	14.5 \pm 1.96	10.35 \pm 2.11		0.02

Table [3]: Distribution of studied cases according to complications

Complications	n=20	%
No postoperative complications	12	60.0
Pin tract infection	4	20.0
Shoulder stiffness	2	10.0
wound infection	1	5.0
Wound sinus (delayed infection)	1	5.0

**Figure [1]:** View of the shoulder from the anteroposterior view in a patient using the adjustable loop fixation technique. A: Before surgery; B: After surgery

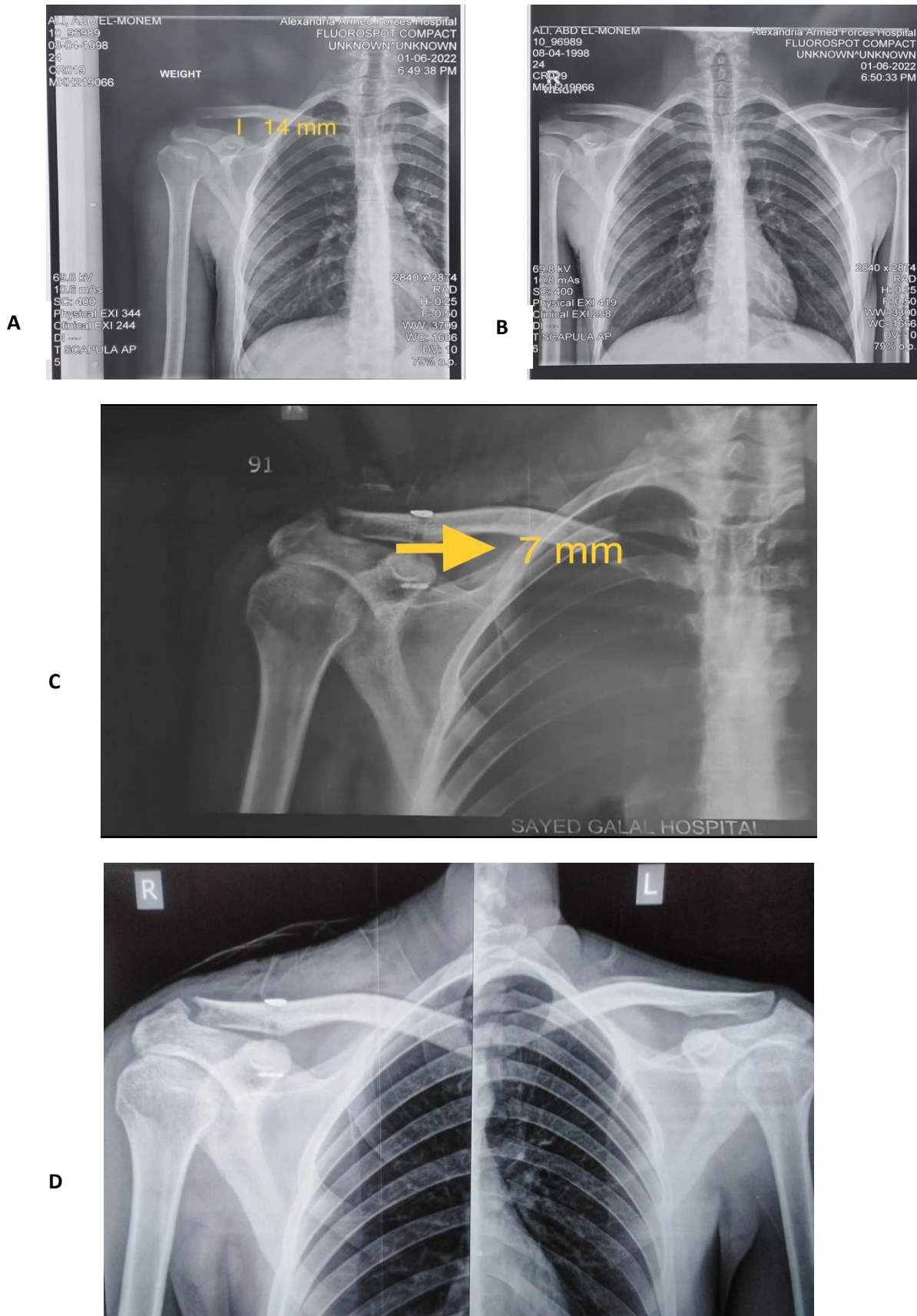


Figure [2]: Male patient 25 years old with history of road traffic accident. A) Stress view shows AC joint disruption Rockwood type III of right shoulder. B) X-ray of both injured and uninjured sides. C) Immediate postoperative x-ray, D) Final follow up x-ray

DISCUSSION

There have been several suggestions for treating acute AC joint dislocation. For the management of full AC joint detachment, more than 70 strategies have already been recommended [17].

The evidence does indicate that these procedures have a significant rate of difficulties. To handle AC joint dislocation, other methods like Kirschner wiring, needles, pins, or hooked plates are again employed [18-21].

The most important objective of all approaches is to restore the AC joint's physiological functions by minimizing dislocation, stabilizing the distal part of the clavicle, and creating a situation for tissue rebuilding. However, incompetency has been demonstrated for these techniques, when the pin or cerclage are used as a temporary fixation due to the pin or cerclage's high incidence of degenerative changes, breaking of the pins, equipment mobility into the thoracic cavity, and bony lesions; so, these techniques have not been recommended for long-standing management [10].

The joint capsule and AC ligament provide a horizontal restriction while the CC ligament plays a significant role in exerting force against vertical translation. Previous studies on the biomechanics of the CC ligament complex have revealed that this complex has a special function in the anterior and superior displacement of the clavicle [22, 23].

Sutures have been utilized in some procedures to shorten the time between AC joint dislocations. Sutures, however, can have sawing effects and cause these procedures to fail [24, 25]. **Ponce et al.** [26] employed tendon auto graft for augmentation fixation in revision instances and nine No. 1 absorbable sutures enfolded in a tension cable rope pattern for AC joint reconstruction.

In this study, we included 20 patients with acute dislocation the AC joint type III, IV and V. Surgical management by the adjustable loop technique was conducted, where we used 2 buttons with suturing on the upper and lower parts. Consequently, the burden applied on the AC joint was distributed similarly; thus, avoiding the slicing forces of the sutures.

As per the studied scores, the used maneuver had satisfactory outcomes in cases of acute AC joint dislocation. In comparison to pre-operation data, post-operative Dash and VAS scores were lower, whereas constant shoulder ratings were greater. This demonstrated that patients were convenient with this method. Two incidences of shoulder stiffness were noted during the follow-up.

In a related study, **Beris et al.** [27] treated acute acromioclavicular joint dislocation with a double-button fixation device. They examined 12 individuals, using the DASH, Constant, and VAS scores as well as the CC distance. There were no reports of osteoarthritis of the AC joint, CC calcification, osteolysis of the distal clavicle, or coracoid process. The mean DASH score dropped at the most recent follow-up, while the mean constant score increased compared to the mean pre-operative value of 34.4. The average VAS score dropped, and the average CC distance from the operated shoulder was comparable to the CC distance from the unoperated side. Their findings support the findings of the current study.

In 18 patients with acute AC joint dislocation, **Shin et al.** [28] investigated the post-operative consequences from arthroscopic CC reconstruction employing a single adjustable-loop length suspensory fixation device. Their findings demonstrated positive clinical outcomes following surgery. Within three months of surgery, radiographic scans revealed CC fixation failure of greater than 50% of the unaffected side for 33% of the patients. Eight patients [44%] reported surgical technical issues and complications related to the adjustable-loop-length suspensory fixation device.

Good clinical outcomes have been documented in numerous other investigations using these single metallic suspension devices attached at the isometric point of the CC ligament [1]; nevertheless, the potential of subsequent subluxation remains a concern [28]. Hardware displacement into the clavicle, coracoid, or both was the most often mentioned problem. According to **Scheibel et al.** [29], the rate of migration reached 89%. Additionally, many patients report ongoing postoperative discomfort from hardware irritation at the superior clavicle fixation site [30].

Limitations: the main limitation of the study is the small sample size; in addition, the

majority of patients had grade III AC dislocation, which restrict the generalization of these results regarding type VI and V. Finally, the duration of follow-up in this study is relatively short; thus, some complications may be appeared later.


Conclusion: The present study's findings indicate that the adjustable loop fixation device is an effective method for treating acute acromioclavicular joint dislocation and causes little harm to the soft tissues surrounding the CC ligaments.

Conflict of interests: None.

REFERENCES

1. Jeong JY, Chun YM. Treatment of acute high-grade acromioclavicular joint dislocation. *Clin Shoulder Elb.* 2020 Sep 1;23[3]:159-165. doi: 10.5397/cise.2020.00150.
2. Babhulkar A, Pawaskar A. Acromioclavicular joint dislocations. *Curr Rev Musculoskelet Med.* 2014 Mar;7(1):33-9. doi: 10.1007/s12178-013-9199-2.
3. Lee SJ, Yoo YS, Kim YS, Jang SW, Kim J, Kim SJ, et al. Arthroscopic Coracoclavicular Fixation Using Multiple Low-Profile Devices in Acute Acromioclavicular Joint Dislocation. *Arthroscopy.* 2019 Jan;35(1):14-21. doi: 10.1016/j.arthro.2018.07.007.
4. Rockwood C, Williams G, Young D. Disorders of the acromioclavicular joint. In: Rockwood CA, editor. *The shoulder.* 3rd ed. Philadelphia, PA: WB Saunders; 2004. pp. 521-95.
5. Kang C, Zhang J. Classification, Diagnosis, And Treatments for Acromioclavicular Joint Injury. *Highlights Sci Eng Technol.* 2022 Aug 17;8:448-53.
6. Cetinkaya E, Arıkan Y, Beng K, Mutlu H, Yalçınkaya M, Üzümcügil O. Bosworth and modified Phemister techniques revisited. A comparison of intraarticular vs extraarticular fixation methods in the treatment of acute Rockwood type III acromioclavicular dislocations. *Acta Orthop Traumatol Turc.* 2017 Dec;51(6):455-458. doi: 10.1016/j.aott.2017.09.002.
7. Pan Z, Zhang H, Sun C, Qu L, Cui Y. Arthroscopy-assisted reconstruction of coracoclavicular ligament by Endobutton fixation for treatment of acromioclavicular joint dislocation. *Arch Orthop Trauma Surg.* 2015 Jan;135(1):9-16. doi: 10.1007/s00402-014-2117-2.
8. Yin J, Yin Z, Gong G, Zhu C, Sun C, Liu X. Comparison of hook plate with versus without double-tunnel coracoclavicular ligament reconstruction for repair of acute acromioclavicular joint dislocations: A prospective randomized controlled clinical trial. *Int J Surg.* 2018 Jun;54(Pt A):18-23. doi: 10.1016/j.ijssu.2018.04.017.
9. Sirin E, Aydin N, Mert Topkar O. Acromioclavicular joint injuries: diagnosis, classification and ligamentoplasty procedures. *EFORT Open Rev.* 2018 Jul 17;3(7):426-433. doi: 10.1302/2058-5241.3.170027.
10. Torkaman A, Bagherifard A, Mokhatri T, Haghighi MH, Monshizadeh S, Taraz H, Hasanvand A. Double-button Fixation System for Management of Acute Acromioclavicular Joint Dislocation. *Arch Bone Jt Surg.* 2016 Jan;4(1):41-6. PMID: 26894217.
11. Ibrahim EF, Forrest NP, Forester A. Bilateral weighted radiographs are required for accurate classification of acromioclavicular separation: an observational study of 59 cases. *Injury.* 2015 Oct; 46(10):1900-5. doi: 10.1016/j.injury.2015.06.028.
12. Maier D, Jaeger M, Reising K, Feucht MJ, Südkamp NP, Izadpanah K. Injury patterns of the acromioclavicular ligament complex in acute acromioclavicular joint dislocations: a cross-sectional, fundamental study. *BMC Musculoskelet Disord.* 2016 Sep 6;17(1):385. doi: 10.1186/s12891-016-1240-3.
13. Kim SH, Lee YH, Shin SH, Lee YH, Baek GH. Outcome of conjoined tendon and coracoacromial ligament transfer for the treatment of chronic type V acromioclavicular joint separation. *Injury.* 2012 Feb;43(2):213-8. doi: 10.1016/j.injury.2011.08.003.
14. Leidel BA, Braunstein V, Kirchhoff C, Pilotto S, Mutschler W, Biberthaler P. Consistency of long-term outcome of acute Rockwood grade III acromioclavicular joint separations after K-wire transfixation. *J Trauma.* 2009 Jun;66(6):1666-71. doi: 10.1097/TA.0b013e31818c1455.
15. Constant CR, Murley AH. A clinical method of functional assessment of the shoulder. *Clin Orthop Relat Res.* 1987 Jan;(214):160-4. PMID: 3791738.
16. De Smet L. The DASH questionnaire and score in the evaluation of hand and wrist disorders. *Acta Orthop Belg.* 2008 Oct;74(5):575-81. PMID: 19058688.
17. Martetschläger F, Kraus N, Scheibel M, Streich J, Venjakob A, Maier D. The Diagnosis and Treatment of Acute Dislocation of the Acromioclavicular Joint. *Dtsch Arztebl Int.* 2019 Feb 8;116(6):89-95. doi: 10.3238/arztebl.2019.0089.

18. Koukakis A, Manouras A, Apostolou CD, Lagoudianakis E, Papadima A, Triantafillou C, et al. Results using the AO hook plate for dislocations of the acromioclavicular joint. *Expert Rev Med Devices*. 2008 Sep;5(5):567-72. doi: 10.1586/17434440.5.5.567.
19. Mlasowsky B, Brenner P, Düben W, Heymann H. Repair of complete acromioclavicular dislocation (Tossy stage III) using Balsa's hook plate combined with ligament sutures. *Injury*. 1988 Jul;19(4):227-32. doi: 10.1016/0020-1383(88)90031-9.
20. Paavolainen P, Björkenheim JM, Pauku P, Slätis P. Surgical treatment of acromioclavicular dislocation: a review of 39 patients. *Injury*. 1983 Mar;14(5):415-20. doi: 10.1016/0020-1383(83)90092-x.
21. Hellmich A, Sievers U. Operative repair of acromioclavicular separation via transcutaneous Kirschner wire fixation: results of follow-up examinations in 45 patients. *Aktuelle Traumatol*. 1988;18(3):9-13.
22. Costic RS, Labriola JE, Rodosky MW, Debski RE. Biomechanical rationale for development of anatomical reconstructions of coracoclavicular ligaments after complete acromioclavicular joint dislocations. *Am J Sports Med*. 2004 Dec;32(8):1929-36. doi: 10.1177/0363546504264637.
23. Harris RI, Vu DH, Sonnabend DH, Goldberg JA, Walsh WR. Anatomic variance of the coracoclavicular ligaments. *J Shoulder Elbow Surg*. 2001 Nov-Dec;10(6):585-8. doi: 10.1067/mse.2001.118480.
24. Dimakopoulos P, Panagopoulos A, Syggelos SA, Panagiotopoulos E, Lambiris E. Double-loop suture repair for acute acromioclavicular joint disruption. *Am J Sports Med*. 2006 Jul;34(7):1112-9. doi: 10.1177/0363546505284187.
25. Wellmann M, Zantop T, Weimann A, Raschke MJ, Petersen W. Biomechanical evaluation of minimally invasive repairs for complete acromioclavicular joint dislocation. *Am J Sports Med*. 2007 Jun;35(6):955-61. doi: 10.1177/0363546506298585.
26. Ponce BA, Millett PJ, Warner JJ. Acromioclavicular joint instability—reconstruction indications and techniques. *Oper Tech Sports Med*. 2004 Jan 1;12(1):35-42.
27. Beris A, Lykissas M, Kostas-Agnantis I, Vekris M, Mitsionis G, Korompilias A. Management of acute acromioclavicular joint dislocation with a double-button fixation system. *Injury*. 2013 Mar;44(3):288-92. doi: 10.1016/j.injury.2013.01.002.
28. Shin SJ, Kim NK. Complications after arthroscopic coracoclavicular reconstruction using a single adjustable-loop-length suspensory fixation device in acute acromioclavicular joint dislocation. *Arthroscopy*. 2015 May;31(5):816-24. doi: 10.1016/j.arthro.2014.11.013.
29. Scheibel M, Dröschel S, Gerhardt C, Kraus N. Arthroscopically assisted stabilization of acute high-grade acromioclavicular joint separations. *Am J Sports Med*. 2011 Jul;39(7):1507-16. doi: 10.1177/0363546511399379.
30. Woodmass JM, Esposito JG, Ono Y, Nelson AA, Boorman RS, Thornton GM, Lo IK. Complications following arthroscopic fixation of acromioclavicular separations: a systematic review of the literature. *Open Access J Sports Med*. 2015 Apr 10;6:97-107. doi: 10.2147/OAJS.M.S73211.



International Journal

<https://ijma.journals.ekb.eg/>

Print ISSN: 2636-4174

Online ISSN: 2682-3780

of Medical Arts