



Losartan prevents methotrexate-induced liver and lung injury in rats via targeting PPAR- γ /TGF- β 1/SMAD3 and Nrf2/redox signaling

Noha A.T. Abbas¹, Shaimaa S. El-Sayed², Samaa Salah Abd El-Fatah³, Walaa M. Sarhan^{4,5}, Omnia Sarhan⁶, Eman M. A. Abdelghany³, Shireen S. Mahmoud^{1,*}

¹Department of Clinical Pharmacology, Faculty of Medicine, Zagazig University, Zagazig, Egypt.

²Department of Pharmacology and Toxicology, Faculty of Pharmacy, Zagazig University, Zagazig, Egypt.

³Department of Human Anatomy and Embryology, Faculty of Medicine, Zagazig University, Zagazig, Egypt.

⁴Department of Medical Biochemistry and Molecular Biology, Faculty of Medicine, Zagazig University, Zagazig, Egypt.

⁵Wake Forest Institute of Regenerative Medicine (WFIRM), NC, USA.

⁶Department of Pharmaceutics, Faculty of Pharmacy, Badr university, Cairo, Egypt.

* Correspondence:

Author name: Shireen S. Mahmoud

Affiliation and address:
Department of Clinical Pharmacology, Faculty of Medicine, Zagazig University, Zagazig, 44519, Egypt

Email:
SSOsman@medicine.zu.edu.eg
ORCID iD: [0000-0001-6592-9708](https://orcid.org/0000-0001-6592-9708)

Submit Date 2022-11-08 11:06:18
Revise Date 2022-11-12 20:35:53
Accept Date 2022-11-14 19:04:44

ABSTRACT

Background: Despite high efficacy-to-toxicity ratio of chemotherapeutic agent, methotrexate, toxicity remains a major concern that limits its use. Inflammatory, oxidative stress and fibrotic pathways are implicated in methotrexate-induced injury. This study aims to investigate the ability of losartan to limit methotrexate-induced liver and lung injury and to elucidate the possible underlying mechanisms.

Methods: Liver and lung injury was induced in adult male Wistar rats via methotrexate *ip* injection twice weekly for 4 weeks (0.5mg/kg), animals were divided into group1 (control) where rats received saline *ip* twice weekly with daily vehicles for 4 weeks; group 2 to 4 included rats treated with methotrexate and began to receive drugs or vehicles concurrently, where in group2 rats received vehicles daily, whereas in group3 rats received losartan at 10mg/kg/day by gavage and those of group4 received both losartan and bisphenol-A-diglycidyl ether (BADGE, 30mg/kg). Circulating liver enzymes, histological examination of liver and lung as well as peroxisome proliferator-activated receptor- γ (PPAR- γ)/transforming growth factor- β (TGF- β)/SMAD3 and nuclear factor (erythroid-derived2)-like2 (Nrf2)/antioxidants pathways were investigated.

Results: Losartan ameliorated methotrexate-induced hepatic and pulmonary injury manifested by improved circulating liver enzymes, restoration of normal liver and lung histology, upregulated PPAR- γ , suppressed TGF- β /SMAD3 signaling while activated Nrf2-mediated antioxidant defenses and reduced lipid peroxidation biomarker malondialdehyde. Losartan effects were abrogated on concurrent use of BADGE, a selective PPAR- γ antagonist.

Conclusions: Losartan's antifibrotic effect via suppression of TGF- β /SMAD3 profibrotic signaling and antioxidant potentials through activation of Nrf2/antioxidant pathway are more likely attributed to PPAR- γ induction. This suggests the usefulness of losartan in limiting methotrexate-associated multiorgan injury.

Keywords

Methotrexate; liver injury; lung injury; losartan; PPAR- γ



1 INTRODUCTION

Methotrexate is an antineoplastic medication that acts as dihydrofolate reductase inhibitor and exhibits efficiency against many disorders including cancers, inflammatory disorders, and rheumatoid arthritis [1]. Methotrexate is known to have favorable efficacy/toxicity ratios, yet toxicity is still a major concern and limits its use [2]. Patients on methotrexate-therapy usually experience adverse reactions, including nausea,

stomatitis, blood toxicity, hepatotoxicity, and pulmonary problems [2]. Methotrexate-induced hepatotoxicity is manifested by augmented aminotransferases, hepatic steatosis which further progresses to fibrosis, and cirrhosis; and this may be attributable to depleted folate stores in liver upon methotrexate-therapy [3]. Pulmonary toxicity is another complication of methotrexate-therapy; as methotrexate was reported to induce asthma,

alveolar epithelial injury, pneumonitis and pulmonary fibrosis [4].

Overproduction of reactive oxygen species (ROS) together with disrupted antioxidant defenses is a key element in methotrexate-induced multiorgan toxicities [5]. ROS production activates nuclear factor (erythroid-derived 2)-like 2 (Nrf2) translocation with consequent expression of antioxidant proteins; thus it can be targeted to alleviate methotrexate adverse effects [6]. Another possible target is peroxisome proliferator-activated receptor- γ (PPAR- γ), which is a ligand-stimulated transcription factor that has a pivotal role in modulating inflammation [7] and oxidative stress [8]. Further, PPAR- γ exerts antifibrotic effects by blocking transforming growth factor- β 1 (TGF- β 1)/Smad3 signaling [9]. Interestingly, PPAR- γ is adversely downregulated with methotrexate therapy [6]; this contributes to its deleterious outcomes.

Ample evidence indicates the role of angiotensin II (Ag II) in the regulation of fibrotic responses to tissue injury including stimulation of fibroblast proliferation, procollagen production and epithelial cell apoptosis via binding to Ang II type I receptor (AT1). Ag II plays an essential role in the initiation and maintenance of hepatic and lung fibrosis [10, 11]. A typical AT1-receptor blocker (ARB), losartan, which has long been used as antihypertensive agent also exerts hepatoprotective [12] and renoprotective [13] effects as well as alleviation of osteoarthritis [14] which all possibly attributed to its PPAR- γ activation.

Whether or not losartan confers hepato- and/or pulmonary protections against methotrexate as well as the possible underlying mechanisms remain scarcely investigated. In the current study, it was hypothesized that losartan can prevent methotrexate-induced hepatotoxicity and pulmonary toxicity via modulating oxidative stress and profibrotic pathways. Further, the current study aimed at scrutinizing the implication of PPAR- γ induction in losartan-conferred protection either in liver or lung. In endeavor to achieve that, an experimental model of methotrexate-chronic injury in rats was utilized herein, where losartan beneficial effects were investigated. Further, PPAR- γ involvement in losartan-conveyed effects was inspected via employing PPAR- γ antagonist, bisphenol-A-diglycidyl ether (BADGE).

2 METHODS

2.1. Experimental Animals

Twenty-four adult male Wistar rats weighing 200 ± 20 g/rat were purchased from the animal house of Faculty of Veterinary Medicine, Zagazig University, Egypt. Rats were housed in plastic

cages with wood shave bedding (6 rats/cage) with maintenance of standard conditions of temperature, humidity, and 12 hours light/dark cycle. Rats received a standard diet and water *ad libitum* and were acclimatized for one week prior to experiment.

2.2 Ethical Statement

The current study protocols including animal handling and experiments were approved by Ethical Committee for Animal Handling at Zagazig University (ECAHZU) with approval number (ZU-IACUC/3/F/83/2022), and this is in accordance with the recommendations of the Weather all report and National Institutes of Health guide for the care and use of Laboratory animals.

2.3 Drugs and Chemicals

Methotrexate was obtained from Minapharm Pharmaceuticals (Cairo, Egypt), while losartan was obtained from Hikma Specialized Pharmaceutical Company (Cairo, Egypt). BADGE and dimethyl sulfoxide (DMSO) were purchased from Sigma-Aldrich (Cairo, Egypt). 10% DMSO in phosphate buffered saline (PBS) was used as a vehicle for BADGE.

2.4 Induction of methotrexate chronic toxicity

Following the week of acclimatization, rats received methotrexate at 0.5 mg/kg, *ip*, twice weekly for 4 weeks [15], while rats assigned for control group received equal volume of saline *ip* at the same time points.

2.5 Experimental Design

Rats were randomly allocated to four groups (n=6 per group) as follows: **group 1** (control): rats received vehicles daily (distilled H₂O by gavage and 10% DMSO in PBS *ip*); **group 2 to 4** included rats subjected to methotrexate toxicity and began to receive drugs or vehicles concurrently with methotrexate administration where **group 2** (methotrexate + Vehicle), rats received vehicles daily; **group 3** (methotrexate + losartan), rats received losartan at 10 mg/kg/day by gavage [16]; **group 4** (methotrexate + losartan +BADGE): rats received losartan at 10 mg/kg/day by gavage with daily *ip* injection of BADGE at 30mg/kg dissolved in 10% DMSO in PBS [17]. Vehicles and treatments were given daily for 4 successive weeks.

2.6 Blood and Tissue Sampling

By the end of experiment, blood samples were collected in heparinized tubes from retro-orbital plexus under light anesthesia with sodium pentobarbital (50 mg/kg, *ip*) [18]. Blood samples were then centrifuged at 5000 rpm for 15 min at 4°C, then serum was aspirated and stored at -80°C for determination of liver enzymes.

Animals were euthanized by carotid exsanguination followed by thoraco-abdominal incision to excise both lungs and liver. Half of the specimens was fixed in 10% neutral formol saline to be further processed for histopathological and immunohistochemical examination. Prefixed liver and lung specimens were processed in ascending grades of alcohol (50%, 70%, 90% and 95%) to be dehydrated, kept in each for one hour. Later, specimens were kept in absolute alcohol (100%) for one hour and this step was repeated once more, then cleared in xylene, embedded in soft paraffin wax at 55°C for 2 hours and in hard paraffin at 60°C for another 2 hours. The other half of specimens was prepared for biochemical analysis. Lung samples were homogenized in 0.9% cold saline while liver samples were homogenized in 50 mM cold potassium phosphate buffer (pH 7.4). Homogenates were then centrifuged at 10,000 rpm at 4°C for 15 minutes, and the supernatants were then stored at -80°C to be used in further analysis.

2.7 Biochemical Analysis

Serum levels of aspartate aminotransferase (AST) and alanine aminotransferase (ALT) were determined using colorimetric kits obtained from Spectrum Diagnostics (Cairo, Egypt). Serum level of γ -glutamyltransferase (GGT) was assessed using a spectrophotometric, kinetic assay kit from Greiner Diagnostics (Langenthal, Switzerland). In liver and lung homogenates, PPAR- γ , profibrotic marker TGF- β and its downstream SMAD3 levels were measured using rat ELISA Kits purchased from LifeSpan Biosciences, Inc. (WA, USA) as per manufacturer's instructions. Nrf2, a key regulator for cellular resistance to oxidative stress, and its regulated enzyme HO-1 were determined using rat ELISA kits supplied from MyBioSource (CA, USA). Antioxidant enzyme, superoxide dismutase (SOD), reduced glutathione (GSH) and malondialdehyde (MDA), as a marker of lipid peroxidation, were measured using commercially available colorimetric kit from Biodiagnostic (Cairo, Egypt), all procedures were conducted as per manufacturer's instructions.

2.8 Histopathological and immunohistochemical studies:

Sections, of 5 μ m thickness, were sliced from paraffin blocks, deparaffinized and stained with hematoxylin and eosin (H&E). For liver sections, scores from 1 (minimal), 2 (mild), 3 (moderate), to 4 (marked) were given to evaluate each of the following parameters: hepatic steatosis, hydropic degeneration, hepatocyte apoptosis and cellular infiltration [19]. For lung sections, scores from 0 (negligible or minimal), 1 (mild), 2 (moderate), 3 (severe) to 4 (maximal) were given to evaluate each

of the following parameters: lung atelectasis, edema, infiltration, hemorrhage [20].

For Nrf2 immunostaining, deparaffinized sections of either liver or lung were incubated overnight with monoclonal Nrf2 antibody (1:100). Following that, sections were treated with a secondary antibody coupled to biotin and a streptavidin-enzyme conjugate (LSAB System HRP) from Biocare (CA, USA). Brown color was developed by adding 3,3'-diaminobenzidine purchased from Dako (CA, USA), then, hematoxylin was used as a counterstain [21]. Image J analysis software (NIH, USA) was used to measure the area % of the Nrf2/unit area. A mean of 10 readings was recorded from 5 serial sections from slides of each animal in each group. Examination and photography were conducted using light microscope LEICA DM500 at the Anatomy Department, Faculty of Medicine, Zagazig University

2.9 Statistical analysis

For data analysis, GraphPad Prism software, version 9.4.1 (681) (CA, USA) was used. Data are depicted as bar graphs representing mean \pm standard error of the mean (SEM). One-way analysis of variance (ANOVA) was used for group comparison whereas post hoc Tukey test was used for pairwise comparisons. A significant difference was considered for values of $p < 0.05$.

3 RESULTS

3.1 Effect of losartan on liver function biomarkers

As demonstrated in **Figure 1**, losartan daily treatment significantly decreased serum levels of AST, ALT and GGT ($p < 0.0001$), compared to methotrexate group, yet still significantly higher compared to control group ($p < 0.05$). BADGE coadministration with losartan resulted in significant increase of circulating levels of liver enzymes (AST, ALT and GGT) as compared to the group treated with losartan alone ($p < 0.0001$).

3.2 Histopathologic findings

As shown in **Figure 2**, H&E-stained liver section from methotrexate group exhibited remarkable disturbance in hepatic architecture showing hepatocytes with vacuolated cytoplasm around congested central vein, inflammatory cell infiltration, fibrosis close to congested portal vein, hydropic degeneration, binucleated cells and ballooned hepatocytes with steatosis. Liver sections from losartan-treated rats demonstrated nearly normal histologic features except for few dark stained nuclei and fatty degeneration (steatosis), whereas those from losartan plus BADGE-treated rats exhibited deteriorated architecture close to those of untreated methotrexate group. H&E-stained lung sections

were displayed in **Figure 3**, where lung sections from methotrexate group and those treated with a combination of losartan and BADGE showed destruction of the bronchioles' epithelial lining, disruption of the surrounding musculosa, and thickened interalveolar septum. Some specimens showed severe interstitial and alveolar hemorrhage. Further, diverse inflammatory cells were found inside the interstitial tissue, especially in the area around the bronchovascular bundle and edematous areas. There were several dilated emphysematous alveoli, thickened blood vessel walls, and collapsed alveoli. Lung sections from losartan-treated rats retained nearly similar features to those of control group except for few infiltrated areas and collapsed alveoli. Significant statistical difference in pathologic scoring of hepatic and lung tissues were found between study groups as depicted in **Figure 2** and **3** respectively.

3.3 Effect of losartan on PPAR- γ / TGF- β / SMAD3 signaling

Methotrexate group demonstrated a significant decline in PPAR- γ while augmented TGF- β and SMAD3 as compared to control ($p < 0.0001$). Losartan significantly increased PPAR- γ while reduced TGF- β and SMAD3 as compared to untreated methotrexate with its action being reversed upon coadministration of BADGE ($p < 0.0001$). Similar findings were encountered in either liver (**Figure 4**) or lung (**Figure 5**).

3.4 Effect of losartan on Nrf2/HO-1/oxidative stress

A pronounced status of oxidative stress was observed upon methotrexate treatment either in liver (**Figure 6**) or lung (**Figure 7**). Methotrexate group manifested significant depletion in Nrf2 as presented by immunohistochemical staining against monoclonal antibodies of Nrf2, both liver and lung sections revealed few immunoreactions against monoclonal antibodies of Nrf2 and similar results were found with BADGE and losartan combination. Contrarily, both control and losartan treated exhibited abundant Nrf2 immuno-positive hepatocyte and pneumocytes. Immunostaining finding for Nrf2 were further supported by biochemical analysis. Further, Nrf2-regulated HO-1 level was significantly declined in liver and lung from methotrexate group indicating reduced antioxidant activity which was further supported by reduced SOD and GSH while augmented MDA as compared to control ($p < 0.0001$). Losartan treatment significantly alleviated oxidative stress via augmenting HO-1, SOD and GSH while mitigating MDA levels in both liver and lung as compared to untreated methotrexate group ($p < 0.0001$). Interestingly, PPAR- γ antagonist (BADGE) abolished losartan-induced attenuation of oxidative stress.

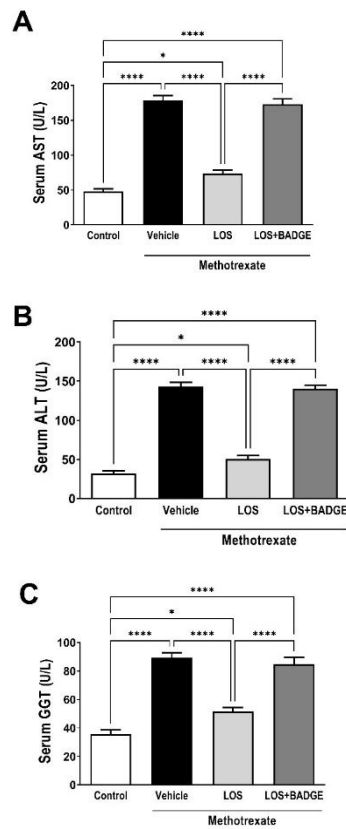


Figure 1 Impact of 4 weeks treatment with losartan (LOS, 10 mg/kg/day, gavage) alone or with bisphenol-A-diglycidyl ether (BADGE, 30 mg/kg/day, *ip*) on liver function biomarkers in serum expressed as aspartate aminotransferase (AST, **A**), alanine aminotransferase (ALT, **B**) and γ -glutamyltransferase (GGT, **C**) in rats concurrently received *ip* methotrexate (0.5 mg/kg, twice weekly) for the same period. One-way ANOVA followed by Tukey's test for multiple comparisons were used for analysis. Values are represented as the mean \pm SEM (n= 6/group). ****p<0.0001, ***p<0.001, **p<0.01 and *p<0.05.

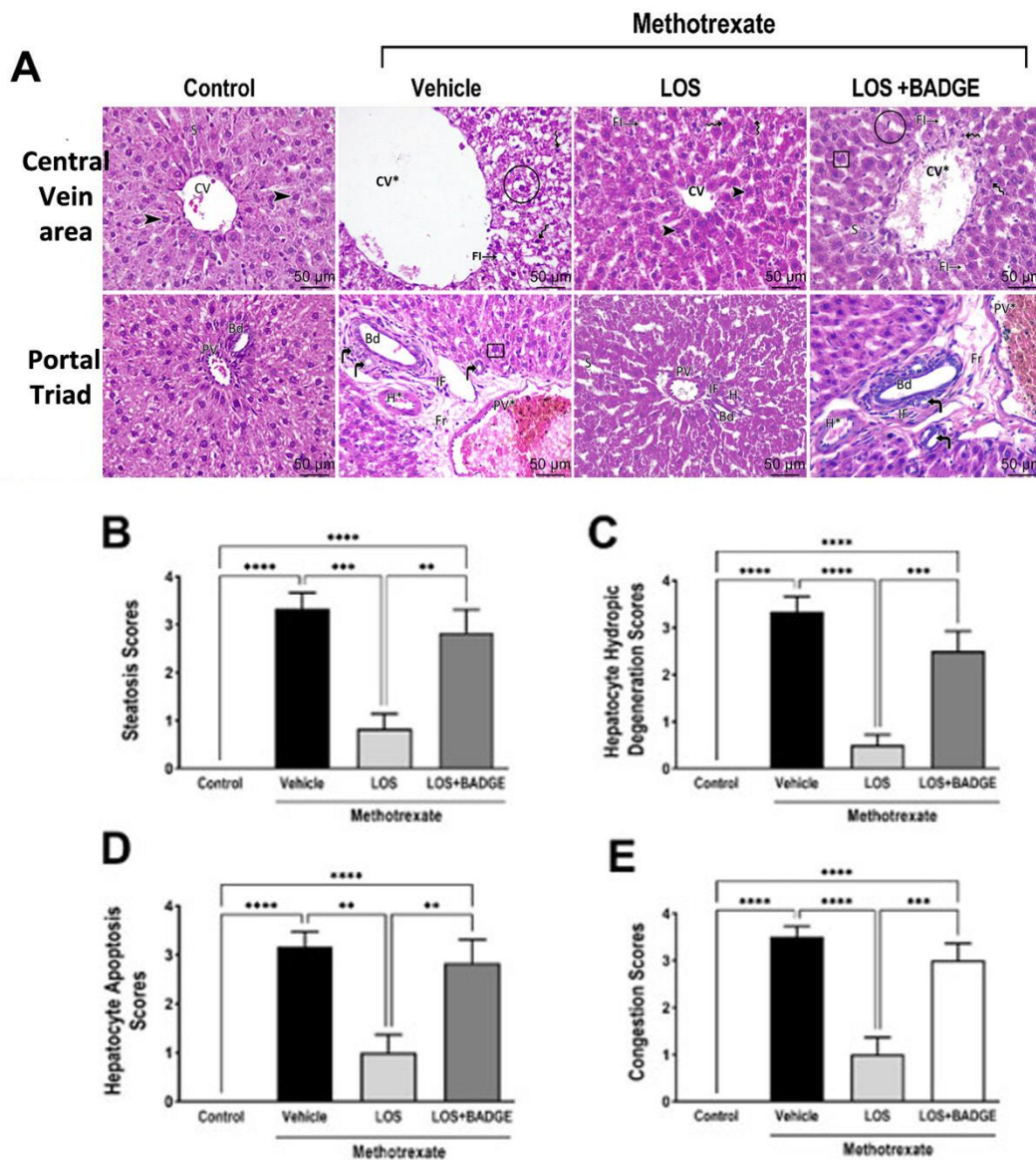


Figure 2 Impact of 4 weeks treatment with losartan (LOS, 10 mg/kg/day, gavage) alone or with bisphenol-A-diglycidyl ether (BADGE, 30 mg/kg/day, *ip*) on liver histology of rats concurrently received *ip* methotrexate (0.5 mg/kg, twice weekly) for the same period. Representative images of liver tissues from central vein area and portal triad are displayed (A), CV, central vein; arrow heads, rounded vesicular nuclei; S, sinusoids; PV, portal vein; H, hepatic artery; Bd, bile duct; circle, swollen hepatocytes with highly hydropic degeneration; zigzag arrows, regular and darkly stained nuclei; FI, hepatic steatosis; CV*, marked dilated congested central vein; curved arrows, proliferated bile ductulus; boxed area, binucleated cells; PV*, dilated and congested portal vein; Fr, fibrosis; IF, cellular infiltration and H*, thickened wall hepatic artery (Scale bar = 50 μ m, x400). Scores for steatosis (B), hepatocyte hydropic degeneration (C), hepatocyte apoptosis (D) and congestion (E) are shown. One-way ANOVA followed by Tukey's test for multiple comparisons were used for analysis. Values are represented as the mean \pm SEM (n= 6/group). ****p<0.0001, ***p<0.001, **p<0.01 and *p<0.05.

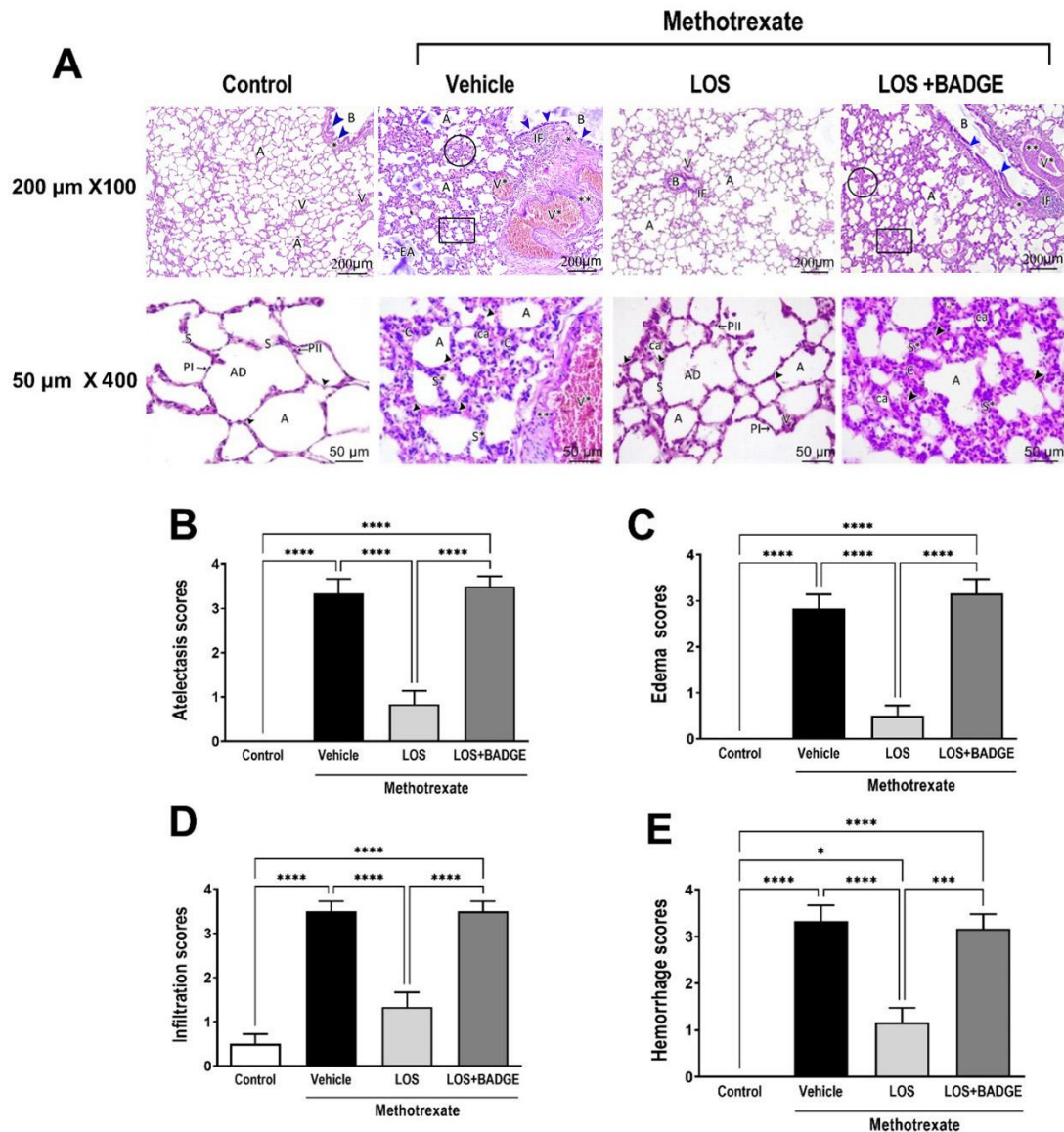


Figure 3 Impact of 4 weeks treatment with losartan (LOS, 10 mg/kg/day, gavage) alone or with bisphenol-A-diglycidyl ether (BADGE, 30 mg/kg/day, *ip*) on lung histology of rats concurrently received *ip* methotrexate (0.5 mg/kg, twice weekly) for the same period. Representative images of lung tissues using 200 μ m x 100 and 50 μ m x 400 scales are displayed (A); B, bronchiole; arrowheads (blue), respiratory epithelium; asterisk, thin smooth muscles fibers; A, alveoli; V, tiny vessels; AD, alveolar duct; S, single-cell-layered interalveolar septum; PI, squamous type I alveolar cells; PII, type II alveolar cells; IF, cellular infiltration; circled area, edema; EA, some dilated emphysematous alveoli; boxed region or ca, collapsed alveoli; V*, congested and dilated blood vessels; double asterisks, thickened smooth muscle fibers; C, consolidation foci; S*, thick protruding interalveolar septa; arrow heads (in 50 μ m x 400), extravasation of red blood cells. Scores for atelectasis (B), edema (C), infiltration (D) and hemorrhage (E) are shown. One-way ANOVA followed by Tukey's test for multiple comparisons were used for analysis. Values are represented as the mean \pm SEM (n= 6/group). ****p<0.0001, ***p<0.001, **p<0.01 and *p<0.05.

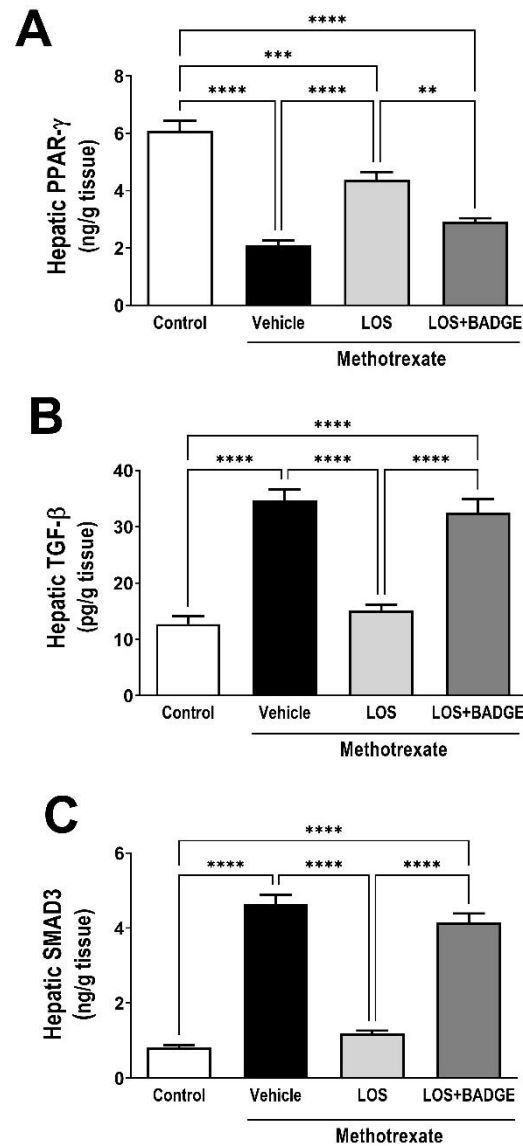


Figure 4 Impact of 4 weeks treatment with losartan (LOS, 10 mg/kg/day, gavage) alone or with bisphenol-A-diglycidyl ether (BADGE, 30 mg/kg/day, *ip*) on peroxisome proliferator activated receptor- γ (PPAR- γ , **A**) and profibrotic markers including transforming growth factor- β (TGF- β , **B**) and SMAD3 (**C**) in liver tissues from rats concurrently received *ip* methotrexate (0.5 mg/kg, twice weekly) for the same period. One-way ANOVA followed by Tukey's test for multiple comparisons were used for analysis. Values are represented as the mean \pm SEM (n= 6/group). ****p<0.0001, ***p<0.001, **p<0.01 and *p<0.05.

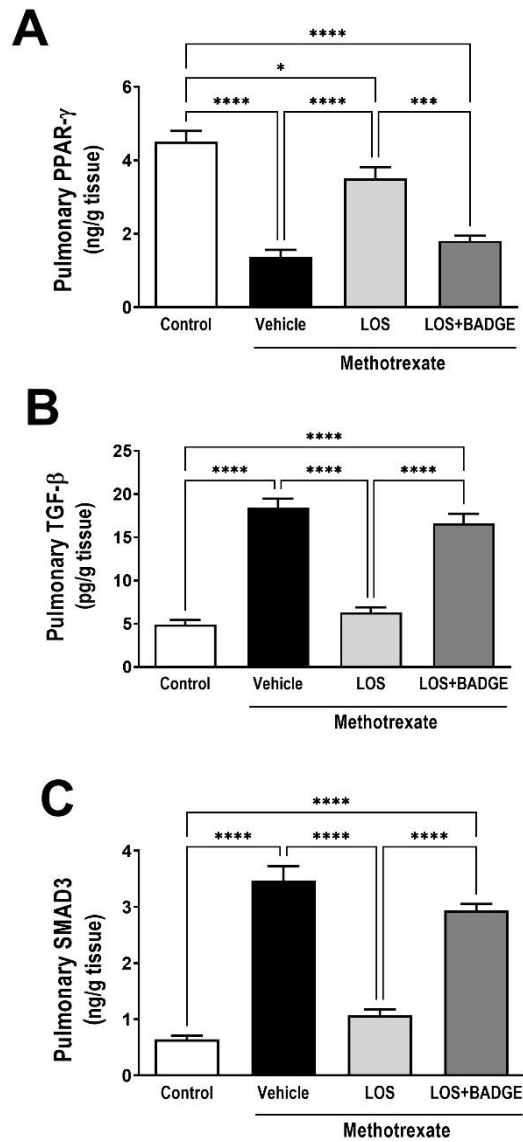


Figure 5 Impact of 4 weeks treatment with losartan (LOS, 10 mg/kg/day, gavage) alone or with bisphenol-A-diglycidyl ether (BADGE, 30 mg/kg/day, *ip*) on peroxisome proliferator activated receptor- γ (PPAR- γ , **A**) and profibrotic markers including transforming growth factor- β (TGF- β , **B**) and SMAD3 (**C**) in lung tissues from rats concurrently received *ip* methotrexate (0.5 mg/kg, twice weekly) for the same period. One-way ANOVA followed by Tukey's test for multiple comparisons were used for analysis. Values are represented as the mean \pm SEM (n= 6/group). ****p<0.0001, ***p<0.001, **p<0.01 and *p<0.05.

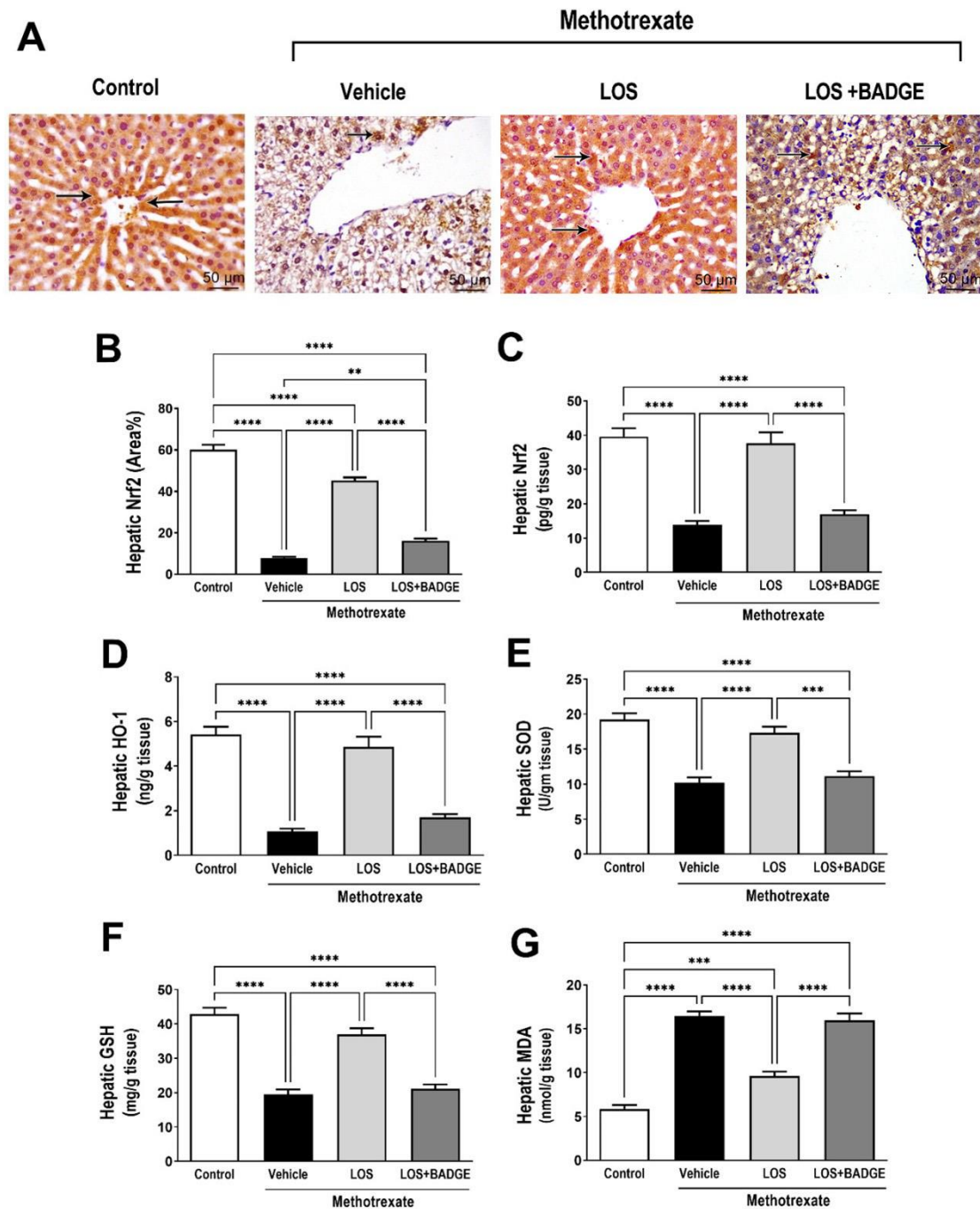


Figure 6 Impact of 4 weeks treatment with losartan (LOS, 10 mg/kg/day, gavage) alone or with bisphenol-A-diglycidyl ether (BADGE, 30 mg/kg/day, *ip*) on hepatic oxidative stress in rats concurrently received *ip* methotrexate (0.5 mg/kg, twice weekly) for the same period. Representative images for nuclear factor (erythroid-derived 2)-like 2 (Nrf2) immunohistochemical staining in liver tissues with arrows signifying dark brown immunopositively stained cells, scale bar 50 μ m x 400 (A), area percent of positive staining of Nrf2 (B), liver content from biochemical measurements of Nrf2 (C), hemeoxygenase-1 (HO-1, D), superoxide dismutase (SOD, E), reduced glutathione (GSH, F) and malondialdehyde (MDA, G) are depicted. One-way ANOVA followed by Tukey’s test for multiple comparisons were used for analysis. Values are represented as the mean \pm SEM (n= 6/group). ****p<0.0001, ***p<0.001, **p<0.01 and *p<0.05.

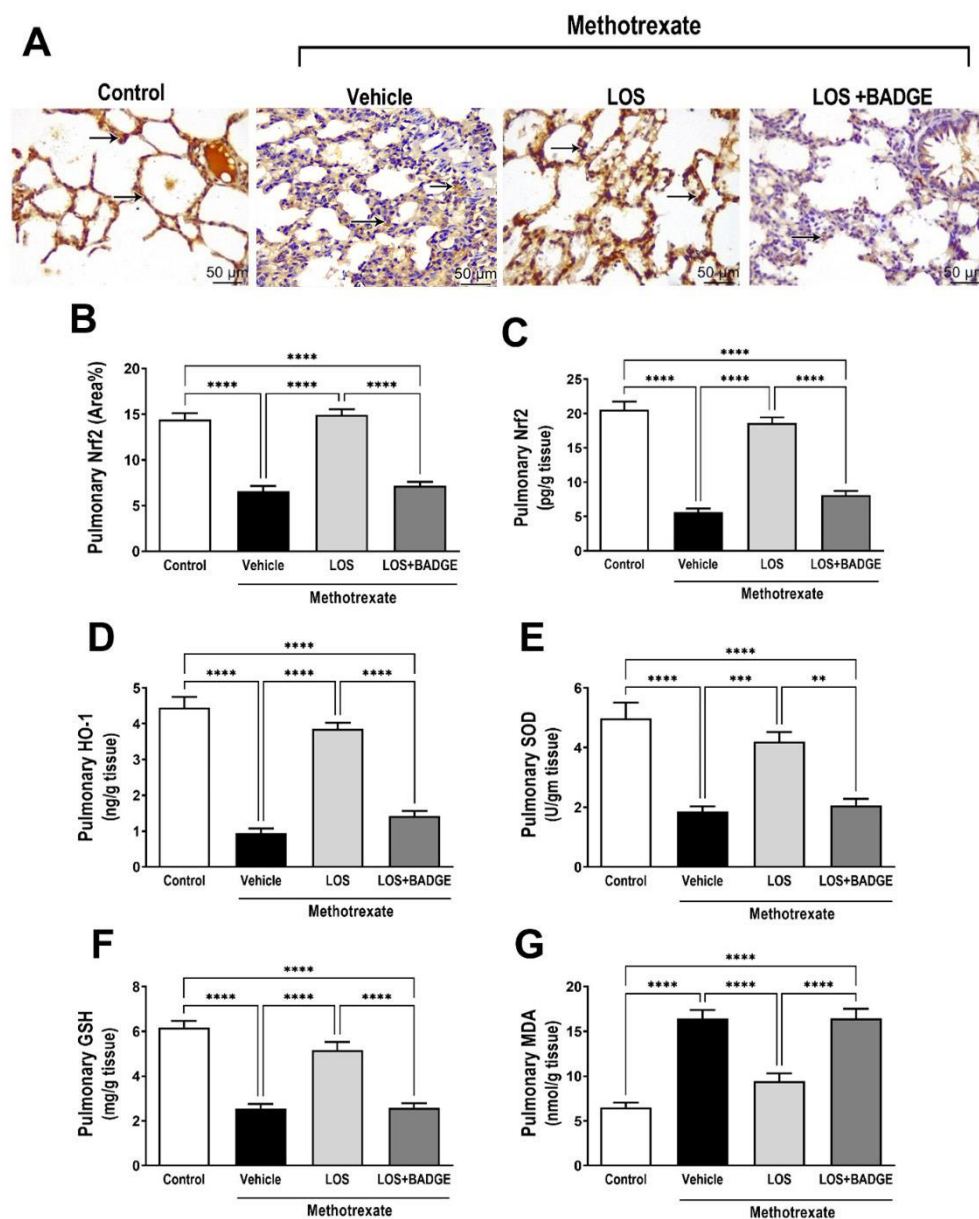


Figure 7 Impact of 4 weeks treatment with losartan (LOS, 10 mg/kg/day, gavage) alone or with bisphenol-A-diglycidyl ether (BADGE, 30 mg/kg/day, *ip*) on pulmonary oxidative stress in rats concurrently received *ip* methotrexate (0.5 mg/kg, twice weekly) for the same period. Representative images for nuclear factor (erythroid-derived 2)-like 2 (Nrf2) immunohistochemical staining in lung tissues with arrows signifying dark brown immunopositively stained cells, scale bar 50 μ m x 400 (A), area percent of positive staining of Nrf2 (B), lung content from biochemical measurements of Nrf2 (C), hemeoxygenase-1 (HO-1, D), superoxide dismutase (SOD, E), reduced glutathione (GSH, F) and malondialdehyde (MDA, G) are depicted. One-way ANOVA followed by Tukey's test for multiple comparisons were used for analysis. Values are represented as the mean \pm SEM (n= 6/group). ****p<0.0001, ***p<0.001, **p<0.01 and *p<0.05.

4 DISCUSSION

Multiorgan injury elicited by cytotoxic drugs such as methotrexate is a major concern in patients receiving it. Liver and lung are among affected organs and their dysfunction contributes to methotrexate-associated morbidity and mortality

[3, 4]. Understanding the pathophysiologic alterations associated with methotrexate helps in developing approaches to counteract the injury. Methotrexate injury is principally associated with ROS overproduction [5], PPAR- γ downregulation [6] and fibrosis [3, 4]. A typical ARB, losartan,

confers PPAR- γ -mediated hepatoprotection against ischemia reperfusion injury [12], suggesting it as a useful candidate in our study. To our knowledge, this is the first study to investigate whether losartan can ameliorate methotrexate-induced liver and lung injury or not, and further scrutinize the implicated mechanisms as well as if these are mediated by PPAR- γ activation giving an insight on TGF- β /SMAD3 signaling and redox sensitive transcription factor Nrf2.

Herein, methotrexate-induced hepatotoxicity was confirmed by augmented circulating liver enzymes and marked deterioration of liver histology. The current findings are consistent with a previous study which reported increased circulating liver enzymes in rheumatoid arthritis patients receiving methotrexate, indicating hepatocellular damage [22]. Others reported abnormal liver architecture and degenerative changes association with methotrexate [23]. Interestingly, losartan administration in methotrexate-treated rats almost retained normal liver histology and thus significantly mitigated the increase in circulating liver enzymes suggesting potent hepatoprotective potentials of losartan. Losartan exhibited hepatoprotective effects in other models of liver injury such as ischemia/reperfusion [12] and CCl₄ [11], consistent with our findings. Regarding lung injury, the current histological findings are in alignment with those seen in lung biopsies taken from patients complaining of respiratory problems while administrated methotrexate [24]. Herein, losartan improved lung histological features which is consistent with previous study of paraquat-induced pulmonary fibrosis [25].

To delineate the mechanisms underlying losartan conferred protective effect against methotrexate-induced fibrosis and oxidative stress damage in liver and lung, PPAR- γ /TGF- β /SMAD3 and Nrf2/HO-1 pathways were investigated. PPAR- γ activation triggers anti-inflammatory [7], antioxidant [8] as well as antifibrotic signaling [9] which are useful in modulating tissue injury. Several studies reported PPAR- γ antifibrotic potentials evidenced by effects of pioglitazone in CCL₄-induced hepatic fibrosis [26], rosiglitazone in cardiac fibrosis [27] and ciglitazone in a model of pulmonary fibrosis [28]. In this study, methotrexate treatment caused a significant decline in PPAR- γ in liver and lung tissues which is consistent with reported downregulated PPAR- γ in methotrexate hepatotoxicity model [6]. The antifibrotic potentials of PPAR- γ agonists are reflected by its ability to reduce TGF- β ₁/SMAD3 signaling as in adipocytic hepatic stellate cells [9] which is also in accordance with our findings,

where losartan treatment significantly attenuated methotrexate-induced downregulation of PPAR- γ and mitigated methotrexate-induced elevation of TGF- β ₁/SMAD3 in liver and lung; thus alleviating tissue injury as confirmed by histopathologic findings. Our findings agree with previous study demonstrated prophylactic losartan attenuation of colonic fibrosis progression through the inhibition of colonic expression of TGF- β [29] and another reported that losartan treatment preserved erectile function in rats via suppression of TGF- β ₁/SMAD pathway [30].

Another cellular protective pathway is Nrf2-mediated oxidative stress resistance, where Nrf2 upregulates cellular antioxidants expression. Upon activation by ROS, Nrf2 translocate into the nucleus, binds to antioxidant response element and initiates transcription of many antioxidative genes, including HO-1 [31]. Surplus production of ROS and downregulated Nrf2 is associated with methotrexate treatment as previously reported [31]. Further, oxidative stress has been implicated in hepatic and pulmonary toxic effect of methotrexate [15]. Herein, methotrexate-induced oxidative stress was confirmed by the declined Nrf2, HO-1, SOD and GSH as well as elevated MDA content in both liver and lung of methotrexate-treated rats suggesting ROS-induced tissue damage as they can attack lipids and disrupt membrane structure and function [5, 32].

In the current study, losartan significantly counteracted methotrexate evoked oxidative stress in liver and lung demonstrated by significant increase of hepatic and pulmonary Nrf2, HO-1, GSH and SOD levels while significant attenuation of MDA levels. These findings are consistent with a study reported reduced oxidative stress involvement in losartan conferred renoprotection in spontaneously hypertensive rats [33].

On the other hand, a selective PPAR- γ antagonist that was employed here (BADGE) significantly blocked losartan beneficial effect in methotrexate-treated rats either in lung or liver as manifested by suppressed PPAR- γ and Nrf2/HO-1 pathways. There is a crosstalk between Nrf2 and PPAR- γ pathways as they collaboratively trigger antioxidant defenses expression [34]. Via autoregulatory mechanisms Nrf2 and PPAR- γ mutually regulate each other as has been associated with suppressed oxidative stress and inflammation in rat models of hepatotoxicity [35] and acute lung injury [36]. Several studies targeted modulation of PPAR- γ and Nrf2 signaling for injury prevention as in bardoxolone methyl in ischemic acute kidney injury [37] and apigenin in non-alcoholic fatty liver [38].

In the current study, losartan not only activates PPAR- γ receptors but also upregulates its expression in hepatic and pulmonary tissues. Through PPAR- γ , losartan exerted antioxidant and anti-fibrotic effects, and this was confirmed by blocking PPAR- γ using BADGE which abolished antifibrotic and antioxidant effects of losartan and was further reflected by histological structural alterations of both liver and lung.

In summary, losartan successfully counteracted liver and lung injury associated with methotrexate therapy. In hepatic and pulmonary tissues, losartan upregulates PPAR- γ , suppressing TGF- β /SMAD3 profibrotic signaling while activating Nrf2/antioxidant pathway. Losartan conferred protection was reversed upon combination with BADGE. Collectively, losartan antifibrotic and antioxidant effects are likely mediated by PPAR- γ . This suggests the usefulness of losartan in limiting methotrexate-associated multiorgan injury, yet further clinical studies are needed.

Conflict of Interest

The authors declare no conflicts of interest, financial or otherwise.

Financial Disclosures: This research did not receive any specific grant from funding agencies in the public, commercial, or not-for-profit sectors.

5 REFERENCES

1. Chan ES, Cronstein BN. Mechanisms of action of methotrexate. *Bull Hosp Jt Dis.* 2013;71(Suppl 1):S5–S8.
2. Shea B, Swinden MV, Tanjong Ghogomu E, Ortiz Z, Katchamart W, Rader T, et al. Folic acid and folinic acid for reducing side effects in patients receiving methotrexate for rheumatoid arthritis. *Cochrane database syst rev.* 2013;5 CD000951.
3. Conway R, Carey JJ. Risk of liver disease in methotrexate treated patients. *World J Hepatol.* 2017;9(26):1092–1100.
4. Ohbayashi M, Suzuki M, Yashiro Y, Fukuwaka S, Yasuda M, Kohyama N, et al. Induction of pulmonary fibrosis by methotrexate treatment in mice lung in vivo and in vitro. *J Toxicol Sci.* 2010;35(5):653–61.
5. Herman S, Zurgil N, Deutsch M. Low dose methotrexate induces apoptosis with reactive oxygen species involvement in T lymphocytic cell lines to a greater extent than in monocytic lines. *Inflamm Res.* 2005;54(7):273–80.
6. Mahmoud AM, Hussein OE, Hozayen WG, Abd El-Twab SM. Methotrexate hepatotoxicity is associated with oxidative stress, and down-regulation of PPAR γ and Nrf2: Protective effect of 18 β -Glycyrrhetic acid. *Chem Biol Interact.* 2017;270:59–72.
7. Cuzzocrea S, Pisano B, Dugo L, Ianaro A, Maffia P, Patel NSA, et al. Rosiglitazone, a ligand of the peroxisome proliferator-activated receptor- γ , reduces acute inflammation. *Eur J Pharmacol.* 2004;483(1):79–93.
8. Chung SS, Kim M, Youn BS, Lee NS, Park JW, Lee IK, et al. Glutathione peroxidase 3 mediates the antioxidant effect of peroxisome proliferator-activated receptor gamma in human skeletal muscle cells. *Mol Cell Biol.* 2009;29(1):20–30.
9. Zhao C, Chen W, Yang L, Chen L, Stimpson SA, Diehl AM. PPARgamma agonists prevent TGFbeta1/Smad3-signaling in human hepatic stellate cells. *Biochem Biophys Res Commun.* 2006;350(2):385–91.
10. Shenoy V, Ferreira AJ, Qi Y, Fraga-Silva RA, Díez-Freire C, Dooies A, et al. The angiotensin-converting enzyme 2/angiogenesis-(1–7)/Mas axis confers cardiopulmonary protection against lung fibrosis and pulmonary hypertension. *Am J Respir Crit Care Med.* 2010;182(8):1065–72.
11. Wei YH, Jun L, Qiang CJ. Effect of losartan, an angiotensin II antagonist, on hepatic fibrosis induced by CCl4 in rats. *Dig Dis Sci.* 2004;49(10):1589–94.
12. Koh EJ, Yoon SJ, Lee SM. Losartan protects liver against ischaemia/reperfusion injury through PPAR- γ activation and receptor for advanced glycation end-products down-regulation. *Br J Pharmacol.* 2013;169(6):1404–16.
13. Maquigussa E, Paterno JC, de Oliveira Pokorny GH, da Silva Perez M, Varela VA, da Silva Novaes A, et al. Klotho and PPAR Gamma Activation Mediate the Renoprotective Effect of Losartan in the 5/6 Nephrectomy Model. *Front Physiol.* 2018;9:1033.
14. Deng Z, Chen F, Liu Y, Wang J, Lu W, Jiang W, et al. Losartan protects against osteoarthritis by repressing the TGF- β 1 signaling pathway via upregulation of PPAR γ . *J Orthop Translat.* 2021;29:30–41.
15. Mohamed DI, Khairy E, Tawfek SS, Habib EK, Fetouh MA. Coenzyme Q10 attenuates lung and liver fibrosis via modulation of autophagy in methotrexate treated rat. *Biomed Pharmacother.* 2019;109:892–901.
16. Chabielska E, Pawlak R, Buczek W. Losartan does not influence the blood platelet aggregation in normotensive rats. *Acta Physiol Hung.* 1996;84(3):271–2.
17. Li G, Xu Z, Hou L, Li X, Li X, Yuan W, et al. Differential effects of bisphenol A diglycidyl ether on bone quality and marrow adiposity in ovari-intact and ovariectomized rats. *Am J Physiol Endocrinol Metab.* 2016;311(6):E922–E7.
18. Mohamed AS, Hosney M, Bassiony H, Hassanein SS, Soliman AM, Fahmy SR, et al. Sodium pentobarbital dosages for exsanguination affect biochemical, molecular and histological measurements in rats. *Sci Rep.* 2020;10(1):378.
19. Tag HM. Hepatoprotective effect of mulberry (*Morus nigra*) leaves extract against methotrexate induced hepatotoxicity in male albino rat. *BMC Complement Altern Med.* 2015;15:252.

20. **Atalay C, Dogan N, Aykan S, Gundogdu C, Keles MS.** The efficacy of spironolactone in the treatment of acute respiratory distress syndrome-induced rats. *Singapore Med J.* 2010;51(6):501-5.
21. **Montes S, Juárez-Rebollar D, Nava-Ruiz C, Sánchez-García A, Heras-Romero Y, Rios C, et al.** Immunohistochemical Study of Nrf2-Antioxidant Response Element as Indicator of Oxidative Stress Induced by Cadmium in Developing Rats. *Oxid Med Cell Longev.* 2015; 2015:570650.
22. **Curtis JR, Beukelman T, Onofrei A, Cassell S, Greenberg JD, Kavanaugh A, et al.** Elevated liver enzyme tests among patients with rheumatoid arthritis or psoriatic arthritis treated with methotrexate and/or leflunomide. *Ann Rheum Dis.* 2010;69(1):43-7.
23. **Moghadam AR, Tutunchi S, Namvaran-Abbas-Abad A, Yazdi M, Bonyadi F, Mohajeri D, et al.** Pre-administration of turmeric prevents methotrexate-induced liver toxicity and oxidative stress. *BMC Complement Altern Med.* 2015;15:246.
24. **Karadag AS, Kanbay A, Ozlu E, Uzuncakmak TK, Gedik C, Akdeniz N.** Pulmonary fibrosis developed secondary to methotrexate use in a patient with psoriasis vulgaris. *North Clin Istanbul.* 2015;2(2):159-61.
25. **Zheng MH, Dai MS, Lin LF.** The effect of captopril and losartan on paraquat-induced pulmonary fibrosis and PIGF expression in the lungs of rats. *Zhonghua Lao Dong Wei Sheng Zhi Ye Bing Za Zhi.* 2017;35(9):656-62.
26. **Leclercq IA, Sempoux C, Stärkel P, Horsmans Y.** Limited therapeutic efficacy of pioglitazone on progression of hepatic fibrosis in rats. *Gut.* 2006;55(7):1020-9.
27. **Iglarz M, Touyz RM, Viel EC, Paradis P, Amiri F, Diep QN, et al.** Peroxisome proliferator-activated receptor- α and receptor- γ activators prevent cardiac fibrosis in mineralocorticoid-dependent hypertension. *Hypertension.* 2003;42(4):737-43.
28. **Honda K, Marquillies P, Capron M, Dombrowicz D.** Peroxisome proliferator-activated receptor γ is expressed in airways and inhibits features of airway remodeling in a mouse asthma model. *J Allergy Clin Immunol.* 2004;113(5):882-8.
29. **Wengrower D, Zanninelli G, Latella G, Necozone S, Metanes I, Israeli E, et al.** Losartan reduces trinitrobenzene sulphonic acid-induced colorectal fibrosis in rats. *Can J Gastroenterol.* 2012;26(1):33-9.
30. **Canguven O, Lagoda G, Sezen SF, Burnett AL.** Losartan preserves erectile function after bilateral cavernous nerve injury via antifibrotic mechanisms in male rats. *J Urol.* 2009;181(6):2816-22.
31. **Mahmoud AM, Hozayen WG, Ramadan SM.** Berberine ameliorates methotrexate-induced liver injury by activating Nrf2/HO-1 pathway and PPAR γ , and suppressing oxidative stress and apoptosis in rats. *Biomed Pharmacother.* 2017;94:280-91.
32. **Jahovic N, Çevik H, Sehirli AO, Yeğen BÇ, Şener G.** Melatonin prevents methotrexate-induced hepatorenal oxidative injury in rats. *J Pineal Res.* 2003;34(4):282-7.
33. **Tang R, Zhou QL, Ao X, Peng WS, Veeraragoo P, Tang TF.** Fosinopril and losartan regulate Klotho gene and nicotinamide adenine dinucleotide phosphate oxidase expression in kidneys of spontaneously hypertensive rats. *Kidney Blood Press Res.* 2011;34(5):350-7.
34. **Lee C.** Collaborative Power of Nrf2 and PPAR γ Activators against Metabolic and Drug-Induced Oxidative Injury. *Oxid Med Cell Longev.* 2017; 2017:1378175.
35. **Mahmoud AM, Al Dera HS.** 18 β -Glycyrrhetic acid exerts protective effects against cyclophosphamide-induced hepatotoxicity: potential role of PPAR γ and Nrf2 upregulation. *Genes Nutr.* 2015;10(6):41.
36. **Cho HY, Gladwell W, Wang X, Chorley B, Bell D, Reddy SP, et al.** Nrf2-regulated PPAR γ expression is critical to protection against acute lung injury in mice. *Am J Respir Crit Care Med.* 2010;182(2):170-82.
37. **Wu QQ, Wang Y, Senitko M, Meyer C, Wigley W, Ferguson DA, et al.** Bardoxolone methyl (BARD) ameliorates ischemic AKI and increases expression of protective genes Nrf2, PPAR γ , and HO-1. *Am J Physiol Renal Physiol.* 2011;300(5):F1180-F92.
38. **Wang F, Liu JC, Zhou RJ, Zhao X, Liu M, Ye H, et al.** Apigenin protects against alcohol-induced liver injury in mice by regulating hepatic CYP2E1-mediated oxidative stress and PPAR α -mediated lipogenic gene expression. *Chem Biol Interact.* 2017;275:171-7.

To Cite:

Abbas, N., El-Sayed, S., Abd El-Fatah, S., Sarhan, W., Sarhan, O., Abdelghany, E., Mahmoud, S. Losartan prevents methotrexate-induced liver and lung injury in rats via targeting PPAR- γ /TGF- β 1/SMAD3 and Nrf2/redox signaling. *Zagazig University Medical Journal*, 2023; (135-148): -. doi: 10.21608/zumj.2022.173474.2682