

## Patterns of Superficial Cubital Veins in Sohag University Students

Salwa M. Ouies\*, Abeer F. Abd El-Naeem

Anatomy Department –Sohag University, Sohag-Egypt

\*Corresponding author: Salwa Mohammed Ouies; Mobile: +20) 01002073124, E-mail: salwaouies@yahoo.com

### ABSTRACT

**Background:** Genetic and hydrodynamic factors have a very important role in the variation between individuals in anatomical patterns of many structures like veins. Knowing of the different types of the superficial veins in the cubital fossa could be a surgically important in performing safer manipulations like venipuncture, venesection, or any another surgery at this region.

**The aim of the present study:** This study aimed to find out patterns of superficial cubital veins in Sohag University students.

**Subjects and methods:** The study was run on 310 participants (220 male and 90 females). A tourniquet was applied 10 cm proximal to elbow with active flexion and extension of fingers until the veins appear clearly.

**Results:** Four patterns of superficial veins in the cubital fossa were noticed. From the total of 620 examined arms and forearms; type 1, type 2, type 3, and type 4 were **30.1%**, **26.6%**, **22%** and **21.3%** respectively. The patterns on right and left sides have no significant change, but there was significant change between males and females.

**Conclusion:** Four Types of superficial cubital veins were identified in Sohag University students with a close prevalence of the 4 types with a significant difference between males and females.

**Keywords:** Patterns, Sohag, Cubital veins.

### INTRODUCTION

There is great importance of the superficial veins of cubital fossa in medical field and surgical maneuvers due to their perfect location in the subcutaneous tissue. Also, these veins are not paired with any artery, so they are easy to be viewed and accessed<sup>(1)</sup>. It is noticed that these veins vary largely between genders and between populations in their anatomical pattern. The study of this variation is important to medical and healthcare professionals to perform safer venipuncture<sup>(2)</sup>.

The major superficial veins of the upper limb included in venipuncture are the Basilic, Cephalic, Antebrachial and Median cubital veins and their tributaries<sup>(3)</sup>.

The vein of choice in medical field in doing venous catheterization is the basilic vein, because its diameter increases in the region of cubital fossa until it reaches the axillary vein. Also, it lies in direct contact with axillary vein. The median cubital vein is the second best choice as it is prominent in this region and in direct line with the basilic vein<sup>(4)</sup>. Superficial venous system in the cubital fossa shows many variations and was classified by different researchers into several types four, six and eight types<sup>(5-10)</sup>.

The aim of the current work was to study the different patterns of superficial cubital veins in Sohag University students.

### SUBJECTS AND METHODS

This study was done in Sohag University students. 220 males and 90 females were randomly selected to participate in this cross-sectional study. All subjects were Egyptians aged between 18 and 22 years (mean 18.6 years) from November 2021 to February 2022. The participants were asked to view their right and left arms and forearms and the patterns of superficial veins were observed.

### Inclusion criteria

- Students without any embryological anomaly or vascular diseases.
- Students with prominent veins with applying of tourniquet.

### Exclusion criteria

- Students with thick skin.
- Students with cut wound in the cubital region.
- Students with vascular diseases.

Data was collected after exposing both upper limbs above the elbow joint in sitting position.

Tourniquet was applied above the elbow joint (for persons with no prominent veins) with active flexion and extension of fingers until veins become prominent. Superficial venous arrangement were classified into 4 types (according to the most common).

### Ethical considerations:

**Study was ethically approved by the Scientific Research Ethics Committee of Sohag University (Sohag faculty of Medicine Ethical Committee under IRB registration, number: Soh-Med-22-06-21).**

**Participation in the study was voluntary and investigators gave a complete full information about the study to students and their role before signing the informed consent with explanation of the purpose and nature of the study.**

**This work has been carried out in accordance with The Code of Ethics of the World Medical Association (Declaration of Helsinki) for studies involving humans.**

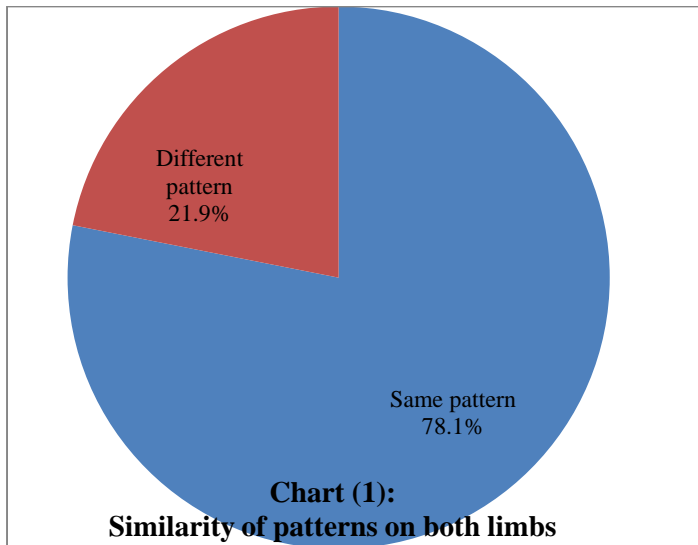
### Statistical analysis

SPSS version 18.0 (SPSS Inc., Chicago, IL, USA) was used for analysis. Chi-square Fisher exact test was used to determine difference between right and left sides and difference between male and female on both sides. It was significance at  $P < 0.05$

### RESULTS

In this study, there were 310 participants, 220 males (71%) and 90 females (29%).

There were 242 (78.1%) persons having the same pattern on both sides, while 68 (21.9%) had different patterns between right and left sides (**chart 1**) with non-significant differences between the two sides ( $p = .5$ ).



Four patterns in the distribution of superficial veins of the cubital fossa were identified:

#### Pattern 1:

(N-type) cephalic vein is seen laterally, basilic vein were seen medially and between them there was connection by median cubital vein, this connection was seen below elbow joint (**Figure 1**).

#### Pattern 2:

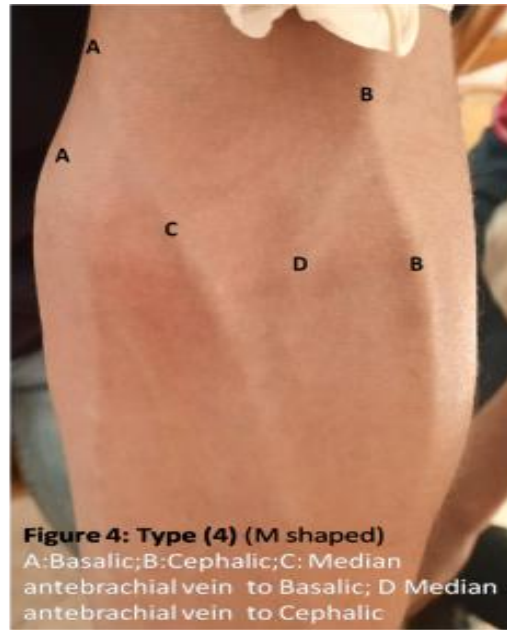
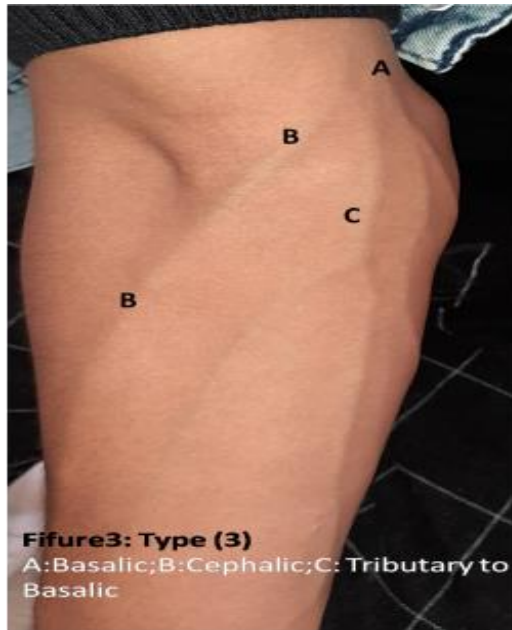
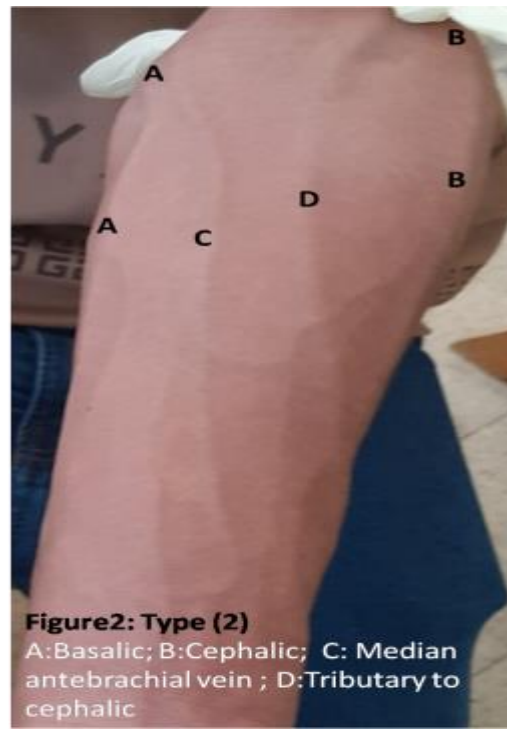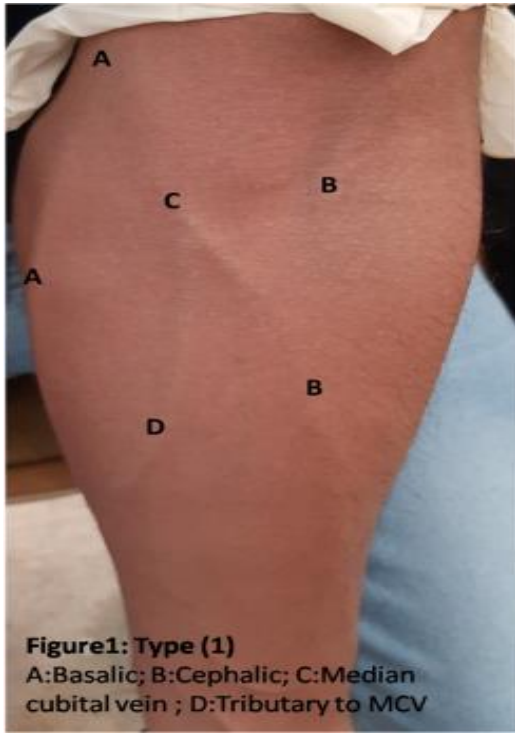
Cephalic and basilic veins appeared without connection, but median antebrachial vein appeared joining basilic vein only, cephalic vein may receive some tributaries (**Figure 2**).

#### Pattern 3:

Cephalic vein runs to join basilic vein directly, basilic vein may receive some tributaries (**Figure 3**).

#### Pattern 4:

(M shape) Basilic and cephalic veins received the 2 terminal tributaries from medial antebrachial vein, which divides below the elbow (**Figure 4**).



**On right side (Table 1 & chart 2):** Type1 was found in 97 (31.3%) of participants, then type two in 78 (25.2%). Type 3 was found in 69 (22.2%) and type 4 was found in 66 (21.3%) of persons.

- **In males:** Type 1 was the commonest type, which was noticed in 88 (40%) of them and type 2 was found in 60 (27%) males, type 3 was found in 24 (11%) only males, and type 4 was noticed in 48 (22%) males.
- **In females:** Type 1 was the least common type noticed only in 9 (10%) of them, type was noticed in 18 (20%) of them, type 3 was the commonest type noticed in females 45 (50%), and type 4 was noticed in 18 (20%) of females like type 2.

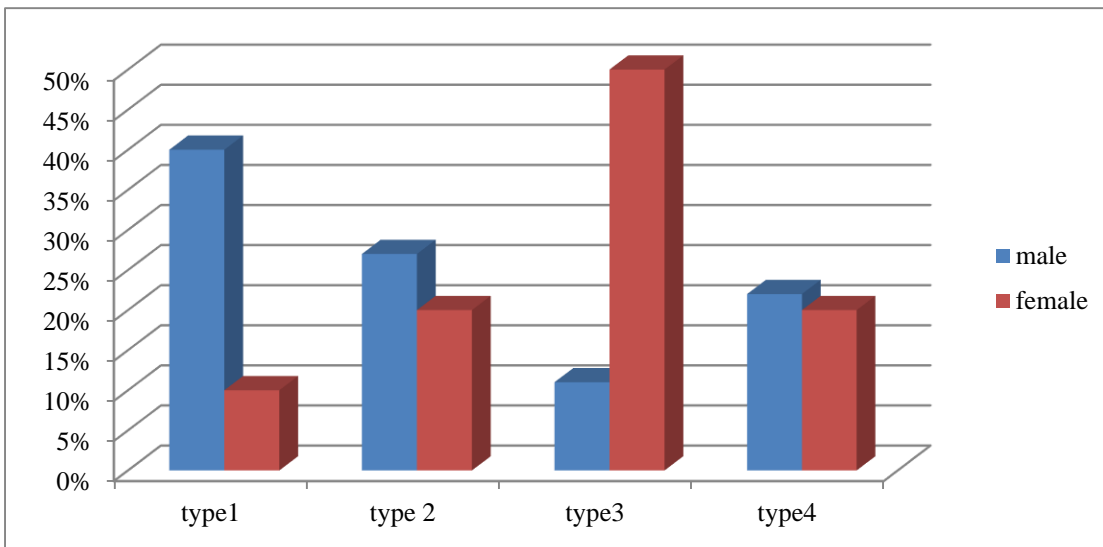
There was highly significant change between males and females on the RT side ( $p \leq 0.00$ ).

**On the left side (Table 1 & chart 3):** Type 1 was found in 89 (28.7%), type 2 was found in 87 (28%), then type 3 in 68 (21.9%) and type 4 was found in 66 (21.4%) of participants.

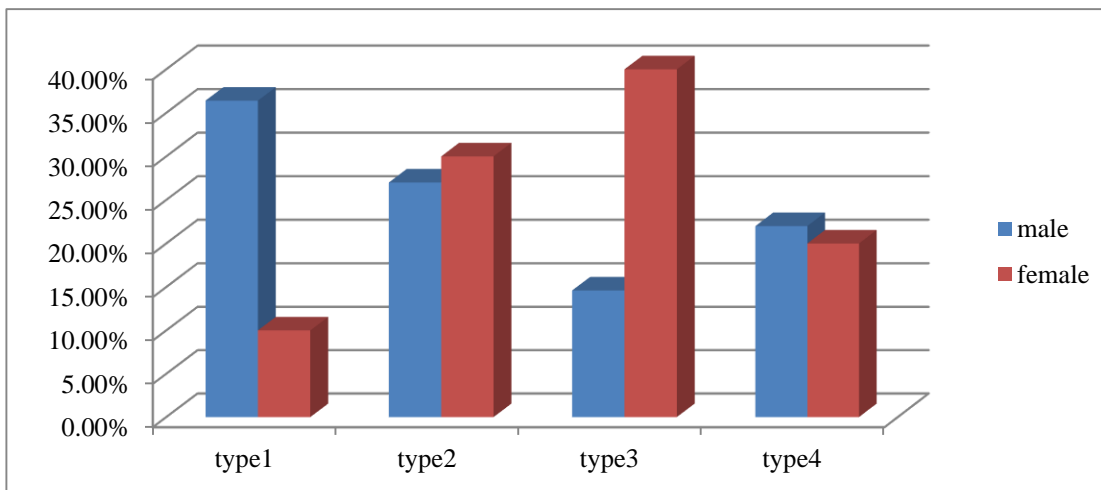
- **In males:** Type 1 was the commonest type, it was noticed in 80 (36.4%) of males, then type 2 was noticed in 60 (27%) of males, type 3 was noticed only in 32 (14.6%) of males, type 4 was noticed in 48 (22%) of males.
- **In females:** Type 1 was noticed only in 9 (10%) of them and it was the least common type, type 2 was noticed in 27 (30%) of females, type 3 in females was the commonest type in them 26 (40%), type 4 was noticed in 18 (20%) of females. Also there was highly significant difference between male and female ( $p \leq 0.00$ ) on the left side. The total pattern 1 was noticed in 30.1% of participants, pattern 2 was noticed in 26.6%, pattern 3 was noticed in 22% of participants and pattern 4 was found in 21.3% of them (Chart 4).

**Table (1):** Patterns of superficial veins on both sides in male and female

		Type1	Type2	Type 3	Type4	Total
<b>Male</b>	RT.	88 (40%)	60 (27%)	24 (11%)	48 (22%)	220
	LT.	80 (36.4%)	60 (27%)	32 (14.6%)	48 (22%)	220
<b>Female</b>	RT.	9 (10%)	18 (20%)	45 (50%)	18 (20%)	90
	LT	9 (10%)	27 (30%)	36 (40%)	18 (20%)	90
<b>Total RT.</b>	RT	97 (31.3%)	78 (25.2%)	69 (22.2%)	66 (21.3%)	310
<b>Total LT.</b>	LT	89 (28.7%)	87 (28%)	68 (21.9%)	66 (21.4%)	310
<b>Total</b>		186 (30.1%)	165 (26.6%)	137 (22%)	132 (21.3%)	620



**Chart (2):** Patterns of veins on right side.



**Chart (3):** Patterns of veins on left side

## DISCUSSION

The present study (subjects), it was also represented in (51.5% of males and 45.4% in females) of the studied group in Jordanian adults<sup>(14)</sup>.

**Ghasem et al.** (2021)<sup>(15)</sup> also found that N type was the most common type in the examined group in Iran (70.1% in males and 64.7% in females) from about 150 females and 160 males of volunteer students. Other study done by **Dharap et al.**<sup>(6)</sup> on 266 participants in Malaysia, reported six patterns, the most common was N-shaped (68%). On the other hand previous study in India<sup>(16)</sup> found that the N type was the second most common pattern observed in their study (28.75% in living subjects and 25% in cadavers)

Systematic review<sup>(17)</sup> of 27 studies, including 9924 arms showed that the commonest type was "N" shaped pattern (≈44-60%) followed by "M" shaped (≈20-25%). In this study M-shaped pattern was the least frequency (21.2%).

**Vocini et al.**<sup>(18)</sup> disagreed with us after study on 169 individuals in 2015 in Serbia; and found that the commonest pattern was the M-shape, and next to it was N-shaped pattern. **Ukoha et al.**<sup>(8)</sup> conducted a study on 135 individuals in Nigeria, and reported that M-shape was the commonest. Also, **Das et al.**<sup>(19)</sup> on a study done in India found that the commonest type was M shape (33.58%).

In this study type 2 pattern with median antebraichial vein joining basilic vein only found in 26.6%, it was represented with 18.6% in Ethiopians<sup>(11)</sup> on the other hand it showed a less incidence in Malaysia (5.6%)<sup>(20)</sup>. It was not detected in Jordanians<sup>(14)</sup>, Korea<sup>(5)</sup> or in India<sup>(21)</sup>. Type 3 with no proximal cephalic vein in this study represented about 22% of the examined group, previous study showed a near result in Nigeria (about 25%)<sup>(8)</sup>, a less incidence was seen in Ethiopia<sup>(11)</sup> (about 14%) and Malaysia (about 4.7%)<sup>(6)</sup>.

The present study showed a statistically significant differences between gender especially in types I and III, which is in accordance with the results from previous studies<sup>(10, 20)</sup>.

This could be attributed to the fact that the superficial cubital veins in males were highly prominent than in females<sup>(22)</sup>. The excess subcutaneous fat in females may obscure some of the superficial veins in the cubital fossa<sup>(14)</sup>.

According to the anthropological significance the prevalent of the four types in the present study were close to researches in Africa specially Ethiopia<sup>(11)</sup> and a little similar to Jordan<sup>(14)</sup> and Nigeria<sup>(8)</sup>.

The knowledge of different patterns of superficial veins may reduce rates of injury to cutaneous nerves in the cubital fossa and decrease the failed trials in collecting venous blood samples especially in emergencies.

## CONCLUSION

- Four different types of superficial veins were represented in this study, which according to prevalence were arranged into: Type I:30.1%, Type II: 26,6%, Type III:22% and Type IV:21.3%
- There were no differences between laterality, although there were significant differences among gender.

**Conflict of interest:** The authors declared no conflict of interest.

**Author contribution:** Authors contributed equally in the study.

## REFERENCES

1. **Standring S (2016):** Gray's anatomy 41th Edition. Anatomical Basis of Clinical Practice, Elsevier. Ch.6 pectoral girdle and upperlimb, Pp: 776-862. <https://www.amazon.com/Grays-Anatomy-Anatomical-Clinical-Practice/dp/0702052302>.
2. **Manandhar B, Shrestha R (2021):** Type A Cubital Venous Pattern among Students of a Dental College: A Descriptive Cross-sectional Study. J Nepal Med Assoc.,59 (238): 547-9
3. **Snell R (2012):** Clinical anatomy by regions. 9th edition, edited by Lipincott William & Wilkins.Ch9. Upper limb Pp: 390-428. [https://books.google.com/books/about/Clinical\\_Anatomy\\_by\\_Regions.html?id=vb4AcULACE0C](https://books.google.com/books/about/Clinical_Anatomy_by_Regions.html?id=vb4AcULACE0C).
4. **Gonzalez R, Cassaro S (2021):** Percutaneous Central Catheter In: StatPearls. Treasure Island (FL): StatPearls Publishing; 2021. Available from: <https://www.ncbi.nlm.nih.gov/books/NBK459338/>. [Last updated on 2019 Feb 11].
5. **Lee H , Lee S, Kim S, Choi W , Lee J , Choi I (2015):** Variations of the cubital superficial vein investigated by using the intravenous illuminator. Anat Cell Biol., 48: 62-65.
6. **Dharap AS, Shaharuddin M (1994):** Patterns of superficial veins of the cubital fossa in Malays. Med J Malaysia, 49: 239-41.
7. **Mikuni Y, Chiba S, Tonosaki Y (2013):** Topographical anatomy of superficial veins, cutaneous nerves, and arteries at venipuncture sites in the cubital fossa. Anat Sci Int., 88: 46-57.
8. **Ukoha U, Oranus C, Okafor J, Ogugua P, Obiaduo A (2013):** Patterns of superficial venous arrangement in the cubital fossa of adult Nigerians. Niger J Clin Pract., 16: 104-9.
9. **Yamada K, Yamada K, Katsuda I, Hida T (2008):** Cubital fossa venipuncture sites based on anatomical variations and relationships of cutaneous veins and nerves. ClinAnat., 21: 307-13.
10. **Pires L, Rafare A, Peixoto B et al. (2018):** The venous patterns of the cubital fossa in subjects from Brazil. Morphologie., 102 (337): 78–82.
11. **Bekel A, bekalu A, moges A, Gebretsadik M (2018):** Anatomical variations of superficial veins pattern in cubital fossa among north west Ethiopians. Anatomy journal of Africa, 7 (2): 1238 – 1243
12. **Corzo Gómez E, Díaz O, Mantilla M, Triana R, Díaz L(2010):**Distribución de los Patrones Venosos de la FosaCubital en unaMuestra de Personas Nacidas en Bucaramanga,Colombia. Int J Morphol., 28 (4): 1011—8.
13. **Moore K, Dally A, Agur A (2014):** Clinically oriented anatomy.7<sup>th</sup> Ed. Williams and Wilkins, ch.6, upper limb, Pp:

- 670-820. <https://www.amazon.com/Clinically-Oriented-Anatomy-sixth-Text/dp/B004V978SI>.
14. **AlBustami F, Altarawneh I, Rababah E (2014):** Pattern of Superficial Venous Arrangement in: The Cubital Fossa of Adult Jordanians. *J Med J.*, 48(4): 269- 274).
  15. **Ghasem G, Nasiri K, Sagha M, Aghamohammadi V, Malekrah A, Eskandari M (2021):**Variation of superficial veins of cubital fossa among students of Ardabil University of Medical Sciences. <https://www.sciencedirect.com/science/article/pii/S2214854X21000261>.
  16. **Dhan M, Suman S, Kumar S, Sinha SK , Singh N (2019):** Observation on the Anatomical Patterns of Superficial Cubital Veins in the Population of Mithilanchal. *Journal of Dental and Medical Sciences*, 18 (11): 30-35.
  17. **Yamine K, Erić M (2017):** Patterns of the superficial veins of the cubital fossa: A meta-analysis. *Phlebology*, 32 (6): 403-414.
  18. **Vučinić N, Erić M, Macanović M (2015):** Patterns of superficial veins of the middle upper extremity in Caucasian population *J. Vasc. Access.*, 17 (1): 87-92.
  19. **Das M, Jahan S, Pankaj P, krSah G (2019):** An observational study of pattern of superficial cubital veins among students of rama university. *Int J Anat Res.*, 7 (3.2): 6835-40.
  20. **Azhar H, Saravanan R, Azreen S, Amer H (2014):** Pattern of superficial venous of the cubital fossa among volunteers in a tertiary hospital. *Trop Med Surg.*, 2: 1-4.
  21. **Vasudha T (2013):** A study on superficial veins of upper limb. *NJCA.*, 2 (4): 204-8.
  22. **Wasfi F, Dabbagh A, Alathari F, salman S (1986):** Biostatistical study on the arrangement of superficial veins of the cubital fossa in Iraqis. *Acta Anat.*, 126 (3): 183-6.