

## Percutaneous Fixation of Trochanteric Fracture Femur by External Fixator In High Risk Patients

Mahmoud M. Beder,<sup>1</sup> MBBCH, Ali M. El-Geoushy,<sup>2</sup> MD, Sameh Anwar Abdel-all,<sup>2</sup> MD.

### \* Corresponding Author:

Mahmoud M. Beder

[drmahmoumabrouk62@gmail.com](mailto:drmahmoumabrouk62@gmail.com)

Received for publication April 21, 2022; Accepted November 16, 2022; Published online November 16, 2022.

doi: 10.21608/aimj.2022.134604.1920.

Citation: Mahmoud MB., Ali ME, and Sameh AA. Percutaneous Fixation of Trochanteric Fracture Femur by External Fixator In High Risk Patients. AIMJ. 2022; Vol.3-Issue11 .48-53.

<sup>1</sup>Orthopedic Surgery Department, kafr El-Sheikh general hospital., kafr El-Sheikh, Egypt.

<sup>2</sup>Orthopedic Surgery Department, Faculty of Medicine, Al-Azhar University, Cairo, Egypt.

### ABSTRACT

**Background:** The intertrochanteric fracture is one of the most frequent proximal femoral fractures, particularly in elderly people with osteoporotic bones. The gold standard therapy is internal fixation. In the patients unfit for surgery, however, it may be difficult.

**Aim of the study:** to assess the clinical, radiological and complications outcome of trochanteric fracture in high risk patients treated by percutaneous external fixation.

**Patients and Methods:** 20 high-risk patients hospitalized in Al Azhar University (Al-Hussien hospital) in addition to kafr El-Sheikh general hospital (April 2020 to March 2021), were treated with an external fixation done under local or regional anaesthesia. There were 8 men and 12 women. The mean average age was 70.80 (57-84) years.

**Results:** The average operational time was 28.85 minutes. Hospital stay was brief, with an average of 1-2 days. No intra operative problems were found. Blood loss was low and none of the patients had any blood transfusion. All fractures healed within a average 12.05 weeks. Two patients developed a superficial pin-tract infection as a result of their treatment (10 percent ). Four (20%) of the patients had a shortening of the fracture. Revision fixation was performed on a patient with implant failure in 5% of cases without any complications. At 12 months, there were no patients with knee mobility restrictions. Pre-injury and 12-month functional scores for daily activities.

**Conclusion:** Treatment of trochanteric fractures is safe and successful when externally fixed. Minimal anaesthetic and surgical risks; There was no blood loss; the hospital stay was brief; and the patient was able to leave the hospital quickly.; low morbidity and mortality; and a quick return to work.

**Keywords:** elderly; external fixation; trochanteric fracture; local anesthesia; high-risk.

**Disclosure:** The authors have no financial interest to declare in relation to the content of this article. The Article Processing Charge was paid for by the authors.

**Authorship:** All authors have a substantial contribution to the article.

**Copyright** The Authors published by Al-Azhar University, Faculty of Medicine, Cairo, Egypt. Users have the right to read, download, copy, distribute, print, search, or link to the full texts of articles under the following conditions: Creative Commons Attribution-Share Alike 4.0 International Public License (CC BY-SA 4.0).

### INTRODUCTION

Hip intertrochanteric fractures are among the most frequent hip fractures, particularly among the elderly and those with osteoporotic bones. With conservative treatment, these fractures are linked with considerable morbidity and death. Hip fractures are projected to rise in frequency as life expectancy increases<sup>1</sup>. For these fractures, internal fixation like the dynamic hip screw, intramedullary nails, and proximal femoral plate is a routine procedure, but in patients with accompanying diseases like liver disease, chronic obstructive pulmonary disorder (COPD), uncontrolled diabetes mellitus, or severe anemia, there is a high risk of anaesthetic or postoperative complications.<sup>2</sup>

As a result of its biomechanical properties, speedy fixation, minimum surgical reduction, and low postoperative complication rates to date, this surgical procedure corresponds strictly to the notion of minimally invasive surgery.<sup>3</sup> for patients who need early ambulation and prevention of recumbence issues, an external fixator may be used under local anaesthetic and sedation or brief regional anaesthesia.<sup>4</sup> In comparison to internal fixation, the procedure takes much less time. The patient's blood loss is modest and the stress of surgery is low. These patients' postoperative discomfort is modest and readily manageable, making their care and mobility simpler; the preservation of fracture hematomas is an added bonus.<sup>4</sup> Infection, broken rod or pins, varus deformity, and shortening are all possible problems

of external fixation for intertrochanteric fractures.<sup>5</sup> Preoperative evaluation and postoperative care are essential to reduce complications after the repair of unstable intertrochanteric fractures, the most frequent of which are cardiac infarction, pneumonia, and urinary tract infections.<sup>5</sup>

We aimed to assess the clinical, radiological and complications outcome of trochanteric fracture in high risk patients treated by percutaneous external fixation.

### PATIENTS AND METHODS

The anaesthetist at Al Azhar University (Al-Hussien Hospital) and kafr El-Sheikh general hospital classified 20 high-risk patients with pertrochanteric fractures between April 2020 and March 2021 as ASA grades 3 in 16 patients or grade 4 in 4 patients and deemed them unfit for conventional fracture fixation under anaesthesia because of their associated medical conditions. (Table 1) shows the medical issues that make these people high-risk. Almost half of the fractures occurred on the right side in 11 patients (55%), 9 in left side (45%) with a male-to-female ratio of 8:12. External fixation under local or regional anesthesia (sciatic or femoral block) was used to treat these individuals. There were eight AO type A1 fractures, ten AO type A2 fractures, and two AO type A3 fractures among the patients., all as determined by radiographs taken from the anterior, posterior, and lateral sides. A simple tumble caused all of the fractures.

Patients with concomitant diseases and a high likelihood of requiring a lengthy surgical procedure were included from consideration for this study.

Patients with dementia , previous hip fracture ,pathological fractures, open fractures, and infections at the fracture site were all excluded from the study.

For each patient, we kept track of their post-op recovery, blood transfusions, pin tract infection, time to union, malunion, varus angulation, shortening, and implant failure. We also tracked their hip and knee range of motion before and after surgery. Pre-injury functional state was assessed using the Foster rating system and the Lower Extremity Measure adapted by Boretto and colleagues<sup>6</sup> based on everyday activities such as walking and discomfort.

#### Technique:

**Positioning:** The patient was placed supine on a fracture table.

**Reduction:** the fracture was reduced by gentle traction in hip flexion and abduction in moderate external rotation followed by gentle extension and internal rotation. The reduction was confirmed by image intensifier in both planes. The reduction was considered to be satisfactory if the neck-shaft angle was reproduced and the gap at the fracture site was

less than 2 mm in both anteroposterior and lateral Fixation: Under image intensifier Two non HA-coated cancellous Schanz(5-6mm) were percutaneously passed across the fracture site at an angle of 130° (roughly) with the shaft along the axis of the neck of the femur. In AP view, both pins were parallel or slightly convergent, and in lateral view, both pins were central. The superior pin was inserted directly above the middle of the neck and head, while the inferior pin was inserted along the inferior of the neck and head. Pins were advanced to a point 5 mm below the head's subchondral bone. Two non HA-coated cortical Schanz screws(5-6mm) were placed into the shaft of the femur with threads beyond the opposite cortex as checked under fluoroscopy and pins were connected through universal clamp and tubular connecting rod.

**follow up:** Within 6-12 hours of surgery, all patients began post-operative mobilisation. After acceptable clinical and radiographic evidence of fracture union were present, patients with stable fractures were allowed by full weight bearing. patients with unstable fractures were allowed by partial weight bearing followed by full weight bearing. Except if there were any evidence of pin tract infection, all patients were seen in the clinic every two weeks for the first four weeks, then monthly after that. The patient's pleasure and function were measured verbally at each appointment. A clinical examination of the pin entry sites, hip and knee range-of-motion (ROM), quadriceps strength, and capacity to walk with or without support were also performed. Hip radiographs in two views are standard.

At each visit, were also acquired to document fracture union. The pin sites were treated with saline on a daily basis, and the patients' relatives were given information on how to care for them after they were discharged. For hip and knee ROM, appropriate therapy was recommended. After radiographic union was accomplished, external fixators were removed in the outpatient clinic. The presence of trabeculae bridging the fracture site or an apparent periosteal callus within the fracture line was used to define radiographic union.

### RESULTS

The mean average age at operation was 70.80±7.79 years (range 57 -84). The average time spent operating was 28.85±4.75 minutes. No intra operative complications were encountered. Injury to surgery mean interval was 1.80± 0.95 days. Blood loss was minimal (20–mL) and none of the patients required blood transfusion. Average (mean) hospital stay was 1.80± 0.95 days (range 1 to 4 days)

None of the fracture failed to unite. Average time of union was 12.05± 1.54 weeks (range 10 to 15 weeks). Nature and incidence of post operative complications is summarized in (Table 2). No complications occurred in 12 patients. The remaining 8 patients had some complications after surgery we encountered pin loosening in one patient (5%). four patients (20%) had

limb shortening of 15 mm or more due to some impaction, varus mal union was present in three patients (15%).two patients(10%) developed superficial pin tract infection,(Only a small amount of irritation was present, which was managed with periodic pin care.)

One (5%)patient with pin tract infections had varus mal union and shortening after union. During follow-up, two individuals died from medical causes unrelated to the surgical operation., one during the first 6months and one during the last 6 month. As a result, only 18 patients were available for the final evaluation. And scoring at 12 months. However, none of the patients was lost prior to union.

At one year, the majority of the 18 surviving patients had returned to their pre-fracture ambulatory condition.Walking ability was normal in 15 (83.3%) patients while3 (16.6%)patients used stick to go out.

At the most recent follow-up, only one patient who used a stick before to surgery needed to use a walker. Knee stiffness is almost always the result of transfixing the vastus lateralis muscle, however it is only transitory and returns to normal after the pins are removed. Final results were excellent in 13 (72.2%) patients based on lower extremity measure score (Table 3). There was no discernible difference between the pre injury and the final functional score (p > 0.05). Excellent results in functional grading and anatomical grading were obtained in Foster rating system in 83.3% and 60% patients respectively (Table 4) 7. and based on Harris hip score (Table5) 8. The benefits of external fixation for the treatment of petrochanteric fractures in elderly, high-risk patients are confirmed in this study. Our results are summarized in (Tables 1\_5 , Figure 1)

	No.	%
Diabetes mellitus	3	15.0
Hypertension	5	25.0
Hepatic disease	2	10.0
Heart failure	2	10.0
Anemia	1	5.0
Coronary disease	4	20.0
Renal disease	2	10.0
Respiratory disease	1	5.0
Malignancy	1	5.0

**Table 1:** Pre-injury health status of the patients

Complications	No.	%
None	12	60.0
Shortening	4	20.0
Pin loosening	1	5.0
Superficial pin tract infection	2	10.0
Varus malunion	3	15.0
Death	2	10.0

**Table 2:** Post operative complications.

score	No.of Patient (initial)	No.of Patients (12 months)	P value
Excellent	12	13	
Very good	3	4	
Good	5	1	
Fair	0	0	
Poor	0	0	
Total patients	20	18	>0.05 (NS)

**Table 3:** Lower Extremity Measure Score

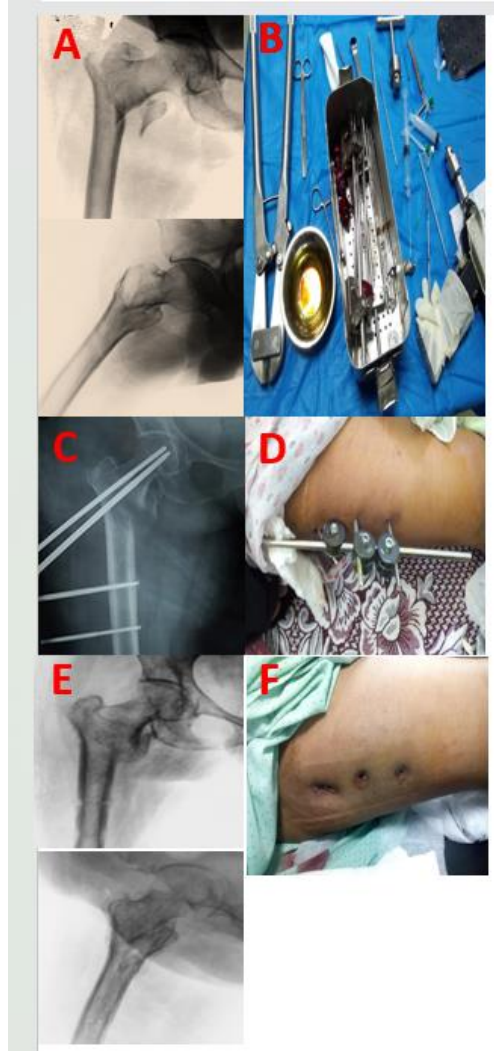
Foster rating system	No	%
Excellent		83.3
Functional grading(Before and after the operation, there are walks. There is no limp or soreness.)	15	60.0
Anatomical grading(Union in perfect position)	12	
Good		16.6
Functional grading(He walks well and uses a stick to get around.)	3	
Anatomical grading (With a varus angle of less than 10° and negligible shortening)	8	40.0
Fair	0	0.0
Functional grading( Requires stick, considerable limp or pain)		
Anatomical grading(With a varus of 10–25 degrees and a half-inch to one-inch shortening)		
Poor	0	0.0
Functional grading( Bedridden or confined to chair)		
Anatomical grading (Severe malunion, a varus deformity of 25° or more, or a shortening of more than an inch)		

**Table 4:** Functional and anatomical results (Foster rating system).<sup>7</sup>

NO of patients	3 months HHS	6 months HHS
1	68	88
2	66	88
3	66	76
4	65	85
5	28	38
6	69	75
7	52	85
8	83	89
9	52	62
10	69	89
11	42	55
12	66	85
13	65	76
14	56	62
15	22	32
16	28	0
17	56	75
18	83	97
19	65	76
20	66	89

**Table 5:** Harris hip score.<sup>8</sup>

The modified Harris hip score was scored from 0 (worst functional outcome and maximum pain) to 100 points (best functional outcome and least pain). Like the original Harris hip score, the interpretation of outcome using the modified Harris hip score was as follows: <70 (poor result), 70–79 (fair result), 80–89 (good result) and >90 (excellent result).



**Fig 1:** A. Radiographic showing pre - operative X-ray of right trochanteric fracture . B. Fixation instruments . C. Post - operative xray. D. patient with right trochanteric external fixation during post-operative follow - up visit . E. antero- posterior and lateral view of right hip showing radiographic union of trochanteric fracture at latest follow- up . F. Patient after removal of external fixator.

## DISCUSSION

As one of the most prevalent types of fractures, proximal femoral fractures are a primary cause of mortality and disability in the senior population.<sup>9</sup> DHS/DCS fixation systems or intramedullary nails have been the gold standard treatment for pertrochanteric fractures<sup>10</sup>, However, these fractures are linked to a significant death rate (up to 60 percent) when managed conservatively, Except in terminally

sick or non-ambulatory individuals, surgical management is required.<sup>11</sup> Trochanteric fractures in elderly individuals with considerable comorbidities and high anaesthetic risk pose a major problem. As a result of the high mortality rate associated with prolonged resuscitation<sup>12</sup> external fixation is a viable option that requires minimal invasion, shorter operating time, less blood loss, less pain, less hospitalization, and early ambulation and thus reduced morbidity and mortality in high risk geriatric patients<sup>13</sup> Pin tract infection is a serious surgical complication, although it is treatable, particularly after the pin has been removed. Pin tract infection was decreased in the majority of patients in our research with frequent removal of pins, saline washes, and antiseptic dressing<sup>14</sup> The vastus lateralis muscle transfixion is likely to be the cause of knee stiffness, although it was only transient in the vast majority of instances, returning to near-normal when the pin was removed. Knee stiffness was reduced due to the more proximal insertion of femoral shaft Schanz pins and knee flexion prior to this treatment.

Only two individuals in our research developed Pin tract infection, but the majority of patients had their infection cleared up with repeated saline washes, antiseptic treatment, and eventually the removal of the pierced organs. Using hydroxyapatite-coated pins did not cause any superficial infections in Moroni and colleagues XX<sup>15</sup>, and while we did not use these pins in our investigation, we are certain that their usage would enhance the result and lower the chance of pin-tract infection.

Pin loosening was also seen in one patient. Mean operating duration in this study was  $28.85 \pm 4.75$  minutes, which falls short of the average time reported in previous studies(14,15). Our research found that the average time of stay in the hospital was  $1.80 \pm 0.95$  days, which is much less than the average time recorded in published studies.<sup>16, 17, 18</sup> The short amount of time that patients spend at the hospital before being operated on in this research. All of these factors, including the quickness of the surgery and the early postoperative mobility, led to the patient being discharged from the hospital earlier, recovering quicker, suffering fewer complications and deaths, and spending less money on care overall. The short intraoperative time, the short hospitalization, and the lack of requirement for postoperative blood transfusion were in conformity with prior investigations.<sup>19</sup> With an average of  $12.05 \pm 1.54$  weeks, all fractures healed, which is in line with the published average of 10–15 weeks.<sup>20, 21, 22</sup> Postoperative knee stiffness induced by distal pin fixation of the fascia lata and vastus lateralis is another issue related with external fixation. According to recent trials on external fixation devices, there was no long-term knee stiffness after 12 months.<sup>16,17,21,22</sup>

Our last follow-up found that the hip's range of motion was normal.

Shortening was seen in three of the 18 individuals with varus angulation.

However, death rates of 14 to 27% have been described in the literature prior to this study in both the six-month and twelve-month follow-ups<sup>20,22,23</sup>, while in this study was 5%-10% because the number of cases in this study is less than the number of cases in previous studies.

Although these studies did not just include high-risk patients, the mortality rate following open reduction and internal fixation was much higher. Most of our patients had good to excellent functional outcomes after a year, which was also seen in other research. In this study regarding the functional outcome Most of the 18 surviving patients returned to their prefracture ambulatory status at one year. Walking ability was normal in 15(83.3%) patients while 3(16.6%) patients used stick to go out. Only one patient who used a stick preoperatively had to use a walker at the last follow-up. in Kourtzis et al<sup>24</sup> the majority of the patients (57.69%) returned to the walking condition they had before the fracture. in Barros et al<sup>24</sup> The remaining 33 walked as they did before their injury. in Hilal Ahmed Kotwal et al<sup>20</sup> Most of the 50 surviving patients returned to their prefracture ambulatory status at one year. Walking ability was normal in 22(44%) patients while 24(48%) patients used stick to go out. Only four patients who used a stick preoperatively had to use a walker at the last follow-up. in Dhal et al.<sup>25</sup> Most of the 35 surviving patients at 6 months returned to their pre fracture ambulatory status. Only two who used a stick preoperatively had to use a walker at the most recent follow-up. In Bozgeyik et al<sup>26</sup> Walking ability was normal in 10 patients, 4 patients used stick to go out. 1 patient Requires stick, considerable limp or pain and 1 patient Bedridden.

### CONCLUSION

Geriatric individuals with a trochanteric fracture and an accompanying medical condition may benefit from external fixation for those who are at high risk for open surgery because of their anaesthesia and blood loss risk. The method is easy, safe, and trustworthy, as well as cost-effective and efficient. As a result, there is less blood loss and decreased risk of problems associated with prolonged resuscitation. After surgery, the patients' post-operative discomfort was modest and readily manageable, making it simpler to care for and move them. External fixation has low morbidity and mortality, is quick to mobilise, has little blood loss, and requires just a brief hospital stay. A local anaesthetic may be used, and the results are the same in terms of union and eventual functional outcome.

Conflict of interest : none

### REFERENCES

- 1- Ozkaya U, Parmaksizo A, Yülu AS, M. G. A. I, et al. Management of osteoporotic pertrochanteric fractures with external fixation in elderly patients. *Acta Orthop Traumatol Turc.* 2008; 42,246-51.
- 2- Kazemian GH, Manafi AR, Najafi F, et al. Treatment of intertrochanteric fractures in elderly highrisk patients: dynamic hip screw vs. external fixation. *Injury.vol.* 2014; 45,568-72.
- 3- Petsatodis G, Maliogas G, Karikis J, et al. External fixation for stable and unstable intertrochanteric fractures in patients older than 75 years of age: a prospective comparative study. *J Orthop Trauma.vol.* 2011; 25,218-23.
- 4- Vekris MD, Lykissas MG, Manoudis G, et al. Proximal screws placement in intertrochanteric fractures treated with external fixation: comparison of two different techniques. *J Orthop Surg Res.* 2011; 6:48.
- 5- Badras L, Skretas E, and Vayanos ED. The use of external fixation in the treatment of trochanteric fractures. *Rev Chir Orthop.* 1997; 83,461. -
- 6- Borreto J, Ferro D, and Torres H. First-year mortality and long-term results of hemiarthroplasty for hip fractures in the elderly. *J Ortho p Trauma.* 2002; 3,35-40.
- 7- Foster JC. Trochanteric fractures of the femur treated by the Vitallium McLaughlin nail and plate. *J Bone Joint Surg Br.* 1958; 40:684-93.
- 8- Harris WH. Traumatic arthritis of the hip after dislocation and acetabular fractures: treatment by mold arthroplasty. An endresult study using a new method of result evaluation. *J Bone Joint Surg Am.* 1969;51(4):737-55.
- 9- Petsatodis G, Maliogas G, Karikis J. External fixation for stable and unstable inter-trochanteric fractures in patients older than 75 years of age: a prospective comparative study. *J Orthop Trauma.* 2011;25:18-23.
- 10- Karn NK, Singh GK, Kumar P, et al. Management of trochanteric fractures of the femur with external fixation in high-risk patients. *IntOrthop.* 2009; 33:785-8.
- 11- V. Patel RM, and Iesaka K. Comparison of a sliding hip screw with atrochanteric lateral support plate to an intramedullary hip screw for fixation of unstable intertrochanteric hip fractures : A cadaver study. *J Trauma .* 2004;56:791-4.
- 12- Gotfried Y, Frish E, Mendes DG, et al. Intertrochanteric fractures in high risk geriatric patients treated by external fixation. *Orthopedics.* 1985;8 (6):769-74.
- 13- Karn NK, Singh GK, Kumar P, et al. Management of trochanteric fractures of the femur with external fixation in high-risk patients. *IntOrthop.vol.* 2009; 33:785-8.
- 14- Moroni A, Faldini C, Pegreffo F, et al. Dynamic hip screw compared with external fixation for treatment of osteoporotic pertrochanteric fractures. A prospective, randomized study. *J Bone Joint Surg Am.* 2005;87:753-9.

- 15- K.Kazakos, DN.Lyras, D. Verettas, V. Galanis, I.Psillakis, K.Xarchas, External fixation of intertrochanteric fractures in elderly high-risk patients. *Acta Orthop Belg.* 2007; vol. 73, pp.44–48.
- 16- Liang Y, Liu S, Zhong F. Outcome of unstable pertrochanteric fractures in high-risk geriatric treated with external fixators. *European Journal of Orthopaedic Surgery & Traumatology.* 2022 Jul;32(5):867-74.
- 17- Bozgeyik B, and Kekeç AF. Is External Fixation Valid Option for Pertrochanteric Fractures in High-Risk Patients?. *Eur J Ther.* 2018 Dec 1;24(4):204-9.
- 18- Ahmad AR. An innovative external fixator for the management of trochanteric fractures of the femur. *Egypt Orthop J.* 2014; 49:1-5.
- 19- Christodoulou NA, and Sdrenias CV. External fixation of select intertrochanteric fractures with single hip screw. *Clin Orthop.* 2000; 381: 204-11.
- 20- Hilal AK. *JMSCR.* 2018; 6(5): 304-10 .
- 21- Karn NK, Singh GK, Kumar P, Singh MP, Shrestha BP, Chaudhary P. Management of trochanteric fractures of the femur with external fixation in high-risk patients. *International orthopaedics.* 2009;33(3):785-8.
- 22- Vossinakis IC, Badras LS. The external fixator compared with the sliding hip screw for pertrochanteric fractures of the femur. *The Journal of Bone and Joint Surgery. British volume.* 2002;84(1):23-9.
- 23- Vossinakis I, Badras L. Management of pertrochanteric fractures in high-risk patients with an external fixation. *International orthopaedics.* 2001;25(4):219-22.-
- 24- Barros JW, Ferreira CD, and Freitas AA. External fixation of intertrochanteric fractures of the femur. *Int Orthop.* 1995;19:217–9
- 25- Dhal A, Varghese M, and Bhasin VB. External fixation of intertrochanteric fractures of the femur. *J Bone Joint Surg Br.* 1997; 73:955–8
- 26- Bozgeyik B, and Kekeç AF. Is External Fixation Valid Option for Pertrochanteric Fractures in High-Risk Patients?. *Eur J Ther.* 2018;24(4):204-9.