

Online ISSN: 2682-2628
Print ISSN: 2682-261X

IJC CBR

INTERNATIONAL JOURNAL OF CANCER AND BIOMEDICAL RESEARCH

<https://jcbr.journals.ekb.eg>

Editor-in-chief

Prof. Mohamed Labib Salem, PhD

**Hepatorenal and cerebellar anti-toxic effects of
curcumin against orlistat associated toxicity in
obese male albino rats**

Samah M. Arisha and Eman H. Kandil



PUBLISHED BY

EACR EGYPTIAN ASSOCIATION
FOR CANCER RESEARCH

Since 2014

Hepatorenal and cerebellar anti-toxic effects of curcumin against orlistat associated toxicity in obese male albino rats

Samah M. Arisha and Eman H. Kandil

Zoology Department, Faculty of Science, Menoufia University, Egypt

ABSTRACT

Background: Orlistat is one of the common medicines in treating overweight, and its use may cause several side effects. Curcumin, a yellow phenolic compound isolated from *Curcuma longa's* rhizome, possesses several pharmaceutical effects due to its antioxidant and anti-inflammatory properties. **Aim:** This work aimed to test the possible protective effect of curcumin against orlistat-induced hepatorenal and cerebellar toxicities in obese albino rats. **Material and Methods:** Forty adult male albino rats were equally separated into four groups; Group I: the control group. Group II: curcumin group; Group III: orlistat group. Group IV, rats were given orlistat ((32mg/kg/day)) then curcumin (200mg/kg body weight three times per week for six weeks). **Results:** In the liver of rats treated with orlistat, the hepatic cells appeared with degenerated cytoplasm containing many vacuoles and darkly stained nuclei. Similarly, some glomeruli in the kidney were atrophic or fractured, the cerebellar cortex is spongiosis, and the Purkinje cells, granule, and molecular cells were degenerated. When rats were treated with orlistat and curcumin, the liver, kidney, and cerebellar the histopathological changes were relatively recovered to the control ones. The number of Kupffer cells, glomerular diameter, Bowman's space width, and the dimensions of the renal tubules significantly decreased, and the epithelial height retrains normal as compared to orlistat treated rats. The levels of MDA, dopamine, and glutamate significantly decreased, and the activity of SOD significantly increased. The rising in PCNA and Bcl2 expression after orlistat is significantly decreased in the studied organs after curcumin treatment. **Conclusion:** This study concluded that curcumin may have a potential role in improving hepatorenal and cerebellar toxicities after orlistat treatment.

Keywords: Cerebellum; Curcumin; Kidney; Liver; Pathological

Editor-in-Chief: Prof. M.L. Salem, PhD - Article DOI: 10.21608/IJCBR.2022.168085.1280

ARTICLE INFO

Article history

Received: October 10, 2022

Revised: November 05, 2022

Accepted: November 13, 2022

Correspondence to

Eman H. Kandil

Zoology Department,

Faculty of Science,

Menoufia University, Egypt

Tel: +201009274112

Email: emanhosney@yahoo.com

Copyright

©2022 Samah M. Arisha and Eman H. Kandil. This is an Open Access article distributed under the Creative Commons Attribution License, which permits unrestricted use, distribution, and reproduction in any format provided that the original work is properly cited.

INTRODUCTION

The term overweight describes excessive fat storage, which may cause health problems (WHO, 2000). Obesity and overweight are considered food-related chronic diseases. It may cause type 2 diabetes, hypertension, and cardiovascular disease, which increased the chance of early mortality to the emergence of serious chronic conditions (Flegal et al., 2002). As a consequence of the harmful side effects of obesity, much research has been done on weight control, including studies on nutrition, exercise, surgery, and using pharmaceutical plants. Medication is the standard and most accessible approach to losing weight, and prescriptions for anti-obesity treatments have

increased significantly over the years (Mohamed et al., 2014).

Orlistat is an anti-obesity medication that inhibits lipase so, lowering the intake of dietary fat, and causing caloric shortage which has a positive influence on weight regulation (Ballinger and Peikin, 2002; Johansson et al., 2010). However, orlistat causes many gastrointestinal side effects such as diarrhea, flatulence, bloating, stomach discomfort, and dyspepsia (Siebenhofer et al., 2013). In animal studies, orlistat caused direct damage to the intestinal villi (Caner et al., 2005), and hepatotoxicity (Filippatos et al., 2008; Yousef, 2018). Also, orlistat has been connected to the development of neurodegenerative disorders (Sriram et al., 2002).

Orlistat exerted damaging effects on tongue mucosa (Ezzat and Labah, 2017; Kassab et al., 2020) and colonic mucosa of rats (Nairooz et al., 2010), acute pancreatitis (Abdelwahab et al., 2017). Also, fat-soluble vitamin deficiencies (D and E) (McDuffie et al., 2002), in addition to severe kidney damage limit the patient compliance for orlistat (Tousson et al., 2018).

Medicinal plants are a dependable source for developing new medications and fighting ailments due to their easy usage, fewer side effect, and many pharmaceutical properties.

Curcumin is the principal yellow phenolic compound isolated from *Curcuma longa's* rhizome. It has specific physical, chemical, and biological features. The curcumin chemical formula is 1,7-bis (4-hydroxy-3-methoxyphenyl)-1,6-heptadiene-3,5-dione, a feruloyl methane molecule, consists of two ferulic acid residues connected by a methylene bridge. It has an aromatic o-methoxy phenolic group, α , β -unsaturated - β diketo moiety, and a seven-carbon linker as its three main functional groups (Indira Priyadarsini, 2013). It is used as a food additive to give flavor and color, as well as for cosmetics and pharmaceutical purposes (Pedraza-Chaverrí et al., 2004).

Additionally, it is widely recognized as a panacea in herbal therapy, having a wide variety of pharmacological activities since it has anti-inflammatory (Kalpana et al., 2007), anticarcinogenic (Ströfer et al., 2011), antioxidant (Venkatesan et al., 2000), wound healing, and blood cholesterol-lowering properties (Jain et al., 2006).

Moreover, Aggarwal and Harikumar (2009) found that it possesses anti-carcinogenic properties and helps treat renal, myocardial, and nervous tissue damage (Duvoix et al., 2005). Curcumin's antioxidant and anti-inflammatory properties have been shown to protect the liver (Khudhair et al., 2022) and kidney (Abubakar et al., 2020), testis (Mira, 2017), and heart (Elshama et al., 2016) in response to toxicity.

So, this study was conducted to evaluate the potential of curcumin against orlistat hepatorenal and cerebellar toxicities.

MATERIAL AND METHODS

Orlistat

Orlistat (Xenical), hard gelatin capsules, was acquired from Hoffmann-La Roche Pharmaceuticals. Each capsule contained 120 mg of activated ingredients. The contents of the capsules were properly emptied and dissolved in distilled water. The therapeutic dose of orlistat (32 mg/kg/day) was administered orally through gastric gavage for six weeks. The dosage was estimated using a method for comparing human and animal doses (Paget and Bernes, 1973).

Curcumin

Curcumin was bought from Sigma Chemical Co. in powder form, USA. It was dissolved in saline solution, and 200 mg/ Kg was given to rats orally via oral tube, day after day, for six weeks (Yu, 2012).

Animals

Forty adult male albino rats weighing 220-240 g were purchased from the Helwan farm in Cairo, Egypt's Ministry of Health. Under normal conditions, they were kept in discrete, well-ventilated cages with unrestricted water and food supply. The rats underwent a 10-day acclimation period before the investigation started. The Menoufia University Faculty of Science Ethics Committee approved (Approved No. MUF/F/HI/6/21) the study's protocol following the National Institutes of Health's guide for the care and use of laboratory animals (NIH publication No. 8023, received 1978).

Experimental Design

Four rat sets of equal size (8 rats each) were treated for six weeks as follows:

- Group I (served as a control) take saline solution daily.
- Group II (curcumin group): rats were administered curcumin (200 mg/kg body weight) by stomach tube three times per week for six weeks.
- Group III (orlistat group): rats orally received orlistat (32 mg/kg/day).
- Group IV (orlistat and curcumin): rats were given orlistat with the same doses as group III and then, two hours later, curcumin in the same doses as group II.

After the sixth week ended, rats fasted overnight following the final treatment; then the next day, the animals were anesthetized by halosan and sacrificed. Each animal's blood sample was taken, from the portal vein, into a sterile tube and kept at room temperature to coagulate to separate serum to determine the neurotransmitters dopamine and glutamate. In addition, each animal's liver, kidney, and cerebellum were rapidly removed and processed for histological, immunohistochemical, and biochemical studies.

Biochemical Examination

According to Beauchamp and Fridovich (1971) and Ruiz-Larea et al. (1994), malondialdehyde (MDA) levels and superoxide dismutase (SOD) activity, respectively, were assessed and estimated in the tissue of the liver and kidney. Dopamine was determined by using dopamine ELISA Kit Catalog Number KA1887 96 assays Version: 13 and glutamate by using glutamate assay Kit WST, technical manual.

Histological Study

The liver, kidney, and cerebellum were chopped into tiny pieces and fixed for 24 hours in neutral formalin (10%); tissues were dehydrated using ethyl alcohol, cleared in xylene, and embedded in paraffin wax (mp. 54-56 °C). Using a rotary microtome, sections with a thickness of 4 microns were cut, then adhered to clean slides, stained with Ehrlich's hematoxylin, and counter-stained with eosin. The Olympus microscope was used to inspect and photograph falls (BX41 TF, Olympus Corporation, Shinjuku City, Tokyo, Japan).

Morphometric Measurements

The number of Kupffer cells in the liver was counted by using 20X per 10 sections. An ocular stage micrometer was used to measure the glomerular diameters, Bowman's space width, and the length and width of both the proximal and distal convoluted tubules. Measurements were done by using 20X per 10 sections.

Immunohistochemical Investigations

According to Hsu et al. (1981), the 4-micron section from the liver, kidney, and cerebellum was processed to assess the immunohistochemical expression of proliferating cell

nuclear antigen (PCNA) and *B-cell lymphoma* (Bcl₂). The software image j was used to determine the intensity of both PCNA and Bcl₂ expressions in the liver, kidney, and cerebellum sections were measured.

Statistical Assessment

The obtained data were expressed as mean ± standard deviation (Mean ± SD). The statistical package for social science (SPSS) program, version 20, was used to do the statistical analysis (Inc., Chicago, USA). To compare the results, one-way analysis of variance (ANOVA) test was used. At $P < 0.05$, the values were deemed significant.

Results

Effect of different treatments on MDA levels and SOD activity

Comparing animals treated with curcumin to the control group, no observable changes in MDA levels and SOD activity in the liver or kidney tissues were recorded. As opposed to control rats, the MDA levels significantly increased, and SOD activity significantly decreased ($P < 0.05$) in animals treated with orlistat. Compared to the orlistat group, rats treated with both orlistat and curcumin recorded a significant decrease in MDA levels ($P < 0.05$) and a significant increase in SOD activity ($P < 0.05$) (Table 1).

Effect of different treatments on serum dopamine and glutamate levels

Table 1 shows different experimental groups' alterations in serum dopamine and glutamate levels. Both animals in the control and curcumin group have the same levels (at $P < 0.05$) of dopamine and glutamate. Rats treated with orlistat exhibited a significant increase ($P < 0.05$) in dopamine and glutamate levels in comparison with the control group. Treatment with orlistat and curcumin significantly decreased ($P < 0.05$) the elevated levels of dopamine and glutamate compared to the orlistat group.

Histological Observations

The liver

The present study examined liver sections obtained from both the control and curcumin groups revealing normal histological structure

organization. The hepatocytes are organized in cords extending from the central veins. The polygonal hepatocytes had a centrally rounded pale stained nucleus and a granular acidophilic cytoplasm. Between the hepatic cell cords, there are narrow spaces of the hepatic blood sinusoids lined with flat endothelial cells and contained Kupffer cells which showed normal count in both control and curcumin-treated rat (26.0 ± 0.55 and 24.0 ± 0.18 , respectively (Figure 1A, Figures. 2A, B).

Examination of liver sections from the orlistat-treated group revealed many degenerative and necrotic features. The hepatic lobules lacked standard architecture and the hepatic cells appeared with degenerated cytoplasm containing many vacuoles and shrunk irregular or darkly stained nuclei. The central veins were dilated and congested. As well as mononuclear cellular infiltration was also seen. Moreover, the blood sinusoids were dilated and the Kupffer cells became activated and significantly increased in number (26.0 ± 0.55 and 38.0 ± 0.85 , respectively, Figure 1A) when compared with control (Figures 2C-E). Animals treated with both orlistat and curcumin showed an obvious improvement. Most of the hepatocytes seemed normal and the dilated central veins nearly disappeared. But some blood sinusoids remained dilated (Figure 2F). Moreover, the number of Kupffer cells was significantly decreased when compared to the orlistat group (38.0 ± 0.85 and 29.0 ± 0.48 , respectively (Figure 1A).

The kidney

The normal architecture of the renal cortex was seen in kidneys obtained from both control rats and animals treated with curcumin. The kidney is consisting of two main parts the outer one, the cortex which is covered externally with a fibrous coat, and the inner part, the medulla. Anatomically, the kidney consists of a large number of nephrons that are responsible for its filtration function. The nephron is composed of Malpighian corpuscles, tubules that are twisted to form proximal and distal convoluted tubules which open in the collecting tubules. The Malpighian corpuscle is made up of Bowman's capsule which is a double-layer cup structure, and the glomeruli which are composed of

clusters of blood capillaries. The urinary space exists between the two layers of Bowman's capsule. The proximal section of the renal tubule has a narrow lumen. Its lining cuboidal epithelia has acidophilic cytoplasm and centrally rounded euchromatic nuclei and has a prominent brush border. While the distal section of the renal tubules is lined with small and flat cuboidal epithelial cells with apical round nuclei and less acidophilic cytoplasm. The lumen of these tubules is larger than that of the proximal ones and is provided with short microvilli (Figures 3A, B). The glomerular diameters, Bowman's space, and the length and width of the proximal and distal convoluted tubules did not show any significant difference between the curcumin-treated animals and the control ones ($P \leq 0.05$) (Table 1).

Animals given orlistat exhibited extensive tissue abnormalities. The size of Malpighian corpuscles varies; some glomeruli were atrophic, shrunken, or fractured with a widening Bowman's space while others had reduced cellularity. When contrasted to the control group, the orlistat group showed a significant increase in glomerular width and Bowman's space ($P < 0.05$) (Table 1). The degenerated tubular epithelial cells had vacuolated cytoplasm and darkly stained (pyknotic) or karyorrhexis nuclei. The lumens of the degenerated tubules appeared dilated and had a hyaline cast. Also, hemorrhage and leukocytosis were seen (Figures 3C-E). The length and width of the proximal and the distal tubules were significantly increased in comparison to the control group (Table 1).

A notable improvement in kidney architecture appeared in rats given orlistat and curcumin. The glomeruli seemed almost identical to the control ones in size and structure. Additionally, this group revealed a significant decrease ($P < 0.05$) in the glomerular diameter and Bowman's space width when compared with rats treated with orlistat alone. Furthermore, cuboidal cells lined the renal tubules also exhibited normal nuclei and homogeneous cytoplasm, except for a few deteriorated ones (Figure 3F). Furthermore, the dimensions of the renal tubules significantly decreased ($P < 0.05$) although the epithelial height significantly

Table 1. Changes in MDA, SOD, dopamine, glutamate levels, the glomerular diameter, Bowman’s space width (µm), and the proximal convoluted tubules' dimensions (µm) in all the experimental groups.

Groups	Control	Curcumin	Orlistat	Orlistat + curcumin
Liver-MDA (nmol/ml)	7.2±0.54	8.3±0.25	28.0±2.55*	18.4±1.89#
Liver-SOD (nmol/ml)	70.0±3.80	66.0±2.14	31.0±1.55*	51.0±1.70#
kidney-MDA (nmol/ml)	8.0±0.80	7.2±0.33	40.0±2.59*	17.0±1.99#
kidney-SOD (nmol/ml)	60.0±2.98	66.0±2.17	22.0±1.47*	39.0±1.87#
Dopamine (nmol/L)	89.0±2.84	91.0±2.16	210.0±4.65*	125.0±2.25#
Glutamate (µmol/l.)	49.0±1.59	46±.01.36	137.0±3.54*	87.0±1.66#
Glomerular diameter (µm)	55.69±1.09	56.58±1.55	30.56±1.30*	52.23±1.84#
Bowman’s space width (µm)	4.50±0.40	3.68±0.80	15.60±0.60*	6.22±0.55#
Length of proximal convoluted tubules (µm)	10.59±1.14	11.23±1.25	20.0±1.65*	14.18±1.48#
Width of proximal convoluted tubules (µm)	6.60±0.25	7.12±0.57	15.87±0.91*	10.24±0.88#

The data were expressed as mean± standard deviation; (n=8).

* P<0.05 significant difference when compared to the control group.

P<0.05 significant difference when compared to the orlistat group

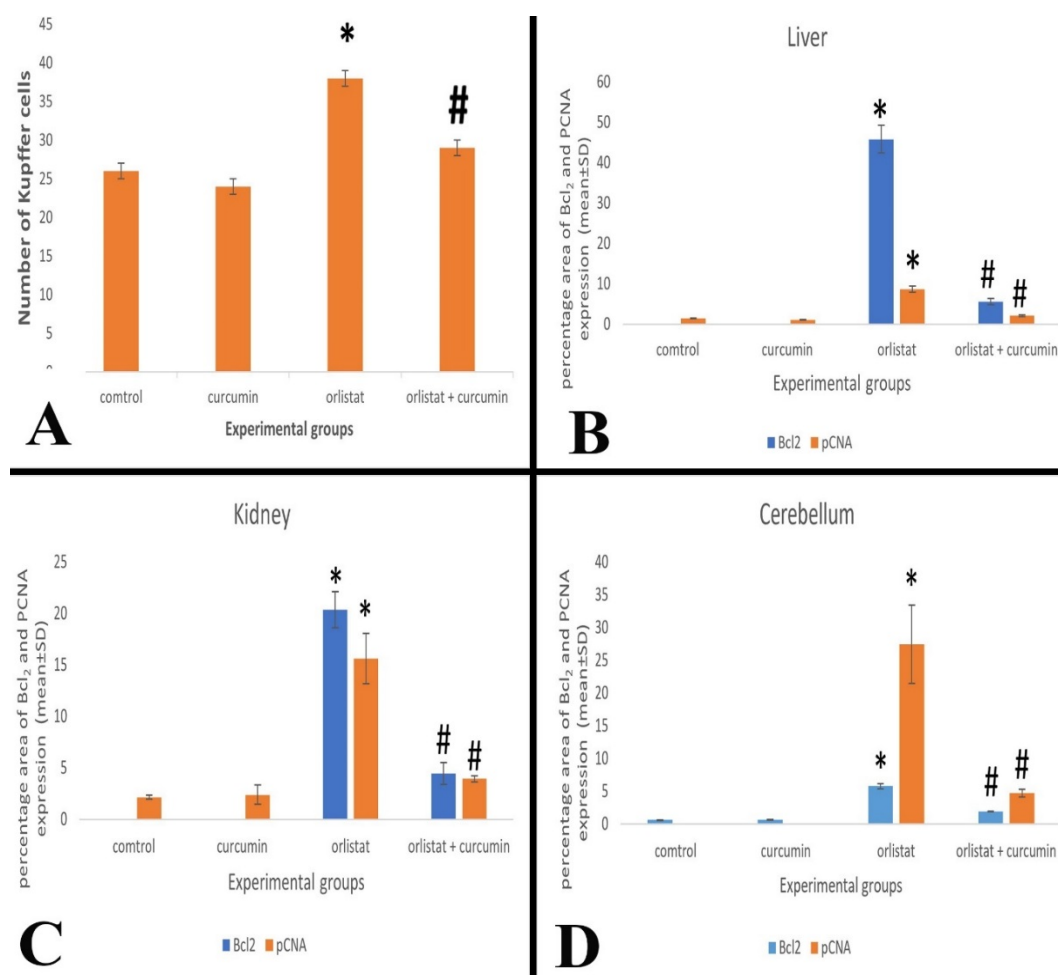


Figure 1. A): Number of Kupffer cells, B-D) the percentage area of PCNA and Bcl₂ expressions in B): the liver, C): kidney, D): cerebellar cortex in all the experimental groups. The data were represented as mean ± standard deviation; (n=8). * P<0.05 significant difference compared to the control group. # P<0.05 significant difference compared to the orlistat group.

increased ($P < 0.05$) after treatment with orlistat and curcumin (Table 1).

The cerebellum

The control and curcumin groups' cerebellar cortex displayed its well-known architecture under light microscopy. The cerebellum consists of outer grey matter and inner white one. The outer layer is found mainly in the covering surface and is known as the cerebellum's cortex. While the white matter is located in the central part and is known as the medulla of the cerebellum. The molecular layer (outer), Purkinje cells layer (middle), and granule cells layer (inner); make up the three layers of grey matter in the cerebellum. The molecular layer, the outer one, is primarily made up of fibers, with a few tiny stellate cells and basket cells. At the intersection of the molecular and granule layers, the Purkinje cell layer revealed giant cells shaped like a flask grouped in one row. These cells had central rounded open-face nuclei with a conspicuous nucleolus surrounded by cytoplasm has Nissl's granules. Each has a slew of dendrites that branch out in the molecular layer. Additionally, the granule neurons were tightly packed together in the granule layer and had minimal cytoplasm and darkly stained nuclei (Figures 4A-C).

The rats treated with orlistat revealed disorganization and structural changes in their cerebellar cortex. The molecular layer was characterized by a prominent spongiosis in the form of numerous vacuolated regions. Purkinje cells displayed a prominent disorganized of the typical linear structure, with some cells pushed higher in the molecular layer and others moved to the granule layer. Also, the degenerated Purkinje cells looked pyknotic, irregular, distorted, and shrunk; they were enclosed in empty spaces. The granule layer is depleted with clumps of pyknotic cells with intercellular eosinophilic areas (necrosis). Moreover, the sub meningeal blood vessels were congested (Figures 4D-E).

Treating animals with curcumin and orlistat showed a remarkable improvement in the structure of the cerebellar tissue. The granule cells appeared mostly with standard features; the cytoplasm and the nuclei were improved. The Purkinje cells were arranged in one layer,

but a few of them still seemed degenerated. The congestion in the sub meningeal blood was decreased, and the spongiosis in the molecular layer nearly disappeared (Figure 4F). Effect of different treatments on Bcl₂ and PCNA expressions in liver, kidney and cerebellum

Immunohistochemical expression of Bcl₂ appeared negative in the cytoplasm of the liver cells of the control animals and the curcumin-treated ones (Figures 5A, B). At the same time, PCNA expression appeared in a few nuclei of the hepatic cells in both the control and the curcumin group (Figures 5E, F). There was a non-significant difference (1.430 ± 0.085 & 1.12 ± 0.014 and 0.00 & 0.00 , respectively) in the percentage area of PCNA and Bcl₂ expressions, respectively, in the curcumin and the control group. In rats treated with orlistat, a great number of hepatic cells expressed Bcl₂ and PCNA as a brown color in their cytoplasm and their nuclei, respectively, (Figures 5C, G). A significant rising (1.43 ± 0.085 & 8.63 ± 0.79 , and 0.00 & 45.79 ± 3.45 , respectively) appeared in the percentage area of PCNA and Bcl₂ expressions, respectively, ($P \leq 0.05$) (Figure 1B). On the contrary, animals given orlistat, and curcumin showed a reduction in the number of hepatic cells expressed PCNA (in their nuclei) and Bcl₂ (in their cytoplasm) (Figures 5D, H). The percentage area of PCNA and Bcl₂ expressions (8.63 ± 0.79 & 2.11 ± 0.23 , respectively, and 45.79 ± 3.45 & 5.89 ± 0.74 , respectively) were significantly decreased in the same group when compared to the orlistat group (Figure 1B).

Figures 8 to 10 showed changes in the immunohistochemical expressions of PCNA and Bcl₂ of kidneys in the different experimental groups. The expression of Bcl₂ was negative in the cytoplasm of glomeruli and renal tubular cells in the control and the curcumin group (Figures 6A, B). In contrast, the expression of PCNA appeared (as a brown color) in a few numbers of the glomeruli and the renal tubular cell nuclei in both the control and curcumin groups (Figures 6E, F). There wasn't any significant change in the expressions of both PCNA and Bcl₂ between the curcumin and the control group (% area was 2.14 ± 0.19 & 2.39 ± 0.93 , respectively and 00.00 & 00.00 , respectively, Figure 1C). Sections obtained from rats treated with orlistat showed expressions of

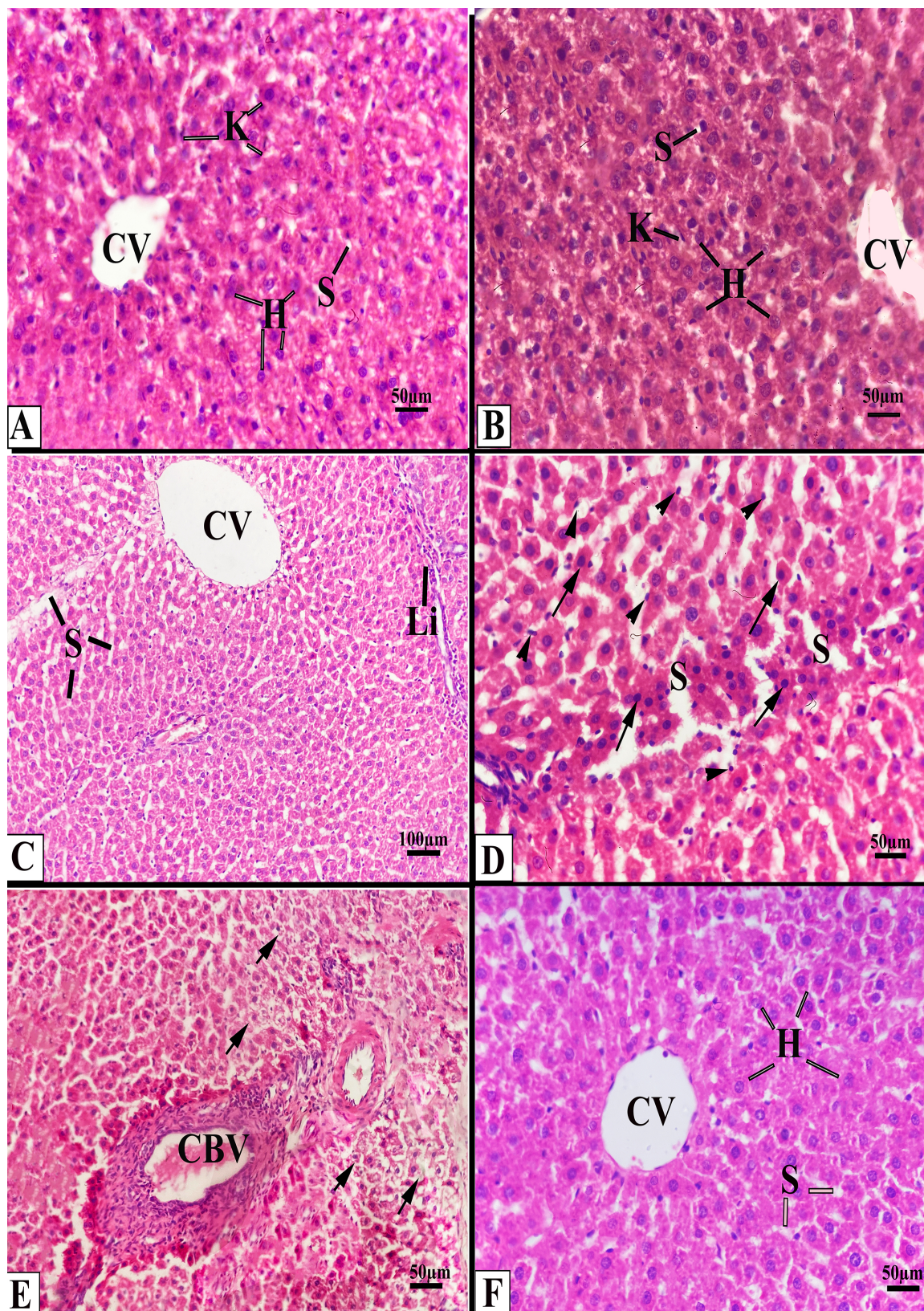


Figure 2. Photomicrographs of sections from the liver. A): control rat showing normal hepatocytes (H), Kupffer cell (K), central vein (CV), and blood sinusoids (S). B): rat treated with curcumin showing standard liver structure. C-E): rats received orlistat C): dilation in the blood sinusoids (S), the central vein (CV), and leucocytic infiltration (Li). D): hepatocytes with shrunken and densely stained nuclei (arrows), a large number of activated Kupffer cells (arrowheads), and dilated sinusoids (S). E): hepatocytes with vacuolated cytoplasm (arrows) and congested blood vessels (CBV). F): rat received orlistat and curcumin, showing approximately normal hepatocytes (H), central vein (CV), and blood sinusoids (S).

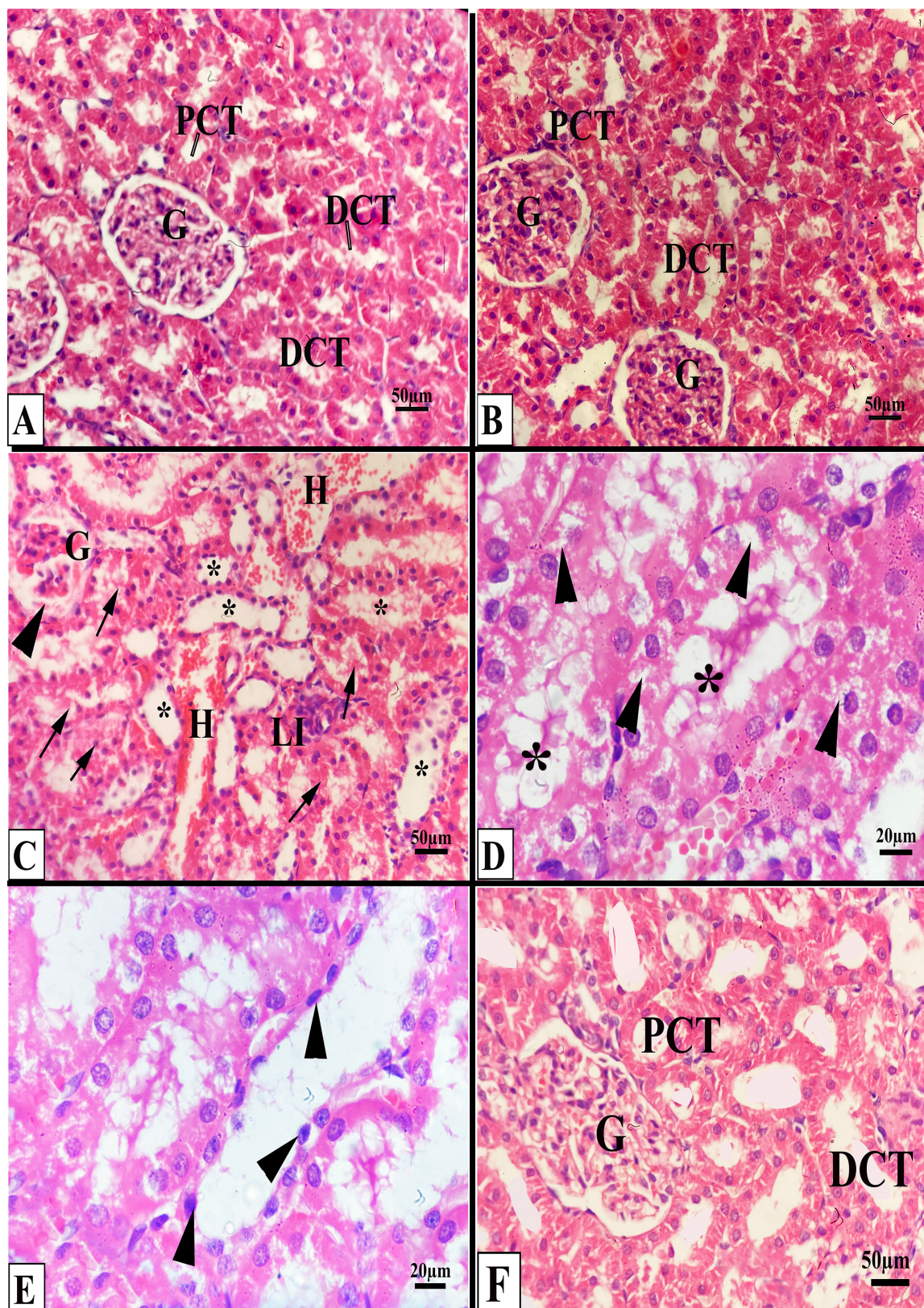


Figure 3. Photomicrographs of the kidney sections. A): control, B): rat received curcumin showing normal glomeruli (G), distal and proximal convoluted tubule (DCT and PCT, respectively). C-E): rats treated with orlistat C): atrophic, fractured glomeruli (G), widened Bowman's space (arrowhead), dilated renal tubules (+), hyaline cast (arrows), leucocytic infiltration (LI), and hemorrhage (H). D): degenerated tubules (+) with vacuolated cells (arrowheads). E): pyknotic nuclei (arrowheads). F): rat treated with orlistat and curcumin showing approximately normal glomeruli (G), distal and proximal convoluted tubules (DCT and PCT, respectively).

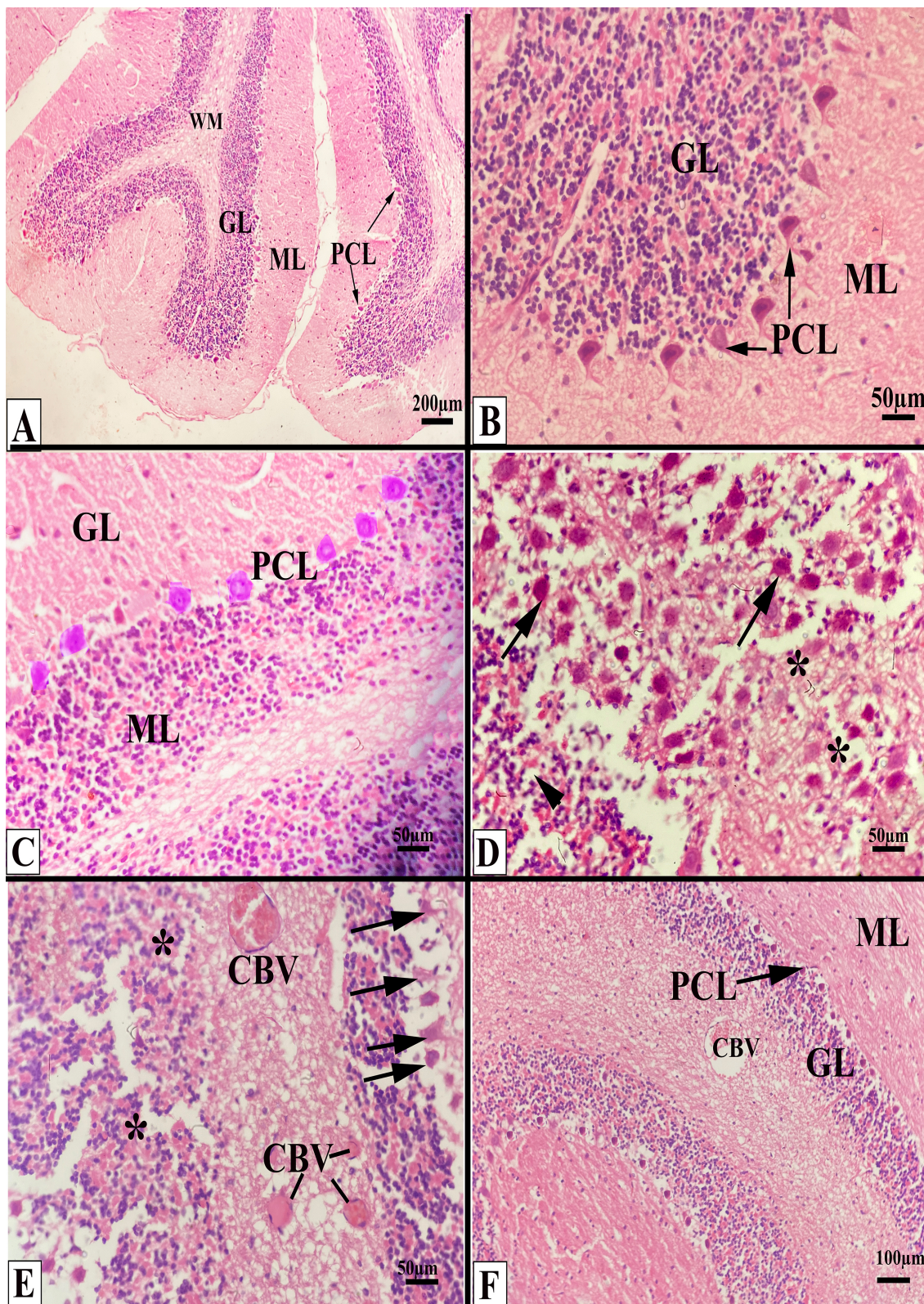


Figure 4. Photomicrographs obtained from the cerebellum. A, B): control rats, C): rat received curcumin showing ordinary white matter (WM), granule cells layer (GL), molecular layer (ML), and Purkinje cell layer (PCL). D, E): rats treated with orlistat D): depleted granule layer (arrowhead), spongy molecular layer (*), disarrangement of the degenerated Purkinje cells (arrows). E): degenerated pyknotic Purkinje cells, irregular and enclosed in empty spaces (arrows), pyknotic granule cells with intercellular eosinophilic areas (*), and congested blood vessels (CBV). F): rats treated with orlistat and curcumin showing approximately normal molecular layer (ML), Purkinje cell layer (PCL), granule cells layer (GL), and some congested blood vessels (CBV) still appeared.

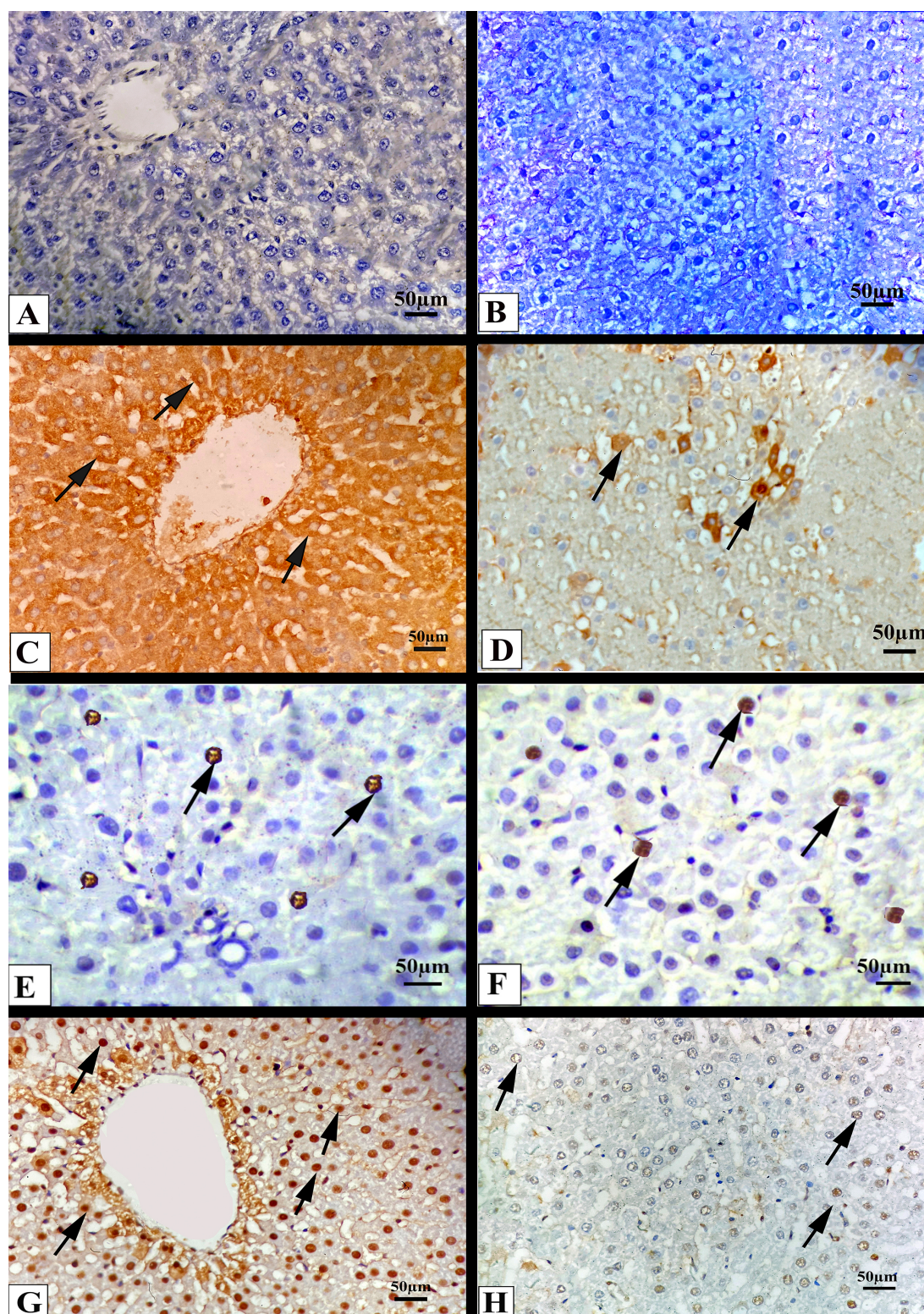


Figure 5. Photomicrographs of sections from liver sections showing Bcl₂ expression. A): control rat. B): animal treated with curcumin showing negative Bcl₂ expression. C): animal treated with orlistat showing positive expression of Bcl₂ in the cytoplasm of numerous hepatocytes (arrows). D): animal treated with orlistat and curcumin showing positive Bcl₂-expression in the cytoplasm of a few hepatocytes (arrows). **Photomicrographs from E to H of liver section showing PCNA expression** E): control rat, F): animal treated with curcumin showing few hepatic cells expressed PCNA as a brown color in their nuclei (arrows). G): animal treated with orlistat showing a large number of hepatic cells expressed PCNA in their nuclei (arrows). H): animal treated with orlistat and curcumin showing few hepatic cells expressed PCNA in their nuclei (arrows).

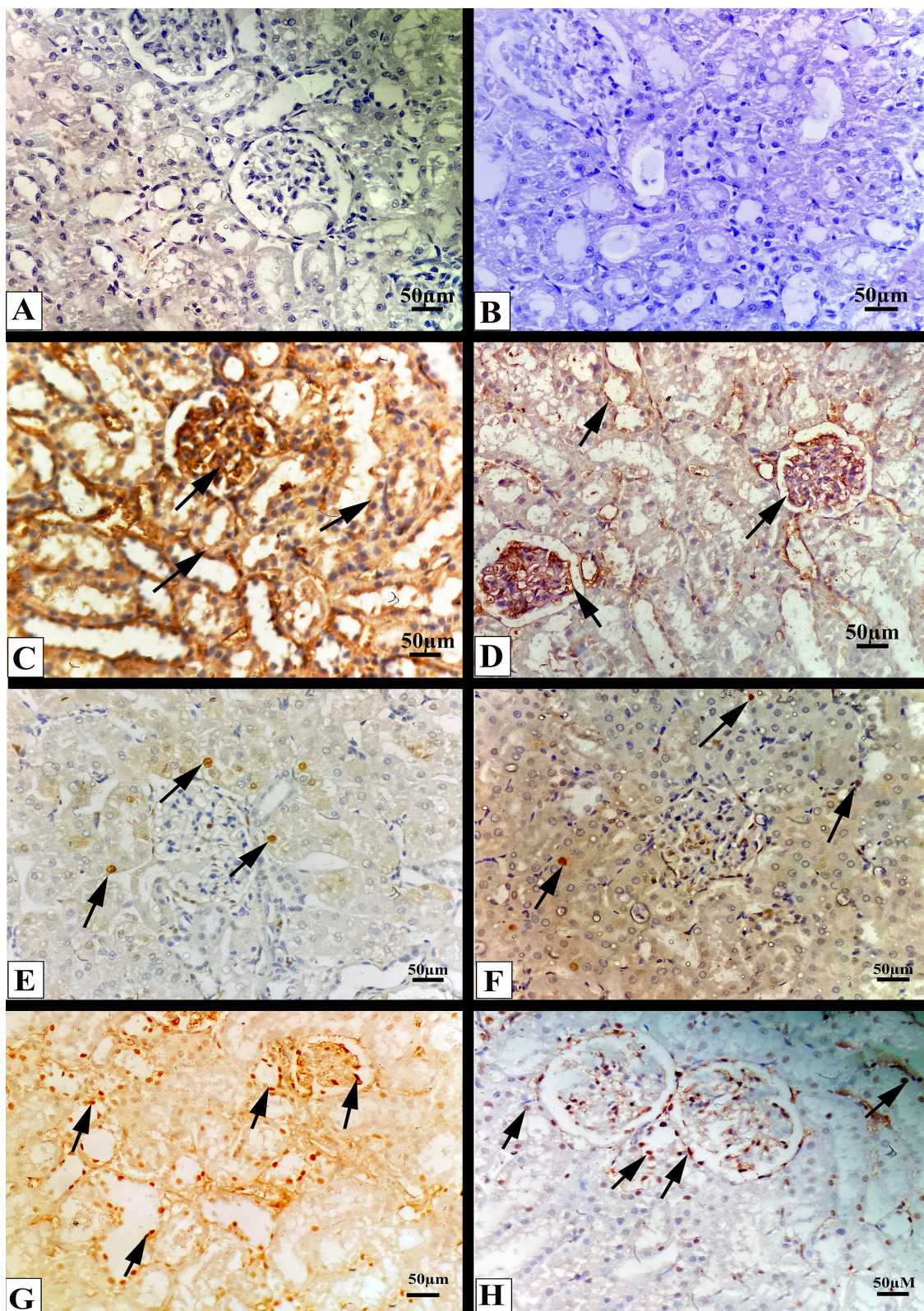


Figure 6. Photomicrographs of sections from renal cortex showing Bcl₂ expression. A): control animal and B): animal treated with curcumin showed negative expression of Bcl₂. C): Animals treated with orlistat showed many glomerular and tubular cells expressing Bcl₂ in their cytoplasm (arrows). D): Animals treated with orlistat and curcumin showed few glomerular and tubular cells expressed Bcl₂ in their cytoplasm (arrows). **Photomicrographs from E to H of renal cortex showing PCNA expression** E): control rat, F): animal treated with curcumin showed few renal tubular cells expressed PCNA in their nuclei (arrows). G): Animals treated with orlistat showed many glomerular PCNA in their nuclei (arrows). H): Animals treated with orlistat and curcumin showed few glomerular and tubular cells expressed PCNA in their nuclei (arrows).

Bcl₂ and PCNA in the cytoplasm and nuclei, respectively, of the glomeruli and the renal tubular cells (as a brown color) (Figures 6C, G), which record a significant increase (2.14 ± 0.19 & 15.62 ± 2.45 , respectively and 0 & 20.36 ± 1.75 , respectively) in the percentage area of PCNA and Bcl₂ expressions in comparison with the control group (Figure 1C). When orlistat was combined with curcumin the expressions of Bcl₂ and PCNA in the cytoplasm and the nuclei, respectively, of the glomeruli and the renal tubular cells was decreased (Figures 6D, H). The percentage area of nuclear PCNA and cytoplasmic Bcl₂ expression was significantly reduced (15.62 ± 2.45 & 3.93 ± 0.32 , respectively, and 20.36 ± 1.75 & 4.46 ± 1.06 , respectively) when compared with the orlistat group (Figure 1C).

The cerebellar immunohistochemical expressions of both PCNA and Bcl₂ in the various experimental groups were illustrated in figure 7. The animal in the control and the curcumin group expressed Bcl₂ in a few Purkinje cells (their cytoplasm) as a brown color. There is no expression of Bcl₂ in the cells of the molecular and the granular layer (Figures 7 A, B). In contrast, PCNA expression was negative in the nuclei of Purkinje and granule cells (Figures 7E, F). The percentage area of PCNA (00.00 & 00.00, respectively) and Bcl₂ (0.62 ± 0.006 & 0.64 ± 0.009 , respectively) showed a non-significant difference between the curcumin and the control group (Figure 1D). Rats received orlistat showed rising in Bcl₂ expression which appeared in many Purkinje cells, molecular neurons and granule cells (in their cytoplasm) as a brown color (Figure 7C). Moreover, the expression of PCNA appeared in the nuclei of Purkinje cells, molecular neurons and granule cell layer as brown color (Figure 7G). In this group, the percentage area of PCNA (00.00 & 27.44 ± 5.96) and Bcl₂ (0.62 ± 0.006 & 5.77 ± 0.39) expressions recorded a significant rising in comparison to the control group. On the contrary to that, animals received orlistat and curcumin showed the Bcl₂ and PCNA expressions in the cytoplasm and the nuclei, respectively, of a few Purkinje cells and granule cells (Figures 7D, H, respectively) and showed a significant decrease in the percentage area of PCNA and Bcl₂ (27.44

± 5.96 & 4.69 ± 0.57 , respectively, and 5.77 ± 0.39 & 0.053 , respectively) expressions when compared with orlistat group (Figure 1D).

DISCUSSION

Obesity is a medical disorder in which a person's body fat accumulation has reached a point where it may be harmful, decreasing their lifespan and contributing to additional health problems. In this study, rats that received orlistat had severe pathological changes in the liver tissue which may happen because it caused oxidative stress, which affects the function of mitochondria, the production of adenosine triphosphate, and the integrity of the cell membrane. In this concern, Chvanov et al. (2005) reported that when free radicals were produced, the cell damage increased by creating lesions in the cell membrane cytoskeleton and DNA damage. In agreement with our results, Filippatos et al. (2008) and Youssef (2018) found similar pathological changes and reported that the usage of orlistat was linked to adverse hepatic consequences like cholestatic hepatitis, cholelithiasis, and subacute liver failures.

The inflammatory cellular infiltration seen in the current research after orlistat treatment may be due to enhancing the production of inflammatory mediators. Moreover, the blood vessel congestion and dilation that appeared in this study may be due to the excess nitric oxide (NO) production caused by orlistat. Similarly, Panek and Zasada (2007) confirmed this suggestion and reported that inducible NO synthase led to local hemodynamic disturbances. McDuffie et al. (2002) attributed the pathogenesis of the orlistat to its ability to cause deficiency of fat-soluble vitamins E and D. AbdelWahab et al. (2017) also found rising in the tumor necrosis factor α (TNF α) expression in tissue macrophages after orlistat treatment for eight consecutive weeks. Tumor necrosis factor α can stimulate cell death through necrosis and apoptosis. Similarly, Bu et al. (2005) reported that TNF α and other inflammatory mediators produced by hepatocytes promote liver damage and leukocytic infiltration.

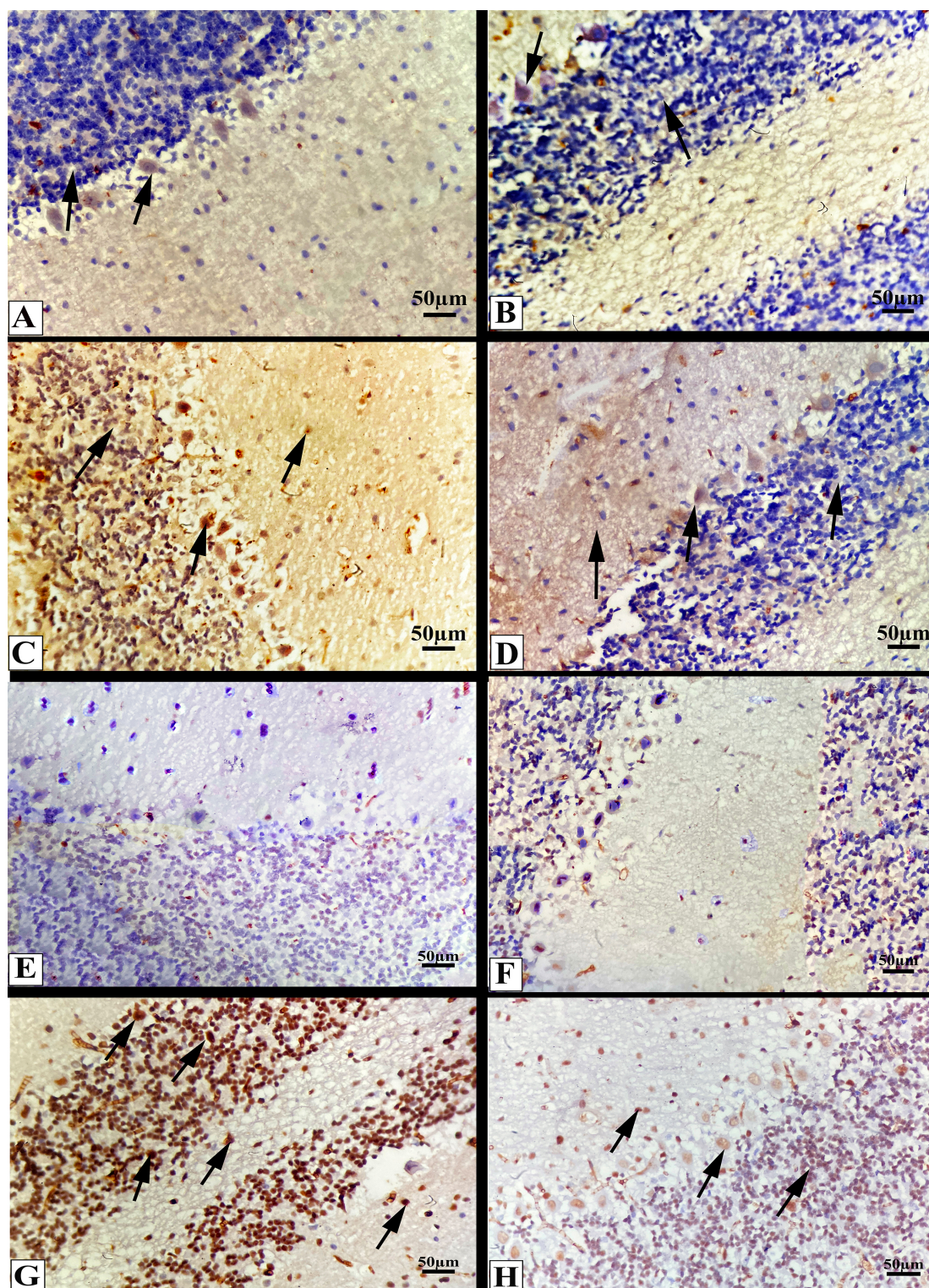


Figure 7. Photomicrographs of sections from the cerebellar cortex showing Bcl₂ expression. A): control rat, B): animal treated with curcumin showing expression of Bcl₂ in the cytoplasm of Purkinje cells as a brown color (arrows). C): animal treated with orlistat showing positive expression of Bcl₂ in Purkinje cells, molecular neurons, and granule cells cytoplasm (arrows). D): animal treated with orlistat and curcumin showing Bcl₂ expression in a few Purkinje cells, granule, and molecular cells cytoplasm (arrows). **Photomicrographs from E to H showing PCNA expression in cerebellar cortex** from E): control rat, F): animal treated with curcumin showing negative expression of PCNA in Purkinje and granule cells nuclei. G): animal treated with orlistat showing positive PCNA expression in Purkinje, molecular neurons, and granule cells nuclei (arrows). H): animal treated with orlistat and curcumin showing PCNA expression in the nuclei of a few Purkinje, molecular, and granule cells (arrows).

In the present work, the renal cortex of animals treated with orlistat exhibited extensive tissue abnormalities includes the glomeruli, proximal and distal convoluted tubules. These changes may be related to a rise of unabsorbed fat in the small intestine, increased oxalate absorption, and excretion after orlistat treatment. Hence, the renal tubules become stressful, increasing the risk of acute kidney damage. Macedo et al. (2003) and Ahmed (2010) found that orlistat treatment caused enteric hyperoxaluria, which is caused by intestinal fat absorption problems and results in the development of calcium soaps and a decrease in the free enteric calcium so the renal tubules become supersaturated and calcium oxalate crystals form, increasing the risk of acute kidney damage.

The present results revealed that rats treated with orlistat showed disorganization and structural changes in the cerebellar cortex. This could be because of an increase in the production of free radicals initiated by orlistat which rapidly affects the central nervous system. Moreover, orlistat has been linked to a higher incidence of neurological abnormalities (Sriram et al., 2002). Calderón Guzmán et al. (2011) showed that orlistat endogenous metabolism initiates ROS production caused oxidative stress in the brain and make damage.

The immunohistochemical results of this study revealed a significant increase in PCNA expression after orlistat treatment. This effect may be attributed to a deficiency of fat-soluble vitamins A and D after orlistat treatment. Vitamin A is crucial for controlling cells' development and differentiation. Additionally, vitamin D stimulates the proliferation and migration of epithelial cells (Sun and Kawaguchi, 2011; Nazzal et al., 2016). In the present study, Bcl₂ expression increased after orlistat treatment, possibly due to inducible NO activation. The NO caused apoptosis by suppressing p53 protein, damaging mitochondrial, alternating the Bcl₂ expression, activating the caspase cascade, and causing DNA fragmentation (Umansky and Schirrmacher, 2001). Moreover, Atiq et al. (2009) found that apoptosis happened due to mitochondrial malfunction that results from ROS and lipid peroxidation products. Moreover, Youssef (2018) reported that the moderately

positive cytoplasmic and nuclear caspase-3 immune reactions in the orlistat-treated group clarified that apoptosis is one of the causes of histopathological and biochemical changes detected after orlistat treatment. The author added that orlistat caused swelling to the mitochondria and impaired their function. This disturbance happened due to oxidative stress that released active cytochrome C from mitochondria into the cytoplasm to elevate the apoptosis cascade (Aliev et al., 2010).

Based on the biochemical results of this study, orlistat treatment significantly increased MDA levels and significantly decreased SOD activity. Moreover, there was a significant increase in dopamine and glutamate levels compared with the control group. The biochemical disturbance after orlistat may be related to histological destructions resulting from oxidative stress. In line with our findings, Chvanov et al. (2005) found that when an injury happened, ROS was increased and caused a reduction in the intercellular protein function and lower antioxidant levels.

In the present study, animals treated with curcumin only did not show any pathological, biochemical and immunohistochemical changes in all investigated tissues, which confirmed its recommendation to use as a food supplement for human health as previously reported by (Khudhair et al., 2022; Al-Attar, 2022; Hu et al., 2022).

Due to the antioxidant characteristics of curcumin, rats treated with orlistat and curcumin recorded a significant lowering in the level of MDA and a significant rising in the activity of SOD. Because of its dual antioxidant properties, curcumin has phenolic groups in its structure that allow it to react with reactive species, directly and indirectly, stimulating the production of cytoprotective and antioxidant proteins, including SOD and catalase (Al-Attar, 2022; Dinkova-Kostova and Talalay, 2008). Curcuminoids work as an antioxidant; it contains the phenolic hydroxyl groups which are involved in stopping ROS production, lipid peroxidation, and getting rid of free radicals, as well as it can boost phase II antioxidant enzymes by activating the nuclear factor erythroid 2, p45,

nuclear-related factor-2, antioxidant response element axis (Calabrese et al., 2008).

According to Khudhair et al. (2022), curcumin treatment resulted in rising SOD activity, glutathione levels in liver tissue, and a significant drop in MDA levels. Curcumin was also reported to prevent induced kidney damage by upregulating antioxidant genes (CAT, SOD1, and GCLM) (Wang et al., 2022). This improving effect may be retained in the antioxidant properties, which inhibited the induced oxidative stress. Curcumin decreased brain MDA levels while increasing SOD activity and glutathione levels (Alhusaini et al., 2022). Hasan et al. (2020) reported that curcumin protected brain cells by raising SOD, and catalase activities, reducing lipid nitric oxide and peroxidation levels.

Rats treated with orlistat and curcumin recorded a significant increase in dopamine and glutamate levels compared with rats who received orlistat alone, which could be attributed to curcumin's anti-inflammatory properties and the improvement in cerebellar architecture that was revealed in the current study. Curcumin and its derivatives have anti-inflammatory properties because hydroxyl and phenol groups are present in its chemical structure, which is required to inhibit prostaglandins and leukotriene (Claeson et al., 1993; Claeson et al., 1996).

Treating rats with orlistat and curcumin improves the histological picture in the liver, kidney, and cerebellum. This improvement may be due to the ability of curcumin to interact with reactive oxygen species to lessen the oxidative damage induced by orlistat. According to Hu et al. (2022), curcumin had a hepatoprotective effect in sepsis by inhibiting inflammatory responses and suppressing hepatocyte apoptosis by up-regulating peroxisome proliferator-activated receptors. Its activations block the transcription of the NF- κ B gene, thereby blocking the secretion and activation of NF- κ B and inflammatory factors, decreasing tissue damage.

Ghosh et al. (2012) reported that curcumin's reno-protective effect impacts by decreasing inflammation via inhibiting the inflammatory mediators such as TNF-A and interleukin 1 β ,

which are overexpressed, and increasing the production of other cytokines by leukocytes and vascular endothelial cells. This is accomplished by activating phospholipase two and cyclooxygenase 2, essential regulators of inflammation and oxidative stress inductors. Additionally, Abubakar et al. (2020) discovered that curcumin prevents the generated hepatorenal damage by inhibiting oxidative stress and acting as a chelator.

Hasan et al. (2020) found that curcumin improved the induced histopathological effect, including Purkinje cells and perineuronal vacuolation, due to its capacity to regulate oxidative stress via scavenging ROS. Alhusaini et al. (2022) reported that curcumin is a potent antioxidant that can modulate all the altered histopathological alterations in the brain after lead acetate toxicity. Curcumin was proven to be a powerful antioxidant due to H-atom found in the free hydroxyl group, which has a free radical scavenging activity (DPPH \bullet , ABTS $\bullet+$, O $_2$ \bullet , and DMPD $\bullet+$), hydrogen peroxide scavenging activity, and reactive radicals scavenging activity (HO \bullet , ROO \bullet). The neuroprotective action of curcumin has activity against the dysfunction in rat brain, probably explained by reducing alteration in proapoptotic and anti-apoptotic proteins (Srivastava et al., 2014; Srivastava et al., 2018).

Compared to the orlistat group rats treated with curcumin and orlistat showed significant reduction in PCNA and Bcl2 expressions. This could be related to curcumin's antiapoptotic effects. Curcumin's anti-apoptotic characteristics are demonstrated by its ability to boost caspase-activated DNase and Bcl2 expression while decreasing apoptotic cell percentage, Bax expression, cleaved-Caspase-3, and Caspase-9 expression in the kidney (Wang et al., 2022).

CONCLUSIONS

This study concluded that orlistat caused an apparent injury in the liver, kidney, and cerebellum of obese rats. Having curcumin with orlistat may minimize these toxic effects due to its anti-inflammatory and antioxidant activities. More research is still needed to clarify orlistat

toxicity and confirm the potential role of curcumin in its treatment.

ABBREVIATIONS

malondialdehyde (MDA), superoxide dismutase (SOD), Proliferating cell nuclear antigen (PCNA) and B-cell lymphoma 2 (Bcl2), statistical package for social science (SPSS), nitric oxide (NO), nuclear factor-B (NF-B) tumor necrosis factor α (TNF α), reactive oxygen species (ROS).

FUNDING

This research received no specific grant from public, commercial, or not-for-profit funding agencies.

CONFLICT OF INTEREST

The authors declare no conflict of interest.

REFERENCES

- Abdelwahab S, Ali A, & Mahmoud A, (2017). Effect of Orlistat on the pancreas of the female albino rat: Histological and Histochemical study. *J. Med. Histol.* 1(1):30-43.
- Abubakar K, Mailafiya MM, Chiroma SM, Danmaigoro A, Zyoud TY, Abdul Rahim E and Abu Bakar Zakaria M Z, (2020): Ameliorative effect of curcumin on lead-induced hematological and hepatorenal toxicity in a rat model. *JBM.* 34(6): e22483. DOI: 10.1002/jbt.22483
- Aggarwal BB and Harikumar KB, (2009): Potential therapeutic effects of curcumin, the anti-inflammatory agent, against neurodegenerative, cardiovascular, pulmonary, metabolic, autoimmune, and neoplastic diseases. *Int. J. Biochem. Cell Biol.* 41(1):40-59.
- Ahmed M, (2010): Orlistat and calcium oxalate crystalluria: an association that needs consideration. *Renal Failure.* 32:1019-1021.
- Al-Attar AM, (2022): Hematological and biochemical investigations on the effect of curcumin and Thymoquinone in male mice exposed to Thioacetamide. *Saudi J. Biol. Sci.* 29(1):660-665.
- Alhusaini AM, Fadda LM, Alsharafi H, Alshamary, AF and Hasan IH, (2022): L-Ascorbic acid and curcumin prevents brain damage induced via lead acetate in rats: possible mechanisms. *Dev. Neurosci.* 44(2):59-66.
- Aliev G, Palacios HH, Gasimov E, Obrenovich ME, Morales L, Leszek J, Bragin V, Herrera AS and Gokhman D, (2010): Oxidative stress induced mitochondrial failure and vascular hypoperfusion as a key initiator for the development of Alzheimer disease. *Pharma.* 3(1):158-187.
- Atiq M, Davis JC, Lamps LW, Beland SS and Rose JE, (2009): Amiodarone Induced liver cirrhosis. report of two cases. *JGLD.* 18: 233-235.
- Ballinger A and Peikin SR, (2002): Orlistat: its current status as an anti-obesity drug. *Eur. J. Pharmacol.* 440(2-3):109-117.
- Beauchamp C and Fridovich I, (1971): Superoxide dismutase: improved assays and an assay applicable to acrylamide gels. *Anal. Biochem.* 44: 276-287.
- Bu DX, Erl W, De Martin R, Hansson GK and Yan ZQ, (2005): IKK β -dependent NF- κ B pathway controls vascular inflammation and intimal hyperplasia. *The FASEB Journal.* 19(10):1293-1295.
- Calabrese V, Bates TE, Mancuso C, Cornelius C, Ventimiglia B, Cambria MT, Di Renzo, L, De Lorenzo, A and Dinkova-Kostova AT, (2008): Curcumin and the cellular stress response in free radical-related diseases. *Mol. Nutr. Food Res.* 52(9):1062-1073.
- Calderón Guzmán D, Hernandez Garcia E, Juarez Jacobo A, Segura Abarca L, Barragan Mejia G, Rodriguez Perez R and Juarez Olguin H, (2011): Effect of orlistat on lipid peroxidation, Na⁺, K⁺ ATPase, glutathione and serotonin in rat brain. *Proc. West Pharmacol. Soc.* (54): 73-77.
- Caner M, Dogruman H, Taskin ER, Kandil A and Demirci C, (2005): Effects of orlistat and its relationship with nitric oxide in the small intestinal mucosa. *Chin. J. Physiol.* 48(4):217-222.
- Chvanov M, Petersen OH and Tepikin A, (2005): Free radicals and the pancreatic acinar cells: role in physiology and pathology. *Philos. Trans. R. Soc. Lond. Biol. Sci.* 360:2273–2284.
- Claeson P, Panthong A, Tuchinda, P, Reutrakul, V, Kanjanapothi, D, Taylor, WC and Santisuk T, (1993): Three non-phenolic diarylheptanoids with anti-inflammatory activity from *Curcuma xanthorrhiza*. *Planta Med.* 59(05):451-454.
- Claeson P, Pongprayoon U, Sematong T, Tuchinda P, Reutrakul V, Soontornsaratune P and Taylor WC, (1996): Non-phenolic linear diarylheptanoids from *Curcuma xanthorrhiza*: a novel type of topical anti-inflammatory agents: structure-activity relationship. *Planta med.* 62(03):236-240.
- Dinkova-Kostova AT and Talalay P, (2008): Direct and indirect antioxidant properties of inducers of cytoprotective proteins. *Mol. Nutr. Food Res.* 52(S1): S128-S138.
- Duvoix A, Blasius R, Delhalle S, Schnekenburger M, Morceau F, Estelle H, Dicato M and Diederich M, (2005): Chemopreventive and therapeutic

- effects of curcumin. *Cancer Lett.* 223(2):181-190.
- Elshama SS, El-Kenawy AE and Osman HE, (2016): Curcumin improves atorvastatin-induced myotoxicity in rats: histopathological and biochemical evidence. *Int J Immunopathol. Pharmacol.* 29(4):742-752.
- Ezzat AM and Labah DA, (2017): Comparative study of the effects of orlistat and green coffee bean extract on tongue mucosa in obese rat model. *Life Sci.* 14(8):11-18.
- Filippatos TD, Derdemezis CS, Gazi IF, Nakou ES, Mikhailidis DP and Elisaf MS, (2008): Orlistat-associated adverse effects and drug interactions. *Drug Saf.* 31(1):53-65.
- Flegal KM, Carroll MD, Ogden CL, Johnson CL, (2002): Prevalence and trends in obesity among US adults, 1999-2000. *JAMA.* 288(14):1723-1727.
- Ghosh A, Pallavi SK, Nagpal B, Hegde U, Archana S and Nagpal J, (2015): Role of Vitamins in Oral Health & Disease: An Overview. *Indian J. Appl. Res.* 5 (12): 292-295.
- Ghosh SS, Krieg R, Massey HD, Sica DA, Fakhry I, Ghosh S, and Gehr TW, (2012): Curcumin and enalapril ameliorate renal failure by antagonizing inflammation in % nephrectomized rats: role of phospholipase and cyclooxygenase. *Am. J. Physiol. Renal Physiol.* 302(4): F439-F454.
- Hasan W, Kori RK, Jain J, Yadav RS and Jat D, (2020): Neuroprotective effects of mitochondria-targeted curcumin against rotenone-induced oxidative damage in cerebellum of mice. *JBMT.* 34(1): e22416. DOI: 10.1002/jbt.22416
- Hsu SM, Raine L and Fanger H, (1981): Avidin and biotin in immunohistochemistry. *Histochem. Cytochem.* 29: 1349-1353.
- Hu G, Wang D, Jiang L, Xu L, Zhao L and Zhou M, (2022): Curcumin protects hepatocytes from sepsis by regulating inflammatory response and hepatocyte apoptosis. *Trop. J. Pharm. Res.* 21(1):67-71.
- Indira Priyadarsini K, (2013): Chemical and structural features influencing the biological activity of curcumin. *Curr. Pharm. Des.* 19(11): 2093-2100.
- Jain SK, Rains J and Jones K, (2006): Effect of curcumin on protein glycosylation, lipid peroxidation, and oxygen radical generation in human red blood cells exposed to high glucose levels. *Free Radical Boil. Med.* 41(1):92-96.
- Johansson K, Sundström J, Neovius K, Rössner S and Neovius M, (2010): Long-term changes in blood pressure following orlistat and sibutramine treatment: a meta-analysis. *Obes. Rev.* 11(11):777-791.
- Kalpana C, Sudheer AR, Rajasekharan KN and Menon VP, (2007): Comparative effects of curcumin and its synthetic analogue on tissue lipid peroxidation and antioxidant status during nicotine-induced toxicity. *Singapore Med. J.* 48(2):124-130.
- Kassab AA, Moustafa KA and Abd-El-Hafez AA, (2020): The possible protective role of pumpkin seed oil in ameliorating tongue mucosal damage induced by orlistat in adult male albino rats: A light and scanning electron microscopic study. *Egypt. J. Histol* 43(4):975-987.
- Khudhair DH, Al-Gareeb AI, Al-Kuraishy HM, El-Kadem AH, Elekhawy E, Negm WA, Saber S, Cavalu S, Tirla A, Alotaibi SS and Batiha GES, (2022): Combination of vitamin c and curcumin safeguards against methotrexate-induced acute liver injury in mice by synergistic antioxidant effects. *Front. Med.* 9: 866343. DOI: 10.3389/fmed.2022.866343.
- Macedo AF, Marques FB, Ribeiro CF, Teixeira F, (2003): Causality assessment of adverse drug reactions: comparison of the results obtained from published decisional algorithms and from the evaluations of an expert panel, according to different levels of imputability. *J. Clin. Pharm. Therapeut.* 28(2):137-143.
- McDuffie JR, Calis KA, Booth SL, Uwaifo GI and Yanovski JA, (2002): Effects of orlistat on fat-soluble vitamins in obese adolescents. *Pharmacotherapy.* 22(7):814-822.
- Mira NM, (2017): The potential ameliorative effect of curcumin in *Schistosoma mansoni* infected mice: an ultrastructural study on the testes. *J. Exp. Biol.* 13(2):125-137.
- Mohamed GA, Ibrahim SR, Elkhayat, ES and El Dine RS, (2014): Natural anti-obesity agents. *BFPC.* 52(2):269-284.
- Nairooz S, Ibrahim SH, Omar SM and Affan M, (2010): Structural changes of the colonic mucosa induced by Orlistat: Experimental study. *Egypt. J. Histol.* 33(4):635-648.
- Nazzal A, Tipton Da Karydis A, Slominski A and Stein SH, (2016): Vitamin D stimulates epithelial cell proliferation and facilitates wound closure via a cathelicidin independent pathway in vitro. *Periodon Prosthodon.* 2(2):1-8.
- Paget GE and Bernes JM, (1973): Evolution of drug activities pharmaceutical. Vol. 1 Toxicity tests. Academic Press, New York and London.
- Panchal HD, Vranizan K, Lee CY, Ho J, Ngai J and Timiras PS, (2008): Early anti-oxidative and anti-proliferative curcumin effects on neuroglioma cells suggest therapeutic targets. *Neurochem. Res.* 33(9):1701-1710.
- Panek J and Zasada J, (2007): The role of nitric oxide (NO) in acute pancreatitis. *Przegl. Lek.* 64:495-497.

- Pedraza-Chaverrí, J, Barrera D, Maldonado PD, Chirino YI, Macías-Ruvalcaba NA, Medina-Campos ON, Castro L, Salcedo MI and Hernández-Pando R, (2004): S-allylmercaptocysteine scavenges hydroxyl radical and singlet oxygen in vitro and attenuates gentamicin-induced oxidative and nitrosative stress and renal damage in vivo. *BMC Clin. Pharmacol.* 4(1):1-13.
- Ruiz-Larrea MB, Leal AM, Liza M, Lacort M and de Groot H, (1994): Antioxidant effects of estradiol and 2-hydroxyestradiol on iron-induced lipid peroxidation of rat liver microsomes. *Steroids.* 59(6):383-388.
- Siebenhofer A, Jeitler K, Horvath K, Berghold A, Siering U and Semlitsch T, (2013): Long-term effects of weight-reducing drugs in hypertensive patients. *Cochrane Database Syst. Rev.* 8(3): CD007654. DOI: 10.1002/14651858.CD007654.
- pub3Sriram K, Benkovic SA, Miller DB and O'Callaghan JP, (2002): Obesity exacerbates chemically induced neurodegeneration. *Neuroscience.* 115(4):1335-1346.
- Srivastava P, Dhuriya YK, Gupta R, Shukla RK, Yadav RS, Dwivedi HN, Pant AB and Khanna VK, (2018): Protective effect of curcumin by modulating BDNF/DARPP32/CREB in arsenic-induced alterations in dopaminergic signaling in rat corpus striatum. *Mol. Neurobiol.* 55(1):445-461.
- Srivastava P, Yadav RS, Chandravanshi LP, Shukla RK, Dhuriya YK, Chauhan LK, Dwivedi HN, Pant AB and Khanna VK, (2014): Unraveling the mechanism of neuroprotection of curcumin in arsenic induced cholinergic dysfunctions in rats. *Toxicol. Appl. Pharmacol.* 279(3):428-440.
- Ströfer M, Jelkmann W and Depping R, (2011): Curcumin decreases survival of Hep3B liver and MCF-7 breast cancer cells. *Strahlenther. Onkol.* 187(7):393-400.
- Sun H and Kawaguchi R, (2011): The membrane receptor for plasma retinol-binding protein, a new type of cell-surface receptor. *Int. Rev. Cell Mol. Biol.* 288:1-41.
- Tousson E, Massoud A, Salem A and Fatoh SA, (2018): Nephrotoxicity associated with orlistat in normal and obese female rats. *JBAAR.* 4(3): 193-198.
- Umansky V and Schirmmacher V, (2001): Nitric oxide-induced apoptosis in tumor cells. *Adv Cancer Res.* 82:107-131.
- Venkatesan N, Punithavathi D and Arumugam V, (2000): Curcumin prevents adriamycin nephrotoxicity in rats. *Br. J. Pharmacol.* 129(2):231-234.
- Wang Y, Liu F, Zhou X, Liu M, Zang H, Liu X, Shan A and Feng X, (2022): Alleviation of oral exposure to aflatoxin b1-induced renal dysfunction, oxidative stress, and cell apoptosis in mice kidney by curcumin. *Antioxidants.* 11(6):1082. Doi: 10.3390/antiox11061082
- WHO, (2000): Consultation on Obesity. Obesity: Preventing and Managing the Global Epidemic. Geneva, Switzerland: World Health Organization. WHO Technical Report Series 894.
- Youssef S, (2018): Light and electron microscopic study of the effect of orlistat on the liver of adult male albino rats and the possible protective role of β -carotene. *FMAR.* 6(2):20-36.
- Yu W, Wu J, Cai F, Xiang J, Zha W, Fan D, Guo S, Ming Z and Liu C, (2012): Curcumin alleviates diabetic cardiomyopathy in experimental diabetic rats. *PLoS one.* 2012; 7(12): e52013. DOI: 10.1371/journal.pone.0052013