

Evaluation of the Protective Effect of Silymarin and Nano Encapsulation of Ginger Extract on Hepatotoxicity in Adult Male Albino Rats

Clara E. Kerolus, Bassma M. Dessouki, Gamal M. Abdel-Rahman,
Noha A. Salem*

Department of Human Anatomy and Embryology, Faculty of Medicine, Suez Canal University, Egypt

Abstract

Background: Antioxidant effect of herbal products like Silymarin & Ginger can get rid of free radicals. Nanoparticles can reach the target easily without inactivation, increase the bioavailability of the therapy and reduce its toxicity. **Aim:** To evaluate the protective effect of silymarin and nano-encapsulation of Ginger extract on hepatotoxicity in adult male albino rats. **Materials and Methods:** Eighty rats were randomized into eight groups (10 rats each). Group I (control): subdivided into 3 control subgroups; Group II: rats received nano-encapsulation of ginger extract 50 mg/kg/day by oral gavage every day. Group III: rats received 0.1 ml/100 gm/kg of CCl₄ dissolved in corn oil (1:1) twice a week by intraperitoneal injection. Group IV: Silymarin was given in a dose of 200 mg/kg/day dissolved in one ml distilled water by oral gavage every day with CCl₄. Group V: nano-encapsulation of ginger 50 mg/kg/day by oral gavage every day CCl₄. Group VI: the doses were administrated as in groups II, III & IV for six weeks in all groups. At the end of the experiment, rats were anesthetized, blood samples collected for ALT and AST measurement then sacrificed and the liver was excised, for SOD, H&E, and histoimmunological studies. **Results:** CCl₄-induced hepatotoxicity can be protected by silymarin or/and nano-encapsulation of ginger that showed more improvement than silymarin in histopathological and immunohistochemical, morphometric, SOD, ALT, and AST results. **Conclusion:** The study found that hepatotoxicity can be protected by the administration of silymarin or/and nano-encapsulation of ginger extract. Nano-encapsulation of the ginger extract showed more improvement than silymarin.

Keywords: liver, Experimental, Nano, immunohistochemical, Antioxidant enzymes

Introduction

Liver damage and its complications as fibrosis, cirrhosis and hepatocellular carcinoma became one of the most major causes of morbidity and mortality in the world⁽¹⁾. Standardized death rate of liver fibrosis and its complications in Egypt was 64.4-133.4 per 100.000 according to World Health Organization WHO survey in 2017⁽²⁾.

Liver diseases are more common in Middle East and North Africa especially in Egypt⁽³⁾. There are many causes of liver fibrosis such as chronic hepatitis C&B infection, alcoholic liver, non-alcoholic fatty liver disease (NAFLD), auto immune diseases and toxic substances. According to WHO survey in 2018, liver cirrhosis is the 9th cause of death in developing countries and about 150 million patients have hepatitis C. So, huge

*Corresponding Author: nohasalem@med.suez.edu.eg

numbers of researches were developed to get rid of liver fibrosis and stop its sequelae⁽⁴⁾. Previous research proved that herbal products which are rich in flavonoids protect against liver diseases. These herbal products have an antioxidant effect and can get rid of free radicals that cause lipid peroxidation and membrane damage. Silymarin is one of these herbal products which is extracted from seeds of milk thistle (*silybum marinum*). It is rich in flavonoids which inhibit lipid peroxidation, have antioxidant, anti-inflammatory and anti-fibrotic effect⁽⁵⁾. Ginger (the rhizome of *Zingiber officinale*) is used to treat and protect against various diseases. It has antioxidant activity, anti-inflammatory and can protect the tissue from free radicals that cause oxidative stress and lead to membrane damage and protects against tumors. Ginger also has a great role in protection of liver diseases such as liver fibrosis through inhibition of lipid peroxidation, elevation levels of Super Oxide Dismutase (SOD), Catalase and decreasing liver enzymes such as Alanine Aminotransferase (ALT) and Aspartate Aminotransferase (AST), also has hepatoprotective role against hepatotoxicity induced by Carbon tetrachloride Ccl_4 ⁽⁶⁾. Nanoparticles (NPs) are Nano structures in the nanometer range, NPs have several advantages in treatment of various diseases because it can reach the target tissue easily without inactivation, increase bioavailability of the therapeutic agent, reduce toxicity of it and can increase broad spectrum of administration routes⁽⁷⁾. So, researchers use them in delivery of drugs, proteins, DNA or genes to target tissues especially the liver as they deliver drugs at higher concentration, increase the stability of volatile drugs and have low immunogenicity⁽⁸⁾. The rationale of this study was to evaluate the protective effect of ginger extract

encapsulated in Sodium Alginate NPs compared to Silymarin on hepatotoxicity induced by Ccl_4 in adult male albino rats.

Materials and Methods

Animals

This study was carried out on eighty adult male Sprague Dawley albino rats weighing (150-200 gm). Their ages ranged from 12 to 16 weeks. The animals were brought from the animal house of Faculty of Veterinary Medicine, Suez Canal University. This study was done at the Department of Human Anatomy and Embryology, Faculty of Medicine, Suez Canal University and was approved by the Animal Research Ethics Committee of the Faculty of Medicine, Suez Canal University (Approval number 4026). Animal's care before and during the experimental procedures was done in accordance with the guidelines of the Animal Research Ethics Committee.

Experimental design

Eighty male Sprague Dawley albino rats were randomly divided in eight equal groups (10 rats for each) as follow: Group I (control group) which is divided into three subgroups: Group IA: (negative control group): rats had no intervention. Group IB: (positive control group): rats received one ml corn oil twice a week (three days apart) for six weeks by intra peritoneal injection (IP)⁽⁹⁾. Group IC: (positive control group): rats received one ml sterile distilled water every day orally for six weeks. Group II (nano- encapsulation of Ginger Extract group): normal rats received nano-encapsulation of ginger extract in a dose of 50 mg/kg/day by oral gavage every day for six weeks⁽¹⁰⁾. Group III: (Carbon tetrachloride group (Ccl_4 group)): rats received 0.1 ml/100 gm of body weight of Ccl_4 dissolved in corn oil (1:1) twice a week (three days

apart) for six consecutive weeks by (IP)⁽¹¹⁾. Group IV: (Carbon tetrachloride and Silymarin group): Silymarin powder was given in a dose of 200 mg/kg/day dissolved in one ml distilled water by oral gavage every day for six weeks with CCl₄⁽¹¹⁻¹³⁾. Group V: (Carbon tetrachloride and Nano-Encapsulation of Ginger Extract group): nano-encapsulation of ginger extract was given in a dose of 50 mg/kg/day by oral gavage every day for six weeks with CCl₄^(10,11,14). Group VI: (Carbon tetrachloride, Silymarin and nano-encapsulation of Ginger extract group): Rats were administered the doses as in group II, III & IV for six weeks.

Chemicals

Carbon Tetrachloride was purchased from ADWIC Co, Egypt. Silymarin was purchased from ALFACURE Pharmaceuticals Company, Badr city, Cairo, Egypt as legalon capsules (30 capsules, 140mg). Nano-Encapsulation of Ginger Extract was prepared in National Research Center, Cairo, Egypt.

Physical and chemical properties of Ginger extract and nano-encapsulation form

I-Transmission Electron Microscopy

The morphology of ginger extract and its Nano-Encapsulation form in sodium alginate was obtained by using transmission electron microscopy at 80 kilovolts (JEOL JEM.10.10 EM) at the Regional Center for Mycology and Biotechnology, Al-Azhar University. The samples were observed by operating at 160 kV (Fig 1).

II-Zeta-sizer and Zeta-potential of Ginger extract and its nano-encapsulation form

The size of NPs and zeta potential of ginger extract and nano-encapsulation form sample were measured using dynamic light scattering by Zeta-sizer (Malvern, Model: Zeta-sizer nano series (Nano ZS), United Kingdom). Samples were measured after

five minutes equilibration at 25°C and results were reported as the average of three measurements⁽¹⁵⁾(Fig 2).

Measurement of liver weight

At the end of the experiment and after blood samples were collected, rats were anaesthetized by ketamine 60 mg/kg intra peritoneally and then sacrificed by decapitation and the liver of each rat was excised and weighted⁽¹⁶⁾.

Biochemical analysis of liver enzymes

All animals were fasted for 12 hours, then blood samples were collected from retro orbital venous plexus for ALT and AST measurement⁽¹²⁾.

Assessment of antioxidant enzymes (SOD)

Left lobe of liver tissue of each animal was dissected and homogenized in phosphate buffer (pH. 7.4) for determination of SOD. Kits were purchased from Bio diagnostic Company, Giza, Egypt^(17,18).

Light Microscopic Examination

Right lobe of liver tissue was fixed in 10% neutral buffered formaldehyde for 24 hours and the specimens were processed and embedded in paraffin^(19,20). Sections (4µm thick) were subjected to the following staining techniques: Hematoxylin and eosin (H&E) stain & Immunohistochemical stain for assessment of Alpha smooth muscle actin (α-SMA)⁽²¹⁾. SMA antibody was obtained from Sigma Biochemical (St. Louis, Missouri, USA). Sections were studied using Leica Microsystems Light Microscope, Germany.

Morphometric analysis

The images were investigated using FIJI image processing software, the mean color area percentage of brown pigments indicated α-SMA reactivity in immune-histochemical stained sections.

Statistical Analysis

Data were analyzed with Statistical software (SPSS Inc., Chicago, IL, USA) (version 17). The normality test of data was non-significant ($p > 0.05$). Statistically significant difference was determined by Uni-Variate analysis of Variance (ANOVA) test and with Post hoc Bonferroni test for quantitative variables.

Results

I-The weight of the liver

Regarding Mean and standard deviation (SD), there was high statistically significant difference in liver weights between different groups. There was no statistically significant difference in liver weight between groups I, II, V&VI. While there was high statistically significant increase in liver weight in group III when compared to control

groups, high significant decrease in group V &VI when compared to group III, but no significant difference between groups III & IV (Table 1).

II-Biochemical analysis of liver enzymes

The results presented in table 2 revealed that there was no difference between I &II groups. There was high statistically significant increase in their levels in group III when compared to control group and in groups IV, V &VI when compared to control. Also, there was high statistically significant decrease in their levels in IV, V &VI groups when compared to group III. High significant decrease in ALT level in VI group when compared to IV &V groups while AST level in VI group was high significantly decreased when compared to IV group, its level also in V group was high significantly decreased when compared to IV group.

Table 1: The difference of liver weights between study groups (N=80)	
Animal Groups	Liver weights (gm)
Group IA	9.6 ± 0.89
Group IB	9.7 ± 0.68
Group IC	9.7 ± 0.53
Group II	9.2 ± 0.53 ^{** (b)}
Group III	10.9 ± 0.19 ^{** (a)}
Group IV	10.1 ± 0.51
Group V	10.0 ± 0.64 ^{* (b)}
Group VI	9.8 ± 0.76 ^{** (b)}

Mean ± SD, Univariate ANOVA, Bonferroni test was used for post-hoc test.

* Statistically significant at $p < 0.05$, **high statistically significant at $p < 0.01$. ** (a): high statistically significant when compared to group IA.

* (b): statistically significant when compared to group III. ** (b): high statistically significant when compared to group III.

III-Assessment of antioxidant enzyme (SOD)

Figure 3 revealed that there was no difference between groups I, II and IV, but there was high statistically significant decrease in the level of SOD in group III when compared to group I. High statistically signi-

ficant decrease in IV &V groups when compared to group I. There was high statistically significant increase in groups IV, V and VI when compared to group III. Also, high significant increase in SOD level in VI group when compared to IV and V groups.

Table 2: The difference of AST and ALT levels between study groups		
Animal Groups	ALT level (IU/L)	AST level (IU/L)
Group IA	48.8 ± 4.02	108.5 ± 10.26
Group IB	50.9 ± 5.17	114.5 ± 8.25
Group IC	51.1 ± 4.23	118.4 ± 8.77
Group II	53.3 ± 4.11 ^(b)	120.9 ± 15.55 ^(b)
Group III	395.7 ± 44.69 ^(a)	384.3 ± 21.01 ^(a)
Group IV	307.0 ± 33.43 ^{(a),(b)}	314.5 ± 9.83 ^{(a),(b)}
Group V	291.0 ± 36.73 ^{(a),(b)}	257.0 ± 16.75 ^{(a),(b),(c)}
Group VI	186.6 ± 9.07 ^{(a),(b),(c),(d)}	240.0 ± 16.24 ^{(a),(b),(c)}

Mean ± SD, Univariate ANOVA, Bonferroni test was used for post-hoc test. High statistically significant at p < 0.01. (a): high statistically significant when compared to group I. (b): high statistically significant when compared to group III. (c): high statistically significant when compared to group IV. (d): high statistically significant when compared to group V.

Table 3: Mean number and ± SD of the area percentage of positive α-SMA in the different groups (N=80).	
Animal groups	Area percentage of α- SMA
Group I	2.99 ± 0.21
Group II	3.77 ± 0.97 ^{** (b)}
Group III	36.9 ± 7.07 ^{** (a)}
Group IV	16.14 ± 1.93 ^{** (a), ** (b)}
Group V	10.42 ± 1.08 ^{* (a), ** (b)}
Group VI	4.85 ± 1.69 ^{** (b), ** (c)}

Mean ± SD, Univariate ANOVA, Bonferroni for post-hoc test. * Statistically significant at p < 0.05, **high statistically significant at p < 0.01. * (a): statistically significant when compared to Group I. ** (a): high statistically significant when compared to Group I. ** (b): high statistically significant when compared to Group III. ** (c): high statistically significant when compared to Group IV.

IV-Light Microscopic results

A-Hematoxylin and eosin stain

Stained liver sections with H&E of control and Nano-encapsulation of ginger extract groups showed normal liver architecture, there were regular arranged hepatic cords radiating from central vein forming hepatic lobules. Hepatic plates were separated by blood sinusoids which were lined by sinusoidal endothelial cells and amoeboid shaped cells with ovoid nucleus called von-Kupffer cells. Portal triads were also shown at the periphery of hepatic lobules and contained branch of hepatic artery,

portal vein and inter lobular bile duct. Hepatic cords were formed of hepatocytes which were polygonal cells, with single prominent central vesicular nucleus and prominent nucleolus but the remainder were binucleated cells, its cytoplasm had basophilic granules (Figures 4a, 4b). Liver sections of CCl₄ treated rats revealed loss of normal architecture of hepatic lobules with lobular inflammation. Hepatocytes showed cytoplasmic vacuolation with focal necrosis and dilated congested portal vein, Sinusoidal congestion, and dilatation with Kupffer cells hypertrophy, dilated bile canaliculi with bile stasis (Figures 5a, 5b).

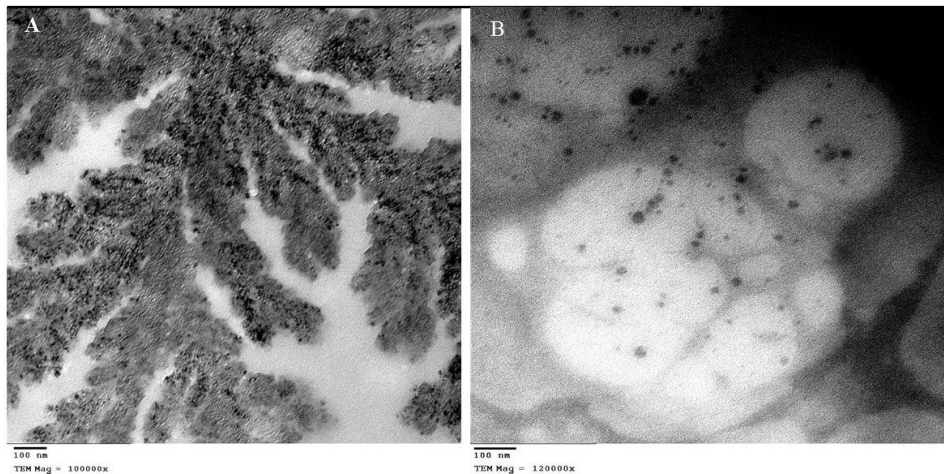


Figure 1: An electron micrograph of
A; ginger extract form (TEM; x 100000). **B;** Nano-encapsulation form of
 ginger extract (TEM; x 120000).

Ccl_4 + silymarin treated rats revealed mild restoration of normal liver architecture. Cytoplasmic vacuolation decreased compared to Ccl_4 group with areas of focal necrosis, central vein and portal vein became less dilated but still congested. Inflammatory infiltrate was observed (Figure 6 (a & b)). While in liver sections of Ccl_4 + nano-encapsulation of ginger extract group were revealed no dilatation or congestion in central veins, few hepatocytes showed

ballooning degeneration, no dilation in blood sinusoids or hypertrophy of Kupffer cell. Portal vein became less dilated with no congestion or bile stasis (Figure 7 (a & b)). Liver architecture in this group was improved compared to Ccl_4 and Ccl_4 + silymarin groups. H&E-stained liver sections of Ccl_4 + silymarin + nano-encapsulation of ginger extract treated rats revealed restoration of normal liver architecture (Figure 8 (a & b)).

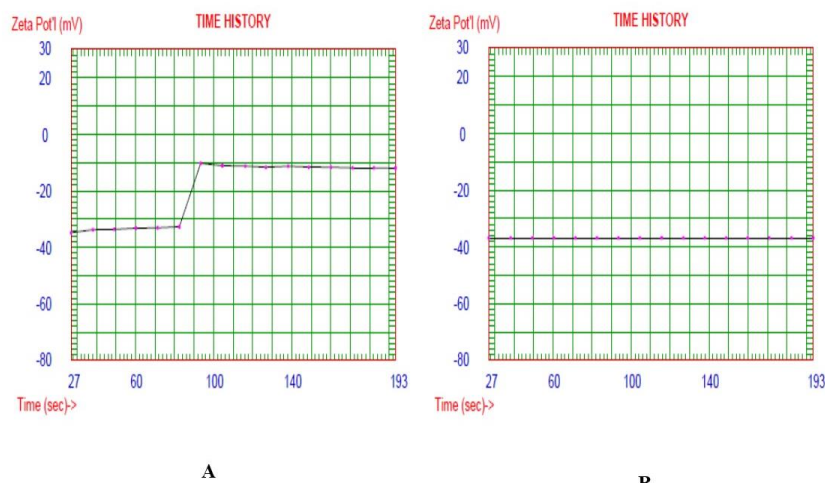


Figure 2: A; Zeta potential of ginger extract. **B;** Zeta potential of
 nano-encapsulation of ginger extract.

B- α -SMA actin Immunohistochemical stain

Immuno-stained liver sections of control and nano-encapsulation of ginger extract groups revealed very mild expression of α -SMA in the stroma of portal veins and hepatic arteries, with no reaction in hepatic lobules within hepatocytes (Fig. 4 (c+d)). Sections of Ccl_4 treated rats revealed intense expression of α -SMA. Dense brown granules were seen in the walls of central veins and blood sinusoids and in the stroma of portal triad (Fig. 5 (c+d)). Immunostained liver sections of Ccl_4 + silymarin treated rats revealed moderate deposition in the walls of central veins and

around blood sinusoids. Also, mild reactivity following bands of fibrous tissue was detected (Fig. 6 (c+d)). Liver sections of Ccl_4 + nano-encapsulation of ginger extract group revealed mild immune reactivity of α -SMA in the walls of central veins, also, no reactivity following fibrous bands between central, or portal veins (Fig. 7 (c+d)) was found. Sections of Ccl_4 + silymarin+ nano-encapsulation of ginger extract treated rats revealed very mild immune expression of α -SMA like that of the control group in the stroma of portal veins and hepatic arteries, with no reactivity following fibrous bands between central or portal veins (Fig. 8 (c+d)).

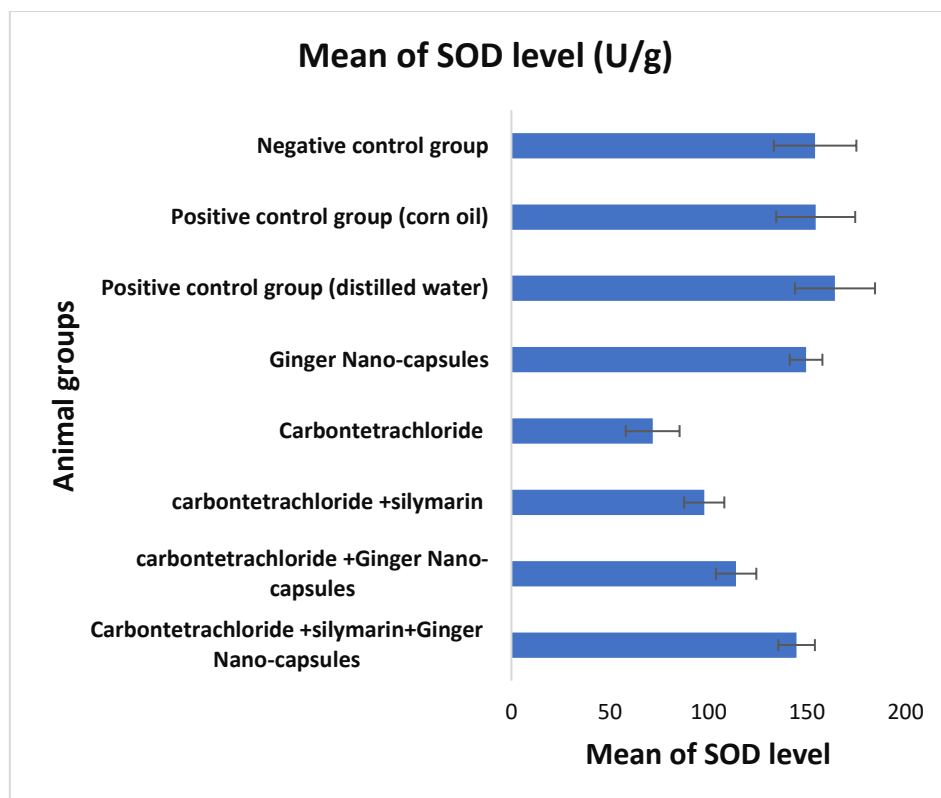


Figure 3: Means of SOD level in different groups. Mean \pm SD, Univariate ANOVA followed by Bonferroni for post-hoc test

Morphometric analysis

Area percentage of immune histochemical staining of α -SMA of the group I, II & V1 revealed very mild reaction, but there was

strong positive reaction in groups III and IV when compared to control group. There was high statistically significant decrease in area percentage of α -SMA in groups IV,

V&IV when compared to group III. There was high statistically significant decrease in group V when compared to group III &

IV. High significant decrease was observed in VI group when compared to IV group (Table 3).

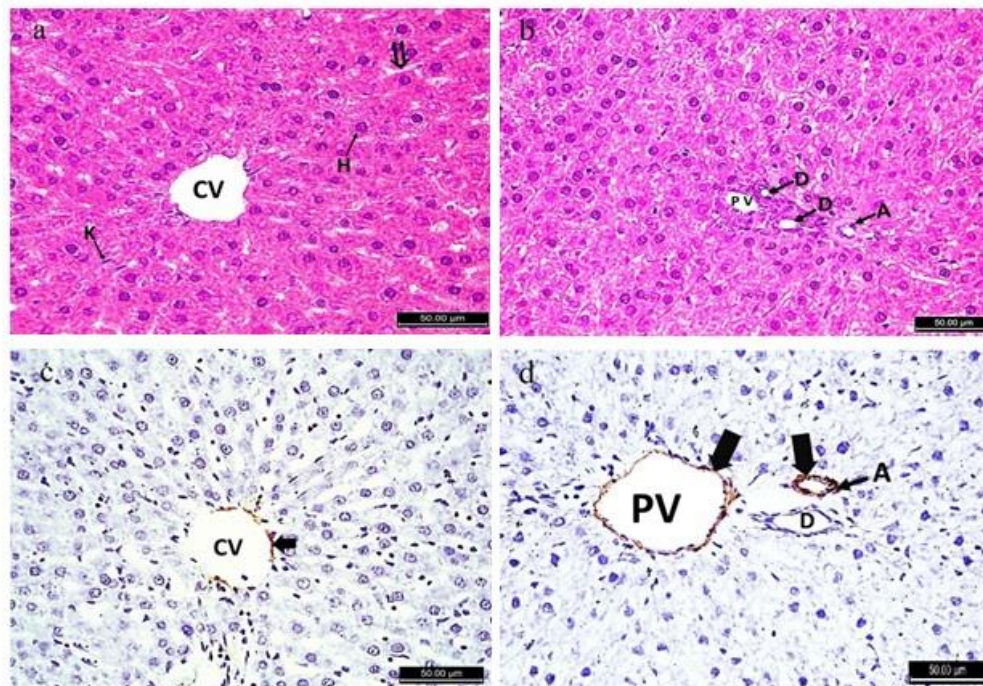


Figure 4: (a); A photomicrograph of the liver of control and nano-encapsulation of ginger extract groups showing normal hepatocytes (H), central vein (CV), Kupffer cell (K) and blood sinusoids (double arrow). (b): portal triad: portal vein (PV), hepatic artery (A) and bile ductules (D) (H&E; $\times 400$). (c); Immuno-stained sections of α -SMA showing very mild immune reactivity around central vein (CV) (black arrow). (d); Very mild immune-reactivity of α -SMA around portal vein (PV), hepatic artery (A) (black arrow) and Bile duct (D). (α -SMA; $\times 400$).

Discussion

Many drugs were manufactured to relieve liver fibrosis, but these anti-fibrotic drugs produced harmful side effects on humans. New strategies of treatment aimed to use antioxidants due to their great effect on oxidative stress in the liver especially herbal types⁽²²⁾. Silymarin is a natural flavonoid which has anti-fibrotic, antioxidant, anti-inflammatory, immune stimulating, regenerative and hepato-protective effect. It shares in regeneration of liver cells, and it was clinically studied in patients with cirrhosis, NAFLD, drug induced liver injury and gave great results⁽²³⁾. Ginger has many

bio-active phenolics and it is considered as antioxidant, anti-inflammatory, anti-carcinogenic, anti-diabetic, anti-lipidemic, anti-emetic and analgesic substance⁽²⁴⁾. But unfortunately, these products are still not efficiently taken up by activated HSCs despite their great effect on reducing oxidative stress. So, researchers began to increase their efficacy by using nano technology to resolve this problem and increase the potential effect of any drug or substance through using therapeutic NPs to be targeted to HSCs receptors and others included in mechanisms of liver fibrosis as silver, zinc oxide and gold NPs but toxicological effects of these NPs were detected

on humans⁽²⁵⁾. We evaluated the effect of both silymarin, and ginger extract encapsulated in sodium alginate NPs individually or combined on hepatotoxicity induced by

Ccl_4 in adult male albino rats. Ccl_4 is metabolized by cytochrome P450 to tri chloromethyl and trichloro methyl peroxy that led to hepatocytes damage⁽²⁶⁾.

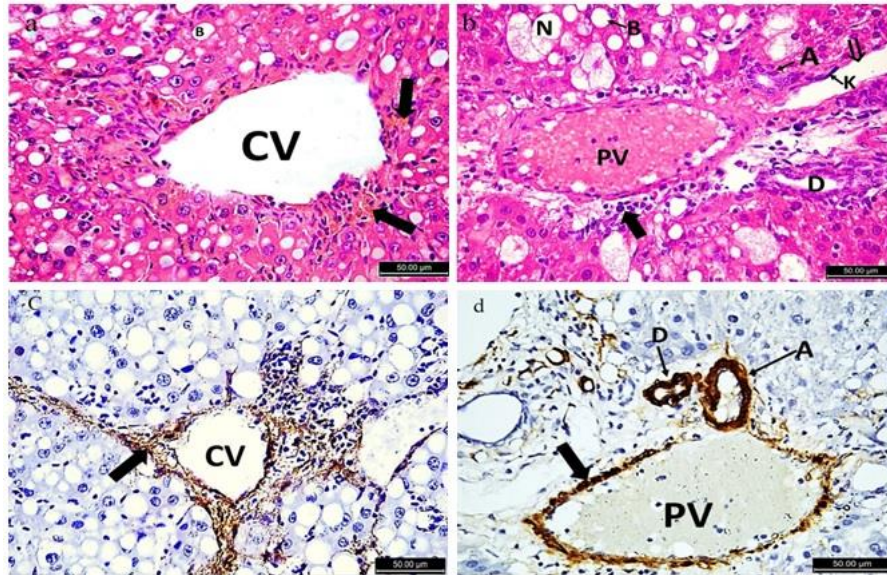


Figure 5 :(a); A photomicrograph of the liver of Ccl_4 group showing dilated central vein (CV), ballooning degeneration of hepatocytes (B) and sinusoidal congestion (black arrow). (b); dilated congested portal vein (PV) with pyknotic nuclei (black arrow), ballooning degeneration of hepatocytes (B), necrotic spots (N), dilated blood sinusoids (double arrow), Kupffer cell hypertrophy (K), hepatic artery (A) and bile duct (D) (H&E; $\times 400$). (c); Immuno-stained sections of α -SMA showing intense brownish positive immune expression in the wall of central vein (CV) (black arrow). (d); Intense brownish positive immune expression of α -SMA in the wall of dilated portal vein (PV), hepatic artery (A) and bile duct (D) (α -SMA; $\times 400$).

In the present study, we used Ccl_4 in inducing liver damage as significant fibrosis occurred after two-four weeks from exposure to it⁽²⁷⁾. Our results agreed with Abdelgayed *et al.*⁽²⁸⁾ who reported that ginger nanoparticles gave better therapeutic results through reducing the parameters of liver toxicity and providing a safe method for drug delivery in addition to excellent biocompatibility relative to ginger extract. Motawi *et al.*⁽²⁹⁾ noticed that ethanol extract of ginger had more potent effect than silymarin on liver weight and Bencheikh *et al.*⁽³⁰⁾ mentioned that Ccl_4 toxicity led to alteration in collagen

synthesis and deposition of collagen I and III in liver leading to disturbance of normal architecture and increase liver weight while silymarin inhibited that. This confirmed our results as we noticed that liver weight was decreased significantly in Ccl_4 + nano encapsulation of ginger extract and mixed groups. In the present study, ALT and AST levels were significantly increased in Ccl_4 group, we observed that mixture of silymarin and nano-encapsulation of ginger extract improved ALT level more than each of them alone while AST level improved in mixed group and Ccl_4 + nano-encapsulation of ginger extract group more than Ccl_4

+silymarin group. Our Results similar to Ramezannezhad *et al.*⁽³¹⁾ which found that silymarin has a potential effect on amelioration of biochemical enzymes in liver toxicity. Another study explained the antioxidant and anti-apoptotic activity of silymarin against lead toxicity and its improving effect on liver biomarkers⁽³²⁾. Cheong *et al.*⁽³³⁾ reported that zingerone (one of active components of ginger) had a

hepatoprotective effect due to its anti-fibrotic, anti-oxidant and anti-inflammatory effect as it can attenuate inflammatory mediators as TNF- α and IL-1 β , prevention of leakage of enzymes and cellular membrane damage. Another study proved that six-gingerol (an active compound of ginger) attenuated the effect of diethyl nitrosamine induced liver damage and had ameliorating effect on ALT and AST levels⁽³⁴⁾.

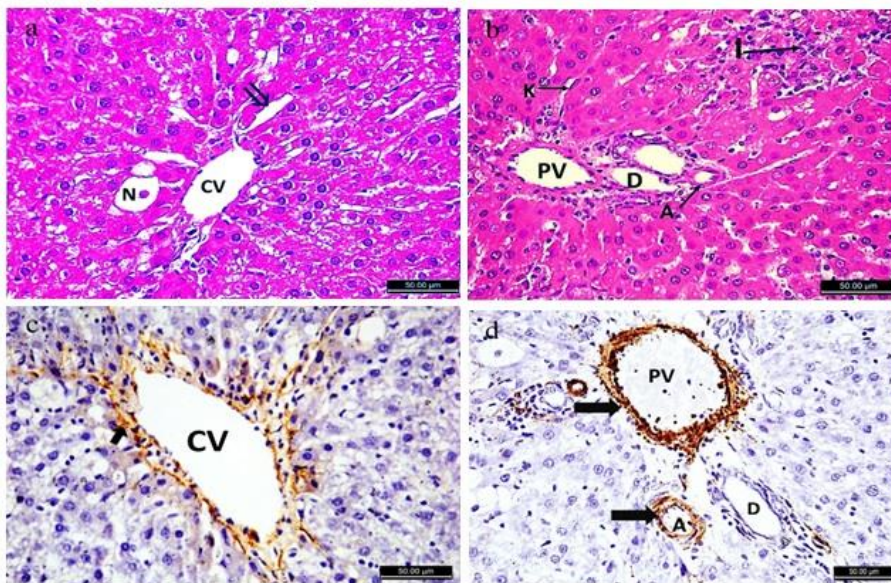


Figure 6: (a); A photomicrograph of the liver of Ccl_4 + silymarin group showing hepatic cords arranged around central vein (CV), area of focal necrosis (N) and dilated blood sinusoids (double arrow). (b); Inflammatory infiltrate (I), portal vein (PV), hepatic artery (A), bile duct (D) and Kupffer cell (K) (H&E; $\times 400$). (c); Immuno-stained sections of α -SMA showing moderate positive immune expression of α -SMA in the wall of dilated central vein (CV). (d); Moderate positive immune expression of α -SMA in the stroma of portal vein (PV), hepatic artery (A) and Bile duct (D) (α -SMA; $\times 400$).

Another research studied that administration of ginger to diethyl nitrosamine treated rats depressed upregulation of expression of this factor and improved liver function tests⁽³⁵⁾. Contrary to this results, Al-Naqeeb *et al.*⁽³⁶⁾ reported that 500 mg of aqueous extract of ginger led to disturbance in ALT and AST levels making mild toxicity. SOD is one of antioxidant enzymes in mammalian bodies as it is a metalloenzyme that detoxifies superoxide anions by catalyzing them into H_2O_2 and O_2 ⁽³⁷⁾. In the

present study, there was significant decrease in the level of SOD in Ccl_4 group compared to control and High significant increase in Ccl_4 + silymarin, Ccl_4 + nano-encapsulation of ginger extract and mixed groups. We also noticed that in mixed group, its level was significantly increased compared to each treatment alone. Abdel-Moneim *et al.*⁽³⁸⁾ also reported the same results. Reduction in level of antioxidant enzymes as SOD leads to high levels of ROS which destroy lipids, proteins and DNA

inducing apoptosis and tissue injury. ROS affect mitochondria and change in energy metabolism, while pretreatment with ginger improved oxidative status in liver through increasing the level of these enzymes⁽³⁸⁾. Also, the same results reported by other studies^(35,40). Our results by H&E stain found loss of normal architecture of liver tissue in CCl₄ group, but liver architecture was restored to a great extent in mixed group. Similar results reported by⁽⁴¹⁾ who explained effect of CCl₄ on Bax and Bcl-2 family in inducing apoptosis, on the

other hand, bile stasis and leakage were due to obstruction of bile canaliculi by fibrosis and accumulation of bile inside so that over distended canaliculi ruptured, and bile was leaked so that hepatocellular functions were inhibited by free radicals especially bile salt efflux pump with subsequent bile retention and impaired membrane permeability. Another study proved the protective effect of silymarin on hepatotoxicity due to their antioxidant activity and their improving effect on liver tissue⁽⁴²⁾.

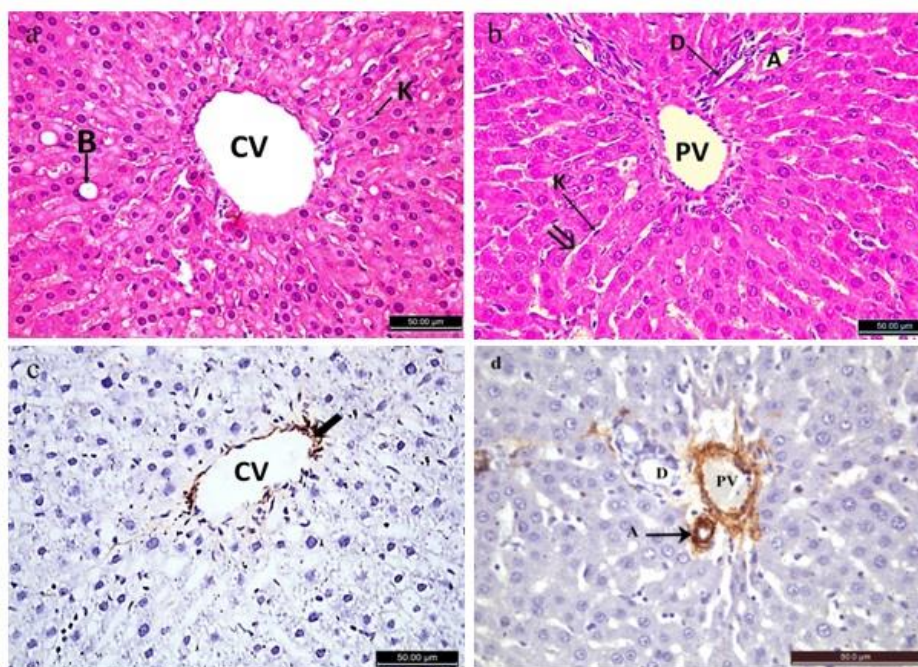


Figure 7: (a); A photomicrograph of the liver of CCl₄ + nano-encapsulation of ginger extract group showing regular arranged hepatic cords around central vein (CV) and few ballooning degeneration of hepatocytes (B) and normal Kupffer cells (K). (b); normal portal vein (PV), hepatic artery (A), bile duct (D) and blood sinusoids (double arrow) (H&E; ×400). (c); Immunostained sections of α-SMA showing mild positive immune expression around central vein (CV). (d); mild positive immune expression around portal vein (PV), hepatic artery (A) and bile duct (D) (α-SMA; ×400).

Also, Motawi *et al.*⁽²⁹⁾ who reported the ability of ginger especially ethanol extract to reduce collagen deposition and restored normal appearance of hepatocytes more than silymarin. Bakr *et al.*⁽⁴³⁾ evaluated the effect of ginger extract and ginger NPs on

hepatotoxicity and nephrotoxicity and found that NPs gave more potent effect on liver and kidney tissue than ginger only as nanoparticles have more hepatoprotective, reno protective and antioxidant effect than ginger extract because NPs are highly

resistant to digestion. So, great amounts of them could reach to liver after oral administration providing safe method of delivery and improving drug bioavailability within the hepatocytes. Also, presence of shogaols in ginger have more affinity to bind with NPs form than free form in ginger extract. So that, less amount of shogaol carried by ginger NPs can achieve more effect on hepatocytes. He also Explained that Shogaols in ginger regulate the genetic expression of antioxidant enzymes and stimulate of nuclear factor-erythroid 2-related factor 2 which is anti-inflammatory mediator. In our study, α -SMA expression was assessed by immunohistochemical staining and morphometric

analysis. We found minimal reactivity in the control, nano-encapsulation of ginger extract and mixed groups but in Ccl_4 group, there was intense reactivity. In Ccl_4 and silymarin group, reaction of α -SMA was moderate and in Ccl_4 and nano encapsulation of ginger extract group was mild reaction. Our results were agreed with Algandaby *et al.*⁽⁴⁴⁾ who reported that the effect of gingerol on hepatic fibrosis and observed marked expression of α SMA in toxic group and limited expression of it with gingerol. Also Eraky *et al.*⁽⁴⁵⁾who explained the protective effect of silymarin against thioacetamide toxicity and evaluated α SMA expression which was improved with silymarin.

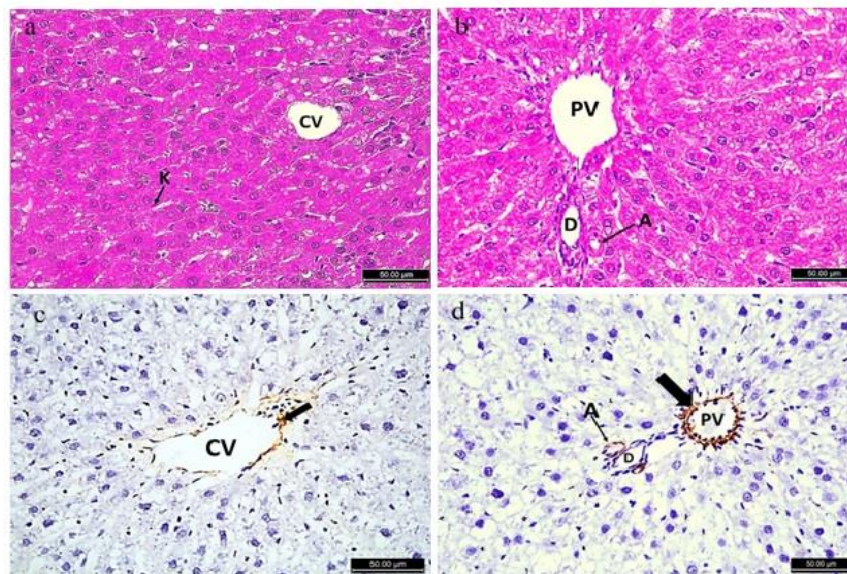


Figure 8: (a); A photomicrograph of a section of the liver of Ccl_4 +silymarin + nano-encapsulation of ginger extract group showing normal regular arranged hepatocytes around central vein (CV) and Kupffer cells (K). (b); normal portal vein (PV), hepatic artery (A) and bile duct (D) (H&E; $\times 400$). (c): Immunostained sections of α -SMA showing very mild positive immune expression around central vein (CV).(d);Very mild positive immune expression around portal vein (PV), hepatic artery (A) and bile duct (D)(α -SMA; $\times 400$).

Conclusion

In conclusion, the present study found that Ccl_4 induced hepatotoxicity can be protected by administration of silymarin

or/and nano-encapsulation of ginger extract. Nano-encapsulation of ginger extract showed more improvement than silymarin. Mixed group showed marked improvement more than each of them

separately in histopathological and immunohistochemical results, antioxidant enzymes and in some biochemical parameters and that Nano-encapsulation of ginger extract can promote normal liver functions with no adverse effects. From the above, it seems that nano-encapsulation of various drugs allow better distribution of the active gradient of the drug, and it will give a revolution step in administration of treating agent in the future.

Acknowledgment

Great thanks and gratitude to Prof. Khaled Fahmy, Technology department, National Research Centre, Giza, who helped in synthesis and evaluation of ginger extract and its nano-encapsulated form.

References

1. Wijayagunawardanea M, Wijerathnea C and Herathb C. Indigenous herbal recipes for treatment of liver cirrhosis. *Procedia Chem.* 2015; 14 (1): 270-276.
2. Sepanlou S, Safiri S, Bisignano C, et al. The global, regional, and national burden of cirrhosis by cause in 195 countries and territories, 1990–2017: A systematic analysis for the global burden of disease study 2017. *Lancet Gastroenterol Hepatol.*2020; 5(3): 245-266.
3. Mokdad A, Lopez A, Shahrzaz S, et al. Liver cirrhosis mortality in 187 countries between 1980 and 2010: A systematic analysis. *BMC Med.* 2014; 12(1): 1-24.
4. Wong M and Huang J. The growing burden of liver cirrhosis: Implications for preventive measures. *Hepatology.* 2018;12(3): 201-203.
5. Singh D, Cho W and Upadhyay G. Drug-induced liver toxicity and prevention by herbal antioxidants: An overview. *Front Physiol.*2016; 6 (1): 363-380.
6. Rahmani A, Shabrmi F and Aly S. Active ingredients of ginger as potential candidates in the prevention and treatment of diseases via modulation of biological activities. *International Journal of Physiology, Pathophysiol Pharmacol.*2014; 6(2): 125-136.
7. Giannitrapani L, Soresi M, Bondi M, et al. Nanotechnology applications for the therapy of liver fibrosis. *WJG.*2014; 20 (23): 7242-7251.
8. Yadav H, Almokdad A, Sumia I, et al . Polymer-based nanomaterials for drug delivery carriers. *Nanocarriers for drug delivery.* 2019; 531-556.
9. Wang J, Pan W, Wang Y, et al. Enhanced efficacy of curcumin with phosphatidylserine-decorated nanoparticles in the treatment of hepatic fibrosis. *Drug Delivery.*2018; 25(1): 1-11.
10. Abdu S, Abdu F and Khalil W. Ginger nanoparticles modulate the apoptotic activity in male rats exposed to dioxin-induced cancer initiation. *Int J Pharmacol.*2017; 13(8): 946-957.
11. Sakr S, El-Abd S, Osman M, et al . Effect of rosemary on carbon tetrachloride-induced hepatotoxicity in albino rats: Histological and biochemical studies. *Egy J Experiment Biol.* 2010; 6(1): 135-140.
12. Tsai J, Liu J, Wu T, et al. Effects of silymarin on the resolution of liver fibrosis induced by carbon tetrachloride in rats. *J Viral Hepatitis.* 2008; 15(7): 508-514.
13. Fatma A, Mahmoud H, Hanan H, et al. The beneficial effects of silymarin in treatment of experimentally induced non-alcoholic fatty liver disease in rats. *Med J Cairo Univ.*2018; 86 (3): 1055-1064.
14. Zhuang X, Deng Z, Mu J, et al. Ginger-derived nanoparticles protect against alcohol-induced liver damage. *J Extracellular Vesicles.* 2015; 4(1):1-19.
15. Clogston J. and Patri A. Zeta potential measurement. *Methods Mol Biol.* 2011; 697(1): 63-70.
16. Atli O, Ilgin S, Altuntas H, et al. Evaluation of azithromycin-induced cardiotoxicity in rats. *Int J Clin Exp Med.* 2015; 8:3681–3690.

17. Hassan S, Mousa A, Eshak M, et al. Therapeutic and chemopreventive effects of nano curcumin against diethylnitrosamine induced hepatocellular carcinoma in rats. *Int J pharmacy pharmaceutical sci.* 2014; 6 (3): 54-62.
18. El-Denshary E, Aljawish A, El-Nekeety A, et al. Possible synergistic effect and antioxidant properties of chitosan nanoparticles and quercetin against carbon tetrachloride-induced hepatotoxicity in rats. *Soft Nanosci Letters.* 2015; 5(3): 36-50.
19. Bancroft J. and Gamble M, eds. *Theory and practice of histological techniques.* Elsevier health sciences, 6th Ed. 2008.
20. Hussein H, Salem N and Al-Badawi M. Role of anise on the hepatotoxicity induced by carbon tetrachloride in adult male albino rats. *Eur J Anatomy.* 2013; 17(4): 220-229.
21. Khimji A, Shao R and Rockey D. Divergent transforming growth factor- β signaling in hepatic stellate cells after liver injury: Functional effects on ece-1 regulation. *Am J Pathol.* 2008; 173(3): 716-727.
22. Casas-Grajales S. and Muriel P. Antioxidants in liver health. *W J Gastrointest Pharmacol Therapeutics.* 2015; 6(3): 59-72.
23. Gillessen A and Schmidt H. Silymarin as supportive treatment in liver diseases: A narrative review. *Adv Ther.* 2020; 37(4): 1279-1301.
24. Beagloo I, Valilu M, Motiei M, et al. The antioxidant and hepatoprotective effect of alcoholic extract of ginger against the cisplatin-induced oxidative stress in rats. *Biomed J Sci Tech Res.* 2019; 19(2): 14240-14245.
25. Surendran S, Thomas R, Moon M, et al. Nanoparticles for the treatment of liver fibrosis. *Int J Nanomed.* 2017; 12(9): 6997-7006.
26. Liu Y, Meyer C, Xu C, et al. Animal models of chronic liver diseases. *Am J Physiol Gastrointest Liver Physiol.* 2013; 304(5): G449-G468.
27. Takahashi Y. and Fukusato T. *Animal models of liver diseases. Animal models for the study of human disease.* 2nd Ed, Elsevier. 2017; 313-339.
28. Abdelgayed S, Bakr A, EL-Tawil O, et al. Cytological study on rat isolated hepatocytes and possible protection of ginger (extract and nanoparticles) against acetaminophen toxicity. *Journal of Microbiology, Biotechnol Food Sci.* 2021; 10(5): 2681-2681.
29. Motawi T, Hamed M, Shabana M, et al. Zingiber officinale acts as a nutraceutical agent against liver fibrosis. *Nutr Metab.* 2011; 8(1): 1-11.
30. Bencheikh N, Bouhrim M, Kharchoufa L, et al. Protective effect of zizyphus lotus l.(desf.) fruit against ccl4-induced acute liver injury in rat. *Evid Based Complement Alternat Med.* 2019;(1): 1-10.
31. Ramezannezhad P, Nouri A and Heidarian E. Silymarin mitigates diclofenac-induced liver toxicity through inhibition of inflammation and oxidative stress in male rats. *J Herbmed Pharmacol.* 2019; 8(3): 231-237.
32. Abd Eldaim M, Barakat E, Alkafafy M, et al. Antioxidant and anti-apoptotic prophylactic effect of silymarin against lead-induced hepatorenal toxicity in rats. *Environ Sci Pollut Res Int.* 2021; 28(41): 1-10.
33. Cheong K, Shin D, Bak J, et al. Hepatoprotective effects of zingerone on carbon tetrachloride-and dimethylnitrosamine-induced liver injuries in rats. *Arch Pharm Res.* 2016; 39(2): 279-291.
34. Alsahli M, Almatroodi S, Almatroudi A, et al. 6-gingerol, a major ingredient of ginger attenuates diethylnitrosamine-induced liver injury in rats through the modulation of oxidative stress and anti-inflammatory activity. *Mediators Inflamm.* 2021;(3): 1-17.

35. Hamza A, Heeba G, Hamza S, et al. Standardized extract of ginger ameliorates liver cancer by reducing proliferation and inducing apoptosis through inhibition oxidative stress/ inflammation pathway. *Biomed Pharmacother.* 2021; 134(2): 1-9.
36. Al-Naqeeb M, Thomson M, Al-Qattan K, et al. Biochemical and histopathological toxicity of an aqueous extract of ginger in female rats. *Kuwait J Sci Engineering.* 2003; 30(2): 35-48.
37. Che M, Wang R, Li X, et al. Expanding roles of superoxide dismutases in cell regulation and cancer. *Drug Discov Today.* 2016; 21(1): 143-149.
38. Abdel-Moneim A, Al-Kahtani M, El-Kersh M, et al. Free radical-scavenging, anti-inflammatory/anti-fibrotic and hepatoprotective actions of taurine and silymarin against ccl4 induced rat liver damage. *PLoS One.* 2015; 10(12): e0144509.
39. Akbari A, Nasiri K, Heydari M, et al. Ameliorating potential of ginger (*Zingiber officinale roscoe*) extract on liver function and oxidative stress induced by ethanol in male rats. *Zahedan J Res Med Sci.* 2019; 21(2): 1-8.
40. Beagloo I, Valilu M, Motiei M, et al. The antioxidant and hepatoprotective effect of alcoholic extract of ginger against the cisplatin induced oxidative stress in rats. *Biomed J SciTech Res.* 2019; 19(2): 14240-14245.
41. Wei L, Chen Q, Guo A, et al. Asiatic acid attenuates ccl4-induced liver fibrosis in rats by regulating the pi3k/akt/mtor and bcl-2/bax signaling pathways. *Int Immunopharmacol.* 2018; 60(7): 1-8.
42. Ahmed M, Rezk N, Fawzy A, et al. Protective effects of curcumin and silymarin against paracetamol induced hepatotoxicity in adult male albino rats. *Gene.* 2019; 5; 712:143966.
43. Bakr A, Abdelgayed S, El-Tawil O, et al. Assessment of ginger extract and ginger nanoparticles protective activity against acetaminophen -induced hepatotoxicity and nephro-toxicity in rats. *Pakistan Vet J.* 2019; 39(4): 479-486.
44. Algandaby M, El-Halawany A, Abdallah H, et al. Gingerol protects against experimental liver fibrosis in rats via suppression of pro-inflammatory and profibrogenic mediators. *Naunyn Schmiedebergs Arch Pharmacol.* 2016; 389(4): 419-428.
45. Eraky S, El-Mesery M, El-Karef A, et al. Silymarin and caffeine combination ameliorates experimentally-induced hepatic fibrosis through down-regulation of Ipar1 expression. *Biomed Pharmacother.* 2018; 101(3): 49-57.