

# Sinus Pericranii associated with Hypoplastic Straight Sinus and Persistent Falcine Sinus

Ali M. Hendi, MD, MHPE

Department of Radiology, College of Medicine, Jazan University, Saudi Arabia

## Case Report

### Abstract

Sinus pericranii (SP) is a rare vascular abnormality of unknown origin that is defined as an aberrant anastomosis joining the intracranial and extracranial venous systems, usually near the midline. Sinus pericranii (SP) can be formed either by focal venous hypertension and abnormal development of diploic veins (congenital type) or by trauma (acquired type).

**Keywords:** Sinus Pericranii, falcine sinus, vascular abnormality

### Case

A 16-month-old boy, full-term and normally delivered, was brought to the hospital for neurosurgery OPD follow-up, with midline scalp occipital painless swelling since birth. This swelling was increased by crying. However, there was no history of vacuum extraction, no history of discharge or bleeding from it, as well as no history of trauma. On physical examination, the swelling is soft, 2x2 cm in size, not compressible or reducible, and covered by normal skin. MRI showed an extracranial midline mass with a small bony defect, connected to the dural sinus, and associated with the hypoplastic straight sinus and persistent falcine sinus (Figures 1-4).

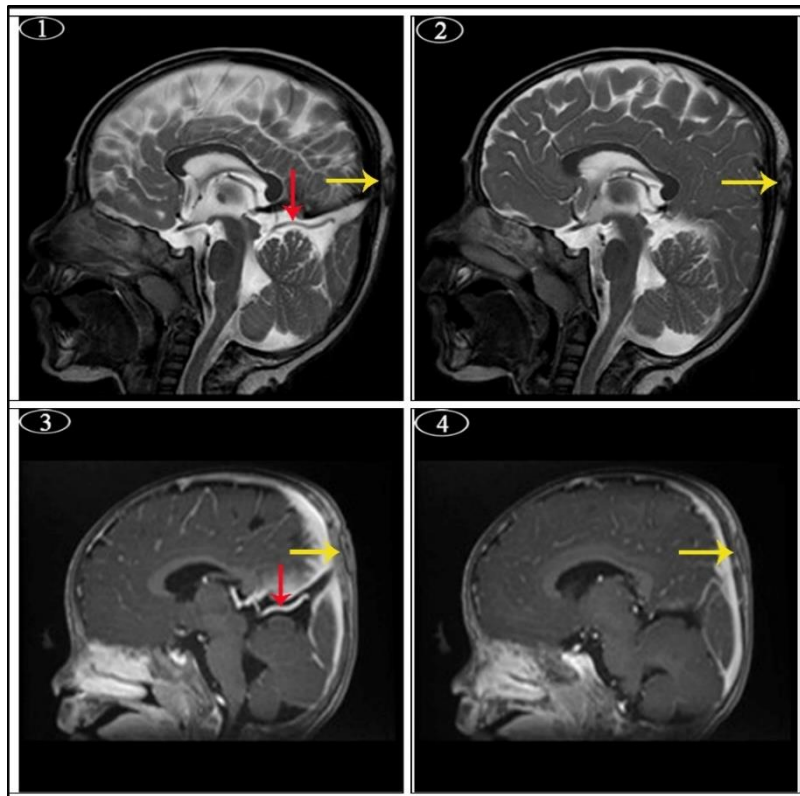
### Discussion

SP is a rare vascular malformation of unknown etiology, defined as an aberrant

anastomosis between the intracranial and extracranial venous systems, nearly in the midline. Congenital, syndrome-related, and acquired instances are all possibilities. The nature of SP is benign. Its venous abnormality consists of an emissary intradiploic vein originating from an intracranial sinus, as well as enhanced subgaleal drainage consisting of a network of thin-walled veins forming a varix on the external table of the skull<sup>(1)</sup>. Furthermore, anastomotic connections can be made up of a single transosseous vessel or several venous systems, which can often reach several centimeters beneath the skull bones, causing severe bony erosion<sup>(1-3)</sup>. As a result of contact between intracranial dural sinuses and dilated epicranial venous structures, blood flows into the sinus pericranii and drains into the intracranial venous sinuses<sup>(4)</sup>. The size of it varies depending on the patient's body posture or, in this example, the Valsalva technique<sup>(5)</sup>. It is unclear why this

is happening. However, as this case report shows, it appears to be primarily congenital in nature and is commonly associated with other venous anomalies and syndromes<sup>(6)</sup>. Sinus pericranii can be isolated (primary) or accompanied by other malformations (secondary), such as craniosynostosis or intracranial venous anomalies such as dural sinus hypoplasia, particu-

larly straight sinus and persistent falcine sinus, as in this case<sup>(7,8)</sup>. The patient's parents' main concern is usually cosmetic, but the most common symptoms are headaches, pressure, or localized pain<sup>(9)</sup>. Furthermore, they may experience severe clinical symptoms such as bradycardia, bradypnea<sup>(10)</sup>, hearing loss, ataxia, or seizures in rare cases<sup>(5, 11)</sup>.



**Figure 1:** Photos 1 & 2 (T2-MRI), photos 3 & 4 (T1-MRI). All photos are in sagittal plan with post-contrast administration. They show extracranial midline mass with small bony defects (yellow arrows), connected to the dural sinus, and associated with hypoplastic straight sinus and persistent falcine sinus (red arrows).

The lesion tends to grow in size over time, but it has also shown spontaneous remission in rare cases<sup>(12)</sup>. An abrupt change in the lesion's appearance from soft and painless to firm and painful should cause alarm for both the patient and the clinician. In most situations, the management is surgical intervention. On the other hand, endovascular treatment and sclerotherapy are used sometimes<sup>(5,13)</sup>. CT or MRI can show a

vascular lesion with a bone defect and its relationship to an intracranial vessel because of its association with significant diploic erosion. Doppler US is useful for the characterization of the nature of the mass lesion and differentiating different vascular anomalies<sup>(13)</sup>. Moreover, digital subtraction angiography (DSA) is the gold standard approach for diagnosis, it is, however, invasive, exposing children to greater radi-

ation, but in some cases, DSA is used as a method for treatment<sup>(14)</sup>. DSA is still important before surgical intervention as it can evaluate the intracranial venous dynamics and the effect of the SP on the venous drainage of the brain. However, nowadays, MR venography can replace conventional angiography for the diagnosis of SP. Based on DSA findings, SP is classified into two forms "dominant" if the primary blood flow is through the SP and bypasses the usual venous outlets, and "accessory" if only a small part of the venous outflow occurs through the extradiploic vessels. This distinction is critical in guiding therapy choices<sup>(15)</sup>. Sinus pericranii treatment includes conservative measures, endovascular embolization, and surgical removal<sup>(5)</sup>. However, surgical excision was the treatment of choice. Surgical removal<sup>(6,15-18)</sup> and direct venous or endovascular occlusion of the SP and its communicating veins<sup>(19,20)</sup> have been performed for cosmetic reasons or when increased intracranial pressure due to intracranial venous hypertension is a concern<sup>(10)</sup>. Other indications for SP treatment are to avoid some serious complications such as venous infarction, intracranial hemorrhage, bleeding, and air emboli, and to ameliorate cosmetic problems<sup>(21)</sup> and spontaneous thrombosis in an SP, which may occur<sup>(22)</sup>. However, spontaneous regression of sinus pericranii has been reported<sup>(23)</sup>. Active surgical management of sinus pericranii was justified by the prevention of infection, traumatic air embolism, or massive bleeding<sup>(9,24-26)</sup> or to decrease discomfort<sup>(15,25,27)</sup>. Different surgical procedures have been reported because significant hemorrhage may be encountered during the operation<sup>(25,26,28)</sup>. Such a procedure can control the bleeding from the communication easily with bone wax, gel foam packing, coagulation, and even by air-powered diamond drilling if it is not large enough<sup>(28)</sup>. This anomaly has a good prognosis. When the scalp flap is just lifted,

however, the risk of SP recurrence by recanalization of the interosseous veins is substantially higher than when the skull bone housing the connecting venous channels are detached<sup>(29)</sup>.

## Conclusion

Sinus pericranii (SP) is a rare vascular anomaly and should be considered a differential diagnosis in patients with a soft, mid-line subcutaneous scalp mass. It is the cutaneous sign of an underlying venous anomaly. For reaching such a diagnosis, clinical history is very significant, but imaging modalities such as CT and MRI are also used for diagnosis. Furthermore, digital subtraction angiography (DSA) is the gold standard for diagnosis, but it is invasive with more radiation exposure for children. It is used as an endovascular treatment. To confirm the diagnosis, pathological examination is still used. Although cosmetic considerations are the primary concern of the patient, the definitive therapy is surgical removal to avoid significant consequences. Finally, SP has distinct clinical and radiological features that can aid in differential diagnosis and treatment options.

## References

1. Ohta T, Waga S, Handa H, et al. Sinus pericranii. *J. Neurosurg.* 1975 Jun 1;42(6):704-12.
2. Park SC, Kim SK, Cho BK, et al. Sinus pericranii in children: report of 16 patients and preoperative evaluation of surgical risk. *J. Neurosurg.: Pediatrics.* 2009 Dec 1;4(6):536-42.
3. Schenk B, Brouwer PA. Bilateral Frontal Sinus Pericranii with an Intratrabular Course: A Case Report. *Interv Neuroradiol.* 2010 Jun;16(2):179-82.
4. Carpenter JS, Rosen CL, Bailes JE, et al. Sinus pericranii: clinical and imaging findings in two cases of spontaneous partial thrombosis. *Am. J. Neuro-radiol.* 2004 Jan 1;25(1):121-5.

5. Pavanello M, Melloni I, Antichi E, et al. Sinus pericranii: diagnosis and management in 21 pediatric patients. *J. Neurosurg.: Pediatrics*. 2015 Jan 1;15(1):60-70.
6. Buxton N, Vloeberghs M. Sinus pericranii. *Pediatric neurosurgery*. 1999; 30(2):96-9.
7. Mitsukawa N, Satoh K, Hayashi T, et al. Sinus pericranii associated with craniosynostosis. *J. Craniofacial Surg*. 2007 Jan 1;18(1):78-84.
8. Yasuda S, Enomoto T, Yamada Y, et al. Crouzon disease associated with sinus pericranii: a report on identical twin sisters. *Childs Nerv Syst*. 1993 Apr 1;9(2):119-22.
9. Vinas FC, Valenzuela S, Zuleta A. Literature review: sinus pericranii. *Neurol. Res*. 1994 Dec 1;16(6):471-4.
10. Anegawa S, Hayashi T, Torigoe R, et al. Sinus Pericranii with Severe Symptom Due to Transient Disorder of Venous Return—Case Report—. *Neurol. Med. -Chir*. 1991;31(5):287-9.
11. Sadler LR, Tarr RW, Jungreis CA, et al. Sinus pericranii: CT and MR findings. *J. Comput. Assist. Tomogr*. 1990 Jan 1;14(1):124-7.
12. Hayakawa I, Fujiwara K, Sasaki A, et al. Spontaneous regression of sinus pericranii—report of a case (author's transl). *No shinkei geka. Neurological surgery*. 1978 Jan 1;6(1):91-5.
13. Ryu JY, Lee JH, Lee JS, et al. Combined treatment of surgery and sclerotherapy for sinus pericranii. *Arch. Craniofacial Surg*. 2020 Apr;21(2):109.
14. Khachatrian VA, Khodorovskaia AM, Sebelev KI, et al. Pericranial sinus. Definition, diagnosis, surgical treatment. *Zhurnal voprosy neirokhirurgii imeni NN Burdenko*. 2014 Jan 1;78(3):30-7.
15. Gandolfo C, Krings T, Alvarez H, et al. Sinus pericranii: diagnostic and therapeutic considerations in 15 patients. *Neuroradiology*. 2007 Jun;49(6):505-14.
16. Higuchi M, Fujimoto Y, Ikeda H, et al. Sinus pericranii: neuroradiologic findings and clinical management. *Pediatr. Neurosurg*. 1997;27(6):325-8.
17. Wakisaka S, Okuda S, Soejima T, et al. Sinus pericranii. *Surg. Neurol*. 1983 Mar 1;19(3):291-8.
18. Desai K, Bhayani R, Goel A, et al. Sinus pericranii in the frontal region: a case report. *Neurol. India*. 2001 Jul 1; 49(3):305.
19. Brisman JL, Niimi Y, Berenstein A. Sinus pericranii involving the torcular sinus in a patient with Hunter's syndrome and trigonocephaly: case report and review of the literature. *Neurosurg*. 2004 Aug 1;55(2):E439-43.
20. Brook AL, Gold MM, Farinhas JM, et al. Endovascular transvenous embolization of sinus pericranii: Case report. *J. Neurosurg.: Pediatrics*. 2009 Mar 1;3(3):220-4.
21. Aburto-Murrieta Y, Bonifacio-Delgado D, Balderrama Bañares J, et al. Sinus pericranii: case report. *Vasc. Endovasc. Surg*. 2011 Jan;45(1):103-5.
22. Carpenter JS, Rosen CL, Bailes JE, et al. Sinus pericranii: clinical and imaging findings in two cases of spontaneous partial thrombosis. *Am. J. Neuro-radiol*. 2004 Jan 1;25(1):121-5.
23. Bouali S, Maatar N, Ghedira K, et al. Spontaneous involution of a sinus pericranii. *Childs Nerv Syst*. 2017 Sep;33(9):1435-7.
24. Arita K, Uozumi T, Kuwabara S, et al. A case of scalp cavernous hemangioma simulating sinus pericranii. *Hiroshima J. Med. Sci*. 1992 Mar 1;41(1):19-23.
25. Bollar A, Allut AG, Prieto A, et al. Sinus pericranii: radiological and etiopathological considerations: case report. *J. Neurosurg*. 1992 Sep 1;77(3):469-72.
26. Spektor S, Weinberger G, Constantini S, et al. Giant lateral sinus pericranii: case report. *J. Neurosurg*. 1998 Jan 1;88(1):145-7.
27. Akram H, Prezerakos G, Haliasos N, et al. Sinus pericranii: an overview and

- literature review of a rare cranial venous anomaly (a review of the existing literature with case examples). *Neurosurg. Rev.* 2012 Jan;35(1):15-26.
28. Jung S, Lee JK, Kim SH, et al. Parietal sinus pericranii: case report and technical note. *Surg. Neurol.* 2000 Sep 1;54(3):270-3.
  29. Rizvi M, Behari S, Singh RK, et al. Sinus pericranii with unusual features: multiplicity, associated dural venous lakes and venous anomaly, and a lateral location. *Acta Neurochir.* 2010 Dec;152(12):2197-204.