

## Morbidly Adherent Placenta: Clinical, Sonographic and Doppler Predictors

Abd El Aziz Galal El din Thabet Darwish<sup>1</sup>,

Mahmoud Sayed Mohamed Ali Zakhera<sup>2</sup>, Ahmed Kamel Ahmed Bakry<sup>1\*</sup>

<sup>1</sup> Obstetrics and Gynecology Department, Faculty of Medicine, Al-Azhar University, Egypt, <sup>2</sup> Obstetrics and Gynecology Department, Faculty of Medicine, Assiut University, Egypt

\*Corresponding author: Ahmed Kamel Ahmed Bakry, E mail: draahmedkamelahmed@yahoo.com

### ABSTRACT

**Background:** Placenta accreta, which complicates 0.9% of all pregnancies, is the improper implantation of the placenta into the uterine wall. Placenta previa and past uterine surgery, including caesarean delivery, are clinical risk factors.

**Aim and objectives:** This study aimed to evaluate the effectiveness of a novel, straightforward scoring method for identifying placenta accreta risk in low- and high-risk pregnant women based on sonographic markers and to identify prenatal imaging results that indicate whether a placenta previa will adhere.

**Subjects and methods:** By reviewing 150 cases of placenta previa, we created "Al- Azhar placenta accreta scoring system" and showed how it may be used to predict placenta accreta. Their clinical information and ultrasound images were gathered, and we assessed them using the scoring technique.

**Result:** 78.4% of total accreta cases that were diagnosed initially by ultrasound as total accreta were diagnosed by laparotomy and histopathology as total accreta, while 21.6% of total accrete cases finally were diagnosed as focal accreta.

**Conclusion:** In order to better prepare for birth and lower the risk of morbidity and mortality in patients with morbidly adherent placentas, the assignment of a scoring system for placenta accreta prediction throughout pregnancy may be beneficial.

**Keywords:** Adherent placenta, Placenta accreta, Clinical and sonographic predictors.

### INTRODUCTION

When a normal gestation is routinely evaluated, the placenta is frequently disregarded, it only receives attention when an anomaly is found. Despite being rare, placenta abnormalities must be recognised due to the risk of maternal and foetal morbidity and mortality <sup>(1)</sup>. When chorionic villi enter the myometrium improperly, placenta accreta develops. The placenta is divided into three grades based on histology: placenta accreta (chorionic villi in touch with the myometrium), placenta increta (chorionic villi invade the myometrium), and placenta percreta (chorionic villi enter the uterine serosa) <sup>(2)</sup>.

Age, pregnancy and placental attachment disorders (PAD) are the most common risk factors. Also, prior caesarean section, and placenta previa. Asherman syndrome and endometrial ablation are risk factors that are more rarely present. Pregnancies resulting from in vitro fertilisation have also increased <sup>(3)</sup>.

Although vaginal bleeding and discomfort might happen, placenta accreta patients are typically asymptomatic. A potentially fatal presentation is acute abdominal pain and hypotension brought on by hypovolemic shock following uterine rupture associated with placenta percreta, despite being uncommon. In the absence of labour, this serious scenario might happen at any point during pregnancy, from the first trimester to full term gestations <sup>(4)</sup>. The caring doctor should have a high index of suspicion because the majority of patients are asymptomatic. The patient's risk indicators suggest a potential diagnosis of a morbidly adherent placenta, which should be investigated further with targeted sonography <sup>(5)</sup>.

### PATIENTS AND METHODS

In a prospective cohort study, we developed "Al-Azhar placenta accreta scoring system". We retrospectively examined 150 cases of placenta previa to establish its viability in the prediction of placenta accreta. Their clinical information and ultrasound images were gathered, and they were then scored using the scoring system.

#### Inclusion criteria:

After 28 weeks of pregnancy, abdomen ultrasonography is used to diagnose all women with placenta previa anterior.

**Exclusion criteria:** Low lying placenta diagnosed before 28 weeks gestation and placenta previa posterior.

**Data collection:** the patient's hospital case number, age, level of education, domicile, employment, consanguinity, gravidity, parity, prior problems of pregnancy, gestational age, height, weight, and history of drug use, employment, education, and the husband's unique habits were all noted on a page.

**Test methods:** The study included all pregnant women seeking care at the Obstetric Outpatient Clinic or the Inpatient Obstetric Department at Assiut University Hospital who had placenta previa detected by abdominal ultrasound after 28 weeks of pregnancy. Women who were deemed to be research candidates and had placenta previa underwent abdominal ultrasounds, where the entire placenta was systematically scanned using both two-dimensional ultrasound and 2D Doppler. The angle of insonation was kept as low as

possible and the placenta was photographed with enough bladder volume to clearly see the serosa-bladder interface. Laparotomy was used to confirm the diagnosis, and a sample from a planned hysterectomy was examined for histology.

#### **Ethical Approval:**

**Each participant in the study provided written informed consent, which was obtained after the project was approved by Al-Azhar University Ethics Board. This work has been carried out in accordance with The Code of Ethics of the World Medical Association (Declaration of Helsinki) for studies involving humans.**

#### **Statistical analysis**

SPSS was used to edit and analyse the data (version 16). Analytical and descriptive numbers and percents (percents) of each variable was used to express the data. Sensitivity, specificity, positive and negative predictive values were shown.

For both 2D ultrasonographies, colour Doppler and 3D Doppler ultrasonography.

#### **Outcome measures:**

Comparison of the diagnosis of a morbidly adherent placenta made at the time of delivery using clinical criteria, 2D abdominal ultrasonography, 2D colour Doppler, and 3D power Doppler (gold standard) including: Focal or total morbidly adherent placenta, placenta separable or non-separable, degree of morbidly adherent placenta whether accrete, percreta or increta and management by conservation or hysterectomy. Confirmation of diagnosis by histopathology of hysterectomy specimen if hysterectomy would be done.

Each study participant underwent the subsequent steps: Past histories of uterine-surgery, such as prior Cesarean delivery. The same operator did complete imaging utilising both diagnostic modalities (gray-scale and 3D power Doppler), after which the captured images and volumes will be offline-analyzed in accordance with a predetermined scoring system, with full delivery information accessible. Ultrasound examination was performed using a 3D ultrasound system (4-8-MHz trans-abdominal transducer, with machine model e.g.voluson). For each patient, the

whole placenta was scanned in a systematic fashion using gray-scale. Gray-scale ultrasound imaging with at least one of the following features is indicative of placenta accreta, according to our research (including its variations, placenta increta and placenta percreta): Complete loss of the retroplacental sonolucent zone, uneven retroplacental sonolucent zone, thinned or disrupted uterine serosa-bladder interface, presence of focal exophytic masses invading the bladder, and aberrant placental lacunae <sup>(8)</sup> are all symptoms to look out for. We performed a 3D power Doppler examination specifically targeted to this region to analyse the angioarchitecture of the lower uterine segment and placenta.

The following views were successively assessed: The serosa-bladder interface and the intraplacental vasculature were shown in the lateral view along the sagittal axis of the maternal pelvis, and the serosa-bladder interface was shown in the basal view in a 90° rotation of the lateral view. To distinguish between placenta accreta and placenta previa totalis, we looked more closely at the patterns of placental vasculature as the extensive neovascularization of the utero-placental area is a noteworthy hallmark of placenta accreta. If at least one of the following 3D power Doppler criteria is demonstrated, the diagnosis of placenta accreta and its variants was considered to be positive: When seen laterally: 'Chaotic branching' in the vascular system, inseparable cotyledonal and intervillous circulations, and intraplacental hypervascularity. Vascular growth is referred to as "chaotic branching."

#### **RESULTS**

Table (1) showed that placenta previa was more common in rural women. There were 105 case of rural women. In our study there were 73 cases before age of 30 years and 77 women after age of 30 years. The mean age of cases was  $30.57 \pm 4.55$  (23.0 - 41.0) years.

A fifth of the cases (19.3%) were illiterate, while 74% of the cases were housewives. In 60% of cases, consanguinity was confirmed. About 15% of cases had illiterate husband. As regards husband occupation 43.3% were farmers, 49.3 were employee. About 76% of husbands were cigarette smokers.

**Table (1):** Distribution of all cases of placenta previa included in the study attending to Women`s Health Hospital according to some socio-demographic criteria (n=150)

	No (150)	%
<b>Age: (years)</b>		
< 30	73	48.7
≥ 30	77	51.3
Mean ± SD (Range)	30.57 ± 4.55 (23.0-41.0)	
<b>Residence:</b>		
Urban	45	30.0
Rural	105	70.0
<b>Occupation:</b>		
Working	39	26.0
Not working	111	74.0
<b>Education:</b>		
Illiterate	29	19.3
Basic education	23	15.3
Secondary	48	32.0
High education	50	33.3
<b>Consanguinity:</b>		
Yes	90	60.0
No	60	40.0
<b>Husband occupation:</b>		
Employee	74	49.3
Farmer	65	43.3
Skilled worker	11	7.3
<b>Husband education:</b>		
Illiterate	22	14.7
Basic education	5	3.3
Secondary	45	30.0
High education	78	52.0
<b>Husband smoking:</b>		
Smoker	114	76.0
Non-smoker	36	24.0

Table (2) showed that there were 82 cases of placenta previa presented with antepartum hemorrhage and 58 cases were asymptomatic. There were 99 cases terminated < 38 weeks and 51 cases terminated ≥ 38 weeks.

**Table (2):** Clinical data and presentation of the studied patients (n=150)

Variable	No (150) %
<b>Gestational age of diagnosis by ultrasound: (weeks)</b>	
< 32 weeks	91 (60.7 %)
≥ 32 weeks	59 (39.3 %)
<b>Gestational age at delivery: (weeks)</b>	
< 38 weeks	99 (66.0 %)
≥ 38 weeks	51 (34.0 %)
<b>First Presentation of the patient:</b>	
Antepartum hemorrhage	82 (54.7 %)
Premature rupture of membrane(PROM)	6 (4.0 %)
Threatened preterm labor (TPL)	4 (2.7 %)
Asymptomatic	58 (38.7 %)
<b>Placental location by US:</b>	
Placenta previa grade 4	57(38.0 %)
Placenta previa grade 3	93 (62.0 %)

Table (3) showed that the most common indication for termination of cases of placenta previa was term baby about 64.7% and elective C.S was done in 103 cases (68.7%) as a mode of termination.

**Table (3):** Data about indications for termination and mode of termination of the studied patients (n=100)

Variable	No (150) %
<b>Type of Caesarian section</b>	
Elective	103 (68.7 %)
Emergency	47 (31.3 %)
<b>Indication of Caesarian section:</b>	
Antepartum hemorrhage	38 (25.3 %)
Term	97 (64.7 %)
In labor	15 (10.0 %)

Table (4) showed that 53.3% of cases the placenta were inseparable and 46.7 % were separable. 91% of cases needed blood transfusion where there were 21% of cases needed more than 5 units of packed RBCs. 25.3% of cases needed to do hysterectomy for life saving. There were 9.3% of cases had bladder injury and vascular complications needed urology and vascular intervention.

**Table (4):** Operative data and placental separation of the studied patients

<b>Placental separation during Caesarian section</b>	
Inseparable	80 (53.3 %)
Separable	70 (46.7 %)
<b>Operative intervention</b>	
Total hysterectomy	17 (11.3 %)
Total hysterectomy with urology and vascular complications	14 (9.3 %)
Subtotal hysterectomy	7 (4.7 %)
Conservative surgery	112 (74.7 %)
<b>No. of blood units received during surgery:</b>	
0	13 (8.7 %)
1 – 2	53 (35.3 %)
3 – 4	52 (34.7 %)
5 or more	32 (21.3 %)

Table (5) showed that the initial diagnosis by ultrasound of cases revealed that 21.3% had total accreta, 61.3% had focal accreta and 17.3% had no accreta. The final diagnosis of all cases showed that 24.7% of cases were diagnosed as total accreta, 34.0% were diagnosed as focal accreta and 41.3% were diagnosed as no accreta. The final outcome showed that 75.3% received conservative management, 20% of cases had morbidity and mortality was 4% of cases.

**Table (5):** Diagnostic data of placenta accreta in the studied group

Variables	No (150) %
<b>Initial diagnosis by US:</b>	
Total accrete	32 (21.3 %)
Focal accrete	92 (61.3 %)
No accrete	26 (17.3 %)
<b>Final diagnosis:</b>	
Total accrete	37 (24.7 %)
Focal accrete	51 (34.0 %)
No accrete	62 (41.3 %)
<b>Final outcome of:</b>	
Conservative management	113 (75.3 %)
Morbidity	31 (20.7 %)
Mortality	6 (4.0 %)

Table (6) showed that the cases that ended with mortality had scores in the range of 14 to 22 with a mean of 19.67. The cases that ended with morbidity had scores in the range of 12 to 24 with a mean of 18.06. The cases that ended with conservative management had scores in the range of 0 to 16 with a mean of 7.45.

**Table (6):** relationship between the final score and final outcome

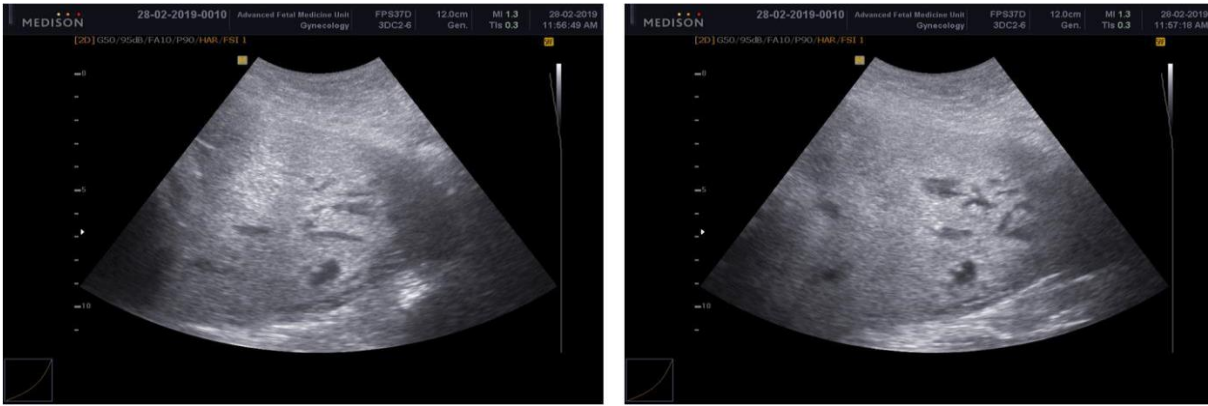
Score	Final outcome			P-value
	Conservative	Morbidity	Mortality	
Mean ± SD	7.54 ± 4.74	18.06 ± 2.85	19.67 ± 3.20	0.000*
Range	0.0-16.0	12.0-24.0	14.0-22.0	

\* \* p<0.01 = highly significant

The presence of diffuse or focal lacunar blood flow is the most sensitive criteria for placenta accreta (82.95% by 2D color Doppler ultrasound). The presence of markedly dilated vessels over the peripheral sub-placenta region is the most specific criteria for the placenta accreta (96.77% by 2D color Doppler ultrasound) as shown in table (7).

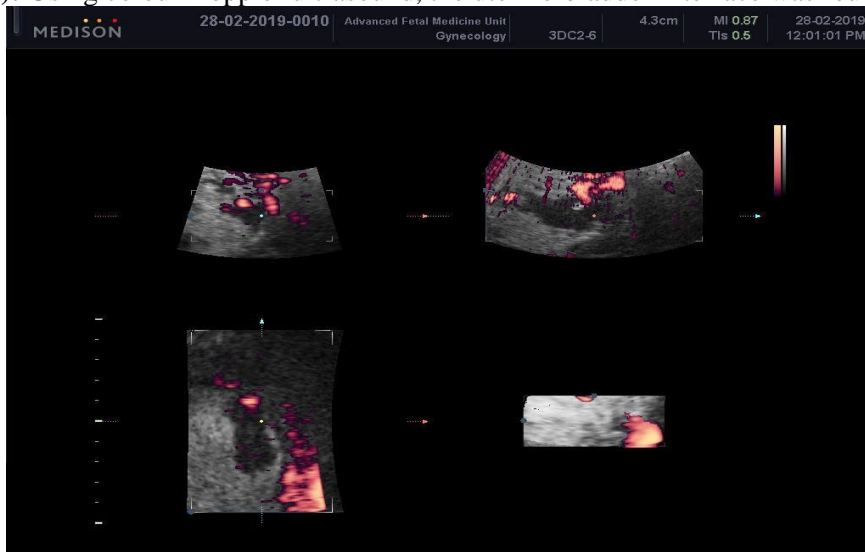
**Table (7):** sensitivity, specificity, PPV, NPV, accuracy and area under curve (AUC) of 2D gray scale ultrasonography, 2D color Doppler ultrasonography and 3D power Doppler ultrasonography in the antenatal diagnosis of placenta accreta

	Sensitivity	Specificity	PPV	NPV	Accuracy	AUC
<b>2D gray scale US:</b>						
Loss of retroplacental sonolucent zone	27.27	100.00	100.0	49.2	57.33	0.636
Irregular Retroplacental sonulcent zone	62.50	83.87	84.6	61.2	71.33	0.732
Abnormal placental lacunae	92.05	59.68	76.4	84.1	78.67	0.759
Thinning or disruption of hyperechoic serosa-bladder interface	72.73	75.81	81.0	66.2	74.00	0.743
Presence of focal exophytic masses invading the urinary Bladder	3.41	100.00	100.0	42.2	43.33	0.517
<b>2D color Doppler US:</b>						
Diffuse or focal lacunar flow pattern	82.95	82.26	86.9	77.3	82.67	0.826
Sonolucent vascular lakes with turbulent Flow	53.41	96.77	95.9	59.4	71.33	0.751
Hypervascularity of the uterine-bladder Interface	25.00	95.16	88.0	47.2	54.00	0.601
Markedly dilated vessels over the peripheral sub-placental region	78.41	96.77	97.2	75.9	86.00	0.876
<b>3D Power Doppler Ultrasound:</b>						
Numerous coherent vessels involving the whole uterine serosa-bladder junction (basal view)	65.91	95.16	95.1	66.3	78.00	0.805
Hypervascularity (lateral view)	45.45	100.00	100.0	56.4	68.00	0.727
Inseparable cotyledonal and intervillous circulation	10.23	100.00	100.0	44.0	47.33	0.551
<b>Previous one caesarian section or more</b>	100.00	1.61	59.1	100.0	59.33	0.508



**Figure (1):** irregular retroplacental sonolucent zone and abnormal placental lacunae with thinning of hyperechoic serosa-bladder interface by 2D gray scale ultrasonography.

**Figure (2):** Using colour Doppler ultrasound, the uterine-bladder interface was found to be hypervascular.



**Figure (3):** intraplacental hypervascularity by 3D power Doppler ultrasonography.

## DISCUSSION

Clinical observation revealed that only 8.7% of cases had no need for blood transfusion, 35% of cases needed at least 1000 mL of blood, and 55% of cases needed 1500 mL or more. Three patients in the accreta group overall showed more blood. Regardless of the patients' actual disease categories, the amount of bleeding and hysterectomy rate across the three patient groups varied greatly. Our study showed that using 3D power Doppler as an additional tool for antenatal diagnosis or exclusion of placenta accreta is beneficial. In this study, the mean age of all patients with placenta previa at the time of diagnosis was  $30.57 \pm 4.55$  years. 53 of them presented asymptotically, 149 had at least one prior caesarean, 82 experienced at least one antepartum haemorrhage event while pregnant. In this collection, 88 patients had placenta accreta and its variants, such as increta and percreta, validated at the time of caesarean delivery.

Before 32 weeks, placenta previa was identified in 91 individuals. All of these patients had previously undergone caesarean deliveries. 65% of patients with placenta previa had a parity of three or greater. The

average number of prior CS was  $3.24 \pm 1.12$  for whole placenta accreta,  $2.84 \pm 1.08$  for focal placenta accreta, and  $2.05 \pm 1.03$  for placenta previa. 38 patients underwent caesarean hysterectomy to stop severe postpartum bleeding. The remaining patients with focal placenta accreta were treated with piecemeal excision and hemostatic sutures without hysterectomy. 14 of the patients who received total hysterectomy during caesarean delivery also suffered urological and vascular problems. According to the original ultrasound diagnosis, there were 92 cases of localised accreta, 21 cases of placenta accreta, and 26 cases of placenta previa without accreta. The surgical diagnostic and pathological investigation resulted in the final diagnosis, which revealed that 51 cases had localised placenta accreta and 37 cases had placenta accreta. Out of the 150 patients, 62 had a confirmed diagnosis of placenta previa without accreta.

The initial diagnosis by ultrasound predicted that nearly 83% of cases had focal or total placenta accreta and 17% of cases without accreta. The final diagnosis according to operative findings and pathological analysis showed that only 59% had focal or total

placenta accreta and 41% were without accreta. By reviewing 150 cases of placenta previa, we created "Al-Azhar placenta accreta scoring system" and showed how it may be used to predict placenta accreta. We rated them using the grading system after acquiring their clinical information and ultrasound pictures. The cutoff point between focal or total accreta and no accreta was 8 when the area under the curve was 95.7% and the score was 8, according to the ROC curves, which also showed that the sensitivity and specificity were, 90.9 and 96.77% respectively. When the score was 9.5 and the area under the curve was 74.6%, the sensitivity and specificity were 55.6 and 89.5% respectively. Thus, the border value of increta and percreta was 10. We created the ensuing prospective study with the goal of confirming the validity of this approach. Since this projected that the patients will neither not have placenta accreta nor have focal accreta, we defined a score of 8 or more as the cut-off point of presence of focal or total placenta accreta. The patients with focal placenta accreta were predicted by a score between 8 and 12, which was termed as the focused accreta group. The total accreta group was characterised as a score of >12, and this score indicated that the patients would have total placenta accreta.

The aforementioned data demonstrated that the scoring method may be trusted to forecast the presence of accreta and the level of danger. A tailored follow-up and treatment plan for patients can be created based on various scoring levels. It showed a significant clinical impact on the timing of pregnancy termination, preoperative planning, surgical technique selection, and team structure. This prevented either an excessive or insufficient waste of blood preparation, which in turn decreased the likelihood of mother and infant illness and mortality Jauniaux or others <sup>(6)</sup>.

Evidence suggested that early detection of placenta accreta can help patients require less blood transfusion and less intraoperative blood loss <sup>(7)</sup>. A patient with a score of fewer than 8 points should have a second ultrasound examination every three to four weeks leading up to delivery and try to deliver after 37 weeks, depending on whether the woman experienced vaginal bleeding, stomach discomfort, or other symptoms. Patients who have previously had a Caesarean section may elect to give birth vaginally if there was no other option available to them (for example, if they have a scarred uterus or a placenta previa). Before delivery, we must prepare two units of red blood cells for this purpose without seeking advice from other departments with score of 8 and 12. Every two to three weeks before delivery, an ultrasound should be done. If possible, attempt to deliver between 35 and 36 weeks, depending on the patient's symptoms.

Although there still seems to be disagreement in the literature on how well ultrasound diagnoses placenta accreta, other studies have found similar results, with sensitivity of 89.5% and specificity of 91%. With the

exception of **Lam et al.** <sup>(8)</sup> research, all report sensitivity ranges between 77-93%, specificity ranges between 71-97%, PPV ranges between 65-88%, and NPV ranges between 92-98%.

While detecting more true positives and having a high reliability in confirming placenta accreta, abnormal placental lacunae in the current study's 2D grey scale ultrasonography has the highest sensitivity (92.05%) and unsatisfactory PPV (76.06%). As a result, it may raise expectations for placenta accreta and hysterectomies. According to **Cali et al.** <sup>(9)</sup>, the aberrant placental lacunae were the most accurate 2D grey scale ultrasonography criterion in the current study, with an NPV of 80%. According to the current study's analysis of 2D colour Doppler ultrasonography, the vessels over the peripheral sub-placental region had the highest PPV of 97%, which is in line with **Finberg and Williams** <sup>(10)</sup> but at odds with **Shih et al.** <sup>(11)</sup>.

The current work showed the possibility of detecting morbidly adherent placenta and its variants utilising a combination of useful sonographic parameters by examining the vascularity of the serosa-bladder interface and the intraplacental arteries. At the uterine serosa-bladder wall contact with extremely confluent anarchic arteries that occasionally appeared to extend into the bladder lumen, there was a noticeable hypervascular appearance. But in contrast to what **Chou et al.** <sup>(12)</sup> study's indicated, 3D demonstrated that in the case of placenta previa without accreta, the serosa-bladder wall interface was unaffected by vascularization. According to **Moniem et al.** <sup>(13)</sup>, the highest PPV and NPV (50% and 100%) are associated with intra-placental hypervascularity. The maximum PPV and NPV in the current investigation were 100% for hypervascularity with chaotic branching and 3D power Doppler and 66.3% and 66.3% respectively for multiple coherent vessels. **Shih et al.** <sup>(10)</sup> study's found that whereas tortuous vascularity with chaotic branching had the best PPV of 100%, intra-placental hypervascularity had the highest NPV at 89%.

A grading system was created by **Tovbin et al.** <sup>(14)</sup> using information from ultrasonography. They divided the patients into low, medium, and high probability groups based on the score. By placing a patient in the high probability group, they were able to predict PA with sensitivity and specificity of 69.6% and 98.7% respectively in order to predict invasive placenta previa.

**Marsoosi et al.** <sup>(15)</sup> reported that for the examination and grading of ultrasound pictures, a scoring system was devised utilising the number of prior caesarean births, the stage of the lacunae, the placement of the placenta, the Doppler assessment, and the loss of clear zone. Subjects ultimately fall into one of the following three categories after accumulating scores: Probabilities of placenta accreta are low (5 points), moderate (6-7 points), or high (8-10 points). The composite scores' area-under-the-ROC curve was 98%, and this generated scoring system overall sensitivity,

specificity, positive and negative predictive values were 91.84%, 87.27%, 86.54%, and 92.31%, respectively. In contrast, our study assigned a score of 0 or 2 depending on the presence or absence of a specific imaging observation. In our investigation, a score of 8 or higher led to the best diagnostic precision, which was comparable to earlier studies of this kind. According to our study, the scoring system's accuracy for predicting placenta accreta was 90.91% sensitive and 96.77% specific, indicating a comparatively high accuracy.

Our research had some limitations. It was looking backwards to determine the effectiveness of this scoring and stratification method in clinical practice. A prospective study would need to validate it. Since the score was determined by two readers working together rather than individually, we did not evaluate the interobserver variability while determining the score. The depth of the invasive placentation was not assessed. The score and the existence of accreta, increta, or percreta were not connected.

## CONCLUSION

Our study demonstrated that the women who were at most risk for a morbidly adherent placenta can be identified using a standardised risk assessment based on the number of prior caesarean deliveries and ultrasound results. Assignment of a scoring index for placenta accreta prediction in pregnancy may be useful for patient counselling and reduce the risk of morbidity and mortality by better preparing for delivery. All of which may ultimately improve pregnancy outcomes in women with morbidly adherent placentas if verified with a larger number of cases of placental invasion.

**Consent for Publication:** I attest that all authors have agreed to submit the work.

**Availability of data and material:** Available

**Competing interests:** None

**Funding:** No fund

**Conflicts of Interest:** According to the authors, they had no competing interests that would prevent this study from being published.

## REFERENCES

1. **Elsayes K, Trout A, Friedkin A *et al.* (2009):** Imaging of the placenta: a multi-modality pictorial review. *RadioGraphics*, 29 (5): 1371–91
2. **Tan C, Tay K, Sheah K *et al.* (2007):** Perioperative endovascular internal iliac artery occlusion balloon placement in management of placenta accreta. *Am J Roentgenol.*, 189 (5): 1158–63
3. **Comstock C, Bronsteen R (2014):** The antenatal diagnosis of placenta accreta. *BJOG Int J Obstet Gynaecol.*, 121: 171–82.
4. **Pron G, Mocarrski E, Bennett J *et al.* (2005):** Prgnancy after uterine artery embolization for leiomyomata: the Ontario multicenter trial. Ontario UFE Collaborative Group. *Obstet Gynecol.*, 105: 67-76.
5. **Berkley E, Abuhamad A (2013):** Prenatal diagnosis of placenta accreta: is sonography all we need? *J Ultrasound Med.*, 32: 1345–1350
6. **Jauniaux E, Chantraine F, Silver R *et al.* (2018):** FIGO consensus guidelines on placenta accreta spectrum disorders: epidemiology. *Int J Gynecol Obstet.*, 140: 265–273. <https://doi.org/10.1002/ijgo.12407>
7. **Zalud I (2016):** Placenta accreta: diagnosis, management and the molecular biology of the morbidly adherent placenta. *J Matern Fetal Neonatal Med.*, 29 (11): 1795–1800. <https://doi.org/10.3109/14767058.2015.1064103>
8. **Lam G, Kuller J, McMahon M (2002):** Use of magnetic resonance imaging and ultrasound in the antenatal diagnosis of placenta accreta. *J Soc Gynecol Investig.*, 9: 37– 40.
9. **Cali G, Giambanco L, Puccio G *et al.* (2013):** Morbidly adherent placenta: Evaluation of ultrasound diagnostic criteria and differentiation of placenta accreta from percreta. *Ultrasound Obstet Gynecol.*, 41: 406–412.
10. **Finberg H, Williams J (1992):** Placenta accreta: prospective sonographic diagnosis in patients with placenta previa and prior cesarean section. *J Ultrasound Med.*, 11: 333-343.
11. **Shih J, Jaraquemada J, Su Y *et al.* (2009):** Role of three-dimensional power Doppler in the antenatal diagnosis of placenta accreta: Comparison with gray-scale and color Doppler techniques. *Ultrasound Obstet Gynecol.*, 33: 193–203.
12. **Chou M, Tseng J, Ho E (2002):** The application of three dimensional color power Doppler ultrasound in the depiction of abnormal uteroplacental angioarchitecture in placenta previa percreta. *Ultrasound Obstet Gynecol.*, 19: 625-627.
13. **.moniem A, Ibrahim A, Akl S *et al.* (2015):** Accuracy of three-dimensional Multislice view Doppler in diagnosis of morbid Adherent placenta. *J Turk Ger Gynecol Assoc.*, 16 (3): 126-136. DOI: 10.5152/jtgga.2015.15
14. **Tovbin J, Melcer Y, Shor S *et al.* (2016):** Prediction of morbidly adherent placenta using a scoring system. *Ultrasound Obstet Gynecol Off J Int Soc Ultrasound Obstet Gynecol.*, 48: 504– 510. <https://doi.org/10.1002/uog.15813>
15. **Marsoosi V, Ghotbizadeh F, Hashemi N *et al.* (2020):** Development of a scoring system for prediction of placenta accreta and determine the accuracy of its results. *J Matern Fetal Neonatal Med.*, 33 (11): 1824-1830. doi: 10.1080/14767058.2018.1531119. Epub 2018. PMID: 30269669.