

Assessment of the Efficacy of Verapamil to Prevent Radial Artery Occlusion during Cardiac Catheterization Procedures: A Randomized Study Comparing Verapamil VS Placebo

Shehab Adel El Etriby*, Ahmed Yehia Ramadan Salama, Sherif Mohamed Kamel Sharaf, Ahmed Fathy Tamara

Department of Cardiology, Faculty of Medicine, Ain Shams University, Cairo, Egypt

*Corresponding author: Shehab Adel El Etriby, Mobile: (+20) 01001717943, E-mail: etribyz@gmail.com

ABSTRACT

Background: During the transradial approach, radial artery spasm is common complication that might make the patient uncomfortable or make it impossible to complete the treatment for patients over 40years old.

Objective: It was to compare the conventional spasmolytic drug (verapamil) with a placebo.

Patients and Methods: We conducted a randomised, double-blind, prospective study at two-center. After being randomly assigned to receive 2.5mg verapamil after sheath insertion and another 2.5mg before sheath removal at the end of the cardiac procedure (each diluted in 5ml normal saline) or placebo 5ml of normal saline after sheath insertion and before removal, 150 patients (75 in each group) who underwent a transradial cardiac catheterization were subsequently included.

Results: The rate of radial occlusion was nearly the same in both groups (10% vs. 15% in verapamil and placebo treated patients, respectively) at the 24-hour follow-up evaluation of the radial artery patency by pulse oximetry and radial arterial duplex. The rate of radial artery blockage was essentially the same in both groups, with insignificant p-value=0.273. There was no statistically significant differences between the two agents in lowering of the radial occlusion rate when verapamil was used (65% had patent arteries with normal flow) or normal saline (60% had patent arteries with normal flow).

Conclusion: Verapamil might not be even required as a preventative measure during transradial treatments. Absence of verapamil might not only lower the drug-related problems, but also enable the safe application of transradial technique to patients who are verapamil-incompatible.

Key words: Verapamil; Radial artery occlusion; Coronary angiography.

INTRODUCTION

Because of its safety and cost-effectiveness, transradial access has become the preferred route for performing coronary angiography (CA) and interventional procedures⁽¹⁾. This approach has fewer access site complications, a shorter hospital stay, and improved patient comfort over the traditional transfemoral approach⁽²⁾. A meta-analysis found that the transradial approach (TRA) reduced major bleeding complications by 78% when compared to the transfemoral approach⁽³⁾. In the RIVAL trial, the incidence of major vascular complications was 1.4% with radial access and 3.7% with femoral access. The most common vascular complication following transradial coronary interventions was radial artery occlusion⁽⁴⁾.

Over the past ten years, TRA has gained popularity and is regularly employed in a variety of patients. Radial artery occlusion (RAO), a drawback of transradial access despite its widespread use, may restrict its use as an access site in the future⁽⁵⁾.

Anticoagulation and intra-arterial nitroglycerine, the use of a smaller sheath, maintaining patency during hemostasis, and cutting the compression time are a few strategies that had been used to lower the incidence of RAO⁽⁶⁾.

The incidence and severity of RAO during the process are known to be decreased by intra-arterial

administration of vasodilating drugs with various mechanisms of action, such as verapamil 2.5mg and nitroglycerin 200mg⁽⁷⁾. There is currently no proof that injecting vasodilators such verapamil at the end of the surgery can lessen the likelihood of RAO.

OBJECTIVE OF THE STUDY

It is to determine the effectiveness of both agents; verapamil versus placebo (normal saline) by measuring radial vasodilator power and preventing radial occlusion during and after cardiac catheterization. To evaluate radial artery patency because of the possible link between radial trauma caused by spasm and subsequent vessel occlusion.

PATIENTS AND METHODS

Study Population:

In a prospective, randomised, placebo-controlled, double-blinded trial. It was done from June to December 2019, on 150 patients who had transradial catheterizations in two reputable radial catheter facilities (Ain Shams University hospital and Souad Kafafy hospital) were enrolled in the current study. They were sequentially randomised to have elective coronary angiography (CA) or percutaneous coronary intervention (PCI). The two groups of patients were created; the first group received 2.5mg of verapamil pre and post operation (n = 75), while the other group

received 5ml of normal saline as a placebo at the conclusion of the radial treatment.

The main out-come was the incidence of RAO, which was determined by the lack of antegrade flow one day after the transradial surgery and analysed by duplex ultrasound⁽⁸⁾, pulse oximetry of the radial artery, and the assessment was done in the dark.

Exclusion criteria:

Patients with acute coronary syndrome, hemodynamic instability, severe LV failure or any other limitations of verapamil use, known hypersensitivity to verapamil hydrochloride, abnormal **Barbeau**⁽⁹⁾ test prior to the procedure and patients taking regular anticoagulation were excluded from the study.

Following that, patients were randomly assigned in a 1:1 ratio to receive an intra-arterial dose of either 2.5mg of verapamil diluted in 5ml normal saline as a vasodilator or 5ml of normal saline (placebo) as a vasodilator.

Procedural Protocol:

After administering 1ml of 2% mepivacaine as local anaesthesia, radial artery cannulation was performed with a 20G needle (Vygon, France). French standard sheath size 6 (Maxi-mum, St. Jude Medical). Heparin (5,000 U) and 2.5mg verapamil diluted in saline were slowly administered through the radial sheath after it was inserted. Throughout the procedure, invasive pressure monitoring was used to determine the availability to administer another 2.5mg after the procedure. The procedure was performed as usual being used (i.e., in case of continuing the diagnostic study with an ad hoc coronary intervention). The period between sheath insertion and withdrawal was regarded as procedural time.

Assessment of Radial Artery Spasm:

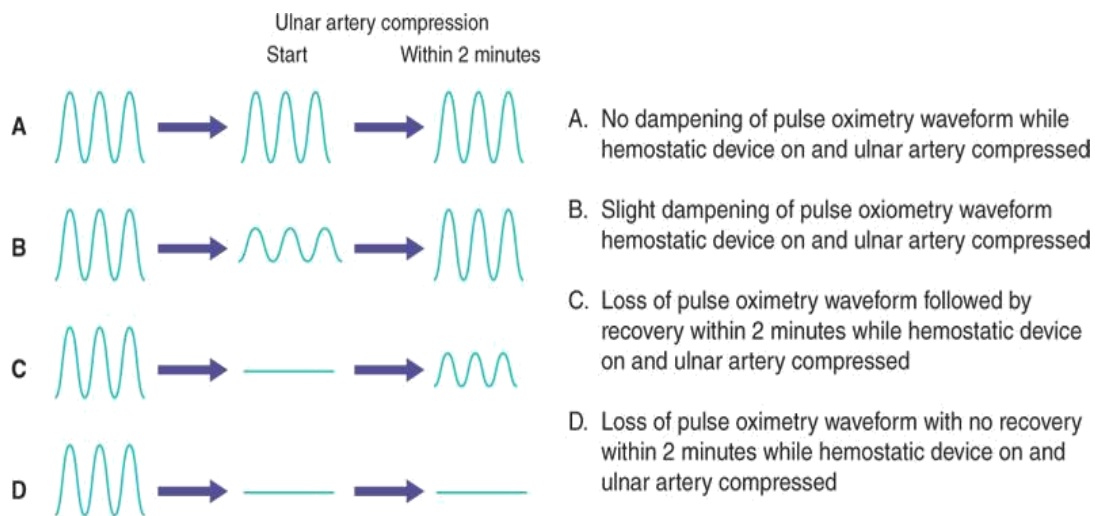


Figure (1): Showing different results of **barbeau**⁽⁹⁾ testing for co-dominance.

The technicians used a questionnaire with five items to determine the likelihood of radial artery spasm: presence of continuous forearm pain, forearm pain solely induced by catheter manipulation, forearm pain during sheath retrieval, firm grip of the catheter during manipulation, and increased resistance to sheath retrieval⁽¹⁰⁾.

When pulse oximetry was performed on the index or thumb and an occluded radial artery was found by a typical radial duplex scan, we considered radial artery occlusion as occurring (abnormal stenotic configuration of radial artery and impaired wave velocity and colour Doppler)⁽¹¹⁾.

Follow-Up Evaluation of Radial Artery Patency:

Within the first 24 hours following the procedure, the patients had another evaluation to ensure the radial artery's patency. Pulse oximetry analysis and radial arterial duplex were used to determine patency. When oxygen saturation and a duplex evaluation of radial patency utilising colour duppler and pulsed velocity were both normal, the artery was deemed patent. Occlusion of the radial artery was indicated by a pulse pressure trace that was damped and had low oxygen saturation.

Pre-, post-procedure examination of radial access of ipsilateral hand:

• **Barbeau**⁽⁹⁾ test (pre-procedure):

The index finger oximetry tracing and saturation readings were reported checking for co-dominance when the radial and ulnar arteries are blocked. Record the oximetric reading after releasing the ulnar artery. This test is deemed abnormal if the waveform was still muted two minutes after it was discharged.

• **Duplex ultrasound (24 hours post-procedure):**

The diameter, configuration, colour Doppler, pulsed wave velocity, and presence or absence of an antegrade flow in the radial artery were all noted.

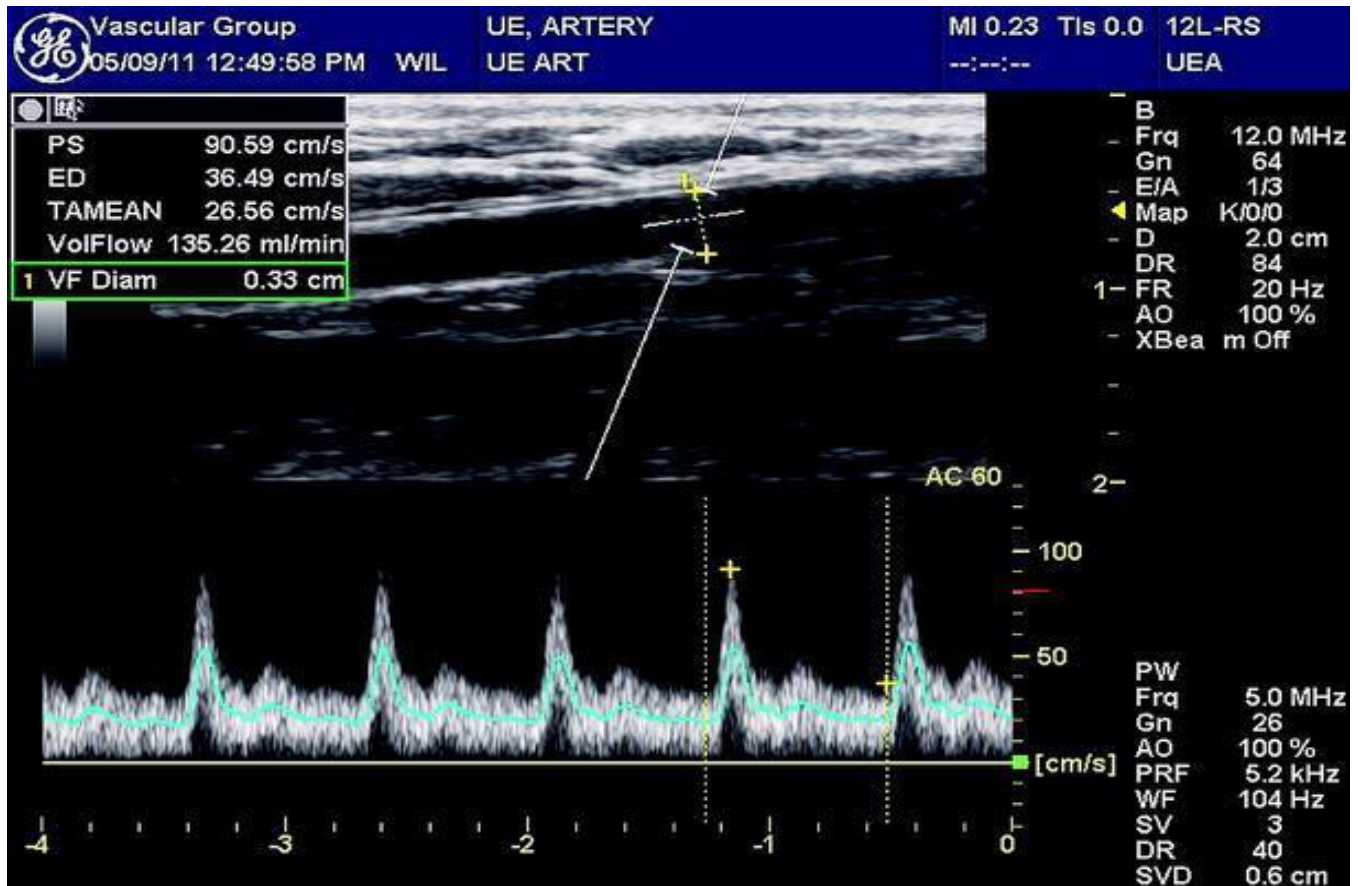


Figure (2): Showing normal pulsed wave velocity in radial artery.

Ethical Concepts:

Ethics approval was granted by the Institutional Review Board in Faculty of Medicine, Ain Shams University, Cairo, Egypt. Patients' consents were informed, written forms that obtained from all participants before their recruited in the research.

All authors had read, approved the work, and gave their agreement to publish this work. All study procedures were accordance with The Code of Ethics of the World Medical Association ⁽¹¹⁾, Declaration of Helsinki for studies involving humans.

Safety of the study:

The intra-radial injection of verapamil at the dosage employed in this trial was safe since no systemic adverse effects related to the administration of the vasodilator were noted.

In contrast, radial occlusion is a complication that, in the event that the wrong individuals are chosen, might have disastrous effects. Because radial occlusion is caused by vascular damage, it may be linked to radial artery spasm during the treatment. Official approval for our study came from Ain Shams University's Ethics Committee.

Statistical Analysis

Statistical analysis was carried out using IBM software's Statistical Package for Social Sciences (SPSS) computer software (version 22, Inc., Chicago, IL, USA). Qualitative data were presented in the form of number and frequency, while quantitative data were represented in the form of mean ± standard deviation (M ± SD). Kolmogorov-Smirnov test was used to test normality of quantitative data. Chi square test was used for compared 2 groups of qualitative data. Independent t-test was used for compared 2 groups of quantitative data. The results were considered statistically significant at $p \leq 0.05$.

RESULTS

The study was conducted on 150 patients with age ranging from 45 to 92 years old with mean age 56.55 ± 8.70 year, 118 were males (78.7%), 32 (21.3%) female patients, 49.3% smokers, 6% non-smokers, the others were ex-smokers. Twenty-four percent of patients had history of previous PCI, 76% didn't undergo PCI before, 24% of them diabetic and 66% non-diabetic patients, 54% hypertensive, and 46% non-hypertensive patients, 58% were loaded by ticagrelor while the other 42% loaded by clopidogrel, and all patients had negative troponin test result.

All of studied groups didn't show statistically significant differences as regard patient characteristic and clinical data (p-value >0.05). The procedural traits of the two groups were equivalent as well. All time, the right radial artery access was used for the entire population, and a 6 Fr sheath was inserted. A large percentage of operations was combined (Diagnostic study followed by an ad hoc coronary intervention) (Table 1; Figure 3).

Aortic pressure was monitored for similar baseline values in both groups. There were no reported negative effects of the vasodilator agent.

The attempt of radial puncture was successful for all patients and no access crossover in the whole population. Mean procedural time was 40.67±9.53 in verapamil group and 40.33±9.81 in placebo with no statistical significant difference with (p-value=0.833) (Table 2). Then after the success of procedure, patients received another dose of recommended agents intra-arterial through the sheath, then it was removed, compression was done by standard compression devices with gradual weaning of compression strength throughout 2 hrs without major complications as regard access site.

Table (1): Patients characteristics and clinical data.

Variables		No. = 150
Age (year):	Mean ±SD	56.55 ± 8.70
	Range	45 – 92
Gender:	Males	118 (78.7%)
	Females	32 (21.3%)
Smoking:	Non-smoker	74 (49.3%)
	Smoker	67 (44.7%)
	Ex-smoker	9 (6.0%)
Previous PCI:	Negative	114 (76.0%)
	Positive	36 (24.0%)
Family history:	Negative	138 (92.0%)
	Positive	12 (8.0%)
Diabetes:	Negative	84 (56.0%)
	Positive	66 (44.0%)
Hypertension:	Negative	69 (46.0%)
	Positive	81 (54.0%)
Troponin:	Negative	150 (100.0%)
	Positive	0 (0.0%)
Loading antiplatelet drug:	Ticagrelor	87 (58.0%)
	Clopidogrel	63 (42.0%)

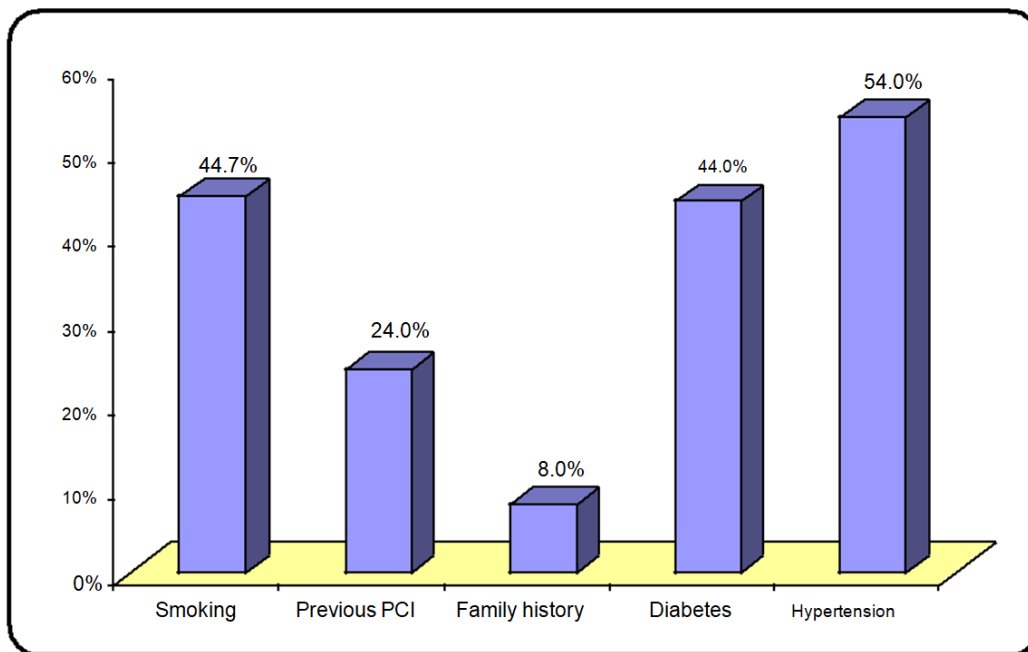


Figure (3): Patients characteristics and clinical data.

Table (2): Mean procedural time in the study groups.

Procedural Time (minutes)	No verapamil	Verapamil	t-test value•	P-value	Sig.
	No. = 75	No. = 75			
Mean ± SD	40.33 ± 9.81	40.67 ± 9.53	-0.211	0.833	NS
Range	20–45	20–45			

P-value > 0.05: Insignificant; **P-value < 0.05:** Significant; **P-value < 0.01:** Highly significant; **•:** Independent t-test

Radial artery occlusion occurred in 25 patients (16.7% of the population). Verapamil was more efficacious to prevent radial artery spasm: 13.3% of cases as compared with 20% in placebo-treated patients with insignificant difference, as regard rate of radial occlusion incidence, with (p-value >0.05) (Table 3).

Table (3): Showing no statistical significant difference between verapamil and placebo groups regarding reduction of radial occlusion rate.

Variables		No verapamil	Verapamil	Chi-Square value	P-value	Sig.
		No. = 75	No. = 75			
Radial artery patency	Negative	15(20.0%)	10 (13.3%)	1.200	0.273	NS
	Positive	60 (80.0%)	65 (86.7%)			

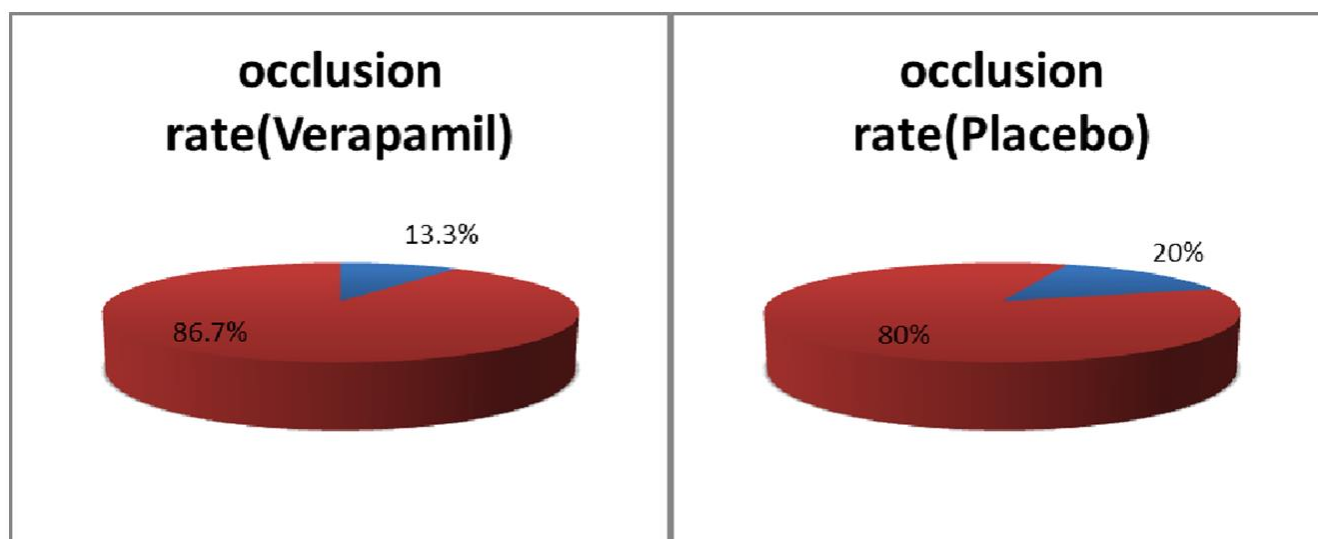


Figure (4): Comparison between verapamil and placebo groups regarding reduction of radial occlusion rate.

Follow-Up of Radial Patency:

At a mean of 24 hours after the surgery, all 75 patients on verapamil (50%) and 75 patients on placebo (50%) were followed-up on.

The two groups had comparable radial artery patency. In 86.7% of cases, patients given verapamil had complete radial patency (normal pulse tracing and saturation added on normal duplex exam), while 13.3% had radial occlusion (bad pulse tracing with declining saturation).

Patients in the placebo group had radial patency and occlusion rates of 80% and 20%, respectively. All the patients were asymptomatic at the time of the reassessment.

DISCUSSION

Radial artery vasospasm is frequent, occurring in 10–20% of radial artery surgeries⁽⁸⁾. Numerous factors may contribute to the development of radial spasm, some of which are mechanical, such as the stretching of the arterial wall brought on by an oversized sheath or the use of devices to manipulate it, while others depend on the local activity of vasoconstrictors like endothelin, tromboxane A2, or circulating sympathomimetic drugs like norepinephrine⁽¹³⁾.

Radial artery spasms make the patient uncomfortable and can require the practitioner to halt the process. Several methods have been devised to prevent radial artery vasospasm, such as proper

patient selection, avoiding this procedure when there is a suspicion that the radial artery is tiny, routine sedation, non-traumatic radial artery cannulation, and the use of a hydrophilic-coated catheter^(14,15). In addition to these maneuvers, intra-radial administration of vasodilating agents is required. Despite the use of numerous drugs such as nitrates, calcium antagonists, and lidocaine, the optimal spasmolytic therapy remains a conundrum.

Verapamil, a papaverine derivative, inhibits the slow entry of calcium ions into the cell, which is important in the contraction of cardiovascular cells. Verapamil had been shown to be an effective spasmolytic in transradial coronary interventions when combined with nitroglycerin⁽¹⁶⁾. Despite its widespread use, verapamil has some limitations as a radial spasmolytic agent. First, verapamil has a lower radial artery vasodilator power than other calcium antagonists⁽¹⁷⁾. Second, some individuals with impaired left ventricular function or conduction abnormalities have had infrequent but severe adverse effects like persistent hypotension, bradycardia, or ventricular asystole⁽¹⁸⁾. Third, 10–20% of procedures still involve spasm even when verapamil is used^(19,20). Fourth, verapamil pre and post operation vs. placebo to prevent radial occlusion in transradial technique have not been directly compared in a prior randomised investigation, to best of our knowledge.

According to our findings, there are no statistically significant differences between the two study groups in terms of the frequency of occlusion in the verapamil and non-verapamil group.

Since patients in **Hizoh *et al.***⁽²¹⁾ received a 5mg bolus in one dosage following the installation of the radial sheath, our study's technique differs from theirs in that verapamil was divided into 2.5mg pre- and post-procedure doses. The study's result was the same as ours, which found no difference between patients who received verapamil and those who received a placebo.

In contrast to other studies on the prophylactic use of verapamil in preventing radial occlusion during transradial access precardiac catheterization, the focus of this investigation was on the local effects of verapamil on the radial arterial wall that have been traumatised throughout coronary angiography, percutaneous intervention, and sheath removal. **Musahl *et al.***⁽²²⁾ studied the local effects of intra-arterial calcium channel blockers in severe cerebral artery vasospasm following subarachnoid haemorrhage and found that they were effective locally. However, there is one important difference between the two studies: in the former, verapamil was applied intra-arterially through continuous infusion for two hours, whereas in the latter, the dose was administered intra-venously.

CONCLUSION

Verapamil may not even be required as a preventative measure during transradial treatments. The absence of prophylactic verapamil may not only lower the likelihood of drug-related problems but also enable the safe application of the transradial technique to those who are verapamil-incompatible.

STUDY LIMITATIONS

The small size of our sample, the two-center study design, the pre-procedure assessment of radial artery patency using only pulse oximetry, the post-catheterization assessment being performed 24 hours after the procedure, and the lack of long-term follow-up data made it impossible to determine the incidence of radial occlusion as a common complication. Since all study participants had right radial access, it is impossible to determine whether there is a difference in the incidence of occlusion between right and left radial access.

Funding: None

Competing interests: None.

REFERENCES

1. **Archbold R, Robinson N, Schilling R (2004):** Radial artery access for coronary angiography and percutaneous coronary intervention. *BMJ.*, 329(7463):443-446.
2. **Mitchell M, Hong J, Lee B *et al.* (2012):** Systematic review and cost-benefit analysis of radial artery access for coronary angiography and intervention. *Circulation*, 5(4): 454-462.
3. **Bertrand O, Bélisle P, Joyal D *et al.* (2012):** Comparison of transradial and femoral approaches for percutaneous coronary interventions: a systematic review and hierarchical Bayesian meta-analysis. *Am Heart J.*, 163(4): 632-648.
4. **Zankl A, Andrassy M, Volz C *et al.* (2010):** Radial artery thrombosis following transradial coronary angiography: incidence and rationale for treatment of symptomatic patients with low-molecular-weight heparins. *Clin Res Cardiol.*, 99(12):841-847.
5. **Avdikos G, Karatasakis A, Tsoumeleas A *et al.* (2017):** Radial artery occlusion after transradial coronary catheterization. DOI: 10.21037/cdt.2017.03.14
6. **Dharma S, Kedev S, Patel T *et al.* (2015):** A novel approach to reduce radial artery occlusion after transradial catheterization: postprocedural/prehemostasis intra-arterial nitroglycerin. *Catheter Cardiovasc Interv.*, 85(5):818-825.
7. **Parbhoo R, Wetz K, Tschampel M *et al.* (2014):** Innovative approach to preparing radial artery cocktails in response to manufacturer shortages of nitroglycerin and verapamil. *Hosp Pharm.*, 49(7): 628-633.
8. **Kiemeneij F, Vajileshall S, Laarman G *et al.* (2003):** Evaluation of a spasmolytic cocktail to

- prevent radial artery spasm during coronary procedures. *Catheter Cardiovasc Interv.*, 58: 281–284.
9. **Barbeau GR, Arsenault F, Dugas L et al. (2004):** Evaluation of the ulnopalmar arterial arches with pulse oximetry and plethysmography: comparison with the Allen's test in 1010 patients. *Am Heart J.*, 147:489–493. doi: 10.1016/j.ahj.2003.10.038.
 10. **Ruiz-Salmerón R, Mora R, Masotti M et al. (2005):** Assessment of the efficacy of phentolamine to prevent radial artery spasm during cardiac catheterization procedures: a randomized study comparing phentolamine vs. verapamil. *Catheter Cardiovasc Interv.*, 66(2): 192-198.
 11. **World Medical Association (2013):** Declaration of Helsinki Ethical Principles for Medical Research Involving Human Subjects. *JAMA.*, 310 (20): 2191-2194.
 12. **Tola M, Yurdakul M, Ökten S et al. (2003):** Diagnosis of arterial occlusive disease of the upper extremities: Comparison of color duplex sonography and angiography. *J Clin Ultrasound*, 31(8): 407-411.
 13. **He G, Yang C (1997):** Radial artery has higher receptor-mediated contractility but similar endothelial function compared with mammary artery. *Ann Thorac Surg.*, 63: 1346 -1352.
 14. **Kiemeneij F, Fraser D, Slagboom T et al. (2003):** Hydrophilic coating aids radial sheath withdrawal and reduces patient discomfort following transradial coronary intervention: a randomized double-blind comparison of coated and uncoated sheaths. *Catheter Cardiovasc Interv.*, 59: 161– 164.
 15. **Koga S, Ikeda S, Futagawa K et al. (2004):** The use of a hydrophilic-coated catheter during transradial cardiac catheterization is associated with a low incidence of radial artery spasm. *Int J Cardiol.*, 96: 255– 258.
 16. **Kiemeneij F, Vajleshall S, Laarman G et al. (2003):** Evaluation of a spasmolytic cocktail to prevent radial artery spasm during coronary procedures. *Catheter Cardiovasc Interv.*, 58: 281–284. doi: 10.1002/ccd.10445.
 17. **He G, Yang C (2000):** Comparative study on calcium channel antagonists in the human radial artery: clinical implications. *J Thorac Cardiovasc Surg.*, 119: 94– 100.
 18. **Lewis J (1983):** Adverse reactions to calcium antagonists. *Drugs*, 25: 196– 222.
 19. **Kiemeneij F, Vajleshall S, Laarman G et al. (2003):** Evaluation of a spasmolytic cocktail to prevent radial artery spasm during coronary procedures. *Catheter Cardiovasc Interv.*, 58: 281–284.
 20. **Mont'Alverne Filho J, Assad J, Zago Ado C et al. (2003):** Comparative study of the use of diltiazem as an antispasmodic drug in coronary angiography via the transradial approach. *Arq Bras Cardiol.*, 81: 59– 63.
 21. **Hizoh I, Majoros Z, Major L et al. (2014):** Need for Prophylactic Application of Verapamil in Transradial Coronary Procedures: A Randomized Trial: The VITRIOL (Is Verapamil In TransRadial Interventions OmittabLe?) Trial. *J Am Heart Assoc.*, 3(2): e000588. DOI: 10.1161/JAHA.113.000588
 22. **Musahl C, Henkes H, Vajda Z et al. (2011):** Continuous local intra-arterial nimodipine administration in severe symptomatic vasospasm after subarachnoid hemorrhage. *Neurosurg.*, 68(6): 1541-1547.