

Microsurgical Decompression of C2 Nerve and Ganglion as a Treatment Option for Occipital Neuralgia with Migraine

Mohammed Hammad Eltantawy*, Ahmad Arab, Shawky A. Elmeleigy

Department of Neurosurgery, Faculty of Medicine, Banha University, Egypt

*Corresponding author: Mohammed H. Eltantawy, Mobile: (+20)01000221379, Email: hammad_neurosurg@yahoo.com

ABSTRACT

Background: Occipital neuralgia associated with migraine or cervicogenic headache is not uncommon clinical syndrome. It's still a debatable issue regarding the pathogenesis and treatment options in the literature.

Objective: It was to study and analyze the rule of microsurgical decompression of C2 nerve and its ganglion in management of intractable occipital neuralgia with migraine.

Patients and Methods: Thirty-six patients with this syndrome had been subjected to full clinical assessment to fulfill the clinical criteria of having occipital neuralgia with migraine (cervicogenic headache). All patients were subjected to image guided C2 ganglion anesthetic block and corticosteroid administration as a therapeutic test.

Results: Among the 10 patients who had surgery and during a mean full up period of 28.1 months, 6 patients 60% (7 sides) were totally free of pain. Three patients (30%) showed moderate degree of improvement with less frequent attacks and controlled with minor medication. Only one patient (10%) showed no improvement but still without worsening of his preoperative symptoms. In nine patients (90%) the main pathology was vascular compression by vertebral venous plexus around the root and ganglion, while in six (60%) patients we found the hypertrophied dorsal atlanto-epistrophic ligament is the main pathology. Osteoarthritic sharp lower border of C1 vertebrae and lateral mass were found in three patients (30%). **Conclusion:** Good selection of patients with typical clinical presentation together with C2 ganglion anesthetic block were the key of success of microsurgical decompression of C2 nerve and ganglion as a valid treatment option in intractable occipital neuralgia with migraine.

Keywords: Occipital neuralgia, Cervicogenic headache, Migraine, C2 nerve decompression.

INTRODUCTION

The term occipital neuralgia describes clinical syndrome of headache that has been defined by the International Classification of Headache Disorders⁽¹⁾ (3rd edition) as sharp shooting pain radiating from the occipital area into the distribution of the greater, lesser, and or 3rd occipital nerves, to the temple and the forehead. Sometimes it can be associated with constant dull aching pain between the attacks. This type of headache is usually difficult to distinguish from migraine headache and maybe associated or precipitated by it forming a clinical syndrome called cervicogenic headache. Concomitant presence of the term occipital neuralgia and migraine headaches has been noted in the literature⁽²⁻⁵⁾. Neck pain has been found to be a predominant symptom in up to 68% of patients with migraine the pain usually relieves by occipital nerve block or C2 nerve and ganglion blockade⁽⁴⁾.

Different modalities of treatment has been proposed to manage properly cervicogenic headache⁽⁶⁾. Some studies had focused on the role of C2 nerve and ganglion entrapment by different pathologies as a causative agent of this type of headache^(2,7,8).

AIM OF THE STUDY

It is to review our results of microsurgical decompression of C2 nerve and its ganglion for treatment of intractable occipital neuralgia with migraine or the so-called (cervicogenic headache).

PATIENTS AND METHODS

Thirty-six patients had been diagnosed as cervicogenic headache (20 females and 16 males), after fulfilling the diagnostic criteria, from June 2017 to March 2022. All of them had been treated as intractable cervicogenic headache with long history of medical treatment by other doctors (Table 1).

Different modalities of treatment had been given to all patients; 20 patients decided to go with conservative treatment only in spite of unsatisfactory results, six patients get benefit from repeated local injection with corticosteroid during a mean follow up of 18.4 months.

Full history and clinical examination has been taken on all patients to confirm the diagnostic criteria of this type of headache according to the ICHD 3⁽⁶⁾.

All patients had MRI brain, cervical spine, and fundus exam to exclude other pathologies that may explain their headache. Cervical disc disease or advanced cervical spondylosis has been excluded.

All patients underwent a diagnostic image guided C2 ganglion anesthetic blockade with corticosteroid administration as a therapeutic test. All patients showed positive response.

The technique has been done with the spinal needle introduced to the anatomical site of C2 below C1 arch, and against lateral C1-C2 joint under C arm image Control. Injecting 5CC's of light Marcaine and confirm the disappearance of symptoms, followed by one vial of long-acting corticosteroid injection. Temporary relief of symptoms is strong evidence of involvement of C2 nerve and ganglion in the etiology of this type of headache (Fig. 1).

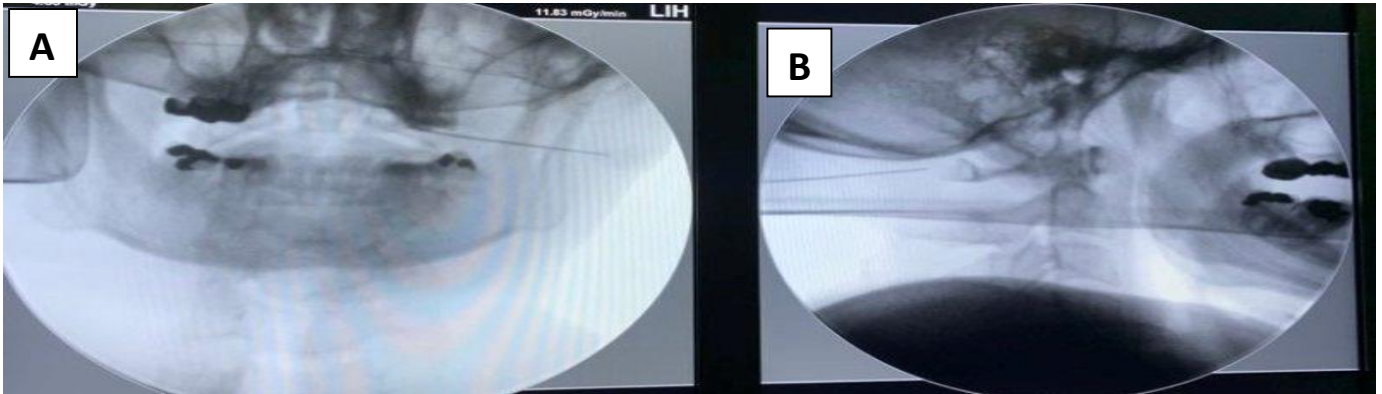


Fig. (1): Image guided local anesthetic injection of C2 nerve and ganglion with spinal needle. (A) Anteroposterior projection towards atlantoaxial Joint. (B) Lateral projection not to exceed C1 arch.

Different modalities of treatment have been discussed with all 36 patients Only 10 patients (11 sides) agreed to have microscopic C2 nerve decompression due to their intractable symptoms.

Operative details:

Patients have been operated in prone position, with midline skin incision over the cranio-cervical junction. Skin, subcutaneous and fascial dissection is then made until we reach the posterior border C1 arch, where the muscular attachment is dissected from medial to lateral. The posterior atlantoaxial ligament is then removed until the dura between C1 and C2 is exposed. Under magnification of the operating microscope, with the assistance of microsurgical tools, the hypertrophied posterior leaflet of the atlanto-epistropheic ligament is coagulated and sharply dissected to expose the medial part of C2 root dural sheath.

Following the root till it forms the ganglion, all the offending vertebral venous plexuses should be coagulated and dissected. Adequate decompression of C2 root and ganglion sometimes needs drilling of the bony spurs of the inferior border of C1 Arch.

The final result should be freeing the C2 nerve and ganglion from all compressive offending pathologies from the dural attachment medially till the nerve enters the muscles laterally (Figure 2).

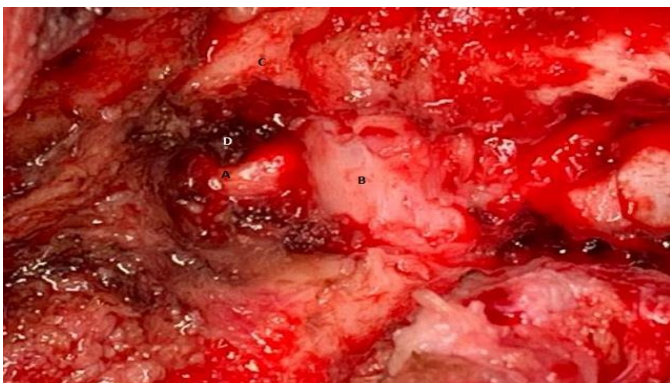

Fig. (2): Intra operative picture after complete decompression of C2 nerve and ganglion (A), showing the dura between C1 and C2 (B), posterior arch of C1(C), coagulated and dissected atlanto-epistropheic ligament (D).

Intraoperative and immediate postoperative data has been collected and evaluated. The 10 patients

have been evaluated postoperatively at regular follow up visits for a mean follow up period of 28.1 months (6 months-40 months).

Patients have been classified according to their response of pain control after surgery into 3 categories:

- **No improvement:** Patients who showed same degree of pain as preoperative.
- **Accepted improvement:** Those patients who showed significant reduction of pain intensity and frequency of attacks with reduction in the need of medication.
- **Full improvement:** Patients who showed complete relief of pain and stoppage of headache medications.

Ethical consent:

An approval of the study was obtained from Benha University Academic and Ethical Committee. Each patient or first degree relative signed a written informed consent after explaining all steps of this surgery and the surgical steps, benefits and complications, which were clearly explained to them.

This work has been carried out in accordance with The Code of Ethics of the World Medical Association (Declaration of Helsinki) for studies involving humans.

Statistical analysis

The collected data were coded, processed and analyzed using the SPSS (Statistical Package for Social Sciences) version 20 for Windows® (IBM SPSS Inc, Chicago, IL, USA).

Quantitative data were analyzed using mean, standard deviation (SD), while frequency and percentage were used with qualitative data.

RESULTS

Table (1) shows patients demographics at the beginning of this study.

Table (1): Patients' demographics

Variable	No. of patients
Total number of patients	36 (100%)
Males	16 (44.4%)
Females	20 (55.6%)
Mean age at presentation ±SD	39 years ±11.4 years
Mean duration of symptoms ±SD	17 months± 28 months

Table (2) shows the clinical presentation of all patients in the beginning of the study.

Table (2): Clinical presentation of the 36 patients with cervicogenic headache.

Clinical presentation	No. (%)
unilateral headache	32 (88.9%)
bilateral presentation	4 (11.1%)
side locked	36 (100%)
triggered by neck flexion	36 (100%)
partial relief by neck extension to the side of pain	30 (83.3%)
Diminished range of neck movement	28 (77.8%)
Positive response to local anesthetic blockade	36 (100%)
the pain travels to temporal frontal and periorbital areas	26 (72.2%)
associated with autonomic manifestations nausea vomiting photophobia	20 (55.6%)
Weak response to anti migraine treatment or other headache medications	29 (80.6%)

Different modalities of treatment have been discussed with all 36 patients; 20 patients (55.6%) decided to go with non-surgical treatment and have been referred to our pain clinic for possible pulsed radio frequency. Six patients (16.7%) get benefit from repeated local injection with corticosteroids during a mean follow up Of 18.1 months. Only 10 patients (11 sides) (27.8%) agreed to have microscopic C2 nerve decompression due to their intractable symptoms (Table 3).

Table (3): Different modalities of treatment chosen by the 36 patients.

Modality of treatment chosen by patients	No. (%)
Conservative treatment because of refusal of surgery	20 (55.6%)
Benefit from repeated injection	6 (16.7%)
C2 nerve decompression surgery	10 (27.8%)
Total	36 (100%)

Eleven sides have been operated on 10 patients at the neurosurgery department of Banha Faculty of Medicine. The microsurgical decompression of C2 nerve and ganglion was successful in long term control

of headache in six patients (60%) (seven sides). Those patients did not suffer from any recurrence of their symptoms in the mean follow up period. Three patients (30%) reported their improvement after surgery as accepted improvement with less frequent attacks, decreased intensity of pain and decreased the need for medication. One of the three patients developed recurrence in his preoperative symptoms after 11 months that necessitated reevaluation. Only one patient (10%) showed no improvement of his preoperative symptoms but still without worsening of it (Table 4).

Table (4): Degree of post operative improvement of 10 patients (11 sides) during a mean of 28.1 months follow up.

Degree of improvement	No. (%)
fully improved	6 patients (seven sides) (60%)
accepted improvement	3 patients (30%)
no improvement	One patient (10%)
worsening of preoperative symptoms	Zero patient (0%)

This patient has been evaluated by C2 nerve blockade and offered another surgery, but he refused and has been sent to pain clinic for possible pulsed radiofrequency. The main offending intraoperative pathology was found to be compression by Venus plexus in nine patients (90%), while hypertrophied atlanto-episthophic ligament was found in seven patients (70%). Sharp lower border of C1 vertebral arch was found in two patients (20%) (Table 5).

Table (5): The main offending pathology found at surgery accounts for C2 compression

Offending pathology	No. (%)
Venus plexus	9 patients (10 sides) (90%)
hypertrophied ligament	7 patients (70%)
bony impingement	Two patients (20%)

No mortality or major morbidity has been encountered in our series. Although during dissection of the venous plexus around the nerve, brisk bleeding may be encountered, but good microscopic bipolar coagulation made the mean blood loss during surgery not exceeding average of 100CC's and no one needed blood transfusion. Three patients developed transient dyesthesia along C2 distribution after surgery that resolved within average of six months in two, and persist in one. No motor weakness or CSF leak has been encountered in our study.

DISCUSSION

Anatomical consideration:

The migranous portion of cervicogenic headache can be explained by the fact that; the trigeminocervical nucleus located in the upper part of

the cervical cord function as a relay station receiving afferent fibers from both the trigeminal nucleus as well as the upper 3 cervical spinal nerves⁽⁹⁾. This will lead to the projection of nociceptive pain sensation in the face and temple, although innervated by the 5th nerve, but originating in the upper cervical area^(6,10).

The Atlanto-epistropheic ligament anatomy is not well studied in the literature, although many authors raised the importance of it as a compressive element on C2 nerve and ganglion^(1,2,7,8).

This ligament encloses the nerve and ganglion from medial to lateral as a sleeve formed of dorsal and ventral parts. Medially the ligament is attached to the dura, superiorly to the inferior border of C1 arch and inferiorly to C2 pedicle⁽⁸⁾.

Epidemiology:

Occipital neuralgia with migraine or the so-called cervicogenic headache is not uncommon clinical syndrome. It affects from 0.4% to 2.5% of the general population⁽¹⁾. Other studies suggested higher incidence up to 4% of the population⁽¹¹⁾.

Cervicogenic headache may contribute to 15 to 20% of chronic headache patients. Usually, it affects middle-aged persons and has a female predominance⁽⁹⁾. It significantly affects the quality of life because it tends to be chronic.

History:

The early reports in literature describing the headache caused by pathology in the neck was done by Holmes in 1913⁽¹²⁾.

The term "cervicogenic headache" was mentioned to describe patients with headache originating in the cervical spine **Sjaastad et al.**⁽¹³⁾ in 1983, they established the Cervicogenic Headache International Study Group (CHIG) in 1987 to describe clearly this type of headache.

Suboccipital pain radiating to the temple was defined as occipital neuralgia by Haddon. He noticed disappearance of nausea and vomiting associated with this pain by greater occipital nerve blockade or C2 nerve blockade⁽¹²⁾.

It was not until 1994, when the International Association for the Study of Pain⁽¹²⁾ (IASP) recognized the cervicogenic headache in a formal description.

Clinical criteria:

The International Headache Society described cervicogenic headache as being a unilateral headache originating in the suboccipital area and tends to propagate towards the temporal, periorbital, and sometimes the frontal or paraital regions. Bilateral presentation is uncommon, and the pain does not alternate between both sides (side locked).

Movement of the cervical spine usually aggravate the headache. The condition may be associated with aura like symptoms of migraine, example nausea and photophobia.

According to the IHS classification also the headache usually aborted by cervical nerve blockade⁽¹⁴⁾. All radiological pathologies including the cervical Spondylosis were not included in the classification as a cause of this type of headache.

Occipital Neuralgia has been defined by the international classification of headache disorders (ICHD-3) in its third edition as a sharp pain originating from the occipital area into the dermatomal supply of the greeter, lesser, and or third occipital nerves, towards the temple and forehead⁽¹⁵⁾.

This sharp pain maybe associated with persistent dull aching pain in between the attacks, tapping on the nerves usually produce pain and nerve blockage is usually effective in relieving pain temporarily (headache classification committee of HIS)⁽¹⁵⁾.

Although the international Headache Society described occipital neuralgia and cervicogenic headache as two different types of secondary headache disorders, many old and recent literature did not find a distinct difference between both conditions either in the clinical presentation or the modalities of treatment^(1,2,5,6,7,16).

Migraine like symptoms was found to be a constant feature in both types of headache. Although classical migraine may have specific clinical features, in which occipital pain is not usually a part of⁽⁴⁾. Occipital neuralgia usually presents in one side with propagation to periorbital and frontal areas.

In 2010 a study has been conducted on 35 patients with occipital neuralgia and migraine the authors concluded that; clinicians must screen patients with migraine for symptoms of occipital neuralgia because of similarities in presentation⁽⁴⁾.

Due to this overlap in symptoms between cervicogenic headache and migraine, **Yi and his colleagues**⁽⁵⁾ raised the question about whether the presumed migraine in patients with cervicogenic headache, is this a misdiagnosis or missed diagnosis, and they found that migraine relief occurred with occipital nerve blockade instead of usual migraine treatment.

Pathological consideration:

Depending on the fact that C2 spinal nerve is the root value of the greater and lesser occipital nerves which is involved in the pathology of cervicogenic headache, different pathologies affecting the C2 nerve, and its ganglion are considered as a pathogenesis of this type of headache⁽¹⁾.

Entrapment of the C2 nerve by hypertrophied atlanto-epistropheic ligament, compression by dense venous plexus varicosities derived from the vertebral venous plexus⁽⁸⁾, irritation by C1 posterior arch, osteoarthritis of C1-C2 joint, direct compression by aberrant or ectatic artery, trauma with rotation and extension at the atlanto axial joint and rarely tumors such as osteochondromas of cervical vertebrae and C2 neuromas, are all possible pathologies that may be

separately or in combination share in the pathogenesis of cervicogenic headache^(1,7).

Modalities of treatment:

Before starting the treatment of cervicogenic headache, full radiological evaluation should be done to exclude any underlying cervical spine pathology or instability⁽¹⁷⁾, as well as metabolic or inflammatory diseases that may produce same picture⁽¹⁸⁾. In such cases treatment should be directed toward the individual pathology.

Physiotherapy and spinal manipulation can be tried in the beginning of treatment. **Haos et al.**⁽¹⁹⁾ found them 50% more likely to improve pain scores.

All used medical treatment are not FDA approved for patients with cervicogenic headache⁽²⁰⁾, and is mainly based on case reports⁽⁶⁾.

Botulinum toxin A injection, although approved for chronic migraine, little information was found to support its use in cervicogenic headache and occipital neuralgia⁽²¹⁾.

Repeated occipital nerve blockade with or without corticosteroid, have 15 to 36% extended relief in some studies⁽²²⁾.

Although long term relief is questionable, the rule of ultrasound guided proximal nerve blockade for C2 nerve as a therapeutic test prior to nerve decompression Surgery, has been found to be effective⁽²³⁾.

Pulsed radiofrequency ablation to the greater occipital and lesser occipital nerves was found to be effective and safe in control of occipital neuralgia with migraine at six weeks⁽²⁴⁾.

Occipital nerve stimulation has been recently used in management of occipital neuralgia with migraine, supported by the guideline of the Congress of neurological surgeon 2015 (Level 3)⁽²⁵⁾.

Surgical treatment of occipital neuralgia with migraine (cervicogenic headache):

Barmherzig and Kingstem⁽⁶⁾ in 2019 suggested that those patients should be subjected to psychological assessment prior to any intervention to improve the functional outcome and to manage the psychological impact of their chronic headache.

In this study none of our patients have been subjected to psychological assessment before surgery which may affected our results, because of the subjective nature of their complain.

Varieties of surgical management for intractable cervicogenic headache have been described in literature. Greater occipital nerve neurectomy, although seems to relieve the pain, but has high recurrence rate. In one study, occipital neurectomy showed 70% response with only 8.1 months pain relief⁽¹⁹⁾.

Greater occipital nerve neurolysis has been advocated by some authors, but still the results showed high rate of recurrence⁽²⁶⁾.

McNutt et al.⁽²⁷⁾ in their systematic review found no evidence supporting neurolysis over neurectomy in management of cervicogenic headache.

C2 ganglionectomy has been described by lozano etal on 39 patients, they noticed 90% decrease in pain in 19 patients and 50 to 90% decrease in pain in seven patients⁽²⁸⁾.

Other authors found less degree of improvement in small series^(29,30). Being a destructive surgery, permanent sensory loss and deafferentation pain syndrome is a major concern⁽⁹⁾.

C2 nerve and ganglion decompression:

In our study we tried to describe the rule of microsurgical decompression of C2 nerve and its ganglion in management of intractable occipital neuralgia with migraine or the so-called cervicogenic headache. All of our patients have been subjected to C2 nerve blockade with corticosteroid administration, a transient relief of pain has been noted which suggested the possible C2 nerve pathology as being the pathogenesis of pain. Repeated injection in six patients were associated with satisfactory results.

Many authors advocated using greater occipital nerve or C2 nerve blockade before surgery as a therapeutic test^(26,30).

C2 blockade was found to be superior in predicting proximal pathology⁽⁷⁾, however other authors found it not efficiently predictive of success of surgery^(3,31).

In our study 10 patients (11 sides) have been subjected to microscopic C2 nerve decompression. Six patients (60%) with 7 sides reported successful long term control of pain during a mean follow up period of 28.1 months, 3 patients (30%) reported accepted improvement, while only one patient (10%) did not benefit at all from surgery.

Other authors described the same technique as being physiological nondestructive. **Stechison et al.**⁽³²⁾ 1997 noticed excellent improvement in five patients. **Pikus et al.**⁽⁷⁾ found adequate pain relief of 90% of his patients during mean follow-up of 21 months. **Jansen et al.**⁽³⁰⁾ performed C2 nerve decompression on six patients with good results.

In 1993 **Jho and Janetta**⁽²⁾ presented 16 patients suffering from cervicogenic headache ,and operated upon with C2 nerve and ganglion decompression, in the 61st annual meeting of AANS. All their patients responded to C2 nerve blockade prior to surgery. After surgery, their patients described complete resolution of their preoperative symptoms.

Pikus et al.⁽⁷⁾ 1996 reported C2 decompression on 35 patients (39 sides). After a mean follow-up of 21 months, 12 patients (13 sides) were totally free of pain, while 15 were adequately improved. Surgery has been failed in eight patients.

The main offending pathology in our study was compression by venous plexus in nine patients (90%), hypertrophied atlanto-epistophic ligament in seven

patients (70%), and bony impingement in two patients (20%).

Pikus et al.⁽⁷⁾ found venous compression in 85% of patients, scarred thickened ligament in 66% of patients and distorted root in 51% of patients. History of trauma was evident in his series.

Jansen et al.⁽³⁰⁾ operated on 16 patients, 13 of them had varicosities surrounding the C2 ganglion. **Jho and Jannetta**⁽²⁾ also reported vascular plexuses and hypertrophied ligament as the main finding.

Direct arterial compression by ectatic radicular arteries has been found by Jansen in some cases⁽³⁰⁾. Another author found cranial distortion of the root together with hypertrophy of the ligament as the main offending pathology⁽⁸⁾.

Proper selection of patients according to criteria of cervicogenic headache as well as successful C2 nerve blockade were associated with better surgical outcome in our study. Similar results have been shown by others^(7,22).

No significant morbidity was linked to surgery in our study. Only annoying numbness in distribution of greater occipital nerve was noticed in three patients (30%), resolved within average of 6 months in 2 patients and only decreased in one patient. This may be related to the use of bipolar coagulation to control bleeding from venous plexus around the C2 ganglion. Blood loss was minimal in spite of attacks of brisk bleeding while cutting and coagulating the venous plexus.

Unsatisfactory outcome from microsurgical decompression of C2 nerve may contribute too many factors. The subjective nature of pain in chronic patients with psychological impact, may made the description of improvement unclear by patients⁽³³⁾, made it difficult to evaluate the outcome. That's why a routine psychological evaluation of all patients with the cervicogenic headache must be made prior to surgery.

Another factor that may affect the outcome is the possible involvement of C3 nerve root which would be untreated in C2 decompression^(34,35).

Other factors; may be the minimal instability which can be found between C1 and C2 joints that can irritate C2 nerve and produce same clinical picture, in which C1-C2 fixation is the ideal treatment⁽⁶⁾.

Probably due to the widespread of interventional methods of pain management used in cervicogenic headache nowadays, surgery for this type of headache has not gained the same popularity as it was in the early 90s.

Although pulsed radio frequency and occipital nerve stimulation seems to be simple and less invasive, still the effect is usually transient, and their long-term control of pain is uncertain⁽²⁴⁾.

Every effort should be made by neurosurgeons to resume the popularity of the surgical procedures for pain control. Also, the need for large series of surgeries to be compared with the interventional methods of pain management should be done.

CONCLUSION

Occipital neuralgia with migraine or cervicogenic is a debilitating clinical syndrome all clinicians should be aware of. In patients with migraine, occipital neuralgia may be concomitantly present but tend to be undiagnosed and therefore improperly treated. Good selection of patients with typical clinical presentation together with successful C2 blockade are the keys for success of the microsurgical decompression of C2 nerve as a valid treatment option in intractable occipital neuralgia with migraine. Further studies are needed to evaluate different modalities of treatment.

Financial support and sponsorship: Nil.

Conflict of interest: Nil.

REFERENCES

1. **Pan W, Peng J, Elmofty D (2021):** Occipital Neuralgia. *Curr Pain Headache Rep.*, 25:61. doi: 10.1007/s11916-021-00972-1.
2. **Weiner R, Reed K (1999):** Peripheral neurostimulation for control of intractable occipital neuralgia. *Neuromodulation*, 2:217–21.
3. **Pikus H, Phillips J (1995):** Characteristics of patients successfully treated for cervicogenic headache by surgical decompression of the second cervical root. *Headache*, 35:621-9.
4. **Sahai-Srivastava S, Zheng L (2011):** Occipital neuralgia with and without migraine: difference in pain characteristics and risk factors. *Headache*, 51:124-128.
5. **Yi X, Cook A, Hamill-Ruth R et al. (2005):** Cervicogenic Headache in Patients With Presumed Migraine: Missed Diagnosis or Misdiagnosis? *J Pain*, 6: 700-703.
6. **Barmherzig R, Kingston W (2019):** Occipital neuralgia and cervicogenic headache: diagnosis and management. *Curr Neurol Neurosci Rep.*, 19(5):1–8.
7. **Pikus H, Phillips J (1996):** Outcome of surgical decompression of the second cervical root for cervicogenic headache. *Neurosurgery*, 39:63-71.
8. **Poletti C, Sweet W (1990):** Entrapment of the C2 root and ganglion by the atlanto epistrophic ligament: Clinical syndrome and surgical anatomy. *Neurosurgery*, 27:288-291.
9. **Rana M (2013):** Managing and treating headache of cervicogenic origin. *Med Clin North Am.*, 97(2):267-80.
10. **Shimohata K, Hasegawa K, Onodera O et al. (2017):** The clinical features, risk factors, and surgical treatment of cervicogenic headache in patients with cervical spine disorders. *Headache*, 57(7):1109–17.
11. **Anthony M (2000):** Cervicogenic headache: prevalence and response to local steroid therapy. *Clin Exp Rheumatol.*, 18(19):59–64.
12. **Antonaci F, Bono G, Mauri M et al. (2005):** Concepts leading to the definition of the term cervicogenic headache: a historical overview. *J Headache Pain*, 6(6):462–6.
13. **Sjaastad O, Saunte C, Hovdahl H et al. (1983):** "Cervicogenic" headache - An hypothesis. *Cephalalgia*, 3:249-56.

14. **Stovner L, Andree C (2010):** Prevalence of headache in Europe: a review for the Eurolight project. *J Headache Pain*, 11(4):289–299.
15. **Headache Classification Committee of the International Headache Society (2018):** The International Classification of Headache Disorders, 3rd edition. *Cephalalgia*, 38(1):1-211. doi: 10.1177/0333102417738202.
16. **Becker W (2010):** Cervicogenic headache: evidence that the neck is a pain generator. *Headache*, 50(4):699–705.
17. **Ehni G, Benner B (1984):** Occipital neuralgia and C1-C2 arthrosis. *N Engl J Med.*, 310: 127. doi: 10.1056/NEJM198401123100220.
18. **Jundt J, Mock D (1991):** Temporal arteritis with normal erythrocyte sedimentation rates presenting as occipital neuralgia. *Arthritis Rheum.*, 34:217-19.
19. **Haas M, Spegman A, Peterson D et al. (2010):** Does manipulation for chronic cervicogenic headache: a pilot randomized controlled trial. *Spine J.*, 10:117–28.
20. **Biondi D (2005):** Cervicogenic headache: a review of diagnostic and treatment strategies. *J Am Osteopath Assoc.*, 105(4 Suppl 2): 18–22.
21. **Linde M, Hagen K, Salvesen Ø et al. (2001):** Onabotulinum toxin a treatment of cervicogenic headache: a randomised, double-blind, placebo-controlled crossover study. *Cephalalgia*, 31(7):797–807.
22. **Choi I, Jeon S (2016):** Neuralgias of the head: occipital neuralgia. *J Korean Med Sci.*, 31(4):479–88.
23. **Doddamani R, Meena R, Sawarker D et al. (2020):** Management options in occipital neuralgia: a review. *J Peripher Nerve Surg.*, 4:7–14.
24. **Choi H, Oh I, Choi S et al. (2012):** Clinical outcomes of pulsed radiofrequency neuromodulation for the treatment of occipital neuralgia. *J Korean Neurosurg Soc.*, 51(5):281–5.
25. **Sweet J, Mitchell L, Narouze S et al. (2015):** Occipital nerve stimulation for the treatment of patients with medically refractory occipital neuralgia: congress of neurological Surgeons' systematic review and evidence-based guideline. *Neurosurgery*, 77(3):332–41.
26. **Bovim G, Fredriksen T, Stolt-Nielsen A et al. (1992):** Neurolysis of the greater occipital nerve in cervicogenic headache. *Headache*, 32:175-9.
27. **McNutt S, Hallan D, Rizk E (2020):** Evaluating the evidence: is neurolysis or neurectomy a better treatment for occipital neuralgia? *Cureus*, 12(11):e11461. doi: 10.7759/cureus.11461.
28. **Lozano A, Vanderlinden G, Bachoo R et al. (1998):** Microsurgical C-2 ganglionectomy for chronic intractable occipital pain. *J Neurosurg.*, 89:359-65.
29. **Stechison M, Mullin B (1994):** Surgical treatment of greater occipital neuralgia: an appraisal of strategies. *Acta Neurochir (Wien)*, 131:236-40.
30. **Jansen J, Bardosi A, Hildebrandt J et al. (1989):** Cervicogenic, hemicranial attacks associated with vascular irritation or compression of the cervical nerve root C2. *Clin Manifest Morphological Findings Pain*, 39:203-12.
31. **Schwedt T, Dodick D, Trentman T et al. (2007):** Response to occipital nerve block is not useful in predicting efficacy of occipital nerve stimulation. *Cephalalgia*, 27:271-4.
32. **Stechison M (1997):** Outcome of surgical decompression of the second cervical root for cervicogenic headache. *Neurosurgery*, 40:1105-6.
33. **Newman S, Steed L, Mulligan K (2004):** Self-management interventions for chronic illness. *Lancet*, 364(9444):1523–37.
34. **Poletti C (1983):** Proposed operation for occipital neuralgia: C-2 and C-3 root decompression. *Neurosurgery*, 12: 221-224.
35. **Mirande M, Smith H (2022):** The potential roles of cervical plexus abnormalities in occipital neuralgia: an anatomic variant explored. *Diagnostics*, 12: 139. doi: 10.3390/diagnostics12010139.