

Tracheal Resection and Reconstruction: Predictors of Postoperative Tracheal Restenosis

Gamal M. Shalaby^{*1}, Ahmed K. Abdallah², Mohamed-Adel F. Elgamel², Rami A. Sabri²

Departments of Cardiothoracic Surgery, ¹Faculty of Medicine, Helwan University and

²Faculty of Medicine, Mansoura University, Egypt

*Corresponding author: Gamal Mansour Shalaby, Mobile: (+20) 01010585804, E-mail: gmansour-cts@med.helwan.edu.eg

ABSTRACT

Background: Tracheal resection and reconstruction (TRR) is a highly challenging mission to any tracheal surgery group. New advances in tracheal surgery declared by Barclay when first trial of tracheal resection and reanastomosis was performed. After that, trials began to allow more tracheal segment to be resected.

Aim: It was to determine predictors of postoperative tracheal restenosis.

Patients and Methods: This retrospective study was conducted on twenty-four patients who underwent TRR that done in Cardiothoracic Surgery Department, Mansoura University Hospital from January 2014 till July 2022. Inclusion criteria included patients with tracheal stenosis of any age, of both sexes, and patients with benign or malignant tumors. Exclusion criteria included immunocompromised patients, diffuse tracheal stenosis, and autoimmune tracheal lesions or tracheal stenosis less than 50% of normal tracheal diameter.

Results: Restoration of normal airway continuity was succeeded in 20 cases (83.3%) and failed in 4 cases (16.7%); 3 cases (75%) due to restenosis and one case (25%) due to anastomotic dehiscence due to epileptic fit. Three cases needed postoperative stenting; one (33.3%) showed good result, one (33.3%) complicated by stent migration, and the last case (33.3%) needed stent removal through anterior tracheotomy and permanent tracheostomy.

Conclusion: Early and regular follow-up visits for patients with prolonged mechanical ventilation after discharging home, ensuring good preoperative preparations for patients with epilepsy with 6 months convulsion free period before surgery and avoiding usage of unipolar diathermy for lateral tracheal dissection could decrease postoperative tracheal restenosis for patients' undergone tracheal resection and reconstruction.

Keywords: Trachea, Tracheal Resection and Reconstruction, Tracheal Stenosis, Anastomotic Complications.

INTRODUCTION

Tracheal resection and reconstruction (TRR) is a highly challenging mission to any tracheal surgery group⁽¹⁾.

Tracheal surgery was started by Aretaeus and Galen in the second Century. New advances in tracheal surgery was declared by Barclay when first trial of tracheal resection and reanastomosis was performed but was limited by removal of not more than 2 cm of the whole tracheal length. The fact that we can't resect more than 4 tracheal rings inhibited more advanced tracheal surgery⁽²⁾.

After that, trials were done to mobilize the thoracic tracheal segment. That trials found that division of the inferior pulmonary ligament and right hilar mobilization facilitate resection of more than 4 tracheal rings and its re-anastomosis found to be applicable, but this also can be achieved by cervical flexion that deliver extrathoracic tracheal segment into the mediastinum⁽³⁾. Later, Grillo⁽³⁾ started the new era of the tracheal surgery by using of different types of tracheal release maneuvers that allowed resection of longer tracheal segment. So, outcome of TRR became gradually improving with reduction in postoperative complications.

AIM OF STUDY

It is to determine predictors of postoperative tracheal resection.

PATIENTS AND METHODS

This was a retrospective, record analysis, descriptive study conducted on all patients who underwent TRR that done in Cardiothoracic Surgery Department, Mansoura University Hospital from January, 2014 till July, 2022 (24 cases). Collected data included patients' demographics, presenting symptoms, comorbidities, stenosis characteristics, and vocal fold mobility was studied as well. All patients were primarily evaluated by bronchoscopy and computed tomography (CT) scan.

Ethical approval:

Ethics approval was granted by the Institutional Review Board in Faculty of Medicine, Mansoura University (Code Number: MD.20.6.334).

Patients' consents were waived due to it was a case record study and with a retrospective nature. All authors had read the author rules and gave their agreement for this work to be published.

Inclusion criteria: included patients with tracheal stenosis of any age of both sexes and patients with benign or malignant tumors.

Exclusion criteria: included immunocompromized patients, diffuse tracheal stenosis, autoimmune tracheal lesions or tracheal stenosis less than 50% of normal tracheal diameter.

Preoperative management:

All patients were assessed before surgery by history taking and general & local clinical examination. Laboratory investigations were done including full CBC, renal function tests, liver function tests, and bleeding profile.

All patients were assessed by preoperative rigid bronchoscopy to assess the trachea for inflammation, site of the lesion, grade of stenosis according to **Cotton Mayer classification**⁽⁴⁾, quality of the airway above and below the lesion, possibility of bronchoscopic dilatation to allow endotracheal tube to pass through the lesion and taking tissue biopsy when needed. Dynamic rigid bronchoscope was done without muscle relaxant to detect extent of tracheomalacia.

Intraoperative management:

The most common used incision was a low collar incision that was done for proximal and mid tracheal lesions. In more distal lesions, additional manubriotomy incision was done. In cases of carinal lesions, full sternotomy was the approach. Dissection of anterior surface of trachea was done for all cases. The tracheal lesion was incised midway between its upper and lower borders then lateral dissection was done cautiously. The distal part of endotracheal tube (ETT) was then pulled from distal trachea to its proximal part then cross field ventilation was started.

If there was tension on suture line, supra hyoid release was done in upper and mid tracheal lesions, while hilar release was used in carinal reconstruction. The two edges of trachea were then sutured by interrupted 4-0 vicryl sutures. The endotracheal tube that was placed in distal trachea was withdrawn and pushing the oral endotracheal tube to pass through distal trachea and the neck becomes flexed. A subcutaneous drain was placed, and the wound was then closed. Rigid bronchoscopy was done routinely immediately postoperative.

Postoperative management:

After surgery, follow-up rigid bronchoscopy was done 2 days, 5 days and 2 weeks to assess the suture line and if there were anastomotic complications.

Statistical analysis

Statistical analysis was done by the use of SPSS statistical software (SPSS, Inc., Chicago, IL, USA). Qualitative data were represented in the form of number and frequency, while quantitative data were represented in the form of mean ± standard deviation (mean ± SD). Kolmogrov-smirov test was used to test normality of quantitative data. Chi square (χ^2) test was used to compare qualitative data. Results were considered significant if p value was less than or equal 0.05.

RESULTS

Twenty-four patients underwent TRR were studied. Of which, 20 cases (83.3%) were males and only 4 cases (16.7%) were females. We have 2 cases under age of 20 years (8.3%), 15 cases (62.5%) between 20 and 39 years, and 7 cases (29.2%) aged 40 years old or more (**Table 1**). We had 4 (16.7%) diabetic patients, 3 (75% of all diabetic patients in the studied group) showed glycemic control difficulties.

Table (1): Demographic data

Age (year)	Sex		χ^2	P
	Male, n (%)	Female, n (%)		
<20y	0 (0.0)	2 (50.0)	15.942	<0.001*
20-39y	14 (70.0)	1 (25.0)		
>= 40y	6 (30.0)	1 (25.0)		
Total	20 (83.3)	4 (16.7)		

*: Significant statistical difference

Causes of tracheal stenosis in our study are shown in **Table 2**. The main cause was post intubation. Presenting symptoms and signs are shown in **Table 2**. The main symptoms were stridor and dyspnea.

Table (2): Caused and presenting symptoms and signs of tracheal stenosis

Subjects (n = 24)	
Causes:	
Post-intubation	20 (83.3%)
Tumor	2 (8.3%)
Tracheomalacia	2 (8.3%)
Symptoms and signs*:	
Stridor	13 (54.2%)
Dyspnea	11 (45.8%)
Cough	9 (37.5%)
Hemoptysis	1 (4.2%)
Cyanosis	1 (4.2%)

*Number is >24 as some patients had >1 symptom and/or sign.

Majority (83.3%) of cases in our study had tracheal lesions at the upper third. Only one (4.2%) case had tracheal lesion at mid-trachea and another one (4.2%) at lower third (**Figure 1**). Length of stenotic tracheal segment needed to be resected as assessed by CT chest, preoperative bronchoscopy and intraoperative findings is shown in (**Figure 2**). **Cotton Mayer**⁽⁴⁾ Classification assessed by CT chest, preoperative bronchoscopy, and intraoperative findings is shown in (**Figure 3**).

The main surgical approach in our study was neck collar incision as it used for upper tracheal lesions (used in 91.6% of cases). Combined neck collar and maubriotomy incisions used once for mid tracheal lesion. Full sternotomy also used once for the only case of lower tracheal lesion.

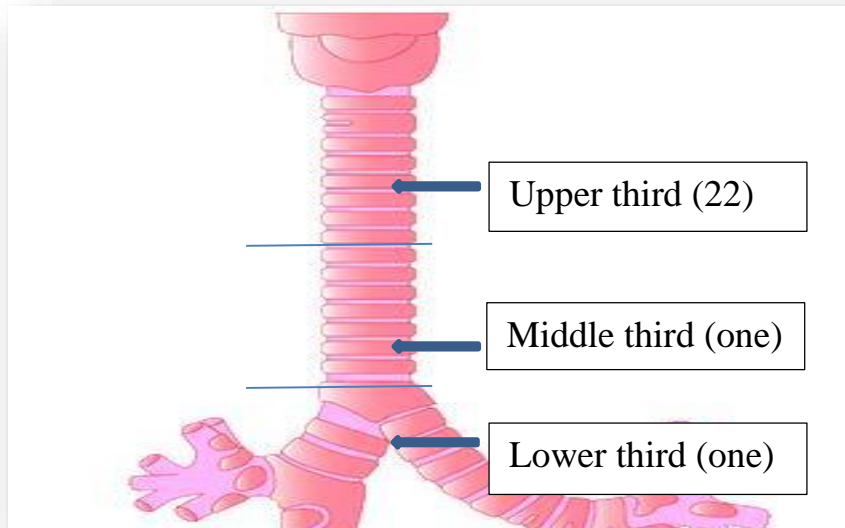


Figure (1): Site of tracheal lesions in our studied group.

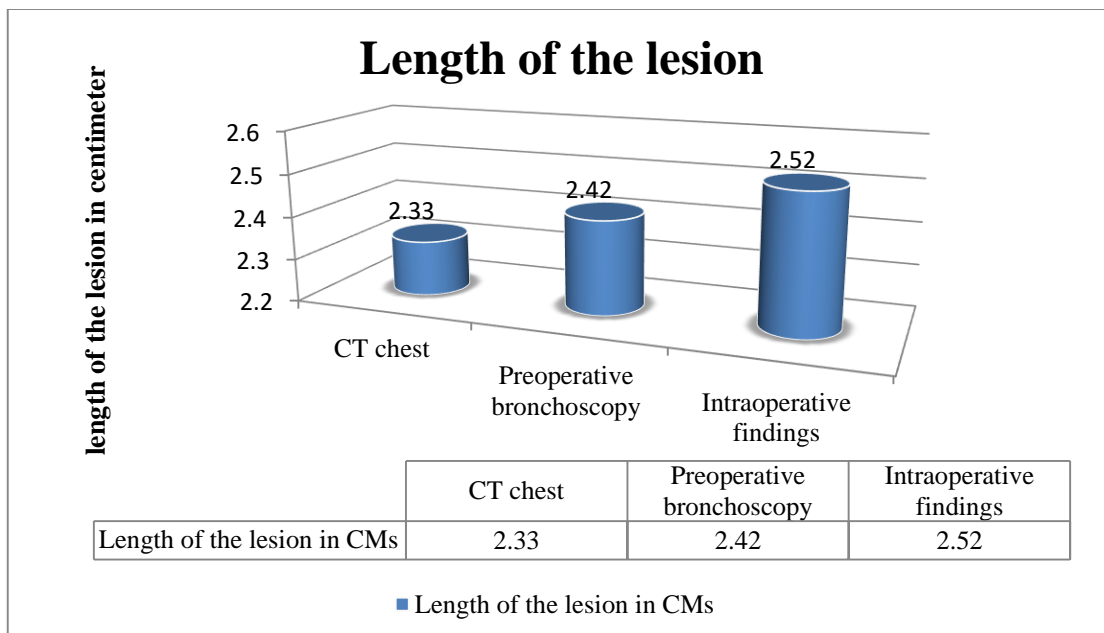


Figure (2): Comparison between lengths of tracheal lesion as assessed by CT chest, preoperative bronchoscopy, and intraoperative findings in the studied group.

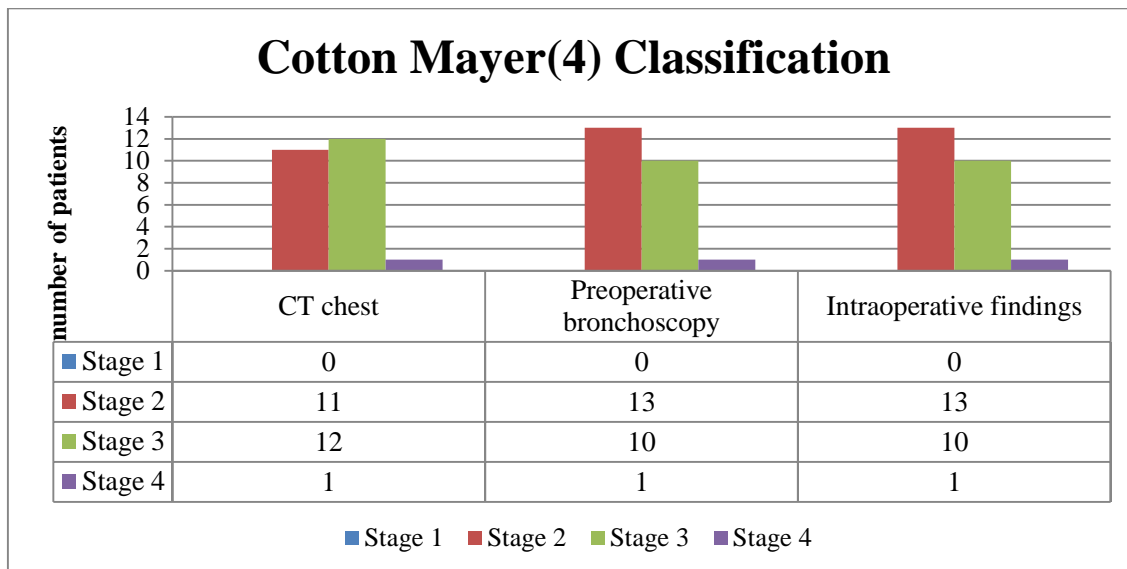


Figure (3): Staging of the studied group of patients by Cotton Mayer⁽⁴⁾ classification by using CT chest, preoperative bronchoscopy, and intraoperative findings.

Dissection of anterior surface of tracheal wall was done in all cases (100%). Additional suprahyoid release was needed in 25% of cases, while hilar release was used in only one case (4.2%). Cardio-pulmonary bypass (CPB) machine was used in only one (4.2%) case of carinal reconstruction. Pericardial patch was used also in one case (4.2%) with iatrogenic injury to posterior membranous tracheal wall. We performed trachea-tracheal anastomosis in 19 cases (79.2%) and trachea-cricoid anastomosis in 4 cases (16.7%), while carinal reconstruction was performed only in one case (4.2%).

As regard postoperative complications, granulation tissue formed in 6 cases (25%); mild form was found in 3 cases (12.5%) and the other 3 cases (12.5%) showed severe form ended by restenosis. We didn't have any case complicated by fistula formation. Only one case (4.2%) complicated by tracheal dehiscence secondary to epileptic fits. We had only one case (4.2%) of laryngeal edema but didn't need reintubation. We had also one case (4.2%) of unilateral vocal cord paralysis secondary to recurrent laryngeal nerve injury.

Restoration of normal airway continuity failed in 4 cases in our study; 3 cases (75%) due to restenosis and one case (25%) due to anastomotic dehiscence secondary to epileptic fits. Three cases (12.5%) needed postoperative stenting; one case (33.3%) showed good result, one (33.3%) complicated by stent migration, and the last case (33.3%) needed removal of stent through anterior tracheotomy and permanent tracheostomy (**Table 3**).

Most cases in our study stayed 2 days in intensive care unit (ICU), 4 days in ward, and were discharged home after 5 days follow-up bronchoscopy had been done without complications. The mean ICU stay in our study was 5.04 ± 6.62 days ranging from 2 to 30 days and mean hospital stay was 9.17 ± 9.08 days ranging from 5 to 45 days.

Table (3): Results of tracheal resection and reconstruction (TRR) among the studied group.

Results	Patients=24
Restoration of normal airway	20 (83.3%)
Failed TRR	4 (16.7%)
Need postoperative tracheostomy	3 (12.5%)
Need postoperative stenting	3 (12.5%)

*Number is >4 as some patients had >1 TRR result

We didn't have any intraoperative, early or late mortality during first year postoperative, but during follow-up we found that there were 2 mortality cases (8.3%) after that; one case (50%) due to pneumonia secondary to tracheostomy about 2 years after surgery and another case (50%) due to stent migration that was placed after one year of tracheostomy placement due to failed TRR.

DISCUSSION

Although there are many non-surgical tracheal interventional modalities such as balloon dilatation, laser ablation, and stenting; TRR should remain the treatment of choice for tracheal stenosis and tracheal tumors⁽⁵⁾. This retrospective study was conducted on 24 patients with tracheal stenosis needed tracheal resection and reconstruction. The majority of cases in our study were adults between 20 to 39 years (15 cases = 62.5%). The mean age was 34.58 ± 10.95 years. Only two cases (8.4%) were under 20 years. We had 20 males (83.3%) in our study and only 4 females (16.7%).

In **Grillo and Donahue⁽⁶⁾**, the mean age was 44 years. There were 138 patients of 503 patients (27.4%) between 20 and 39 years. In series of **Morshed et al.⁽⁷⁾** conducted on 37 patients, 78.4% (29 patients) were males while only 21.6% of the studied group (8 patients) were females.

In our study, the main cause of tracheal stenosis was post intubation, which was responsible for 83.3%

(20 patients) of cases; 55% of them (11 cases out of 20) needed tracheostomy tube after extubation as they were presented with stridor. There were only 2 patients (8.3%) suffering from tracheomalacia and another 2 patient (8.3%) had tracheal tumor.

In **Gaissert et al.**⁽⁸⁾ study, the main cause of tracheal stenosis was mechanical ventilation that was accounting for 61.4% (86 out of 140 patients). There were 12 patients (8.6%) with malignant tracheal tumor and only four patients (2.9%) with tracheomalacia. In **Segura-Salguero et al.**⁽⁹⁾ study that was conducted on 43 patients, long period on mechanical ventilation was the main reason (72%) for tracheal stenosis.

There is no conflict that post intubation and post tracheostomy are main causes of tracheal stenosis as there are a lot of causes that need endotracheal intubation and tracheostomy due to diseases in other systems but airway can't be kept patent without those procedures to maintain adequate ventilation rather than primary airway lesion. That's why; there was no significant difference as regard causes of tracheal stenosis between patients in our study in comparison with the other studies.

Stridor, dyspnea, and cough were the main presenting symptoms in our studied group. There were 13 cases complaining of stridor; 11 cases (45.8%) complaining of dyspnea and 9 cases (37.5%) presented also with cough. There was only one case (4.2%) suffering from cyanosis and another one case (4.2%) presented by hemoptysis. In **Segura-Salguero et al.**⁽⁹⁾, dyspnea on exertion was the most common presenting symptoms (76.7%) followed by stridor (39.5%). In a study done by **Shweel et al.**⁽¹⁰⁾, ten patients out of 24 patients of the studied group (41.7%) had grade III and 14 (58.3%) had grade IV dyspnea. Seventeen patients (70.8%) had stridor.

In our study, most of cases had tracheal stenosis at the upper third (22 cases = 91.6%). Tracheal stenosis at the middle third presented only in one case (4.2%) and another case (4.2%) at the lower third. Site of tracheal stenosis was mainly in the upper third as the main reason of tracheal stenosis in our study was post intubation (83.3%) and tracheostomy (45.8%). The other 2 cases (8.3%) whose site of their tracheal lesions was in middle and lower thirds were due to tracheal tumor.

The mean length of tracheal lesion assessed by CT chest in our study was 2.40 ± 0.79 cm and by preoperative bronchoscopy was 2.85 ± 0.81 cm, while the intraoperative assessment of the stenotic tracheal length was 2.92 ± 0.82 cm ranging from one to 5.5 cm without significant difference. Assessment of degree of tracheal stenosis in our studied group of patients depends on **Cotton Mayer**⁽⁴⁾ classification by using CT chest, preoperative bronchoscopy, and intraoperative findings. We found that assessment of degree of tracheal stenosis by using CT chest had 91.7% accuracy in comparison to intraoperative finding (as CT accurately measured degree of tracheal stenosis in

22/24 patients). We found also the preoperative rigid bronchoscopy had 100% accuracy in detection of degree of tracheal stenosis.

Morshed et al.⁽⁷⁾ cleared the degree of tracheal narrowing was correctly assessed by preoperative fiberoptic bronchoscopy in all patients except only 2 (its accuracy was 97.3% when compared to operative data). CT measurements correctly estimated 36/37 patients (its accuracy was 97.3% when compared to operative data).

Our own experience in this point shows that as regard CT findings, its results showed overestimation in some cases as secretions at site of tracheal lesions gives false impression. Although, its accuracy is high while as regard using preoperative bronchoscopy, we thought using rigid bronchoscopy is very sensitive with high accuracy.

All cases in our series needed anterior release. We needed to do suprahyoid release in addition to anterior release in 6 cases (25%). The length of the resected segment of trachea in cases whose suprahyoid release was done was 2.5 cm or more. There was only one case that needs hilar release. That case had carcinoid tumor near the carina at the lower third, so we used full sternotomy approach to reach the site of tumor and that's why, we can't do suprahyoid release, so the best release maneuver option in addition to anterior release was to do hilar release.

In a large series done by **Broussard and Mathisen**⁽¹¹⁾ at Massachusetts General Hospital, Boston, MA, USA, on patients that need tracheal surgery for post intubation narrowing, laryngeal release was used only in 9% of cases. The need for laryngeal release increased in cases of redo tracheal surgery. The average length of trachea resected with laryngeal release maneuver was 4.4 cm. **Mitchell et al.**⁽¹²⁾ series was conducted on 134 cases that need carinal reconstruction and found that hilar release maneuvers were needed in 50 cases.

Trachea-cricoid anastomosis was done in 4 cases (16.7%) in our study due to subglottic stenosis. Trachea-tracheal anastomosis was done in 19 cases (79.2%). We needed to do carinal reconstruction in only one case. This case had carcinoid tumor near carina so, we used full sternotomy approach then we used cardiopulmonary bypass to maintain oxygenation without using tracheobronchial tree for that and to facilitate dealing with the site of dissection that made resection and carinal reconstruction easier. We used also intrapericardial hilar release after releasing of inferior pulmonary ligament to decrease tension on suture line. As regard to anastomotic complications in our study, granulation tissue formation was found to be occurred in 6 patients (25%) on follow-up bronchoscopy after 5 days of surgery. Three (12.5%) of which had mild granulation tissue and cleaned out at this session and so, they become totally free on follow-up bronchoscopy after 2 weeks of surgery. The other 3 patients (12.5%) had moderate to severe granulation

tissue formation and those patients developed tracheal restenosis. Two of those 3 cases with tracheal restenosis treated with permanent tracheostomy, while the third case was 7 years old female child that underwent frequent sessions of repeated tracheal dilatation by using rigid bronchoscopy and then placement of endotracheal stenting by silicon stent. Only one case (4.2%) complicated by tracheal dehiscence secondary to epileptic fits. Tracheostomy tube was inserted after tracheal dehiscence had been confirmed.

In series done by **Auchincloss and Wright**⁽¹⁴⁾, 9.0% of patients had anastomotic complications. These complications were in the form of tracheal restenosis (4%), tracheal dehiscence (4%), and granulation tissue formation (only 1%). Fistulous connection between trachea and esophagus or innominate artery was a rare complication (only six case).

Mitchell et al.⁽¹²⁾ series was conducted on 134 cases with carinal reconstruction. The rate of anastomotic complications in this study was 17.2% (23 patients). This included necrosis, narrowing, and formation of granulation tissue on suture line.

We have slightly higher degree of anastomotic complications especially as regard restenosis. All 3 cases who complicated by restenosis were in the first 6 cases of our studied group and the operative details of these 3 patients confirmed over dissection by unipolar diathermy at anastomotic tracheal ends.

As regard non-anastomotic complications in our study, we had only one case with glottis dysfunction secondary to recurrent laryngeal nerve injury. We had also 4 cases (16.7%) with superficial wound infection, 3 (75%) of which were diabetic.

As regard non-anastomotic complications in **Auchincloss and Wright**⁽¹⁴⁾ series, surgical wound infection was found in about 7% of patients. Laryngeal dysfunction was found in about 3% of patients. Usually laryngeal edema that need intervention is not common. There was no difference clearly found between our results as regard non-anastomotic complications in comparison with other series. We should emphasize strict glycemic control to minimize wound infection in our locality. We have only 2 mortality cases (8.3%) in our study. One of them was due to stent migration and the other patient died 2 years later secondary to pneumonia after doing tracheostomy.

CONCLUSIONS

Early and regular follow-up visits for patients with prolonged mechanical ventilation after discharging home to give a chance for detection of early signs and symptoms of tracheal stenosis, ensuring good preoperative preparations for patients with epilepsy with 6 months convulsion free period before surgery and avoiding usage of unipolar diathermy for lateral tracheal dissection could decrease postoperative tracheal restenosis for patients undergoing TRR. Also, performing urgent rigid bronchoscopic dilation for patients come to emergency room with acute stridor

instead of doing tracheostomy to decrease stenotic tracheal segment that need resection to decrease possibility of postoperative complications especially tracheal restenosis.

Conflicts of interest: The authors declare that they have no competing interests.

Funding sources: This research did not receive any specific grant. It is self-funded.

Availability of data and materials: The data that support the findings of this study are available from the corresponding author upon request.

ACKNOWLEDGEMENTS

Special thanks to Dr. Amr Abdullatif, associate Professor of Cardiothoracic Surgery, Faculty of Medicine, Mansoura University, for his great work in management of patients in this research work.

REFERECES

1. **Srivastava P, Kumar A, Asaf B (2017):** Tracheal reconstruction under cross-field anesthesia. *J Anesthesia Crit Care Open Access*, 9(1):00331.
2. **Belsey R (1950):** Resection and reconstruction of the intrathoracic trachea. *Br J Surg.*, 38(150):200-205.
3. **Grillo H (1973):** Reconstruction of the trachea. Experience in 100 consecutive cases. *Thorax.*, 28(6):667-679.
4. **Myer C, O'Connor D, Cotton R (1994):** Proposed grading system for subglottic stenosis based on endotracheal tube sizes. *Ann Otol Rhinol Laryngol.*, 103(4 Pt 1):319-23.
5. **Rahbar R, Brown L, Folkman J et al. (2007):** Role of vascular endothelial growth factor A in children with acquired airway stenosis. *Ann Otol Rhinol Laryngol.*, 116(6):430-435.
6. **Grillo H, Donahue D (1996):** Post intubation tracheal stenosis. *Semin Thorac Cardiovasc Surg.*, 8(4):370-380.
7. **Morshed K, Trojanowska A, Szymanski M et al. (2011):** Evaluation of tracheal stenosis: comparison between computed tomography virtual tracheobronchoscopy with multiplanar reformatting, flexible tracheofiberoscopy and intra-operative findings. *Eur Arch Otorhinolaryngol.*, 268(4):591-597.
8. **Gaissert H, Grillo H, Mathisen D et al. (1994).** Temporary and permanent restoration of airway continuity with the tracheal T-tube. *J Thorac Cardiovasc Surg.*, 107(2):601-606.
9. **Segura-Salguero J, Díaz-Bohada L, Ruiz A (2022):** Perioperative management of patients undergoing tracheal resection and reconstruction: a retrospective observational study. *Brazil J Anesthesiol.*, 72(3):331-337.
10. **Shweel M, Shaban Y (2013):** Radiological evaluation of post-traumatic tracheal stenosis using multidetector CT with multiplanar reformatted imaging and virtual bronchoscopy: Comparison with intraoperative findings. *Egypt J Rad and Nucl Med.*, 44:513-521.
11. **Broussard B, Mathisen D (2018):** Tracheal release maneuvers. *Ann Cardiothorac Surg.*, 7(2):293-298.
12. **Mitchell J, Mathisen D, Wright C et al. (1999):** Clinical experience with carinal resection. *J Thorac Cardiovasc Surg.*, 117(1):39-53.
13. **Grillo H, Donahue D, Wright D et al. (1995):** Postintubation tracheal stenosis. Treatment and results. *J Thorac Cardiovasc Surg.*, 109(3):486-493.
14. **Auchincloss H, Wright C (2016):** Complications after tracheal resection and reconstruction: prevention and treatment. *J Thorac Dis.*, 8(2):s160-s167.